



# Easy and Simple Techniques to Reconstruct Natural Nailfold with the Wrap-around Flap for Finger Reconstruction

Takeo Matsusue, MD<sup>1</sup>

<sup>1</sup>Department of Plastic Reconstructive Surgery, Kansai Electric Power Hospital, Osaka, Japan

Arch Plast Surg 2022;49:764–768.

Address for correspondence Takeo Matsusue, MD, Department of Plastic Reconstructive Surgery, Kansai Electric Power Hospital, 2-1-7 Fukushima, Fukushima-ku, Osaka, 553-0003, Japan (e-mail: matsusue.takeo@c5.kepco.co.jp).

## Abstract

The wrap-around flap (WAF) has become a popular approach to thumb reconstruction because the results are functionally and cosmetically excellent. By modifying to a partial toenail transfer, the WAF can also be used for finger reconstruction. However, performing cosmetically superior finger reconstruction is a significant challenge because it is difficult to reconstruct the natural nailfold by partial nail transplantation, although partial nail transplantation is required to reconstruct a narrow fingernail. One side of the reconstructed lateral nailfold tends to be a missing nail margin, and one side of the proximal nailfold angle tends to be retracted. Based on the rationale that loss of the lateral nailfold volume due to the postoperative tension of the volar flap would result in a missing nail margin, the volume of the lateral nailfold was maintained with a single thread that was passed from the nail to the volar flap. Additionally, half of the proximal nailfold from the nail plate was elevated to advance it forward. The results indicated that a cosmetically natural nailfold was achieved with the WAF approach to finger reconstruction. These easy and simple techniques enable reconstruction of a cosmetically natural nailfold using WAF for finger reconstruction.

## Keywords

- ▶ nail
- ▶ finger
- ▶ free flaps
- ▶ finger injuries
- ▶ surgical flaps

## Introduction

Similar to the face, the hand is always exposed. Despite good hand function, many patients with finger defects or deformities may have cosmetic impairment. Therefore, finger reconstruction must be high quality not only in terms of function but also in terms of aesthetics.

The wrap-around flap (WAF) has become popular for thumb reconstruction because it provides functionally and cosmetically excellent results. However, if the nail of the great toe is totally harvested for reconstruction of a finger with WAF, the outcome may be a reconstructed finger that is too thick compared with the contralateral finger. Therefore,

various modifications have been reported, including the following three methods: partially harvesting the nail, thinning the flap on the plantar part, and combining a small vascularized partial toenail flap and a local finger flap.<sup>1–5</sup> However, the partial nail transplantation tends to result in a missing nail margin, meaning a finger that appears to have no lateral nailfold on one side.<sup>6,7</sup> Moreover, the natural roundness from the proximal to the lateral nailfold tends to be lost. For these reasons, some surgeons do not think the partial nail transplantation should be performed.<sup>6,7</sup>

Reconstructing a cosmetically natural nailfold is a significant challenge in finger reconstruction. Nailfold reconstruction

received  
March 30, 2022  
accepted after revision  
June 30, 2022

DOI <https://doi.org/10.1055/s-0042-1757573>.  
eISSN 2234-6171.

© 2022. The Korean Society of Plastic and Reconstructive Surgeons. All rights reserved.

This is an open access article published by Thieme under the terms of the Creative Commons Attribution-NonDerivative-NonCommercial-License, permitting copying and reproduction so long as the original work is given appropriate credit. Contents may not be used for commercial purposes, or adapted, remixed, transformed or built upon. (<https://creativecommons.org/licenses/by-nc-nd/4.0/>)

Thieme Medical Publishers, Inc., 333 Seventh Avenue, 18th Floor, New York, NY 10001, USA

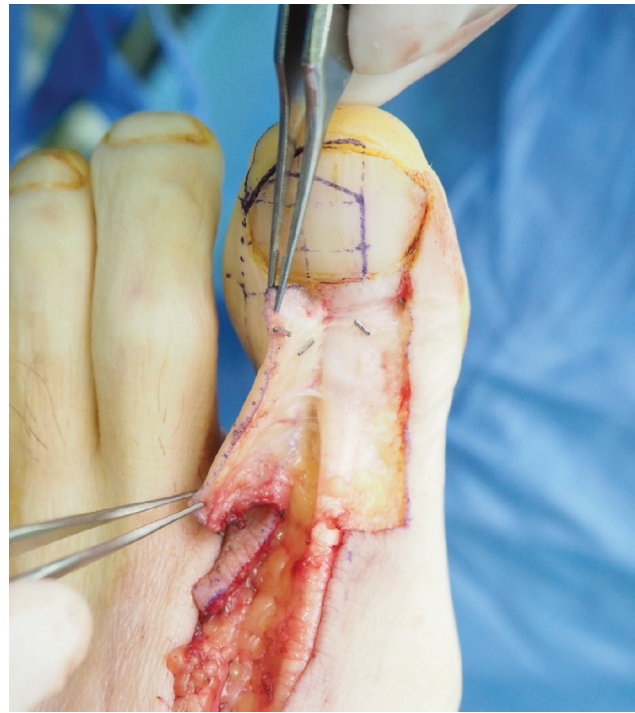techniques are required that are easy to perform, are simple in terms of complexity and understanding, and produce stable results. However, few studies have investigated these techniques. Based on direct experience with using partial nail transplantation for the WAF, this author–surgeon devised simple methods to reconstruct natural lateral and proximal nailfolds and describes these techniques and results herein.

**Idea**

The WAF design for the great toe is as follows: the nail width is 1 to 2 mm wider than the contralateral fingernail, and the skin reconstructing the pulp is about the same size as the contralateral finger. These measurements are based on research describing the author’s 20 WAF cases, which showed that the average width reductions for the distal phalanx included in WAF was 1.2 mm and the flap circumference at the proximal nailfold was not greatly changed.<sup>8</sup> It is important that the WAF design includes the skin area of the lateral nailfold to be reconstructed.

The area of the proximal nailfold is elevated from the nail plate up to about half of the nail to advance it forward (►Fig. 1). To ensure blood circulation, it is important not to damage the veins of the proximal nailfold during elevation. Harvesting the nail is performed using the partial nail and dorsal split distal phalanx of the great toe. The interphalangeal joint and plantar cortical bone of the great toe are preserved. This approach is a modification of the Doi method to partially harvest the width of the nail and the distal phalanx.<sup>9,10</sup> The plantar part of the WAF is elevated as a thin flap as thin as the finger pulp to avoid becoming a bulging pulp and ensure that it is not elevated above the periosteum or paratenon.<sup>10</sup> Particularly, the reconstructed part of the lateral nailfold and fingertip is elevated with a small portion of subcutaneous fatty tissue.

The author considered that volar flap tension occurs regardless of the method used in a direction away from the reconstructed lateral nailfold. This causes a loss of lateral nailfold volume, which subsequently results in a missing nail margin (►Fig. 2). Therefore, the author devised an approach to maintain the amount of tissue needed for reconstructing the lateral nailfold. A single thread was passed through the nail plate to suppress the displacement of the volar flap so that the volume of the lateral nailfold can be maintained

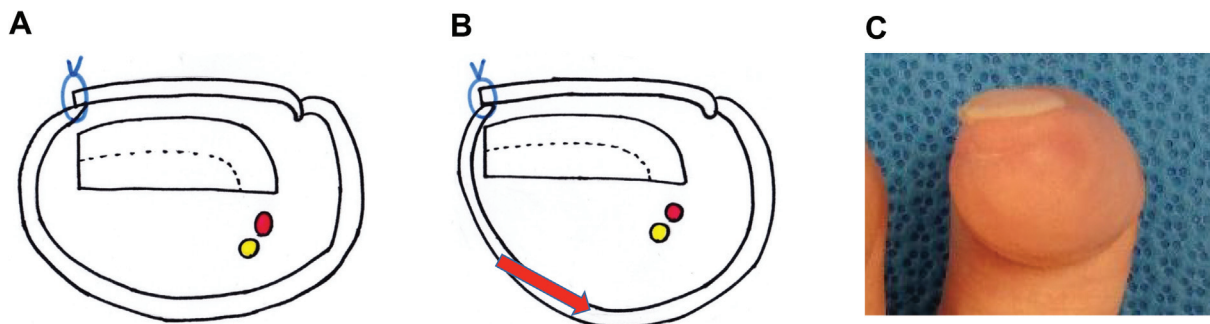


**Fig. 1** Dorsal flap elevation. The proximal nail fold is elevated from the nail plate sufficiently to advance it forward.

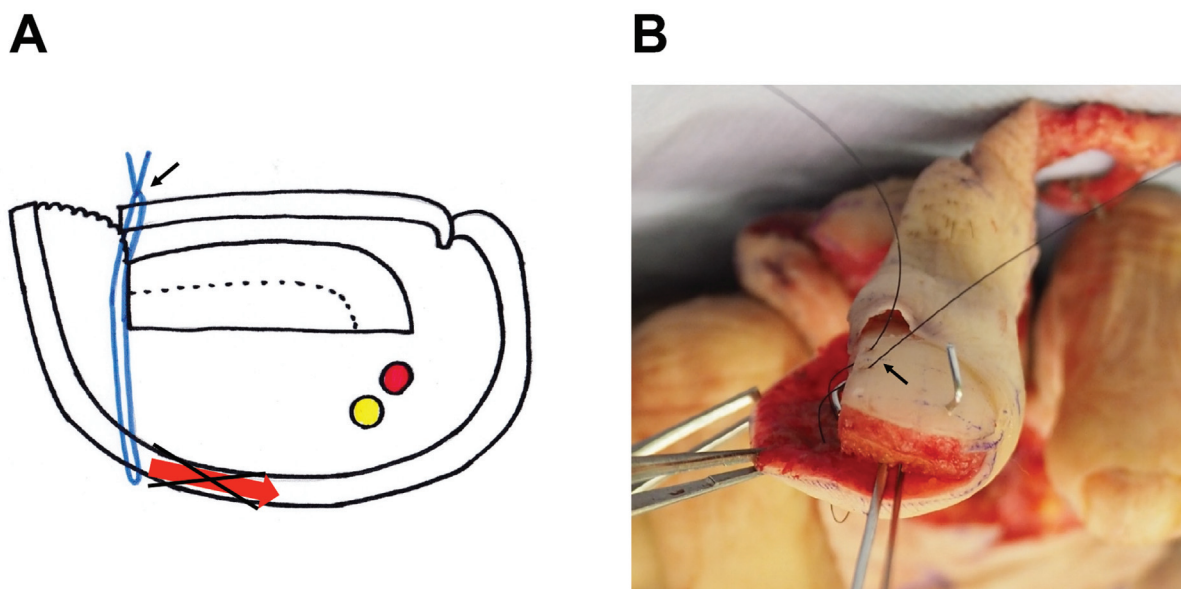
(►Fig. 3). Careful attention is needed for this step: if tying this thread tightly, flap blood circulation may become poor. Therefore, this thread must be tied while checking the flap color after flap revascularization.

Further, the proximal nailfold is advanced to the position balanced with the contralateral proximal nailfold angle. The proximal nailfold can be easily advanced without tension because the half proximal nailfold is elevated from the nail plate when the flap is harvested. The fingertip and lateral nailfold skin are not forcibly closed, resulting in an open wound (►Fig. 4).

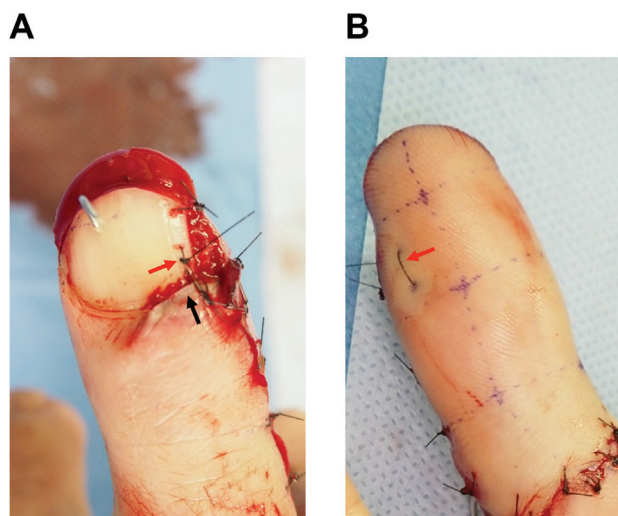
Postoperatively, a commonly used topical medication is applied to the wound, and no other special treatment is required. In most cases, the epithelialization of the open wound is completed in a few weeks. The suture used for the lateral nailfold reconstruction is maintained in place for 2 to 3 months. These techniques stably reconstruct the natural bulge of the lateral nail fold and the natural roundness of the



**Fig. 2** Cause of the missing nail margin. If simply suturing the volar flap, the volume of the lateral nail fold is lost due to the tension of the volar flap: (A) ideal outcome; (B) potential actual outcome; (C) missing nail margin. Red arrow: direction of the flap tension.



**Fig. 3** Lateral nailfold reconstruction. A single thread suppresses the displacement of the volar flap: (A) cross-section view; (B) intraoperative view, before suturing. *Black arrow*: thread for the lateral nailfold reconstruction.



**Fig. 4** Proximal nailfold advancement and maintaining the volume of lateral nailfold. The tip and lateral nail fold are made open: (A) dorsal view; (B) palmar view. *Black arrow*: advanced proximal nail fold. *Red arrow*: thread that suppresses the displacement of the volar flap.

proximal nail fold, yielding a successful cosmetic outcome (→Fig. 5). The author used this method of reconstruction in more than 30 cases, of which flap necrosis occurred in 1 case.

The donor site was prepared with sufficient time for granulation to grow, and then split-thickness skin grafting was performed. Although nail deformity in the donor site was inevitable, most of the author's patients had few donor-site morbidities, such as gait impairment and pain.

If the design is too large or the elevated plantar part of the great toe is thick, the reconstructed finger pulp becomes bulky, but as long as the design includes the part of the lateral nail fold to be reconstructed, the natural bulge of the lateral nail fold can be reconstructed using just this one thread.

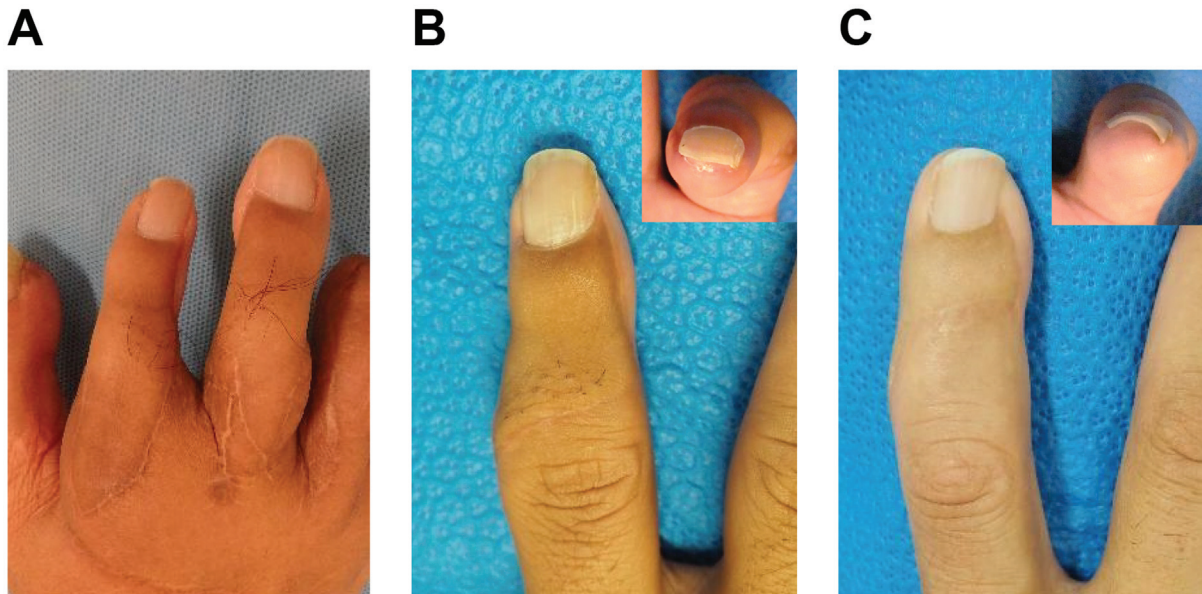
When the reconstructed finger pulp is bulky, secondary volume reduction surgery is the solution. The secondary pulp plasty is performed by making a midlateral skin incision to preserve the reconstructed lateral nail fold, elevating the palmar tissue again, and then reducing the excess tissue.<sup>10</sup> The presented mattress suture technique is included while closing the wound because simple skin closure tends to make the preserved nail fold relatively small caused by postoperative palmar tissue tension.

Written informed consent was obtained from patients for the publication of this article. This study was approved by the Institutional Review Board of Kansai Electric Power Hospital (IRB no. 21-114).

## Discussion

Reconstruction of a natural nailfold using partial nail transplantation for WAF is difficult. The author devised an easy nailfold reconstruction technique based on simple advancement of the proximal nailfold and maintaining the lateral nailfold volume by a single thread.

Several reports have described lateral nailfold reconstruction in WAF. Hirasé et al reconstructed a lateral nailfold using the additional local flap in the recipient finger or the second toe skin flap, which was combined with WAF.<sup>2</sup> Wang et al reconstructed one finger with two osteo-onychocutaneous free flaps taken from the bilateral great toe.<sup>11</sup> Although their method can be used to successfully reconstruct the lateral nailfold, it is technically complicated. In the design by Koshima et al, the contralateral nailfold skin connected only to the great toe tip was added to the partial nail transplantation.<sup>12</sup> In this design, the added lateral nailfold skin was the narrow reverse flap, which may raise concerns for poor blood circulation in this nailfold skin. In contrast, the current author's technique uses only a single thread. Therefore, this approach is definitely



**Fig. 5** Postoperative follow-up at 24 months for three cases. Reconstruction outcomes: (A) 55-year-old, index and middle finger; (B) 36-year-old, index finger; (C) 50-year-old, index finger.

simpler and easier than these other approaches, and blood circulation is stable.

Hirasé et al advanced the proximal nailfold to reconstruct an aesthetic proximal nailfold, and the current author's technique is based on theirs.<sup>2</sup> In addition to that advancement, Hirasé et al also incised and retracted the contralateral proximal nailfold angle.<sup>2</sup> However, the contralateral proximal nailfold angle should be able to be reconstructed without any additional procedures because it has already natural roundness. Furthermore, separating wide area of proximal nailfold may result in poor blood circulation in the area. A key feature of the current author's technique is that the proximal nailfold is separated only up to half of the nail, and no further procedure is performed to the proximal nailfold. Therefore, this technique for reconstructing the natural proximal nailfold is also easy to perform and has a low risk of poor blood circulation.

When the wound is closed, the fingertip and lateral nailfold are intentionally maintained as open with this technique. Few studies have detailed how to close these wounds. The reason why these wounds are made open is that suturing and closing them often causes poor blood circulation in these areas due to skin tension. These open wounds are then contracted and epithelialized, resulting in a naturally rounded fingertip and lateral nailfold. The critical point of lateral nailfold reconstruction is how to maintain the volume of the lateral nailfold, not how to close the wound.

Scar formation and collagen remodeling in humans occurs over several months.<sup>13</sup> During this period, the WAF volar flap will contract in the direction away from the reconstructed lateral nailfold. Therefore, the author keeps the suture used for lateral nailfold reconstruction in place for 2 to 3 months. Despite the potential for inflammation and abscess formation due to this suture, such complications rarely occurred in the author's cases. This lack of complication may be because

the suture was performed with a strength that did not interfere with the local blood circulation of the flap and did not bite into the flap skin.

Most of the author's patients had few donor-site morbidities. The author's method preserves the interphalangeal joint, the plantar cortical bone, and much of the plantar soft tissue of the great toe. These preservations seem to be related to low donor-site morbidity. The author recommends reoperation of the WAF as a salvage procedure in case of flap loss because of the low donor-site morbidity and high success rate. However, the psychological burden on the patient in the reoperation of the WAF is an important concern that cannot be ignored. In fact, the author recommended another WAF reconstruction from the contralateral great toe for one case of flap loss, but the patient declined the offer and instead opted for a prosthetic finger.

The main limitation of the study was that determination of the morphologic improvement of the nailfold was based on the author's subjective evaluation, rather than objective data such as the measured value of the lateral nailfold volume or the angle of the proximal nailfold. Gathering such data will be difficult in terms of study methodology, but these data are of importance and interest for a future study.

Aesthetic nailfold reconstruction is important in finger reconstruction using WAF. This study described techniques for aesthetic nailfold reconstruction by advancing one side of the proximal nailfold and maintaining the volume of the lateral nailfold. These techniques are simple and are technically easy, and the results are stable.

#### Ethical Approval

The study was approved by the Institutional Review Board of Kansai Electric Power Hospital (IRB no. 21-114) and

performed in accordance with the principles of the Declaration of Helsinki.

#### Patient Consent

The patients provided written informed consent for the publication and the use of their images.

#### Conflict of Interest

None declared.

#### Acknowledgments

The author would like to thank Enago ([www.enago.jp](http://www.enago.jp)) for the English language review.

#### References

- 1 Foucher G, Merle M, Maneaud M, Michon J. Microsurgical free partial toe transfer in hand reconstruction: a report of 12 cases. *Plast Reconstr Surg* 1980;65(05):616–627
- 2 Hirasé Y, Kojima T, Matsui M. Aesthetic fingertip reconstruction with a free vascularized nail graft: a review of 60 flaps involving partial toe transfers. *Plast Reconstr Surg* 1997;99(03):774–784
- 3 Hahn SB, Park HJ, Kang HJ, Kang ES. Finger reconstruction with a free neurovascular wrap-around flap from the big toe. *J Reconstr Microsurg* 2001;17(05):319–323
- 4 Koshima I, Moriguchi T, Soeda S, Ishii M, Murashita T. Free thin osteo-onychocutaneous flaps from the big toe for reconstruction of the distal phalanx of the fingers. *Br J Plast Surg* 1992;45(01):1–5
- 5 Kobayashi K, Masuyama N, Nishimura K. Aesthetic reconstruction of fingers and thumbs with the vascularized half-big toenail flap with minimum donor site morbidity. *J Hand Surg Glob Online* 2020;2(04):203–211
- 6 Koshima I, Etoh H, Moriguchi T, Soeda S. Sixty cases of partial or total toe transfer for repair of finger losses. *Plast Reconstr Surg* 1993;92(07):1331–1338, discussion 1339–1341
- 7 Adani R, Marcoccio I, Tarallo L, Fregni U. The aesthetic mini wrap-around technique for thumb reconstruction. *Tech Hand Up Extrem Surg* 2005;9(01):42–46
- 8 Matsusue T, Yoshimi I, Kimura K. Changes in the size of the distal phalanx included in wrap-around flap and in the flap circumference for finger and thumb reconstruction. *J Plast Reconstr Aesthet Surg* 2021;74(10):2776–2820
- 9 Doi K, Hattori Y, Dhawan V. The wrap-around flap in thumb reconstruction. *Tech Hand Up Extrem Surg* 2002;6(03):124–132
- 10 Matsusue T. Evaluation of sensation in volume reduction techniques of a wrap-around flap. *Microsurgery* 2021;41(06):543–549
- 11 Wang Z, Sun W, Lineaweaver WC, et al. Distal finger reconstruction by bilateral lateral hallux osteo-onychocutaneous free flap. *Ann Plast Surg* 2019;82(3, Suppl 2):S157–S161
- 12 Koshima I, Kawada S, Etoh H, Saisho H, Moriguchi T. Free combined thin wrap-around flap with a second toe proximal interphalangeal joint transfer for reconstruction of the thumb. *Plast Reconstr Surg* 1995;96(05):1205–1210
- 13 Gundogan B, Orgill DP. Basic science of wound healing and management of chronic wounds. In: Chung KC, ed. *Grabb and Smith's Plastic Surgery*. 8th ed. Philadelphia, PA: Wolters Kluwer; 2020:9–17