



Pediatrics

Epidemiological and Clinical Presentation of Retinoblastoma among Nepalese Children in 2019

Ben Limbu¹ Prerna Arjyal Kafle² Diwa Hamal Lamichanne² Suresh Raj Pant³ Samyek Shakya⁴
Suresh B.K. Rasaily⁴

¹ Department of Oculoplastic and Reconstructive Surgery, Tilganga Institute of Ophthalmology, National Academy of Medical Sciences, Kathmandu, Nepal

² Department of Oculoplastic and Reconstructive Surgery, Biratnagar Eye Hospital, Biratnagar, Nepal

³ Department of Oculoplastic and Reconstructive Surgery, Geta Eye Hospital, Attariya, Nepal

⁴ Department of Vitreoretinal Surgery, Geta Eye Hospital, Attariya, Nepal

⁵ Department of Oculoplastic and Reconstructive Surgery, Rapti Eye Hospital, Dang, Nepal

Address for correspondence Suresh B.K. Rasaily, MD, Department of Oculoplastic and Reconstructive Surgery, Rapti Eye Hospital, Dang 22400, Nepal (e-mail: srasaly@gmail.com).

South Asian J Cancer 2023;12(2):199–205.

Abstract



Suresh B.K. Rasaily

Keywords

- ▶ affordability
- ▶ chemotherapy
- ▶ clinical presentation
- ▶ epidemiology
- ▶ ethnicity
- ▶ retinoblastoma

Objectives Retinoblastoma (RB) is rare but potentially fatal if left untreated. This study aimed to evaluate the epidemiological profile, clinical manifestation, classification, and affordability of RB treatment among Nepalese children in the year 2019.

Materials and Method A multicentric, multiethnic hospital-based cross-sectional study after ethical approval from the National Health Research Council was conducted from January 2019 to December 2019 by incorporating ophthalmologists all over the nation. Twenty-seven RB centers were selected. All the RB presented in the RB centers either newly diagnosed or ongoing treatment consented to the study were included and failed to consent for the study, RB survivors were excluded from the study. Data based on demographic profile, clinical manifestation, ethnical and geographical distribution, and treatment received were collected in the customized Google Form.

Each case was classified at the time of diagnosis as per the International Classification of Retinoblastoma groups and different treatment modalities offered as per grouping and staging. The affordability of treatment was calculated using a catastrophic approach. **Statistical Analysis** Data were entered into Microsoft Excel 2010 and analyzed using Statistical Package for Social Sciences version 20.

Result A total of 34 RB cases, 21 (61.76%) in ongoing treatment group and 13 (38.2%) in newly diagnosed group presented in the RB centers. Out of total, 32 (64.7%) had unilateral and 12 (35.3%) cases had bilateral involvement. The majority of patients was from Province 1 (35.3%) and belonged to the upper caste (38.2%). Leukocoria was the

DOI <https://doi.org/10.1055/s-0042-1757581> ISSN 2278-330X

How to cite this article: Limbu B, Kafle PA, Lamichanne DH, et al. Epidemiological and Clinical Presentation of Retinoblastoma among Nepalese Children in 2019. South Asian J Cancer 2023;12(2):199–205.

© 2022. MedIntel Services Pvt Ltd. All rights reserved.

This is an open access article published by Thieme under the terms of the Creative Commons Attribution-NonDerivative-NonCommercial-License, permitting copying and reproduction so long as the original work is given appropriate credit. Contents may not be used for commercial purposes, or adapted, remixed, transformed or built upon. (<https://creativecommons.org/licenses/by-nc-nd/4.0/>)

Thieme Medical and Scientific Publishers Pvt. Ltd., A-12, 2nd Floor, Sector 2, Noida-201301 UP, India

most common presentation (73.9%) followed by proptosis, red eye, and phthisis bulbi. More than 75% patients presented at advanced group D (54%) and E (21%) and stage 0 (90%). More than 90% of patients received systemic chemotherapy, and 42.6% received transpupillary thermotherapy. The average cost of RB treatment was estimated to be 521% of the nonfood expense of the family which is unaffordable to almost all cases (100%).

Conclusion Leukocoria is the most common mode of clinical presentation in both unilateral and bilateral RBs. Early diagnosis and appropriate treatment are key to success for saving life, sight, and eye. However, community awareness programs against RB, active referral networks, and the establishment of chemotherapy centers with trained human resources are needed to reduce loss of life, sight, and eye.

Introduction

Retinoblastoma (RB) is the most common primary intraocular tumor of childhood with an incidence of 1 in every 15,000 to 18,000 live births and is considered potentially fatal if untreated.¹ The primary goal of RB treatment is to save the life of a child followed by sight and eye. The treatment outcome has been drastically changed in developed countries while low-income countries are still struggling for improvement. The main reasons are late presentation and inadequate availability of specialized treatment services. The average age of patients of developed countries is 20 months whereas 35 months in developing countries.² Almost half of the patients from low-income countries presented with extraocular disease and 25% presented with distant metastasis as compared with <2% extraocular and <1% distant metastasis in children of high-income countries.^{3,4}

Despite its rarity, RB is potentially fatal if left untreated. The mortality rate of RB ranges from 70% in Kenya to as low as 1% in Canada.⁵ The treatment modality has been transformed aiming to save sight and eye in developed countries whereas developing countries like Nepal are struggling to save the life of a child due to late presentation and lack of conservative treatment modalities and trained human resources.⁶ Destructive eye surgeries like enucleation and exenteration for RB still remain major treatment modality in low-income countries.^{7,8} In the context of Nepal, chemotherapy is limited to certain centers, and focal therapy like transpupillary thermotherapy (TTT), laser, and cryotherapy are available only in major cities.⁹ Other advanced treatment modalities like genetic screening and counseling, intra-arterial chemotherapy, and brachytherapy are not available throughout the nation.

In this study, we attempted to estimate the prevalence of RB among Nepalese children in the year 2019, mode of clinical presentation and classification, lag time of presentation, available treatment modalities, and cost. To our knowledge, no similar studies have been performed evaluating ethnic and geographical variation and affordability of treatment of RB in our country, herein we conducted this multicentric, multiethnic cross-sectional study to help and guide in the formulation of national policy and treatment strategy.

Materials and Methods

This was a multicentric, multiethnic, cross-sectional study conducted from January to December 2019, after ethical approval from the National Health Research Council Ethical Review Board (Ref. no 1768). Twenty-seven RB centers were selected from seven provinces based on geographical location, patient flow, and acceptance by the institute. All the Nepalese children diagnosed with RB attending allocated RB centers willing to participate in this study were included and foreign nationalities and children not willing to participate were excluded from this study.

Detailed demographic information including age, gender, ethnicity, geographical location, clinical features, examination under anesthesia (EUA), and orbital imaging were collected in customized Google Form. An ethnicity code was provided to each case as per the Health Management Information System ethnic code.¹⁰ Each case was classified and staged at diagnosis based on clinical features on EUA and orbital imaging as per the International Classification of Retinoblastoma (ICRB) groups, as shown below.

1. Group A: Small tumor:
 - i. RB < 3 mm in size in basal dimension and thickness.
2. Group B: Larger tumor:
 - i. RB > 3 mm in basal dimension/thickness.
 - ii. Macular location (< 3 mm to the fovea).
 - iii. Juxtapapillary location (< 1.5 mm to disc).
 - iv. Clear subretinal fluid (< 3 mm from margin).
3. Group C: Focal seeds:
 - i. C1 subretinal seeds < 3 mm from RB.
 - ii. C2 vitreous seeds < 3 mm from RB.
 - iii. C3 both subretinal and vitreous seeds < 3 mm from RB.
4. Group D: Diffuse seeds:
 - i. D1 subretinal seeds > 3 mm from RB.
 - ii. D2 vitreous seeds > 3 mm from RB.
 - iii. D3 both subretinal and vitreous seeds > 3 mm from RB.
5. Group E: Extensive RB:
 - i. Occupying > 50% globe, or
 - ii. Neovascular glaucoma.

- iii. Opaque media from hemorrhage in the anterior chamber, vitreous, or subretinal space.
- iv. Invasion of post-laminar optic nerve, choroid (> 2 mm), sclera, orbit, or anterior chamber.

International Staging System for RB:

Stage 0: No enucleation (one or both eyes may have the intraocular disease).

Stage I: Enucleation, tumor completely resected.

Stage II: Enucleation with microscopic residual tumor.

Stage III: Regional extension:

- A. Overt orbital disease.
- B. Preauricular or cervical lymph node extension.

Stage IV: Metastatic disease:

- A. Hematogenous metastasis:
 1. Single lesion.
 2. Multiple lesions.
- B. Central nervous system (CNS) extension:
 1. Prechiasmatic lesion.
 2. CNS mass.
 3. Leptomeningeal disease.

The delayed presentation of RB was defined as the lag time (symptom to presentation at RB center) of more than a month. Similarly, affordability of treatment of RB children was estimated using a catastrophic approach, and total health care expenditures exceeding 40% of nonfood expense is considered catastrophic.

Statistical Analysis

Data were entered into Microsoft Excel 2010 and analyzed using Statistical Package for Social Sciences version 20 (SPSS, Inc. Chicago, Illinois, United States). For descriptive statistics, percentage, mean, and standard deviation were computed and presented in graphical and tabular presentation.

Results

A total of 34 RB cases comprising newly diagnosed 13 (38.2%) and ongoing treatment 21 (61.76%) were received at the end of the study period from different RB centers. The majority of participants were from Province 1 (35.3%) followed by Bagmati province (23.5%). Of the total, 22 (64.7%) cases were unilateral that included right eye 12 (35.3%) and left eye 10 (29.4%), whereas the remaining 12 (35.3%) were bilateral RB. Out of the total, 18 (52.9%) patients were male and 16 (47.1%) female. The mean age of patients at presentation was 33.5 ± 20.31 months (range, 1.5–73 months). The detailed demographic characteristics of study participants are shown in **Table 1**.

In our study, most of the cases 13 (38.2%) were from the so-called upper caste group followed by the disadvantaged non-Dalit Terai caste group 8 (23.5%). However, religious minority

Table 1 Demographic characteristics of study participants

Characters	Value ^a
Age Mean age \pm SD (range)	33.5 \pm 20.31 mo (range, 1.5–73 mo)
Gender	
Male	18 (52.9%)
Female	16 (47.1%)
Family history of retinoblastoma	
Positive	1 (2.9%)
Negative	33 (97.1%)
Consanguinity marriage of parents	
Yes	4 (11.8%)
No	30 (88.2%)
Ethnicity	
Dalits	2 (5.9%)
Disadvantaged Janjatis	5 (14.7%)
Disadvantaged non-Dalit Terai caste group	8 (23.5%)
Religious minority Muslims and Churaute	6 (17.6%)
Relatively advantaged Janjatis	0
Upper caste groups	13 (38.2%)
Laterality	
Right eye	12 (35.3%)
Left eye	10 (29.4%)
Both eye	12 (35.3%)
Treatment status	
On treatment	21 (61.76%)
New cases	13 (38.24%)
Geographical distribution	
Province 1	12 (35.3%)
Province 2	7 (20.6%)
Bagmati province	8 (23.5%)
Gandaki province	0
Lumbini province	1 (2.9%)
Karnali province	2 (5.9%)
Province 7	4 (11.8%)

Abbreviation: SD, standard deviation.

^aValues are expressed in numbers and %.

Muslims and Churaute comprised 17.6% of total cases. Very few cases 1 (2.9%) had a positive family history of RB whereas 4 (11.8%) cases revealed parental marriage consanguinity.

We found that out of total 46 eyes, leukocoria (73.9%, $n = 46$) was the most common mode of presentation in both unilateral and bilateral cases. The clinical feature presented either in unilateral or bilateral RB cases is shown in **Table 2**.

Concerning the classification of RB, each case was classified as per the ICRB groups after meticulous EUA. Three-

Table 2 Distribution of clinical features at time of presentation

Clinical features	Unilateral	Bilateral	Total
	Number (%)	Number (%)	Number (%)
Leukocoria	18 (72)	16 (76.2)	34 (73.9)
Proptosis	1 (4)	2 (9.5)	3 (6.5)
Red eye	3 (12)	0 (0)	3 (6.5)
Squint	0 (0)	1 (4.8)	1 (2.2)
Phthisis bulbi	1 (4)	2 (9.5)	3 (6.5)
Total hyphema	2 (8)	0 (0)	2 (4.4)
Total	25 (100)	21 (100)	46 (100)

Table 3 Distribution of eyes as per ICRB

Group	Laterality			Total
	OD	OS	OU	
	Number (%)	Number (%)	Number (%)	Number (%)
A	0 (0)	0 (0)	2 (7.7)	2 (4.4)
B	0 (0)	0 (0)	7 (26.9)	7 (15.2)
C	0 (0)	1 (12.5)	1 (3.8)	2 (4.4)
D	4 (33.3)	3 (37.5)	3 (11.5)	10 (21.7)
E	8 (66.7)	4 (50)	13 (50)	25 (54.4)
Total	12 (100)	8 (100)	26 (100)	46 (100)

Abbreviations: ICRB, International Classification of Retinoblastoma; OD, oculus dexter; OS, oculus sinister; OU, oculus utro.

fourth cases of RB cases presented in an advanced group consisting Group E (54%) and Group D (21.74%) which have poor prognosis. However, bilateral RB cases were presented in Group A (7.69%) and Group B (26.92%) with better prognosis. The distribution of cases as per ICRB groups in unilateral and bilateral RB is shown in [Table 3](#).

In this study, nearly 90% of cases were presented in stage 0 with a good survival prognosis as per the ICRB staging. Stage I was present in one case of unilateral and two cases of bilateral RB. However, only one case of unilateral RB was presented at stage IV as shown in [Table 4](#).

The mean lag time, that is, symptom to the first visit to RB center ranged from 15 to 912 days (mean 172.3 days). More than three-quarters of patients had delayed presentation >30 days to the RB center. The reason behind the delayed presentation was reported that parents thought symptom was normal in more than 50% cases followed by unawareness about RB center and poverty in few cases.

Among the ongoing treatment group, more than 90% cases had undergone some form of systemic chemotherapy and only 19% cases had undergone enucleation, whereas more than half of newly diagnosed cases were planned for enucleation as depicted in [Fig. 1](#).

Table 4 Distribution of eyes as per ICRB staging for retinoblastoma

Stage	Unilateral	Bilateral	Total
	Number (%)	Number (%)	Number (%)
0	20 (90.9)	10 (83.3)	30 (88.2)
I	1 (4.6)	2 (16.7)	3 (8.8)
II	0 (0)	0 (0)	0 (0)
III	0 (0)	0 (0)	0 (0)
IV	1 (4.6)	0 (0)	1 (2.9)
Total	22 (100)	12 (100)	34 (100)

Abbreviation: ICRB, International Classification of Retinoblastoma.

Almost all parents or guardians, 33 (97.1%), of the participants agreed with the treatment protocol as advised by the ophthalmologists. However, two-thirds (67.6%) of cases were referred for systemic chemotherapy or unavailability treatment services as shown in [Fig. 2](#).

In this study, the average cost of treatment for RB was found to be 521% of nonfood expense of the RB family which is catastrophic and unaffordable to all families.

Discussion

In this multicentric hospital-based study, 34 RB cases were received from 10 RB centers during the said study period. Of the total, 13 cases were newly diagnosed which is relatively smaller than 250 to 300 cases/year in the United States, 40 cases/year in the United Kingdom, and 100 cases/year in India and China.¹¹⁻¹³ We thought that the lower incidence of RB in our country is probably due to lower population size as compared with those countries. The hospital-based prevalence of RB was 2.66/10,000 in the population of the 0 to 6 years' age group. If we assume that all the RB cases come to the hospital, then the annual incidence of RB will be 3.01 per million population of age group 0 to 6 years which is comparable to the published literature.^{14,15}

In our study, the mean age of patients at presentation was 33.5 ± 20.31 months (range, 1.5–73 months) which is inconsistent with other studies.¹⁶⁻¹⁸ However, bilateral cases presented earlier than unilateral RB in our study. The late presentation of RB in our country is due to ignorance, illiteracy, and poverty that lead to an advanced stage with a poor prognosis. There are no standard screening protocols and awareness programs against RB in our country which causes misdiagnosis and progression of RB into the advanced stage.

Of the total, 18 (52.9%) male and 16 (47.1%) female patients were enrolled. There was no significant difference between males and females in RB as consistent with other studies.^{19,20} However, male predominance over female has been reported in some studies,^{21,22} whereas female predominance was reported in other studies.^{23,24} More than two-thirds of cases were unilateral 32 (64.7%) and only 12 (35.3%) cases were bilateral similar to previous studies done in Nepal and abroad.^{9,16,22,23,25,26}

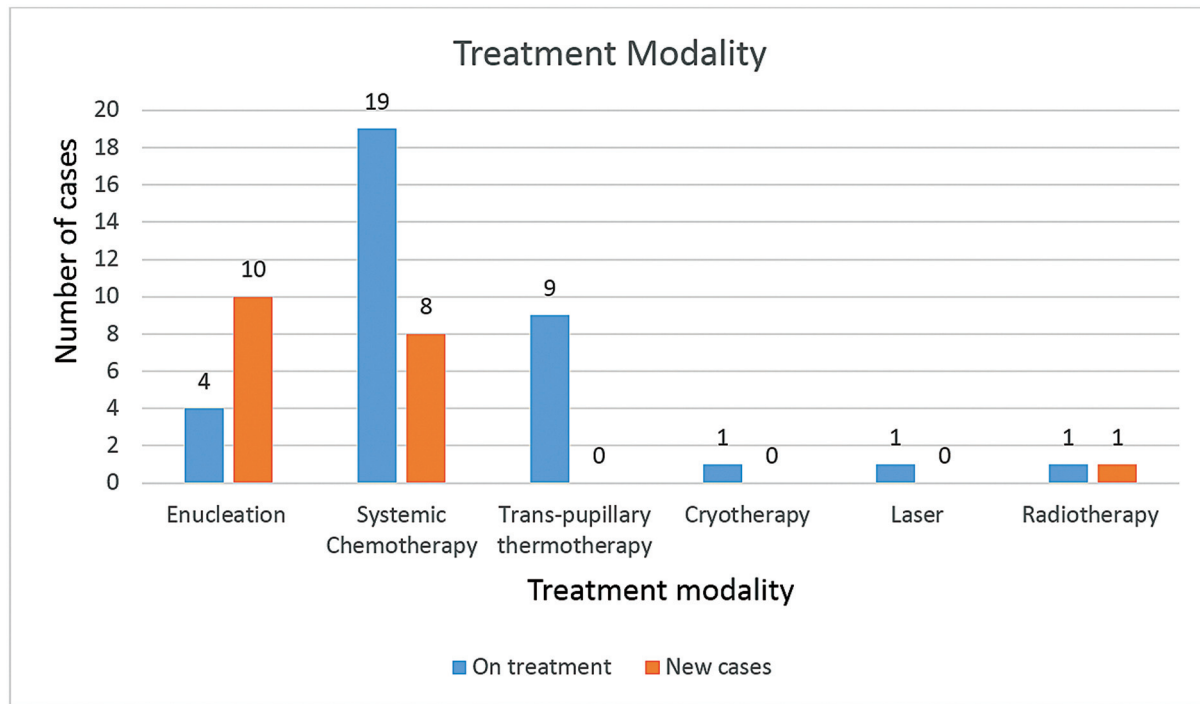


Fig. 1 Distribution of participants as per treatment modality.

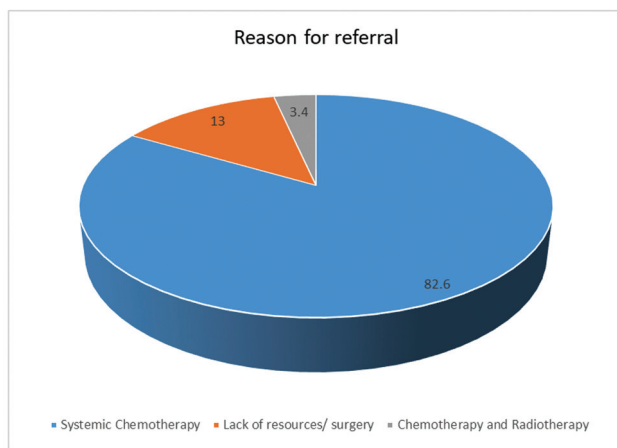


Fig. 2 Causes of referring retinoblastoma cases.

Concerning geographical distribution, the majority of patients reported from Province 1 (35.3%) followed by Bagmati province (23.5%). However, few cases were found in other provinces which could be because of ignorance and unawareness of RB and low socioeconomic status as well. The availability of RB treatment is mostly centered in the capital city and other developed cities in eastern Nepal. We think relatively larger numbers of eye care services are available in Province 1 and Bagmati province referring to suspected cases of RB in our study centers.

In our study, more than one-third of cases were from the upper caste 13 (38.2%) followed by disadvantaged non-Dalit Terai caste group 8(23.5%). The upper caste group comprising the largest castes Chhetri and Brahmin in census 2011, is the most advantaged group in political

and socioeconomic status in the country. Similarly, religious minority Muslims and Churaute shared 17.6% of total cases while other disadvantaged groups like Dalits and Janjatis occupied 5.9 and 14.7% of total cases. The reason behind the few cases reported among Dalits and Janjatis could be inaccessibility and unaffordability of treatment in addition to illiteracy and ignorance. However, RB has no racial or gender predisposition in incidence. The risk factors like positive family history and consanguinity of marriage are closely related to bilateral RB. Surprisingly, only 1 (2.9%) case had a positive family history and 4 (11.8%) cases had a history of consanguinity marriage of parents which is similar to published literature.²⁷ Although another study was done in Nepal suggested there is no role of consanguinity in RB among Nepalese children,⁸ some other studies have shown close relation of consanguinity with bilateral RB.^{6,28}

The patients presented with multiple symptoms at RB centers. The majority of patients (73.9%) presented with leukocoria followed by red eye, proptosis, and phthisis bulbi each accounting for 6.52%. The red eye and total hyphema were present only in unilateral cases whereas squint was present in bilateral RB only. Proptosis was a common clinical presentation in developing countries as shown in previous studies, nowadays leukocoria has become the common mode of presentation even in developing countries.^{16,22–26,29,30} Leukocoria is the first symptom and if noticed and presented early, gives a better chance of survival of both life and sight. More than 75% of patients in our study presented at Group D and E with bad prognoses which are similar to most parts of the globe. This is probably due to the fact that symptomatic cases usually present in Group C or advanced.^{16,21,26,31,32}

This signifies that more awareness programs against RB are needed at the local and national levels for early diagnosis and treatment. However, nearly 90% of patients were at stage 0 and 3 (8.2%) cases presented at stage I.

The presenting study reported that the mean lag time (symptoms to the first visit at RB center) was 173.23 days (range, 15–912 days) which is longer than median lag time of 49 days with range 7 to 560 days reported in the Goddard et al study.¹² Similarly, a shorter lag time has been reported in a retrospective study in Egypt (69 days).³² One previous study in Nepal reported a shorter mean lag time of 75 days with a range of 3 to 365 days, while Badhu et al reported delayed presentation up to 1,000 days.^{8,25} The reason behind delayed presentation (> 1 month) in our study was that more than 50% of parents thought symptoms were normal, 30% of parents did not know where to consult, and 20% of parents did not have the money. This shows that ignorance, illiteracy, and poverty are key factors for delayed presentation and poor prognosis of RB. However, it is necessary to create an awareness program against RB in the community and rapid screening camps for pupillary white reflex in the community.

The primary goal of RB treatment is to save a child's life, sight, and eye. Enucleation and exenteration used to be a common mode of treatment a decade ago due to lack of conservative measures and advanced stage of presentation. However, the trend has been changed to focus more on conservative management. Among ongoing treatment group, more than 90% cases obtained some form of systemic chemotherapy whereas only 19% cases underwent enucleation. Systemic chemotherapy is an important conservative treatment modality. However, previously published literature reported systemic chemotherapy in up to 51% of cases which is lower than our study. Systemic chemotherapy in our study is even better than similar studies in Indonesia, Mongolia, and India.^{21,26,30}

Of the total 34, 14 (41.2%) patients had undergone primary enucleation which is lower than that reported in previous studies in Nepal (51–90%).^{8,9,25} The primary enucleation for RB was found to be similar in India (35%), Indonesia (22%), and Mongolia (61%).^{26,30,33} However, more than 50% of newly diagnosed cases were planned for primary enucleation. None of our cases underwent exenteration while other previous studies have reported exenteration rates ranging from 5 to 38%.^{8,9,25}

Out of 34, 23 (67%) patients were referred to a higher center for further treatment. The most common reason for referral was for systemic chemotherapy (82.6%) which is available only in few medical colleges and government hospitals.⁶ TTT was first started in Tilganga Institute of Ophthalmology in 2019 along with cryotherapy and periocular topotecan and carboplatin. Nine patients among the ongoing treatment group had received TTT while cryotherapy, laser therapy, and radiotherapy were provided to one patient each. However, none of the patients had received TTT and cryotherapy for RB in previous studies in Nepal.^{8,9,25,34} This indicates that management of RB is shifting toward a conservative treatment modality due to

early presentation and availability of conservative measures. Other modalities of treatment like genetic screening and counseling, brachytherapy, and intra-arterial chemotherapy are not available in our country, so we have to refer some cases abroad.

RB management is a multidisciplinary approach. Only a few tertiary care centers are designed for RB treatment, but still lack adequate equipment and trained human resources. So we found that almost all RB centers have to refer patients for systemic chemotherapy, radiotherapy, and other newer treatment modality. However, the cost of treatment is unaffordable in almost all (100%) cases in our study that leads to increasing defaulters and ultimately death. Early diagnosis and a multidisciplinary approach to treatment are key to success. The RB programs like the RB development program in Central America may help to reduce defaulters and loss to follow-up patients.³⁵ Early diagnosis and treatment of RB is the most important step for saving the life, vision, and eye of the child which is only possible with an awareness program against RB and early screening at the community level.

Conclusion

This is a multicentric, multiethnic cross-sectional study incorporating large number of ophthalmologists all over the nation for evaluating RB among Nepalese children in terms of incidence, clinical presentation, classification, and treatment modality. We recommend a community-based awareness program against RB and an active well-formed referral network and a well-equipped RB center with trained manpower to reduce the burden of RB in the community and nation. However, the government's ownership over RB management and the establishment of chemotherapy centers all over the nation is needed.

Ethical Approval

Ethical approval from National Health Research Council (NHRC) Ethical Review Board (Ref. no 1768).

The authors declared that the study was conducted in accordance with the tenets of Declaration of Helsinki.

Authors' Contributions

B.L. played a pivotal role in conceptualizing the study, designing it, and contributing to the manuscript's written content, along with performing statistical analysis. P.A. also made significant contributions to manuscript writing, statistical analysis, and interpretation. D.H. actively participated in manuscript writing, manuscript review, statistical analysis, and interpretation of results. S.R.P. was involved in writing, reviewing the manuscript, and performing statistical analysis. S.S. contributed to both writing and manuscript review, as well as analyzing the results. Lastly, S.B.K.R. was instrumental in manuscript writing and design, critically analyzing the results, and providing valuable input during manuscript review. Our collective efforts have culminated in this comprehensive piece of work.

Funding

This study was supported financially and logistically by Nepalese Society of Oculoplastic Surgeons (NESOS) and KAKS foundation.

Conflict of Interest

None declared.

Acknowledgments

The authors would like to acknowledge the Nepalese Society of Oculoplastic Surgeons and KAKS foundation for financial support and logistics management for this particular study.

References

- Reddy SC, Anusya S. Clinical presentation of retinoblastoma in Malaysia: a review of 64 patients. *Int J Ophthalmol* 2010;3(01):64–68
- Naseripour M. "Retinoblastoma survival disparity": the expanding horizon in developing countries. *Saudi J Ophthalmol* 2012;26(02):157–161
- Fabian ID, Abdallah E, Abdullahi SU, et al; Global Retinoblastoma Study Group. Global retinoblastoma presentation and analysis by national income level. *JAMA Oncol* 2020;6(05):685–695
- Chantada GL, Qaddoumi I, Canturk S, et al. Strategies to manage retinoblastoma in developing countries. *Pediatr Blood Cancer* 2011;56(03):341–348
- Dimaras H, Kimani K, Dimba EAO, et al. Retinoblastoma. *Lancet* 2012;379(9824):1436–1446
- Sah KP, Saiju R, Roy P, Kafle S. Retinoblastoma: ten years experience at Kanti Children's Hospital. *JNMA J Nepal Med Assoc* 2013;52(192):576–579
- Ben L, Aemero M, Gushchin AG, Moore GH, Rohit S. Clinicopathological patterns of patients who underwent orbital exenteration in a tertiary eye hospital of Nepal. *Ethiop J Health Sci* 2016;26(06):543–548
- Saiju R, Moore G, Shrestha U, Shrestha MK, Ruit S. Retinoblastoma: geographic distribution and presentation at a tertiary eye care centre in Kathmandu, Nepal. *Nepal J Ophthalmol* 2013;5(02):169–176
- Gurung HBLB, Lama AJBH, Saiju R. Retinoblastoma: changing trend in a tertiary eye center. *Indian J Clin Exp Ophthalmol* 2019;5(April-June):252–256
- Health Management Information System Ethnic Code Accessed September 19, 2022, at: https://plos.figshare.com/articles/dataset/_Ethnic_codes_as_defined_by_the_Health_Management_Information_System_/767015/1
- Shields CL, Shields JA. Basic understanding of current classification and management of retinoblastoma. *Curr Opin Ophthalmol* 2006;17(03):228–234
- Goddard AG, Kingston JE, Hungerford JL. Delay in diagnosis of retinoblastoma: risk factors and treatment outcome. *Br J Ophthalmol* 1999;83(12):1320–1323
- Seth R, Singh A, Guru V, Chawla B, Pathy S, Sapra S. Long-term follow-up of retinoblastoma survivors: experience from India. *South Asian J Cancer* 2017;6(04):176–179
- Akhiwu WO, Igbe AP. Epidemiology of retinoblastoma. In: *Retinoblastoma: An Update on Clinical, Genetic Counseling, Epidemiology and Molecular Tumor Biology*. IntechOpen 2012
- Rangamani S, Sathishkumar K, Manoharan N, et al. Paediatric retinoblastoma in India: evidence from the National Cancer Registry Programme. *Asian Pac J Cancer Prev* 2015;16(10):4193–4198
- Zhao J, Li S, Shi J, Wang N. Clinical presentation and group classification of newly diagnosed intraocular retinoblastoma in China. *Br J Ophthalmol* 2011;95(10):1372–1375
- Naseripour M, Nazari H, Bakhtiari P, Modarres-zadeh M, Vosough P, Ausari M. Retinoblastoma in Iran: outcomes in terms of patients' survival and globe survival. *Br J Ophthalmol* 2009;93(01):28–32
- Chung SE, Sa HS, Koo HH, Yoo KH, Sung KW, Ham DI. Clinical manifestations and treatment of retinoblastoma in Korea. *Br J Ophthalmol* 2008;92(09):1180–1184
- MacCarthy A, Birch JM, Draper GJ, et al. Retinoblastoma in Great Britain 1963–2002. *Br J Ophthalmol* 2009;93(01):33–37
- Chen YH, Lin HY, Hsu WM, Lee SM, Cheng CY. Retinoblastoma in Taiwan: incidence and survival characteristics from 1979 to 2003. *Eye (Lond)* 2010;24(02):318–322(Lond Engl)
- Kaliki S, Patel A, Iram S, Ramappa G, Mohamed A, Palkonda VAR. Retinoblastoma in India: clinical presentation and outcome in 1,457 patients (2,074 eyes). *Retina* 2019;39(02):379–391
- Kazadi Lukusa A, Aloni MN, Kadima-Tshimanga B, et al. Retinoblastoma in the democratic republic of Congo: 20-year review from a tertiary hospital in Kinshasa. *J Cancer Epidemiol* 2012;2012:920468
- Pedram M, Alghasi A, Salari F, et al. Retinoblastoma in southwest Iran. *Iran J Blood Cancer* 2015;7(03):143–148
- Azar D, Donaldson C, Kalapesi F, Cumming R. Retinoblastoma in New South Wales 1975 to 2001. *J Pediatr Hematol Oncol* 2006;28(10):642–646
- Badhu B, Sah SP, Thakur SK, et al. Clinical presentation of retinoblastoma in Eastern Nepal. *Clin Exp Ophthalmol* 2005;33(04):386–389
- Chuluunbat T, Jamiyanjav B, Munkhuu B, et al. Retinoblastoma in Mongolia: clinical characteristics and survival from 1987 to 2014. *Taiwan J Ophthalmol* 2016;6(02):79–84
- Sahu S, Banavali SD, Pai SK, et al. Retinoblastoma: problems and perspectives from India. *Pediatr Hematol Oncol* 1998;15(06):501–508
- Harini R, Ata-ur-Rasheed M, Shanmugam MP, Amali J, Das D, Kumaramanickavel G. Genetic profile of 81 retinoblastoma patients from a referral hospital in southern India. *Indian J Ophthalmol* 2001;49(01):37–42
- Butros LJ, Abramson DH, Dunkel IJ. Delayed diagnosis of retinoblastoma: analysis of degree, cause, and potential consequences. *Pediatrics* 2002;109(03):E45
- Miranda GA, Simanjuntak GWS. Clinical findings and demography of retinoblastoma in a tertiary hospital in a remote area in a developing country. *Asia Pacific J Cancer Care* 2018;3(02):37
- Lim FP, Soh SY, Iyer JV, Tan AM, Swati H, Quah BL. Clinical profile, management, and outcome of retinoblastoma in Singapore. *J Pediatr Ophthalmol Strabismus* 2013;50(02):106–112
- El Zomor H, Nour R, Alieldin A, et al. Clinical presentation of intraocular retinoblastoma; 5-year hospital-based registry in Egypt. *J Egypt Natl Canc Inst* 2015;27(04):195–203
- Kaliki S, Srinivasan V, Gupta A, Mishra DK, Naik MN. Clinical features predictive of high-risk retinoblastoma in 403 Asian Indian patients: a case-control study. *Ophthalmology* 2015;122(06):1165–1172
- Saiju R, Thakur J, Karmacharya PC, Shah DN. Retinoblastoma in Nepal: a clinical profile of 30 cases. *Nepal Med Coll J* 2006;8(03):171–175
- Wilimas JA, Wilson MW, Haik BG, et al. Development of retinoblastoma programs in Central America. *Pediatr Blood Cancer* 2009;53(01):42–46