Article published online: 2022-11-24

A Rare Case of Encephalopathy in Children—Known but Unknown

Mukesh Kumar Jain[1] Chinmaya Kumar Behera[1] Sangram Panda[2] Sibabratta Patnaik[1] Bandya Sahoo[1] Reshmi Mishra[1] Jyoti Ranjan Behera[1]

[1] Department of Pediatrics, Kalinga Institute of Medical Sciences, Kalinga Institute of Industrial Technology, Bhubaneswar, Odisha, India
[2] Department of Radiodiagnosis, Kalinga Institute of Medical Sciences, Kalinga Institute of Industrial Technology, Bhubaneswar, Odisha, India

Address for correspondence Mukesh Kumar Jain, MD, IDPCCM, AT-Flat No. 845, Tower -12, Royal Lagoon, Raghunathpur, Bhubaneswar, Odisha 751024, India (e-mail: mukesh26.jain@gmail.com).

J Pediatr Neurol 2023;21:391–394.

Abstract

Metronidazole-induced encephalopathy is a rare cause of toxic encephalopathy in children. Although many cases have been reported in adults, it is rarely reported in the pediatric population. Here, we report a case of an 11-year-old boy who presented with acute-onset encephalopathy with slurring of speech after receiving metronidazole for treatment of acute gastroenteritis. Neuroimaging is the cornerstone in the diagnosis of this entity with typical involvement of cerebellum, brain stem, and splenium of the corpus callosum. In our case, magnetic resonance imaging of the brain revealed hyperintensity of the splenium of the corpus callosum on the fluid-attenuated inversion recovery sequence along with diffusion restriction in the diffusion-weighted imaging and apparent diffusion coefficient images. Rapid complete neurological and radiological recovery with supportive treatment is key in making the diagnosis. Although a safer and commonly used drug, new-onset encephalopathy after the use of metronidazole must be considered.

Keywords
- metronidazole
- encephalopathy
- children
- corpus callosum

Introduction

Many protozoal and anaerobic infections are commonly treated by metronidazole, a 5-nitroimidazole antibiotic. Although it is a safe drug, a patient may experience serious neurologic side effects during acute and chronic use. The common neurologic effects are peripheral neuropathy, cerebellar dysfunction, visual impairment, seizures, and encephalopathy.[1,2] Our case is unique in that it occurred in a pediatric patient after a short course of metronidazole.

Case Report

An 11-year-old boy was admitted to the pediatric intensive care unit with acute-onset encephalopathy/altered sensorium following an episode of acute gastroenteritis. On admission, he was afebrile, heart rate was 134/min, respiratory rate 20/min, blood pressure 110/70 mm Hg, and SpO_2 98% in room air. On central nervous system (CNS) examination, he was disoriented, confused with slurring of speech. Glasgow coma scale was 13/15 (E-3 V-4 M-6), and the examination of motor, sensory, cranial nerves, skull, and spines were normal, and there were no meningeal signs. There was a history of ingestion of outside food 2 days prior to this episode, following which he developed diarrhea and vomiting and was admitted to a local hospital and treated with intravenous fluids and antibiotics (ceftriaxone 1.5 g twice daily and metronidazole 500 mg thrice daily for 2 days). After 2 days of treatment, he developed altered sensorium (confusion and slurring of speech) for which the patient was referred to our hospital. He was admitted with a provisional diagnosis of acute encephalitis syndrome and further evaluation was done. His preliminary reports revealed a total leukocyte count

received
June 1, 2022
accepted after revision
August 31, 2022
article published online
November 24, 2022

© 2022. Thieme. All rights reserved.
Georg Thieme Verlag KG,
Rüdigerstraße 14,
70469 Stuttgart, Germany

DOI https://doi.org/10.1055/s-0042-1757623.
ISSN 1304-2580.

This document was downloaded for personal use only. Unauthorized distribution is strictly prohibited.

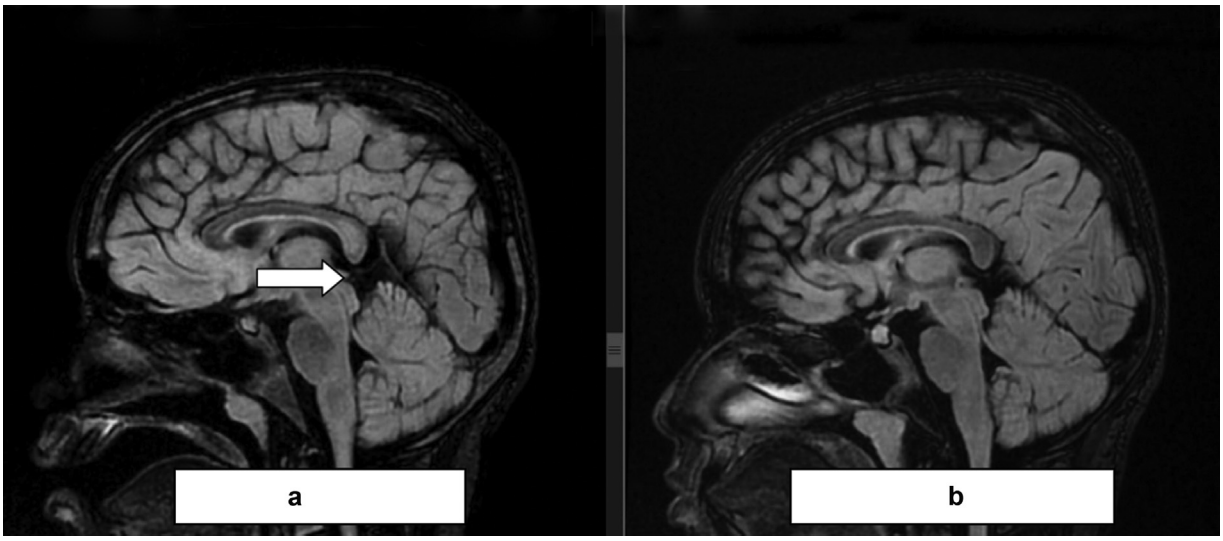

Fig. 1 (**a**, **b**) Fluid-attenuated inversion recovery image in initial magnetic resonance imaging shows hyperintensity in the splenium of corpus callosum, which appears to be resolved in the follow-up scan.

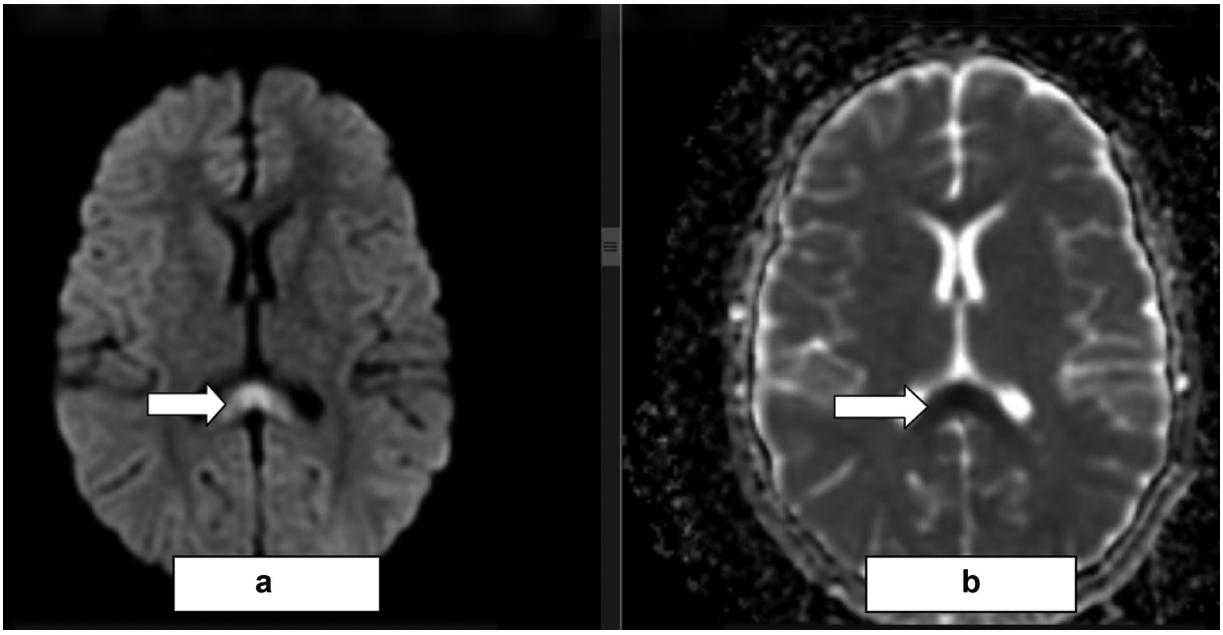

Fig. 2 (**a**, **b**) Initial MRI. DWI and ADC images show diffusion restriction in splenium of corpus callosum, suggestive of cytotoxic edema. ADC, apparent diffusion coefficient; DWI, diffusion-weighted imaging; MRI, magnetic resonance imaging.

9,600 (N-86%, L-10, M-4), hemoglobin 14.1 g/dL, platelet count 15,700, and C-reactive protein 450 mg/L. Renal function showed serum urea 81 mg/dL, creatinine 1.81 with normal electrolytes, and liver function test revealed transaminitis (serum glutamic-pyruvic transaminase and serum glutamic-oxaloacetic transaminase 143/82). He was treated conservatively with intravenous fluids, 3% saline, ceftriaxone, and acyclovir. Cerebrospinal fluid (CSF) study was normal (five cells, all lymphocyte, protein 45 mg/dL, glucose 80 mg/dL, culture sterile). CSF polymerase chain reaction for viral panel was negative. Other causes of infection such as malaria, typhoid, and scrub typhus were excluded, and blood and stool cultures were sterile. Electroencephalogram was done to rule out nonconvulsive status epilepticus, which showed diffuse slowing without epileptic discharges. Magnetic resonance imaging (MRI) of the brain revealed hyperintensity of splenium of corpus callosum in fluid-attenuated inversion recovery (FLAIR) sequence (►**Fig. 1a**) along with diffusion restriction in diffusion-weighted imaging (DWI) and apparent diffusion coefficient (ADC) image, suggestive of cytotoxic edema (►**Fig. 2a, b**). Considering the specific MRI finding and exclusion of other possible etiologies with rapid clinical improvement led to the diagnosis of metronidazole-induced encephalopathy (MIE). The patient was discharged after 7 days with complete neurological recovery. Repeat MRI after 4 weeks revealed complete resolution of

 © 2022. Thieme. All rights reserved.

This document was downloaded for personal use only. Unauthorized distribution is strictly prohibited.

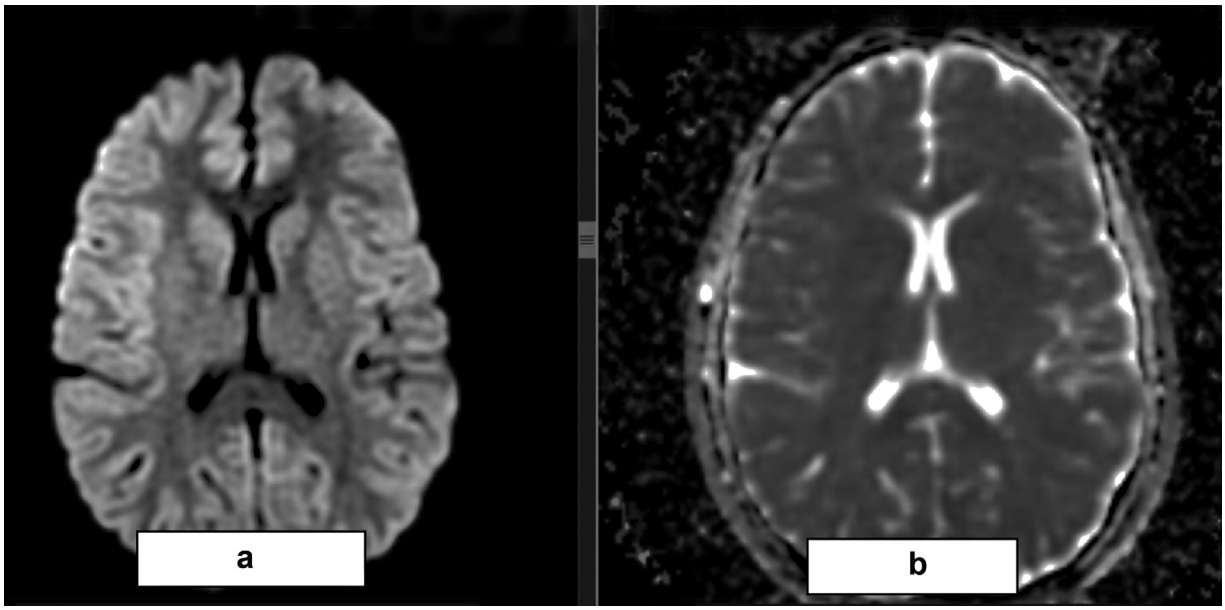

Fig. 3 (**a, b**) Follow-up MRI. DWI and ADC images show complete resolution of the cytotoxic edema in splenium of corpus callosum. ADC, apparent diffusion coefficient; DWI, diffusion-weighted imaging; MRI, magnetic resonance imaging.

Table 1 Summary of metronidazole-induced encephalopathy

Risk factors	Prolonged administration, high doses, high cumulative doses of metronidazole, use of metronidazole in CNS cases
Sign and symptoms	Cerebellar dysfunction (dysarthria, dysmetria, ataxia, nystagmus), altered mental status, and seizures
Imaging	Area involved are cerebellar dentate nuclei (most common), brain stem, splenium of corpus callosum, basal ganglia, thalamus, white matter MRI of the brain revealed hyperintensity of area involved in T2-weighted FLAIR sequence along with diffusion restriction in DWI and ADC image, suggestive of cytotoxic edema
Treatment	Withdrawal of offending drugs, supportive treatment, steroid in some resistant cases

Abbreviations: ADC, apparent diffusion coefficient; CNS, central nervous system; DWI, diffusion-weighted imaging; FLAIR, fluid-attenuated inversion recovery; MRI, magnetic resonance imaging.

Table 2 Differential diagnosis of MIE includes

Metabolic	Maple syrup urine disease, Leigh's syndrome, Canavan's disease, glutaric aciduria type 1, hypoglycemia, hyponatremia
Infectious	Enteroviral encephalomyelitis, acute disseminated encephalomyelitis
Autoimmune	Systemic lupus erythematosus
Neurological	Wernicke's encephalopathy, stroke, hypertensive encephalopathy
Drug induced	Methotrexate and 5-fluorouracil
Others	Pre-eclampsia, renal failure, high altitudinal edema, methyl bromide intoxication

Abbreviation: MIE, metronidazole-induced encephalopathy.

signal abnormalities, which again confirmed our diagnosis (►**Figs. 1b** and **3a, b**).

Discussion

Metronidazole is a rare cause of toxic encephalopathy and the exact incidence of MIE is not known.[3] There is no sex predisposition and majority of reports are found in adult, though there have been a few pediatric cases as well.[4,5] Median duration of development of complications from treatment initiation is 2 weeks (range: 1–90 days) and average cumulative dose is 93.4g (range: 0.25–1,095 g).[6] In our case, symptoms developed after 48 hours and cumulative dose is 3 g. Recent evidence indicates that the neurotoxicity does not depend on the amount, duration, or route of administration (oral or intravenous or topical).[1,7]

 © 2022. Thieme. All rights reserved.

This document was downloaded for personal use only. Unauthorized distribution is strictly prohibited.

Cerebellar dysfunction (75%) is the most common manifestation followed by altered mental status (33%) and seizures (13%). Among cerebellar dysfunction, dysarthria, ataxia, dysmetria, and nystagmus were the most common.[6] Altered mentation is mainly due to encephalopathy, but it can be due to nonconvulsive status as well.[8]

The mechanism of metronidazole-induced CNS toxicity is multifactorial and includes inhibition of protein synthesis by binding with neural RNA, alteration of inhibitory neurotransmitters gamma-aminobutyric acid receptor within the cerebellum, reversible mitochondrial dysfunction, and vasogenic and cytotoxic edema.[9,10]

he most common area of involvement is symmetrical T2-weighted (T2W) or FLAIR hyperintensities in the areas of cerebellar dentate nucleus (most characteristic), followed by brain stem and splenium of the corpus callosum.[11] Restriction in DWI with high or normal ADC points toward axonal swelling or vasogenic edema, whereas low ADC (cytotoxic oedema) or "true" restriction points toward ischemic process.[12] Summary of the case including risk factors, presentation, imaging findings, and management is presented in ►**Table 1**.

Differential diagnosis of T2W hyperintensity of the splenium of corpus splenium and other areas involved in MIE are summarized in ►**Table 2**.[13]

Diagnosis is often difficult due to lack of any specific criteria and needs a high index of suspicion. Neuroimaging is the cornerstone in the diagnosis of metronidazole toxicity, and it mainly involves cerebellum, brain stem, and corpus callosum.[12] The presence of characteristic imaging findings with partial or complete resolution after withdrawal of the offending agent is helpful in making the diagnosis of this rare entity.[13]

Withdrawal of the offending agent, supportive therapy, and treatment of underlying disease is the only proven measure. In majority of cases, there is clinical improvement after discontinuation of the drug.[6] However, reversibility is not a rule. Groothoff et al reported irreversible encephalopathy with metronidazole resulting into mortality.[14] The timing of clinical and radiological improvement occurs after withdrawal of the drug and goes hand in hand. The most remarkable feature of this disease is total or near-total resolution of the original lesions on follow-up.[11]

Conclusion

Although a safer and commonly used drug, new-onset encephalopathy after the use of metronidazole is an alarm for clinician to consider MIE. Increasing awareness among physicians may enable early recognition of this potentially reversible neurotoxicity and avoid unwarranted prescription of such medications. The use of metronidazole in CNS cases needs extra caution. Whenever in doubt, better to withdraw the medication and look for reversibility of findings. Our case is unique in that it occurred in the pediatric population after a short course of metronidazole, in a developing country like India.

Ethical Approval

Waved off as a case report, as an institutional policy.

Conflict of Interest

None declared.

References

1 Agarwal A, Kanekar S, Sabat S, Thamburaj K. Metronidazole-induced cerebellar toxicity. Neurol Int 2016;8(01):6365
2 De Bleecker JL, Leroy BP, Meire VI. Reversible visual deficit and corpus callosum lesions due to metronidazole toxicity. Eur Neurol 2005;53(02):93–95
3 Knorr JP, Javed I, Sahni N, Cankurtaran CZ, Ortiz JA. Metronidazole-induced encephalopathy in a patient with end-stage liver disease. Case Reports Hepatol 2012;2012:209258
4 Gaye A, Sanghavi A. Metronidazole-induced encephalopathy in a pediatric patient. J Allergy Clin Immunol 2007;119:S38
5 Sun Y, Overby PJ, Mehta H. Case 271: metronidazole-induced encephalopathy. Radiology 2019;293(02):473–479
6 Kuriyama A, Jackson JL, Doi A, Kamiya T. Metronidazole-induced central nervous system toxicity: a systematic review. Clin Neuropharmacol 2011;34(06):241–247
7 Mathew RP, Kunhimohammed SP, Joseph M. A case of topical metronidazole-induced encephalopathy. JAMA Neurol 2020;77(10):1318–1319
8 Cantador AA, Meschia JF, Freeman WD, Tatum WO. Nonconvulsive status with metronidazole. Neurohospitalist 2013;3(04):185–189
9 Wright KH, Tyler JW. Recognizing metronidazole toxicosis in dogs. Vet Med 2003;98:410–418
10 Evans J, Levesque D, Knowles K, Longshore R, Plummer S. Diazepam as a treatment for metronidazole toxicosis in dogs: a retrospective study of 21 cases. J Vet Intern Med 2003;17(03):304–310
11 Kim E, Na DG, Kim EY, Kim JH, Son KR, Chang KH. MR imaging of metronidazole-induced encephalopathy: lesion distribution and diffusion-weighted imaging findings. AJNR Am J Neuroradiol 2007;28(09):1652–1658
12 Ahmed A, Loes DJ, Bressler EL. Reversible magnetic resonance imaging findings in metronidazole-induced encephalopathy. Neurology 1995;45(3 Pt 1):588–589
13 Malhotra HS, Garg RK, Vidhate MR, Sharma PK. Boomerang sign: clinical significance of transient lesion in splenium of corpus callosum. Ann Indian Acad Neurol 2012;15(02):151–157
14 Groothoff MV, Hofmeijer J, Sikma MA, Meulenbelt J. Irreversible encephalopathy after treatment with high-dose intravenous metronidazole. Clin Ther 2010;32(01):60–64

This document was downloaded for personal use only. Unauthorized distribution is strictly prohibited.