Article published online: 2022-11-09

Concomitant Transatrial and Transapical CRT-D Lead Implantation in a Patient with Chest Burn Injury

Adam Riba[1] Aref Rashed[2] Roland Toth[2] Tamas Tahin[1]

[1] Department of Cardiology, Zala County Saint Rafael Hospital Ringgold Standard Institution, Zalaegerszeg, Hungary
[2] Department of Cardiac Surgery, Zala County Saint Rafael Hospital Ringgold Standard Institution, Zalaegerszeg, Hungary

Address for correspondence Adam Riba, MD, PhD, Department of Cardiology, Zala County St. Rafael Hospital, Zrinyi str. 1., H-8900 Zalaegerszeg, Hungary (e-mail: adam8804@gmail.com).

Thorac Cardiovasc Surg Rep 2022;11:e61–e63.

Abstract

Cardiac resynchronization therapy device with defibrillator (CRT-D) implantation is indicated for patients with a history of malignant ventricular arrhythmias, symptomatic heart failure, wide QRS, or high-degree atrioventricular block. A 67-year-old patient with dilated cardiomyopathy received a CRT-D with the conventional method but 1 month later skin necrosis was diagnosed above the device. The complete system was extracted from the patient and we utilized negative pressure wound therapy for the treatment of the remaining tissue. We decided to perform surgical reimplantation of the device using minithoracotomy: right atrial and right ventricular leads were introduced through the right atrial appendage and the left ventricular lead was inserted transapically. The device was implanted under the less scabby abdominal skin. We successfully applied the combination of transatrial and transapical lead placement, which has not been reported in the literature yet. It serves as an alternative method if the standard approach is not feasible.

Keywords
- heart failure
- minimally invasive surgery (includes port access, minithoracotomy)
- wound healing

Introduction

According to the current clinical guidelines, cardiac resynchronization therapy device with defibrillator (CRT-D) implantation is indicated for patients with a history of malignant ventricular arrhythmias, symptomatic heart failure, wide QRS, or high-degree atrioventricular block.[1] However, there are certain conditions where the standard implantation approach is not applicable due to congenital or acquired conditions.

Case Description

A patient with dilated cardiomyopathy underwent conventional CRT-D implantation using left subclavian vein access following a successful resuscitation due to ventricular tachycardia. One month later skin necrosis was detected above the device. Our hypothesis was that burn injury—which he suffered 40 years prior—has damaged the microcirculation of the skin and was accountable for the necrosis. The complete system was explanted, and we utilized negative pressure wound therapy for the treatment of the remaining tissue (►**Fig. 1**).

We decided to perform surgical reimplantation of the device using minithoracotomy: right atrial and right ventricular leads were introduced through the right atrial appendage and the left ventricular lead was inserted transapically.

Surgical Technique

For minithoracotomy, a vertical right lateral 5.5 cm long skin incision was made over the fourth right intercostal space just

received
July 10, 2022
accepted
August 29, 2022

DOI https://doi.org/10.1055/s-0042-1757788.
ISSN 2194-7635.

© 2022. The Author(s).
This is an open access article published by Thieme under the terms of the Creative Commons Attribution-NonDerivative-NonCommercial-License, permitting copying and reproduction so long as the original work is given appropriate credit. Contents may not be used for commercial purposes, or adapted, remixed, transformed or built upon. (https://creativecommons.org/licenses/by-nc-nd/4.0/)
Georg Thieme Verlag KG, Rüdigerstraße 14, 70469 Stuttgart, Germany

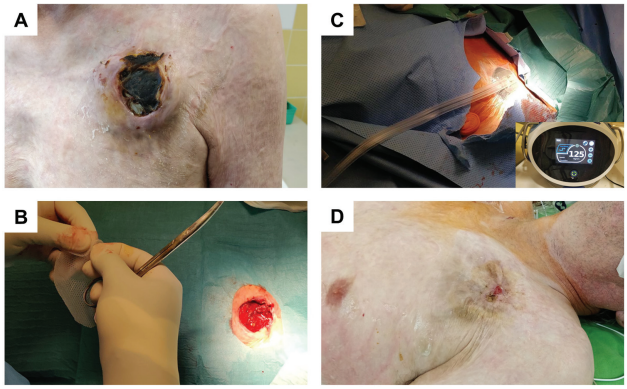

Fig. 1 (**A**) Three weeks after the implantation. (**B**) The complete system was removed, and a large tissue gap remained. (**C**) Negative pressure of 125 mm Hg was applied, to cover the tissue defect and facilitate tissue regrowth. (**D**) Three weeks after the device explantation. With continuous negative pressure wound therapy, the absence of skin tissue was almost completely closed.

anterior to the midaxillary line. Single-lung ventilation was initiated, and the right lung was retracted posteriorly. The pericardium was carefully opened.

A guidewire was inserted with Seldinger's technique through the puncture of right appendage into the right atrium. The wire was then exchanged to a sheath and a right ventricular shock electrode was introduced. Eventually, it was positioned and secured to the right ventricular apex under fluoroscopy guidance with good electrode parameters.

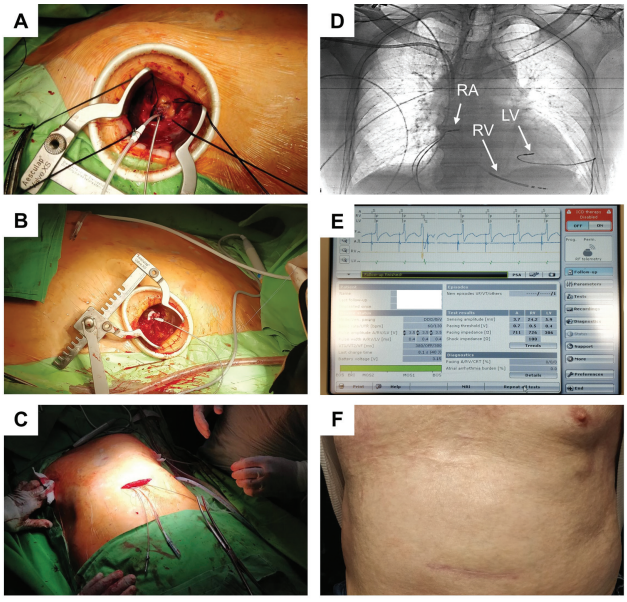

Fig. 2 Surgical cardiac resynchronization therapy device with defibrillator (CRT-D) implantation. (**A**) Right lateral minithoracotomy. The right ventricular and right atrial leads are positioned and fixed with purse-string sutures. (**B**) Left lateral minithoracotomy. The left ventricular lead was introduced through the apex of the left ventricle. (**C**) The leads were pulled through tunnels into the abdominal part and attached to the CRT-D device. (**D**) Positioning of the leads was performed with fluoroscopy guidance. (**E**) Good parameters were recorded at the end of the procedure. (**F**) Six months after the surgery.

The right atrial lead was also introduced with the same method and positioned with a J-shaped stylet into the anterior part of the right auricle. Bleeding was controlled and the electrodes were secured with purse-string sutures around the puncture points (►**Fig. 2A**).

Next, the ideal site for the incision to reach the apex of the left ventricle (LV) was identified and marked by transthoracic echocardiography guidance at the corresponding intercostal space. A second minithoracotomy was performed on the left side of thorax. A guidewire was inserted with Seldinger's technique through the puncture of the apex into the LV. After removal of the guidewire, the pacing electrode was inserted into the LV cavity through the sheath and peel-off sheath was removed. Bleeding from the LV was controlled with purse-string sutures around the puncture point (►**Fig. 2B**). Fluoroscopy was utilized for the endocardial fixation of the electrode at the lateral wall of the LV (►**Fig. 2D**).

The device was implanted in the abdominal area, where the skin was almost intact, below the diaphragm and the electrodes were tunneled (►**Fig. 2C**) (►**Video 1**). Anticoagulation was initiated because of the foreign body in the LV. Six months later there was no sign of complications, and the surgical wounds healed completely.

Discussion

CRT is a well-established therapy for patients with heart failure and ventricular dyssynchrony. The side branches of the coronary sinus are the first choice of sites for left ventricular lead implantation. However, biventricular pacing does have some challenges, including high pacing threshold, unavoidable phrenic nerve stimulation, the rate of nonresponders and rarely, chest deformities, and the rate of unsuccessful implantation. Several minimally invasive alterative implantation techniques have been developed.[2,3] Techniques, involving transvenous approach, cannot be obtained in our case because the reimplantation of the device in the conventional subclavicular region was not possible. Several authors recommend pocket change and subpectoral placement, but the skin could not be sutured properly as a result of the previous burn injury. Transfemoral lead insertion with CRT-P implantation was also reported, but this technique cannot be adopted for a patient requiring an implantable cardioverter defibrillator.[4] Therefore, we chose a surgical, but minimally invasive approach for implanting the leads. With our approach, some similarly challenging cases of complex device implantations can be successful.

Lifelong anticoagulation was initiated after the procedure with a target international normalized ratio level equivalent to mitral prosthetic valves (2.5–3.5). This approach is not an option for patients with contraindication to anticoagulation. For them the only possible solution is the epicardial implantation (if the conventional transvenous also failed).

We successfully applied the combination of transatrial and transapical lead placement in a CRT-D device, which has not been reported in the literature yet. It serves as an alternative method in selected cases, where the standard approach is not feasible.

Video 1

Steps of the procedure presented in the video: right axillary minithoracotomy, fixing RA and RV leads, left axillary minithoracotomy and introduction of LV lead, making the infraclavicular pocket, tunneling the electrodes, closing the wound. LV, left ventricle; RA, right atrium; RV, right ventricle. Online content including video sequences viewable at: https://www.thieme-connect.com/products/ejournals/html/10.1055/s-0042-1757788.

Conflict of Interest
None.

References

1 Glikson M, Nielsen JC, Kronborg MB, et al; ESC Scientific Document Group. 2021 ESC Guidelines on cardiac pacing and cardiac resynchronization therapy. Eur Heart J 2021;42(35):3427–3520
2 Kassai I, Pozzoli A, Friedrich O, et al. Transapical approach to optimize left ventricular resynchronization in patients with dilated cardiomyopathy (in Eng). Multimed Man Cardiothorac Surg 2017;2017. Doi: 10.1510/mmcts.2017.005
3 Gellér L, Salló Z, Molnár L, et al. Long-term single-centre large volume experience with transseptal endocardial left ventricular lead implantation. Europace 2019;21(08):1237–1245
4 Chaggar PS, Skene C, Williams SG. The transfemoral approach for cardiac resynchronization therapy. Europace 2015;17(02):173. Doi: 10.1093/europace/euu340