



Glycyrrhizin and Mannitol Nasal Therapy: Cytological and Clinical Outcomes in Chronic Rhinitis

Giulio Pagliuca¹ Veronica Clemenzi² Salvatore Martellucci¹ Francesco Gazia³
Sara Santarsiero⁴ Luigi Farina² Andrea Stolfa² Andrea Gallo²

¹Otolaryngology University Unit, "S.M. Goretti Hospital", Latina, Italy

²Department of Sensorial Organs, ENT Section, "Sapienza" University of Rome, Rome, Italy

³Department of Adult and Development Age Human Pathology "Gaetano Barresi", Otorhinolaryngology Unit, Messina, Italy

⁴Otorhinolaryngology Unit, Pediatric Hospital "Bambino Gesù", Roma, Italy

Address for correspondence Francesco Gazia, MD, Department of Adult and Development Age Human Pathology "Gaetano Barresi", Unit of Otorhinolaryngology, Via Consolare Valeria 1, 98125, Messina, ME, Italy (e-mail: ssgazia@gmail.com).

Int Arch Otorhinolaryngol 2023;27(4):e586–e592.

Abstract

Introduction Chronic rhinitis (CR) represents a widespread inflammation with a high incidence in the general population. Although it is generally considered a benign condition, CR has a relevant impact on quality of life and requires a specific treatment approach.

Objective The aim of the present study was to investigate the efficacy of glycyrrhizin and mannitol intranasal treatment on chronic rhinitis using cytological analysis and subjective evaluation of symptoms.

Methods A total of 55 patients suffering from chronic rhinitis were enrolled in the present study, 34 with allergic rhinitis (AR) and 21 with nonallergic rhinitis (NAR). The severity of four different nasal symptoms was determined by using a visual analogue scale (VAS). Specimens obtained by nasal scraping were collected for cytological analysis. Data were acquired before and after a 30-day treatment with glycyrrhizin and mannitol nasal spray. Statistical analyses were performed.

Results The VAS scores for all four nasal symptoms considered in the present study, as well as for neutrophil cells, reduced significantly after therapy in both allergic and nonallergic patients. The number of eosinophils was not significantly lower in nonallergic patients.

Conclusion A 30-day topical treatment with glycyrrhizin and mannitol may improve nasal symptoms and reduce inflammatory cells in the nasal mucosa in patients with chronic rhinitis without significant contraindications. Further studies could support our results and would better clarify all the aspects of this treatment.

Keywords

- ▶ allergic rhinitis
- ▶ cytology
- ▶ glycyrrhizin
- ▶ glycyrrhetic acid
- ▶ mannitol
- ▶ therapy

received

May 18, 2022

accepted

July 19, 2022

article published online

March 3, 2023

DOI <https://doi.org/10.1055/s-0042-1758219>

ISSN 1809-9777.

© 2023. Fundação Otorrinolaringologia. All rights reserved.

This is an open access article published by Thieme under the terms of the Creative Commons Attribution-NonDerivative-NonCommercial-License, permitting copying and reproduction so long as the original work is given appropriate credit. Contents may not be used for commercial purposes, or adapted, remixed, transformed or built upon. (<https://creativecommons.org/licenses/by-nc-nd/4.0/>)

Thieme Revinter Publicações Ltda., Rua do Matoso 170, Rio de Janeiro, RJ, CEP 20270-135, Brazil

Introduction

Chronic rhinitis (CR) is a common condition in the general population and has a negative impact on quality of life due to sleep deprivation, difficulty concentrating at work, low productivity, and social impairment.^{1,2} According to etiopathogenetic criteria, two subtypes of CR are distinguished: allergic rhinitis (AR) and nonallergic rhinitis (NAR). In AR, one or more specific allergens induce the inflammatory reaction of the nasal mucosa, whereas triggers of NAR symptoms, once called “vasomotor rhinitis”, vary and are nonspecific.³ Both in AR and in NAR, inflammatory cell infiltration characterizes the nasal mucosa; therefore, anti-inflammatory treatment is indicated for both conditions.

Currently, therapeutic strategies include decongestants, antihistamines, corticosteroids or a combination of these. Despite their effectiveness on nasal congestion, decongestant use for CR should be limited due to its systemic and local adverse effects and self-inducing inflammation of the nasal mucosa (self-medicating persistent rhinitis). Antihistamines are effective on histaminergic phlogosis, but they do not completely suppress the histamine-independent pathways of nasal inflammation.⁴ Long-term therapy with corticosteroid nasal spray represents a first-line treatment in the medical management of CR, having been demonstrated to reduce nasal inflammation and improve symptoms.⁵ Nonetheless, the general trend observed in medical practice, where the use of natural remedies is increasing, has led to a widespread use of substances based on available natural substrates. Sprays composed of glycyrrhizin (a triterpene glycoside extracted from the roots of the licorice plant known as *glycyrrhiza glabra*) and mannitol (a well-known osmotic agent) act osmotically, producing antiedematous and anti-inflammatory effects, have proven to be effective on nasal symptoms.⁶

In the last few years, nasal cytology has been increasingly used in the study of the cellular features of the nasal mucosa, to investigate AR and NAR, and to identify other causes of this nasal condition.⁷ In the present study, we examined subjective outcomes and nasal cytology changes after glycyrrhizin and mannitol intranasal treatment in patients suffering from AR and NAR in order to better clarify the effectiveness and safety of this topical treatment.

Methods

Study Population

Our cases were selected among patients who presented at the ENT unit of a tertiary referral hospital between March and October 2019. All eligible patients provided verbal and written informed consent.

We selected 55 consecutive patients aged between 19 and 72 years old, 32 males and 23 females suffering from CR. The diagnostic criteria included the presence of ≥ 1 nasal symptoms (obstruction, rhinorrhea, sneezing, and itching) for at least 12 weeks, in line with current rhinitis guidelines.⁸ Any additional conditions that could cause nasal inflammation were excluded, such as a recent acute infection of the upper

airways, specific drug use (α -adrenergic, α -blockers, cocaine, clonidine, ACE-inhibitors, oral contraceptives, antiepileptics, neuroleptics, aspirin and other NSAIDs, and calcium antagonists), occupational exposure to nasal irritants, cigarette smoke, hormonal factors (pregnancy, premenstrual phase, hypothyroidism), and some known pathologies (vasculitis, cystic fibrosis, and ciliary dyskinesia). Other exclusion criteria included previous nasal and/or sinus surgery and systemic and/or topical treatment with corticosteroids, antihistamines, or decongestants during the 30 days previous to our evaluation. Nasal endoscopy was performed to observe the anatomical features of the patients. Subjects with nasal polyposis, obstructive septal deviations, and adenoid hypertrophy were also excluded.

Skin Prick Test

The study design required each patient to undergo a skin prick test (SPT) (even if they had previously had one), a subjective evaluation of nasal symptoms and a sample collection for nasal cytology. The SPT was performed using inhalant allergens with positive and negative controls (Allergopharma GmbH & Co. KG, Reinbek, Germany), according to the European Academy of Allergy and Clinical Immunology standard protocol.⁹ Patients positive for at least one allergen were considered subjects with chronic AR. Patients were asked to rate each symptom they perceived (obstruction, rhinorrhea, sneezing, and itching) from 0 to 100 millimeters on the VAS, where 0 refers to a nonannoying symptom and 100 refers to the most annoying symptom.¹⁰

Nasal Cytology

Nasal cytology was performed by applying Gelardi's cytological technique, which was approved by the Italian Academy of Nasal Cytology (AICNA, in the Italian acronym).¹¹ Nasal samples were collected by two physicians (Farina L. and Pagliuca G.) and microscope observation was performed independently by two physicians (Farina L. and Santarsiero S.). All procedures took place in a room with constant humidity and temperature. The examiner asked the patient to blow his/her nose to remove any excess secretions before sample collection. Specimens of nasal epithelium were collected under visual control by scraping the mucosa in the middle third of the inferior turbinate with a sterile nasal curette (Rhino-Probe, Arlington Scientific Inc, Springville, UT, USA). Sample collection was performed for each nostril separately. Each sample was uniformly spread in the middle of a microscope slide, fixed by air-drying and stained with May Grunwald Giemsa quick stain (Bio-Optica Milano SpA, Milan, Italy). Each slide was washed in tap water, air-dried and mounted in a synthetic resin. Finally, a cover glass was applied. Microscopic examination was conducted using a light microscope (Eclipse E-100, Nikon, Tokyo, Japan) equipped with 100x, 400x, and 1,000x objective lenses. The examiners performed a first general observation at a low magnification (100x). Once the area with the highest cell concentration was identified, the examiners focused in on it using a higher magnification lens (400x). Cell counting was performed by placing a drop of immersion oil on the

established area and then counting all the cells present in each observation field using a high magnification lens (1,000x). Cells were counted and categorized as ciliated cells (CCs), goblet cells (GCs), neutrophils, and eosinophils. Each examiner reported the average of each cell type observing five observation fields.

Subjective evaluation of symptoms and nasal cytology were repeated by the same examiners and with the same techniques after a 30-day treatment with glycyrrhizin and mannitol nasal spray (2 sprays per nostril twice a day). Differences between the number of neutrophils and eosinophils and the CCs to GCs ratio after therapy were statistically analyzed. Visual analogue scale scores assessed before and after treatment were also compared.

Statistical Analyses

Statistical analyses were performed using SPSS for Windows version 15.0 (SPSS Inc., Chicago, IL, USA). Continuous variables were presented as means with standard deviations (SDs) and categorical variables were summarized with numbers and proportions. Data normality was assessed using the Kolmogorov-Smirnov test. The Student t-test was used to compare VAS score nasal symptoms and age. The Mann-Whitney U-Test was used to compare the cells counting. The chi-squared test was used for comparisons of the gender distribution of the groups. Differences were considered significant at $p < 0.05$.

Results

No adverse effects were reported during the present study. Thirty-four patients had a positive SPT for inhalant allergens, whereas in 21 cases the SPT did not reveal any allergies. The demographic characteristics of the study population are summarized in **Table 1**.

Table 2 reports VAS scores for nasal symptoms before and after 30 days of intranasal glycyrrhizin and mannitol therapy. All the mean VAS scores reduced significantly after treatment in both allergic and nonallergic subjects. All differences in terms of mean values of VAS scores and p-values in positive and negative SPTs are illustrated in **Table 2**.

Ciliated cells, goblet cells (**Figure 1A**), neutrophils (**Figure 1B**), and eosinophils (**Figure 1C**) were examined

Table 1 Demographic characteristics of the patients

	SPT+	SPT-	p-value
Gender			
M	22	10	> 0.05
F	12	11	
Age (years old)			
Range	19–72	19–69	> 0.05
Average	47.38 ± 18.74	42.57 ± 14.98	

Abbreviations: SPT +, Skin Prick Test positive for at least one allergen; SPT-, Skin Prick Test negative for all the allergens tested.

Table 2 Visual analogue scale scores for nasal symptoms before and after a 30-day treatment with glycyrrhizin and mannitol nasal spray

Symptoms (VAS)	Total VAS score mean values (55 patients)		p-value	VAS score mean values of patients with SPT+ (34 patients)		p-value	VAS score mean values of patients with SPT- (21 patients)		p-value
	Before Therapy	After Therapy		Before Therapy	After Therapy		Before Therapy	After Therapy	
Nasal obstruction	65.27 ± 20.89	50 ± 19.15	$p < 0.001$	65.29 ± 24.52	52.35 ± 20.31	$p < 0.001$	63.33 ± 16.22	46.19 ± 16.87	$p < 0.001$
Rhinorrhea	43.09 ± 23.64	34 ± 20.05	$p < 0.001$	41.47 ± 25.24	31.76 ± 21.67	$p < 0.001$	45.71 ± 21.11	37.62 ± 17	$p < 0.001$
Sneezing	44.54 ± 24.78	32.55 ± 20.57	$p < 0.001$	43.52 ± 24.35	35.59 ± 21.77	$p < 0.001$	41.9 ± 25.61	32.38 ± 22.34	$p < 0.001$
Nasal itching	27.63 ± 22.6	20.54 ± 16.6	$p < 0.001$	31.47 ± 24.39	20.59 ± 15.56	$p < 0.001$	21.43 ± 18.24	14.76 ± 10.78	$p < 0.001$

Abbreviations: SPT +, skin prick test positive for at least one allergen; SPT-, skin prick test negative for all allergens tested. Significant p-values are highlighted in bold.

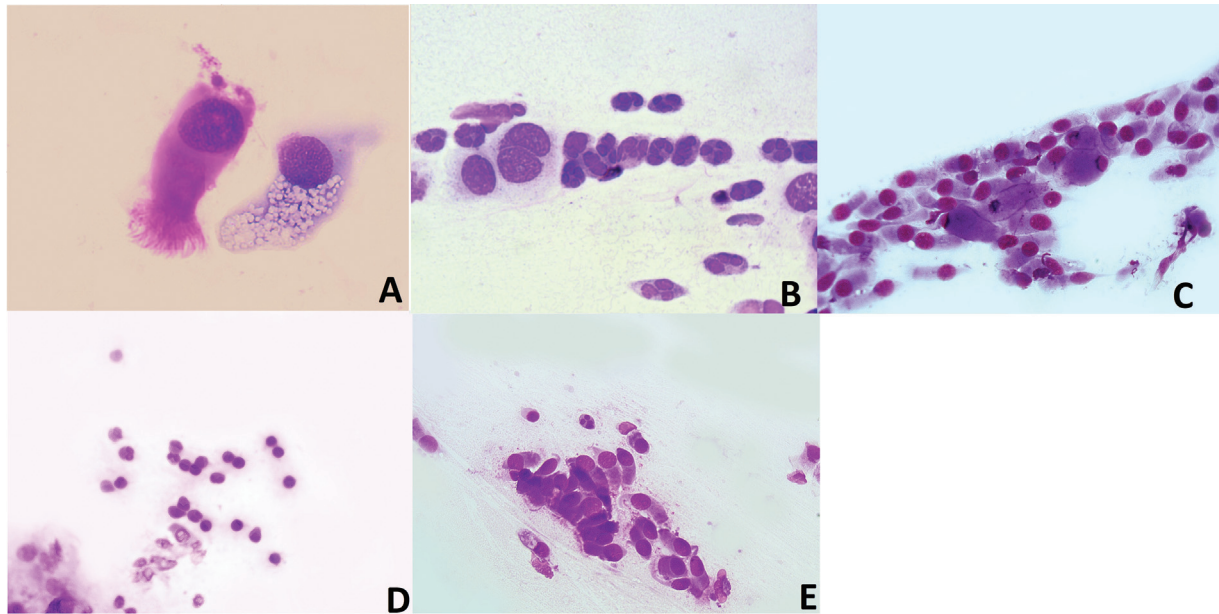


Fig. 1 (A) Ciliated cell and goblet cell obtained by nasal scraping (stained by May Grunwald Giemsa Quick Stain, original magnification x1,000). (B) Neutrophils obtained by nasal scraping (stained by May Grunwald Giemsa Quick Stain, original magnification x1,000). This sample was collected from nonallergic patients before therapy. (C) Sample obtained by nasal scraping (stained by May Grunwald Giemsa Quick Stain, original magnification x1,000). Neutrophils are absent. Notice two goblet cells among the ciliated cells. (D) Eosinophils obtained by nasal scraping (stained by May Grunwald Giemsa Quick Stain, original magnification x400). This sample was collected from allergic patients before therapy. (E) Sample obtained by nasal scraping (stained by May Grunwald Giemsa Quick Stain, original magnification x400). Eosinophils are absent. Notice one neutrophil among the ciliated cells.

and counted. The CCs to GCs ratio did not show a significant change after therapy in both allergic and nonallergic subjects. The average number of neutrophils reduced significantly in both groups after therapy (► **Table 3** and ► **Figures 1D-1E**).

Eosinophils were present in 32 subjects (58.2% of our cases); with 28 out of 34 allergic patients (82%) and 4 out of 21 nonallergic patients (19%). The mean eosinophil count decreased significantly ($p < 0.001$) after 30 days of nasal spray therapy. A significant difference was observed in allergic as opposed to non-allergic subjects (► **Table 3** and ► **Figures 1D-1E**).

Discussion

The present study analyzed the effects of a 30-day mannitol and glycyrrhizin intranasal therapy on nasal symptoms and changes in nasal cytology in selected patients with allergic and nonallergic rhinitis. Glycyrrhetic acid is a potent inhibitor of the HMGB1 protein, a proinflammatory mediator released by inflammatory cells, especially from eosinophils.¹² The HMGB1 protein acts as a late mediator of phlogosis, activating the monocytes through COX2-induction. It was found in high concentrations in nasal secretions collected from patients affected with AR, nonallergic rhinitis with eosinophilia syndrome (NARES), or nasal polyposis.¹³ In all these conditions, eosinophils play a primary pathogenetic role.¹⁴ It has been observed that glycyrrhetic acid not only inactivates the HMGB1 protein, but also prevents its release through eosinophils and promotes eosinophil apoptosis, finally reducing the protein level in nasal secretions.^{13,14}

These observations led to the hypothesis that the presence of high levels of HMGB1 protein in the nasal mucosa could lead to nasal symptoms. Salpietro et al. showed a linear correlation between the amount of HMGB1 protein in nasal secretions and the severity of nasal symptoms.¹⁵ In another study, a 30-day treatment with glycyrrhizin and mannitol nasal spray increased the rate of mucociliary transport in 97.9% of the cases by promoting hair cell differentiation in the nasal epithelium.¹⁶ Both the anti-inflammatory and cleansing action seem to restore the “cytological architecture” of the nasal mucosa.^{17,18} In a comparative study, Mansi et al. observed a similar benefit of intranasal glycyrrhizin and mannitol and intranasal corticosteroid in reducing nasal congestion.⁶

Nasal corticosteroids are currently the first therapeutic choice in chronic rhinopathies. They reduce local immunoglobulin E (IgE) production, which is the pathogenetic basis of AR.¹⁹ Moreover, an overall decrease of the inflammatory infiltrate has been demonstrated, particularly for lymphocytes and eosinophils.²⁰ Ciofalo et al. observed a reduction of neutrophils in the rhinocytogram in acute rhinosinusitis after intranasal sodium hyaluronate therapy.²¹ Gelardi et al. suggested the use of topical corticosteroids in acute forms, while high molecular weight hyaluronic acid may also be employed in CR considering its anti-inflammatory and lubricating qualities.²² A combination of glycyrrhetic acid and mannitol nasal spray has similar proprieties and could be suitable for prolonged use in patients with chronic rhinitis, particularly when corticosteroids should be avoided. Treatment with intranasal corticosteroids is contraindicated in patients with glaucoma or cataracts and their use should also

Table 3 Cell count performed before and after a 30-day treatment with glycyrrhizin and mannitol nasal spray

Cell type	Total mean number of cells (55 patients)		p-value	Mean number of cells in patients with SPT+ (34 patients)		p-value	Mean number of cells in patients with SPT- (21 patients)		p-value
	Before Therapy	After Therapy		Before Therapy	After Therapy		Before Therapy	After Therapy	
Neutrophils	8.34 ± 6.1	5.43 ± 11.76	p < 0.001	9.32 ± 6.35	6.2 ± 11.79	p < 0.001	6.76 ± 5.53	4.19 ± 5.04	p < 0.001
Eosinophils	3.42 ± 3.94	1.69 ± 2.42	p < 0.001	4.61 ± 3.71	2.03 ± 2.02	p = 0.01	1.48 ± 3.59	1.14 ± 2.92	p = 0.1295
Ratio between CC and GC	0.792	0.797	p > 0.8	0.79	0.792	p > 0.8	0.789	0.791	p > 0.8

Abbreviations: SPT+, skin prick test positive for at least one allergen; SPT-, skin prick test negative for all allergens tested. Significant p-values are highlighted in bold.

be limited in patients with liver dysfunctions and during pregnancy, breastfeeding, and in children. Furthermore, the chronic use of corticosteroid nasal sprays, and the consequent mucosal dryness, seems to predispose to recurrent epistaxis.²³ On the other hand, no relevant side effects associated with glycyrrhizin and mannitol nasal therapy have been identified neither in the literature²⁴ nor in our study. Mansi et al. observed an increased incidence of nasal dryness after treatment with glycyrrhizin and mannitol compared with topical corticosteroids, despite the well-known lubricating qualities of the former. The authors attributed this finding to the mechanical insertion of the device in the nasal cavities.⁶

In order to assess the effectiveness of intranasal therapy based on the improvement of the measured symptoms, several studies used different specific questionnaires, categorical scales, or the VAS. In our study, we chose the VAS for the subjective evaluation of the symptoms of the patients since we believe that it is more suitable than the categorical scales when measuring chronic subjective features such as symptoms of CR, as previously reported by other authors.²⁵ In our study, the statistical analysis of the VAS scores showed a significant improvement of all symptoms after therapy in both allergic and nonallergic subjects. Similar results have previously been reported by Mansi et al. in the pediatric population suffering from AR.⁶ In their study, obstruction, rhinorrhea, and sneezing scores showed a significant improvement with a nonsignificant decrease only for itching. In our study, performed on adults, we observed an improvement of all four considered symptoms in both AR and NAR patients.

Nasal cytology is a useful technique in measuring the entity of nasal phlogosis based on the identification of inflammatory cell in nasal mucosa. A correlation between the severity of symptoms and inflammatory cell infiltration in the nasal mucosa have been described.¹¹ The effect of intranasal treatment on nasal inflammation may be measured objectively using nasal cytology performed before and after therapy. To the best of our knowledge, this is the first study to evaluate the effects of intranasal glycyrrhizin and mannitol therapy on AR and NAR using nasal cytology.

The rhinocytogram of a healthy subject is characterized by a prevalence of ciliated and nonciliated columnar cells, mucous cells, and basal cells. Sometimes, there can be sporadic neutrophils and rare bacteria. Normally, ciliated cells and mucous cells have a typical 4 to 1 ratio. The amount of GCs can increase considerably when the nasal mucosa is chronically exposed to irritants.⁷ In a previous study, we observed a reduction in GCs compared with haired cells when nasal inflammation reduced.²⁶ In the present study, the mean count of both haired cells and GCs remained almost constant after therapy, and the ratio between them did not show any significant differences either. A possible explanation is that 1 month of therapy might not be enough to restore the ratio between these two groups of cells, although a reduction of inflammatory cells is present, as suggested by our results. We observed a statistically significant reduction

of neutrophils and eosinophils in our cases. Although neutrophil infiltration of the nasal mucosa is a nonspecific event, it is actually considered to be responsible for typical nasal symptoms during rhinitis.⁷ Their persistence and their continuous release of chemical mediators, especially the neutrophil elastase, may increase the free radicals and the consequent distress of the nasal epithelium, which is clinically characterized by the development of symptoms. Our results seem to confirm the role of glycyrrhetic acid and mannitol in reducing neutrophils in the nasal mucosa in both allergic and nonallergic patients.

Eosinophil counts showed a significant reduction after therapy in all our cases and in allergic patients; on the other hand, we did not observe a significant reduction of cells in nonallergic subjects. In our study, a substantial number of eosinophils were present in specimens of only four nonallergic patients. It is not easy to explain why allergic patients present a significant reduction of eosinophil counts after therapy and nonallergic patients do not. It is possible that, in this subgroup of cases suffering from NARES, uninvestigated mechanisms prevent a reduction of these cells after therapy. However, the low number of NARES cases in our study may not be enough for an accurate statistical analysis. It is also not easy to explain why we did not observe a reduction of GCs compared with hair cells after therapy as we would have expected and as we observed in a previous experience.^{26,27} A possible explanation may be that a 1-month therapy session may be too short to observe significant changes in the numbers of these 2 cell types. Further studies and a larger study sample are required in order to better clarify all the aspects of our results.

Conclusion

Our study would suggest that a 30-day treatment with intranasal glycyrrhizin and mannitol can be considered safe and effective in improving nasal symptoms in patients with CR and in reducing inflammatory cells in their nasal mucosa. The tolerability, safety, and efficacy of this intranasal treatment, as suggested by our results, may make it a valid alternative to intranasal corticosteroids in patients with chronic AR and NAR.

Funding

The present study did not receive any funding from either private, public, or not-for-profit organizations.

Conflict of Interests

The authors have no conflict of interests to declare.

Acknowledgments

We would like to thank Maria Grazia Saladino for her assistance in the English revision of the present manuscript.

References

- Meltzer EO. Allergic Rhinitis: Burden of Illness, Quality of Life, Comorbidities, and Control. *Immunol Allergy Clin North Am* 2016;36(02):235–248
- Gelardi M, Maselli Del Giudice A, Fiorella ML, et al. Quality of life in non-allergic rhinitis depends on the predominant inflammatory cell type. *J Biol Regul Homeost Agents* 2008;22(01):73–81
- Gelardi M, Iannuzzi L, Tafuri S, Passalacqua G, Quaranta N. Allergic and non-allergic rhinitis: relationship with nasal polyposis, asthma and family history. *Acta Otorhinolaryngol Ital* 2014;34(01):36–41
- Segboer C, Gevorgyan A, Avdeeva K, et al. Intranasal corticosteroids for non-allergic rhinitis. *Cochrane Database Syst Rev* 2019 Nov 2;2019:CD010592
- Juel-Berg N, Darling P, Bolvig J, et al. Intranasal corticosteroids compared with oral antihistamines in allergic rhinitis: A systematic review and meta-analysis. *Am J Rhinol Allergy* 2017;31(01):19–28
- Mansi N, D'Agostino G, Scirè AS, et al. Allergic Rhinitis in Children: A Randomized Clinical Trial Targeted at Symptoms. *Indian J Otolaryngol Head Neck Surg* 2014;66(04):386–393
- Gelardi M, Fiorella ML, Russo C, Fiorella R, Ciprandi G. Role of nasal cytology. *Int J Immunopathol Pharmacol* 2010;23(1, Suppl)45–49
- Wallace DV, Dykewicz MS, Bernstein DI, et al; Joint Task Force on Practice American Academy of Allergy Asthma & Immunology American College of Allergy Asthma and Immunology Joint Council of Allergy, Asthma and Immunology. The diagnosis and management of rhinitis: an updated practice parameter. *J Allergy Clin Immunol* 2008;122(2, Suppl)S1–S84
- Heinzerling L, Mari A, Bergmann KC, et al. The skin prick test - European standards. *Clin Transl Allergy* 2013;3(01):3
- Klimek L, Bergmann KC, Biedermann T, et al. Visual analogue scales (VAS): Measuring instruments for the documentation of symptoms and therapy monitoring in cases of allergic rhinitis in everyday health care: Position Paper of the German Society of Allergy (AeDA) and the German Society of Allergy and Clinical Immunology (DGAKI), ENT Section, in collaboration with the working group on Clinical Immunology, Allergology and Environmental Medicine of the German Society of Otorhinolaryngology, Head and Neck Surgery (DGHNOKHC). *Allergo J Int* 2017;26(01):16–24
- Gelardi M, Iannuzzi L, Quaranta N, Landi M, Passalacqua G. NASAL cytology: practical aspects and clinical relevance. *Clin Exp Allergy* 2016;46(06):785–792
- Bellussi LM, Cocca S, Chen L, Passali FM, Sarafoleanu C, Passali D. Rhinosinus Inflammation and High Mobility Group Box 1 Protein: A New Target for Therapy. *ORL J Otorhinolaryngol Relat Spec* 2016;78(02):77–85
- Chen D, Bellussi LM, Cocca S, et al. Glycyrrhetic acid suppressed hmgb1 release by up-regulation of Sirt6 in nasal inflammation. *J Biol Regul Homeost Agents* 2017;31(02):269–277
- Cavone L, Cuppari C, Manti S, et al. Increase in the Level of Proinflammatory Cytokine HMGB1 in Nasal Fluids of Patients With Rhinitis and its Sequestration by Glycyrrhizin Induces Eosinophil Cell Death. *Clin Exp Otorhinolaryngol* 2015;8(02):123–128
- Salpietro C, Cuppari C, Grasso L, et al. Nasal high-mobility group box-1 protein in children with allergic rhinitis. *Int Arch Allergy Immunol* 2013;161(02):116–121
- Passali D, Cappello C, Passali GC, Cingi C, Sarafoleanu C, Bellussi LM. Nasal Muco-ciliary transport time alteration: efficacy of 18 B Glycyrrhetic acid. *Multidiscip Respir Med* 2017;12:29
- Passali D, Bellussi LM, Gregori D, Lauriello M, Passali FM, Passali GCGip Stop Study Group. Nasal obstruction as a key symptom in allergic rhinitis: efficacy and safety of a medical device in children. *Otolaryngol Pol* 2012;66(04):249–253
- Rosato C, Pagliuca G, Martellucci S, et al. Effect of Radiofrequency Thermal Ablation Treatment on Nasal Ciliary Motility: A Study with Phase-Contrast Microscopy. *Otolaryngol Head Neck Surg* 2016;154(04):754–758
- Gelardi M, Incorvaia C, Fiorella ML, et al; Italian Academy of Nasal Cytology. The clinical stage of allergic rhinitis is correlated to

- inflammation as detected by nasal cytology. *Inflamm Allergy Drug Targets* 2011;10(06):472–476
- 20 Ciprandi G, Gelardi M. Trattamento delle riniti allergiche e vasomotorie: il ruolo del beclometasone dipropionato e dell'acido ialuronico (ad alto peso molecolare) [Treatment of allergic and vasomotor rhinitis: the role of beclomethasone dipropionate and hyaluronic acid (with high molecular weight)]. *Recenti Prog Med* 2018 Apr;109(4):257e–265e. Italian
- 21 Ciofalo A, Zambetti G, Altissimi G, et al. Pathological and cytological changes of the nasal mucosa in acute rhinosinusitis: the role of hyaluronic acid as supportive therapy. *Eur Rev Med Pharmacol Sci* 2017;21(19):4411–4418
- 22 Gelardi M, Taliente S, Fiorella ML, et al. Ancillary therapy of intranasal T-LysYal® for patients with allergic, non-allergic, and mixed rhinitis. *J Biol Regul Homeost Agents* 2016;30(01):255–262
- 23 Wu EL, Harris WC, Babcock CM, Alexander BH, Riley CA, McCoul ED. Epistaxis Risk Associated with Intranasal Corticosteroid Sprays: A Systematic Review and Meta-analysis. *Otolaryngol Head Neck Surg* 2019;161(01):18–27
- 24 Bellussi LM, Cocca S, Passali GC, Passali D. HMGB1 in the Pathogenesis of Nasal Inflammatory Diseases and its Inhibition as New Therapeutic Approach: A Review from the Literature. *Int Arch Otorhinolaryngol* 2017;21(04):390–398
- 25 Damiani V, Camaioni A, Viti C, Scirè AS, Morpurgo G, Gregori D. A single-centre, before-after study of the short- and long-term efficacy of Narivent® in the treatment of nasal congestion. *J Int Med Res* 2012;40(05):1931–1941
- 26 Gelardi M, Cavaliere C, Jannuzzi L. Nasal cytology. *J Biol Regul Homeost Agents* 2018;32(1, Suppl. 1):37–40
- 27 Pagliuca G, Rosato C, Martellucci S, et al. Cytologic and functional alterations of nasal mucosa in smokers: temporary or permanent damage? *Otolaryngol Head Neck Surg* 2015;152(04):740–745