Article published online: 2023-02-10

Frontotemporal Craniotomy for Clipping of Unruptured Aneurysm Using a Diamond-Coated Thread Wire Saw and Reconstruction Using Calcium Phosphate Cement without Metal Fixation

Hiroyuki Koizumi, PhD[1] Daisuke Yamamoto[1] Hajime Handa[1] Wakiko Saruta[1] Satoru Shimizu[2] Takuichiro Hide[1] Toshihiro Kumabe[1]

[1] Department of Neurosurgery, Kitasato University School of Medicine, Sagamihara, Kanagawa, Japan
[2] Department of Neurosurgery, Yokohama Brain and Spine Center, Yokohama, Kanagawa, Japan

Address for correspondence Hiroyuki Koizumi, PhD, Department of Neurosurgery, Kitasato University School of Medicine, 1-15-1 Kitasato, Minami-ku, Sagamihara, Kanagawa 252-0375, Japan (e-mail: koizumi-h@cl.cilas.net).

Arch Plast Surg 2023;50:248–253.

Abstract

Metal fixation systems for cranial bone flaps cut by a drill are convenient devices for cranioplasty, but cause several complications. We use modified craniotomy using a fine diamond-coated threadwire saw (diamond T-saw) to reduce the bone defect, and osteoplasty calcium phosphate cement without metal fixation. We report our outcomes and tips of this method. A total of 78 consecutive patients underwent elective frontotemporal craniotomy for clipping of unruptured intracranial aneurysms between 2015 and 2019. The follow-up periods ranged from 13 to 66 months. The bone fixation state was evaluated by bone computed tomography (CT) and three-dimensional CT (3D-CT). The diamond T-saw could minimize the bone defect. Only one wound infection occurred within 1 week postoperatively, and no late infection. No pain, palpable/cosmetically noticeable displacement of the bone flap, fluid accumulations, or other complications were observed. The condition of bone fixation and the cosmetic efficacy were thoroughly satisfactory for all patients, and bone CT and 3D-CT demonstrated that good bone fusion. No complication typical of metal fixation occurred. Our method is technically easy and safety, and achieved good mid-term bone flap fixation in the mid-term course, so has potential for bone fixation without the use of metal plates.

Keywords
- calcium phosphate cement
- cranioplasty
- craniotomy
- diamond-coated thread wire saw
- metal fixation

Introduction

The techniques of cranial bone flap fixation have changed with the development of medical devices. The cranial bone flap was originally fixed with the use of silken threads, nylon thread, or wire. Rigid fixation of bone flaps using titanium plates was first documented in 1991.[1] The titanium plates spectacularly improved the rigidity and stability of the free bone flap. Accordingly, the titanium plates have been adopted worldwide as the most widely and easily used way to fix the cranial bone flap. However, several complications associated with plate fixation have recently been

received
March 8, 2022
accepted after revision
July 23, 2022
article published online
February 10, 2023

DOI https://doi.org/10.1055/s-0042-1758543.
eISSN 2234-6171.

© 2023. The Author(s).
This is an open access article published by Thieme under the terms of the Creative Commons Attribution License, permitting unrestricted use, distribution, and reproduction so long as the original work is properly cited. (https://creativecommons.org/licenses/by/4.0/)
Thieme Medical Publishers, Inc., 333 Seventh Avenue, 18th Floor, New York, NY 10001, USA

documented including pain and discomfort, protrusion of the plates and/or screws on palpation, skin inflammation, ulcer formation, scalp rupture, and infection of the surrounding tissue.[2–5]

The bioabsorbable plate has since been developed to overcome the complications specific to titanium plates but with equivalent efficacy to the titanium implant system.[6,7] Furthermore, bioabsorbable implants do not interfere with clinical imaging. For these reasons, the bioabsorbable plate system is an appealing alternative to the conventional metal plate system. However, bioabsorbable plates are not commonly used in Japan. The intraoperative handling procedure of the bioabsorbable plate system is relatively complex and difficult. However, the greatest impediment to the widespread use of bioabsorbable plates is the much higher cost compared with titanium plates. The implant cost of the bioabsorbable plate is approximately sixfold higher than that of the titanium plate.[7]

Consequently, we have adopted an inexpensive alternative technique for supratentorial craniotomy avoiding the need for flap fixation with metal devices, based on craniotomy using a diamond-coated thread wire saw (diamond T-saw) since 2006.[8,9] The diamond T-saw was originally developed for spinal surgery, which reduces the bone gap for fitted bone flap fixation. A series of 77 adults undergoing elective supratentorial craniotomy suffered no complications such as dural laceration, flap displacement, resorption, or infection of the flap in a follow-up period of up to 50 months.[8]

The only concern as our reports was that methyl methacrylate (MMA) was applied to the burr hole.[8,9] Cranial reconstructive surgery done using MMA has higher rates of infection and wound-healing disorders.[10,11] Study of the long-term consequences of MMA usage for cranioplasty found a 23% complication rate within 8 years of operation.[12] Another study demonstrated that MMA has a high infection rate of 12.7% compared with other materials and is similar to autologous flaps.[13] MMA carries high risks of extrusion, decomposition, and allergic reaction, and the residual monomer from cold polymerization may be toxic.[14–16]

Therefore, we considered the use of calcium phosphate cement. Calcium phosphate cement is a natural component of bone. Calcium phosphate cement is a bioactive grafting material, available as powder that mixed with various pH neutral liquids sets as hydroxyapatite. The crystalline structure and porosity of calcium phosphate are effective as osteoconductive material with better biocompatibility. Calcium phosphate cement has more effective bone repair mechanisms. Patients who underwent calcium phosphate cement cranioplasty had lower incidence of cerebrospinal fluid leak because of the watertight properties of the hardened cement.[17] In contrast to MMA, calcium phosphate cement causes few foreign body reactions and has decent chemical bonding to bone.

Here we present our modified craniotomy experience with a diamond T-saw and reconstruction using calcium phosphate cement without metal fixation, and report the outcomes and provide additional procedural tips.

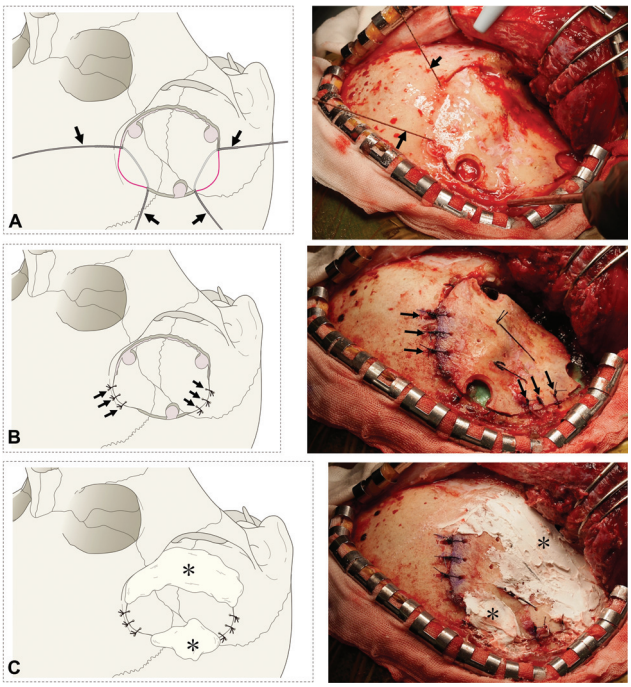

Fig. 1 Schema of surgical technique.
Intraoperative photograph and Illustrations of right frontotemporal craniotomy using a diamond T-saw. (**A**) A bony bridge (red line) is left between two osteotomies performed with a craniotome. Black arrows indicate the diamond T-saw. Using reciprocating strokes, a diagonal slit is created in the bony bridge. Fixation of the bone flap without metal fixation. (**B**) Small drill holes are made from the surface of the bone to the cut edge at each corner of the craniotomy for flap fixation (black arrows). Fixation of the bone flap using nonabsorbable 2–0 sutures (black arrows). Reconstruction using calcium phosphate cement. (**C**) Calcium phosphate cement (asterisks) is used to fill the burr holes and temporal base bone defect.

Idea

Study Population

This study included 78 patients (26 males, 52 females), aged between 33 and 79 years (mean age, 60.9 ± 11.1 years), with unruptured intracranial aneurysm treated at our hospital between June 2015 and December 2019. All patients underwent frontotemporal craniotomy for neck clipping of anterior circulation aneurysm through the pterional approach. Informed patient consent for the analysis was not required because of the retrospective nature of the study; all patients or their guardians consented to undergoing the neurosurgical procedures described in the study.

Surgical Technique

Surgery basically followed our previously reported method.[8,9] The scalp and pericranium were dissected and reflected, then a burr hole was drilled at each corner of the intended craniotomy, the dura dissected from the inner table, and a craniotome partially used for osteotomy between the adjacent burr holes. A medium-sized (the diameter is 0.64 mm) diamond T-saw (MANI, Inc., Utsunomiya, Tochigi, Japan) was introduced between the burr holes through the epidural space using a genuine flexible diamond

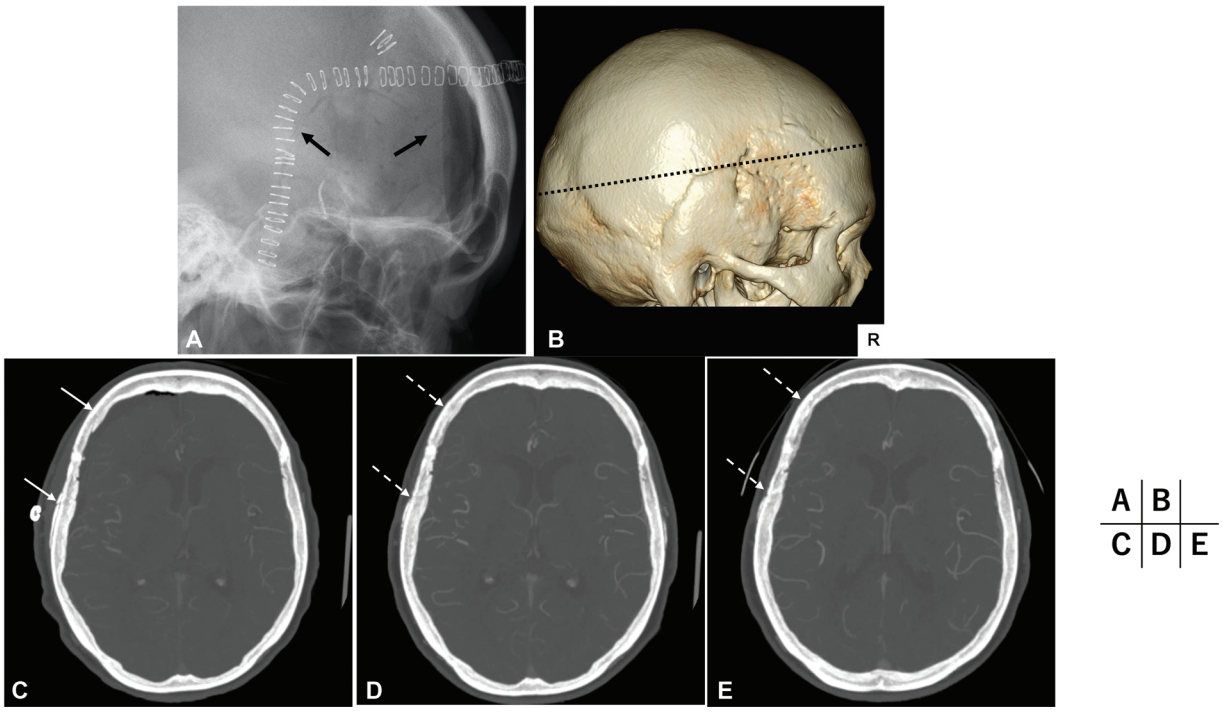

Fig. 2 Case of right frontotemporal craniotomy using a diamond T-saw and reconstruction using calcium phosphate cement without metal fixation.
Lateral views of immediate postoperative skull X-ray. (**A**) Postoperative skull X-ray showed minimum gaps between the bone flap and the surrounding bone (black arrows) were observed in the craniotomy using a diamond T-saw. Lateral view of three-dimensional computed tomography (3D-CT) scan on the third postoperative year. (**B**) Axial bone images of CT scans on the seventh postoperative day. (**C**) Axial bone images were obtained at the level indicated by the dotted black line on 3D-CT as shown in figure B. Postoperative bone CT scans obtained 1 week after the surgery showed a minimum gap between the bone flap and the surrounding bone (white arrow) and no displacement of the bone flap. Axial bone images of CT scans on the first postoperative year. (**D**) Postoperative bone CT scans obtained one and three years after the surgery demonstrated secondary fixation by autologous fibrous and/or osseous fusion (white broken arrows) without bone flap displacement. Axial bone images of CT scans on the third postoperative year (**E**).

T-saw guide catheter. Reciprocating strokes were performed to create a beveled cut, which is key for supporting the bone flap on closure (►**Fig. 1A**). The saw was irrigated with saline solution for cooling and smooth movement during the reciprocating motion. The base of the temporal bone was shaved to get microscopically operative field by drill.

On closure, flap fixation used small drill holes from the surface of the bone to the cut edge at each corner of the craniotomy. Nonabsorbable 2–0 sutures were passed through adjacent holes in the skull and flap and tied (►**Fig. 1B**). Calcium phosphate cement (BIOPEX-R; HOYA Technosurgical Corp., Tokyo, Japan) was filled in the burr holes and temporal base bone gap (►**Fig. 1C**). The lines cut using the diamond-T-saw attached firmly, so calcium phosphate cement insertion is not mandatory. The scalp was closed in the usual fashion.

Clinical Outcomes Data

Follow-up periods ranged from 21 to 75 (median, 53) months. Complications were discovered at return clinic visits and during routine follow-up care. We paid particular attention to incomplete wound healing or skin breakdown at the craniotomy site, deformity in appearance, and infection with purulent drainage. Cosmetic outcome after surgery was assessed by the patients themselves and two neurosurgeons (H.K. and D.Y).

Skull X-ray immediately after the surgery and bone computed tomography (CT) of the head obtained 1 week after the surgery were evaluated for initial displacement of the bone flap and applied calcium phosphate cement. Three-dimensional CT (3D-CT) scans were reconstructed in some cases. Bone CT and 3D-CT obtained 1 and 3 years after the surgery were evaluated for long-term displacement and cosmetic efficacy. Short- and long-term displacement of bone fixation of 5 mm or more was considered as significant. These data were compared with data of 66 cases of the frontotemporal craniotomy using a craniotome and reconstruction with the titanium implant system for neck clipping of ruptured anterior circulation aneurysm through the pterional approach during the same period.

Results

Compared with the craniotomy using a craniotome, the bone gaps between the bone flap and the surrounding bone seemed to be much less on the skull X-ray (►**Figs. 2A, –3A**). 3D-CT image and bone CT at early postoperative period also depicted the calcium phosphate could completely cover the burr hole and the temporal base bone defect (►**Fig. 4A, B**); bone CT after

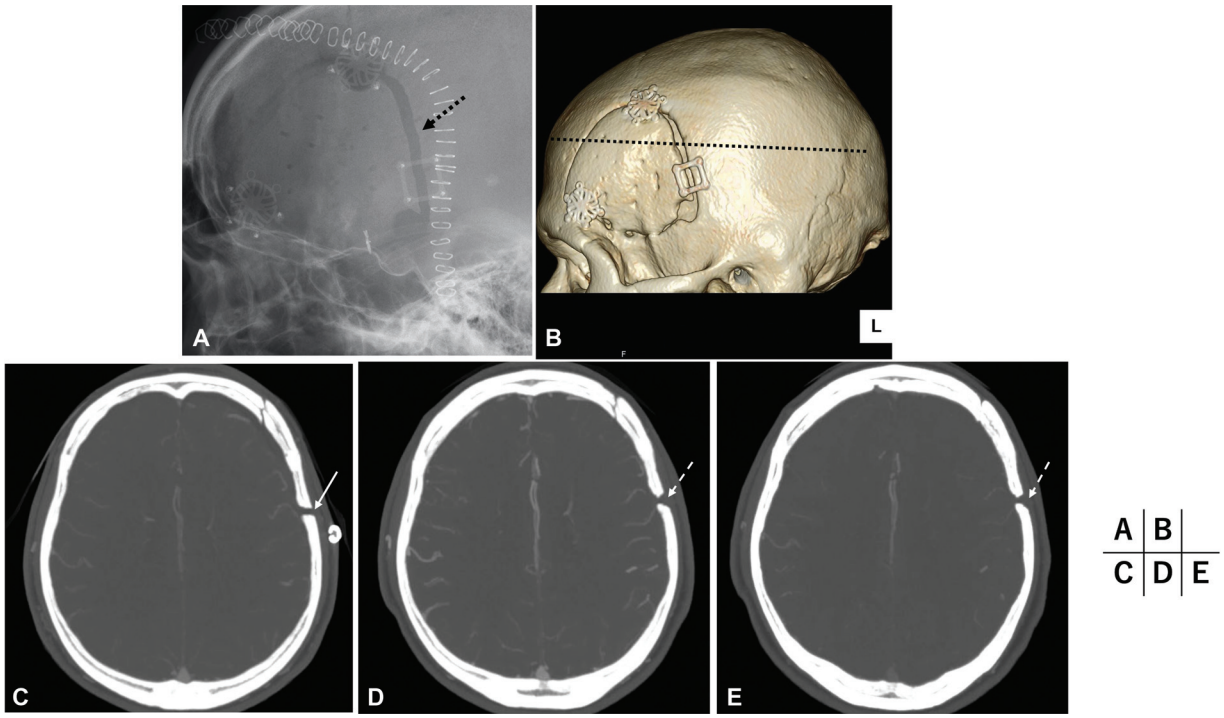

Fig. 3 Case of left frontotemporal craniotomy using a craniotome.
Lateral views of immediate postoperative skull X-ray. (**A**) Postoperative skull X-ray showed wide gaps (black broken arrows) could be detected in the craniotomy using a craniotome. Lateral view of three-dimensional computed tomography (3D-CT) scan on the third postoperative year. (**B**) Axial bone images of CT scans on the seventh postoperative day. (**C**) Axial bone images were obtained at the level indicated by the dotted black line on 3D-CT as shown in figure B. Postoperative bone CT scans obtained 1 week after the surgery showed wide gaps between the bone flap and the surrounding bone (white arrow). Axial bone images of CT scans on the first postoperative year. (**D**) The surgery demonstrated no secondary fixation by autologous fibrous and/or osseous fusion, resulting wide gaps remaining around the bone flap (white broken arrows). Axial bone images of CT scans on third postoperative year (**E**).

third years produced a similar finding (►**Fig. 4C**). Even if the bone flap was not fixed with the titanium implant system, no initial displacements of bone flaps was detected by bone CT (►**Fig. 2C**). Also, owing to the narrow osteotomy obtained by a diamond T-saw, the bone gaps between the bone flap and the surrounding skull were minimum. All patients had long-term bone displacement of less than 5 mm based on bone CT (►**Fig. 2D, –2E**). In addition, postoperative these images obtained 1 (►**Figs. 2D,–4D, 4E**) and 3 years (►**Figs. 2E,–4F, 4G**) after the surgery demonstrated secondary fixation by autologous fibrous and/or osseous fusion between the bone flap and the surrounding skull. In contrast, postoperatively these images after the craniotomy using a craniotome and reconstruction without calcium phosphate cement could not depict the secondary fixation between the bone flap and the surrounding skull, resulted long-term bone gaps (►**Fig. 3**). 3D-CT images obtained 1 (►**Fig. 4D, –4E**) and 3 years (►**Fig. 4F, –4G**) after this procedure demonstrated satisfactory long-term fixation of the bone flap and affinity binding of calcium phosphate cement applied to the burr hole and the temporal base bone defect.

Wound infection within a week postoperatively occurred in only one patient, with no late infection. No pain, palpable displacement of the bone flap that was cosmetically noticeable, fluid accumulation, or other complication occurred. No patient complained of unsatisfactory cosmetic outcomes.

Discussion

Our case series of patients were treated with modified craniotomy with a diamond T-saw and reconstruction using calcium phosphate cement without metal fixation. Satisfactory long-term fixing and no complications were found except for one case of early postoperative wound infection. Cosmetic results using calcium phosphate cement were very satisfactory.

Fixation of bone flaps with only sutures, without using the diamond T-saw, requires that the sutures remain extremely tight until fibrous or osseous fusion occurs. A cadaver study showed that bone flaps immobilized by sutures were immediately structurally unstable and easily dislocated.[18] Therefore, sutures allow micromovements, resulting in delayed osseous fusion. The reduction in bone gap using the diamond T-saw allows stability of initial fixation. In our method, stability was immediate and resulted in adequate bone–bone fixation, so the bone flap remained motionless until secondary fixation by fibrous or osseous fusion occurred. Secondary fixation by autologous fibrous or osseous fusion and calcium phosphate cements can be achieved without problems due to the stability of the primary fixation. This process leads ultimately to good satisfaction with the long-term fixation and cosmetic appearance.

We used calcium phosphate cement to fill the burr holes and temporal base bone gap to avoid the known problems

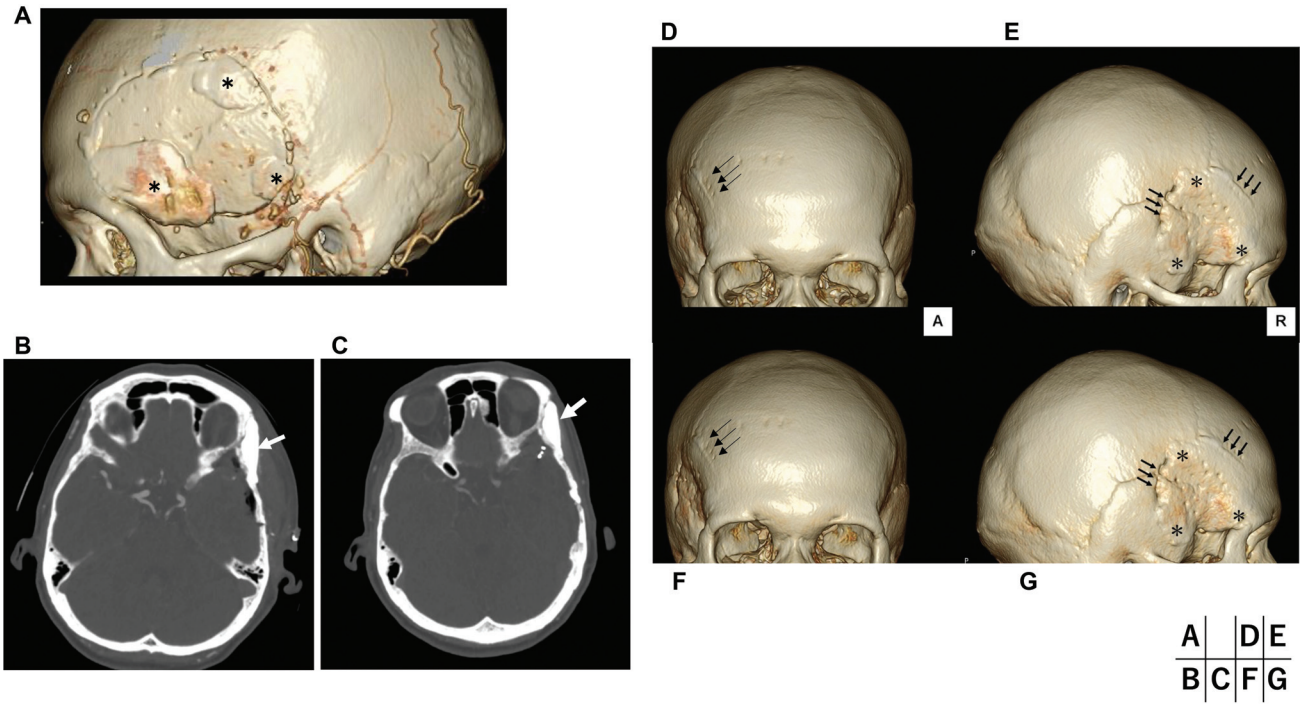

Fig. 4 Outcome of the craniotomy using a diamond-coated thread wire saw.
The seventh postoperative day. (**A**) Lateral view of three-dimensional computed tomography (3D-CT) scan of a patient who underwent left frontotemporal craniotomy using a diamond T-saw and reconstruction using calcium phosphate cement (asterisks) without metal fixation. The seventh postoperative day. (**B**) axial bone image of CT scan. Anteroposterior 3D-CT scans on the first postoperative year. (**C**) axial bone image of CT scan. Anteroposterior 3D-CT scans on the third postoperative year. (**D**) The bone flap was fixed by sutures passing through the opposed small drill holes beside the narrow cutting line made by a diamond T-saw (black arrows). Lateral 3D-CT scans on the first postoperative year. (**E**) A patient who underwent right frontotemporal craniotomy using a diamond T-saw and reconstruction with calcium phosphate cement applied to the burr hole and the temporal base bone defect (asterisks). the cosmetically good reconstruction of the temporal base bone defect using calcium phosphate cement (asterisks). Anteroposterior 3D-CT scans on third postoperative year. (**F**) Lateral 3D-CT scans on the third postoperative year. (**G**) The calcium phosphate could completely cover the burr hole and the temporal base bone defect (asterisks). Satisfactory beauty long-term fixation of the bone flap without metal fixation could be obtained.

with MMA. Fixation and cosmetic outcome were thoroughly satisfactory, and the reconstructions using calcium phosphate cement were free from the various problems involved with MMA. The first Japanese national survey on complications related to cranial implants in neurosurgery indicated that usage of MMA was significantly associated with infection.[19] Our research results further corroborated this finding. Hydroxyapatite undergoes osteointegration in animal models,[20] but there is no evidence for osteointegration for humans in vivo. Demonstration of osteointegration for humans in vivo will not be easy. CT showed bony fusion and affinity between calcium phosphate cements and bone in our series, but we are not sure whether the histological structure is adequate.

This study has several limitations that require discussion. First, our follow-up period was only a median of 45 months. Therefore, only long-term follow-up will show whether the fixation and cosmetic appearance will remain, and the chronic infection rate may change. The only foreign materials were the nonabsorbable sutures, so complications associated with plate fixation including pain and discomfort, protrusion of the plates and/or screws on palpation, skin inflammation, ulcer formation, scalp rupture, and infection of the surrounding tissue will not theoretically happen. Second, the cutting speed of bone using the diamond T-saw is lower than the craniotome. Therefore, this method is not appropriate in patients who require emergent removal of the bone flap for decompression. Third, the retrospective design, nonrandomized patients, surgical technique selection, and the relatively small number of patients treated at a single institute of a single surgical team were all limitations of this study, necessitating further clinical studies to examine the detailed associations between calcium phosphate cement-related complications and long-term outcomes.

In conclusion, our method is technically easy and safety, and achieved satisfying mid-term fixing performance on CT in the mid-term clinical course, so has the potential for skull bone fixation without the use of metal plates.

Ethical Approval

This study was approved by the Kitasato University Hospital Institutional Review Board for Human Research in Sagamihara City, Kanagawa, Japan (B20–344).

Authors' Contributions

H Koizumi and S Shimizu conceptualized the study. H Koizumi, S Shimizu, and T Kumabe contributed to

methodology. T Kumabe and T Hide did the project administration. D Yamamoto, W Saruta, and H Handa helped in investigation. W Saruta and H Handa collected the data. H Koizumi and T Kumabe wrote, edited, and reviewed the original draft. All the authors provided approval of final manuscript.

Patient Consent

Informed consent was obtained from all individual participants included in the study.

Conflict of Interest

None declared.

References

1 Smith SC, Pelofsky S. Adaptation of rigid fixation to cranial flap replacement. Neurosurgery 1991;29(03):417–418

2 Berryhill WE, Rimell FL, Ness J, Marentette L, Haines SJ. Fate of rigid fixation in pediatric craniofacial surgery. Otolaryngol Head Neck Surg 1999;121(03):269–273

3 Gupta R, Adeeb N, Griessenauer CJ, et al. Removal of symptomatic titanium fixation plates after craniotomy. Acta Neurochir (Wien) 2016;158(10):1845–1848

4 Yamada SM, Gorai K, Gonda K. Pinwheel-shaped titanium plates should be fixed to the skull using all screw holes to protect the plates from being bent. Case Rep Surg 2019;2019; 5709285

5 Wakui D, Nagashima G, Ueda T, Takada T, Tanaka Y, Hashimoto T. Three cases of scalp rupture and cosmetic deformity caused by a fixation plate after craniotomy. . [in Japanese]Jpn J Neurosurg 2012;21(02):138–142

6 Noda K, Tanikawa R, Sugimura T, et al. Use of bioabsorbable plates for cranial fixation. Neurol Med Chir (Tokyo) 2009;49(11): 559–562

7 Wu CM, Chen YA, Liao HT, Chen CH, Pan CH, Chen CT. Surgical treatment of isolated zygomatic fracture: outcome comparison between titanium plate and bioabsorbable plate. Asian J Surg 2018;41(04):370–376

8 Shimizu S, Kondo K, Yamazaki T, Nakayama K, Yamamoto I, Fujii K. Repositioning of cranial bone flaps cut with a diamond-coated threadwire saw: 5-year experience with cosmetic cranioplasty without fixation devices. Skull Base 2011;21(05):323–328

9 Shimizu S, Miyazaki T, Suzuki S, et al. Supratentorial craniotomy using a threadwire saw. Technical note. Neurol Med Chir (Tokyo) 2008;48(04):191–194, discussion 194

10 Höhne J, Werzmirzowsky K, Ott C, et al. Outcomes of cranioplasty with preformed titanium versus freehand molded polymethylmethacrylate implants. J Neurol Surg A Cent Eur Neurosurg 2018; 79(03):200–205

11 Novaković N, Malivuković A, Minić L, Lepić M, Mandić-Rajčević S, Rasulić L Cranial reconstruction using autologous bone and methylmethacrilate. J Craniofac Surg 2017;28(04):877–881

12 Blum KS, Schneider SJ, Rosenthal AD. Methyl methacrylate cranioplasty in children: long-term results. Pediatr Neurosurg 1997; 26(01):33–35

13 Matsuno A, Tanaka H, Iwamuro H, et al. Analyses of the factors influencing bone graft infection after delayed cranioplasty. Acta Neurochir (Wien) 2006;148(05):535–540, discussion 540

14 Gautschi OP, Schlett CL, Fournier JY, Cadosch D. Laboratory confirmed polymethyl-methacrylate (Palacos)-hypersensitivity after cranioplasty. Clin Neurol Neurosurg 2010;112(10):915–916

15 Pacheco KA. Allergy to surgical implants. Clin Rev Allergy Immunol 2019;56(01):72–85

16 Shah AM, Jung H, Skirboll S. Materials used in cranioplasty: a history and analysis. Neurosurg Focus 2014;36(04):E19

17 Frederickson AM, Sekula RF Jr. The utility of calcium phosphate cement in cranioplasty following retromastoid craniectomy for cranial neuralgias. Br J Neurosurg 2013;27(06):808–811

18 Lerch KD. Reliability of cranial flap fixation techniques: comparative experimental evaluation of suturing, titanium miniplates, and a new rivet-like titanium clamp (CranioFix): technical note. Neurosurgery 1999;44(04):902–905

19 Yasuhara T, Murai S, Mikuni N, Miyamoto S, Date I. Japanese national questionnaire survey in 2018 on complications related to cranial implants in neurosurgery. Neurol Med Chir (Tokyo) 2020; 60(07):337–350

20 Marcacci M, Kon E, Zaffagnini S, et al. Reconstruction of extensive long-bone defects in sheep using porous hydroxyapatite sponges. Calcif Tissue Int 1999;64(01):83–90