



# An Open Cranial Vault Remodeling Procedure for Craniosynostosis: A Retrospective Study

Anas Abdallah<sup>1</sup>  Meliha Gündoğ Papaker<sup>2</sup>  Gökhan Baloğlu<sup>3</sup> 

<sup>1</sup>Department of Neurosurgery, Istanbul Training and Research Hospital, Samatya, Istanbul, Turkey

<sup>2</sup>Department of Neurosurgery, Bezmialem Vakif University, Fatih, Istanbul, Turkey

<sup>3</sup>Department of Neurosurgery, Osmaniye State Hospital, Merkez, Osmaniye, Turkey

**Address for correspondence** Anas Abdallah, MD, Department of Neurosurgery, Istanbul Training and Research Hospital, Org. Abdurrahman Nafiz Gürman Street, Etyemez, 34098 Samatya, Istanbul, Turkey  
(e-mail: abdallahanas@hotmail.com; dr.anasabdallah@gmail.com).

J Child Sci 2022;12:e212–e223.

## Abstract

Craniosynostosis is a skull malformation occurring due to the premature fusion of one or more cranial sutures. This pathological entity is a relatively commonly observed congenital malformation and is reportedly seen in 1/1,700–1,900 live births. The study aimed to evaluate the surgical outcomes of the open cranial vault remodeling (OCVR) in children with craniosynostosis.

Medical records of 76 children with craniosynostosis who were diagnosed at the neurosurgery departments of our centers for 11 years (from January 2010 to December 2020) were retrospectively examined. Among them, 54 consecutive children who underwent OCVR were included in this study. Surgical outcomes were discussed with a related literature review.

Fifty-four (32 males and 22 females) consecutive children received OCVR for craniosynostosis with a mean age of  $12.6 \pm 7.1$  months. Eight children were syndromic. Three children were shunt-induced craniosynostosis. Syndromic children were four with Apert, two with Pfeiffer, and two with Crouzon syndrome. Twelve children were brothers/sisters. The misshapen skull was the most commonly recorded symptom in 49 children (90.7%). The most affected sutures were bicoronal craniosynostosis found in 20 children. The complication rate was 9.3% ( $n = 5$ ). Two of these five children needed reoperation for optimal remodeling. One child died postoperatively in the intensive care unit due to cardiac arrest.

These findings demonstrated that the OCVR approach is an efficient surgical method to get good outcomes. Satisfactory results with an acceptable complication rate can be obtained with expert hands. Further studies are warranted to support these findings.

## Keywords

- ▶ craniosynostosis
- ▶ open cranial vault remodeling
- ▶ cranioplasty
- ▶ children
- ▶ surgical outcomes

## Introduction

Craniosynostosis is a skull malformation occurring due to the premature fusion of one or more cranial sutures. It can cause neurological deficits and esthetic deformations by restricting skull growth, thereby restricting brain parenchymal devel-

opment.<sup>1,2</sup> This pathological entity is a relatively common congenital malformation and reportedly occurs in 1 of 1,700 to 1,900 live births. Pediatric neurosurgeons divided craniosynostosis into two main groups: primary and secondary craniosynostoses. Primary craniosynostosis is further

received  
August 21, 2022  
accepted  
August 23, 2022

DOI <https://doi.org/10.1055/s-0042-1758809>.  
ISSN 2474-5871.

© 2022. The Author(s).  
This is an open access article published by Thieme under the terms of the Creative Commons Attribution License, permitting unrestricted use, distribution, and reproduction so long as the original work is properly cited. (<https://creativecommons.org/licenses/by/4.0/>)  
Georg Thieme Verlag KG, Rüdigerstraße 14, 70469 Stuttgart, Germany

divided into two subgroups: nonsyndromic and syndromic. Children with nonsyndromic craniosynostosis are reported sporadically. Nonsyndromic craniosynostosis is usually associated with isolated single-suture synostosis with normal neurological and intelligence development.<sup>2,3</sup> Syndromic craniosynostosis comprises 5 to 15% of all patients with craniosynostosis and is generally associated with multiple sutures. Children with syndromic craniosynostosis may be clinically diagnosed with high intracranial pressure (ICP). These children may have other congenital pathologies and developmental retardation. These pathologies include mental retardation, epilepsy, hydrocephalus, Chiari malformation, syringomyelia, spina bifida, and venous anomalies.<sup>4</sup>

Both magnetic resonance imaging (MRI) and/or three-dimensional computed tomography (3D-CT) are essential to diagnose craniosynostosis. The brain parenchymal pressure can be evaluated using an MRI and/or 3D-CT remains the gold standard screening method for a better examination of suture closure.<sup>5-7</sup>

Several factors are affecting the management of children with craniosynostosis. These factors include prematurely fused sutures, clinical presentations, general status, comorbidities, and radiological findings.<sup>1-7</sup> Surgeons manage craniosynostosis conservatively or surgically regarding the previously mentioned factors. Conservative treatment approaches include massaging, helmet therapy, changing lying positions, and physiotherapy. Surgical techniques include classic open remodeling approaches with or without fronto-orbital advancement (FOA) and minimally invasive endoscopic surgeries. The surgeons generally use a suitable intervention that gives the maximal calvarial correction with the minimal complication rate. Either it was open or minimally invasive endoscopic surgical intervention. Tessier was the first who defined the principles of modern craniofacial surgery.<sup>1</sup> With the advancements of these principles, surgical intervention has been accepted as the standard treatment method for craniosynostosis. Early surgical intervention is recommended for both syndromic and nonsyndromic craniosynostosis.<sup>1-7</sup> In complicated cases, early interventions facilitate proper craniofacial growth and reduce neurological complications associated with high ICP.<sup>1</sup> Therefore, this retrospective study aimed to evaluate the surgical outcomes of open cranial vault remodeling (OCVR) in children with craniosynostosis.

## Patients and Methods

### Studied Patient Sample and Data Collection

Medical records of 76 children with craniosynostosis who were diagnosed at neurosurgery departments of our centers for 11 years (from January 2010 to December 2020) were retrospectively examined. Among them, 54 consecutive children who underwent OCVR were included in this study. Inclusion criteria were (1) diagnosis of craniosynostosis made using an MRI and 3D-CT after presenting clinical symptoms of skull malformation, (2) age <36 months, (3) children with parents who signed written consent for the surgical procedure and the study participation, and (4)

children who underwent OCVR. Exclusion criteria were (1) age >36 months, (2) no preoperative scanning (MRI and 3D-CT) images, (3) children lost to follow-up, and (4) children who did not attend control visits.

The authors discussed surgical outcomes with a related literature review.

### Ethics Committee Approval

Our institution's Non-interventional Research Ethics Committee approved this retrospective study on December 18, 2018, with the decision number of 23/289.

### Evaluation of the Children with Craniosynostosis

The first doctors who diagnose children with craniosynostosis are pediatricians. They distinguish malformed skulls and then refer the children to neurosurgeons or craniofacial teams of craniosynostosis evaluation. The teams request further radiological investigations, including ultrasonography (USG), 3D-CT, and MRI, for all craniosynostosis-suspected children. Generally, the evaluation is performed by a multidisciplinary team. The majority of the craniosynostosis children's families present to a physician to restore the proper head shape aesthetically. The main indication for surgical treatment is to avoid the sequela of a high ICP (>15 mm Hg).<sup>1-4</sup> An increased ICP can cause a neurodevelopmental delay.<sup>1-3</sup>

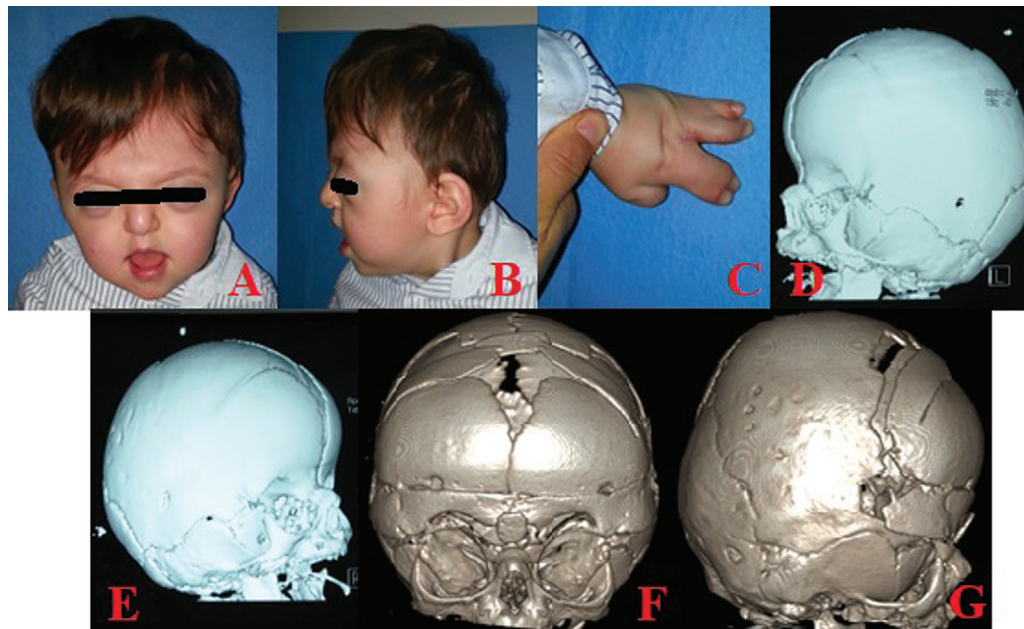
Our general approach is operating all children who are believed to be benefited from the remodeling surgery. When the families disagreed with immediate surgical intervention, close follow-up with serial eye examinations was recommended. When papilledema or ICP symptoms are detected, surgical treatment was encouraged strongly.

### Genetic Analysis

All patients evaluated had undergone detailed physical examination by an expert clinical geneticist. With the presence of associated pathologies in suspicion of syndromic craniosynostoses, the entailed genetic tests including chromosome analysis, array comparative genomic hybridization, and targeted gene sequences were requested. These associated pathologies include microcephaly, ear abnormality, syndactyly, developmental delay, epilepsy, or congenital malformations. In this series, the authors operated on eight syndromic children; four with Apert, two with Pfeiffer, and two with Crouzon syndrome.

### Preoperative Evaluation

An experienced physician can differentiate deformational and positional craniosynostoses. In positional craniosynostosis, the physicians should eliminate underlying causes such as torticollis or other malformations. In suspected deformational children, the child was referred to the Department of Neuro-ophthalmology to evaluate increased ICP-induced dilated eye examination and visual abnormalities. Imaging scans including 3D-CT and MRI were requested. After confirming the diagnosis with scans, all treatment options and unlikely complications were discussed with the family.



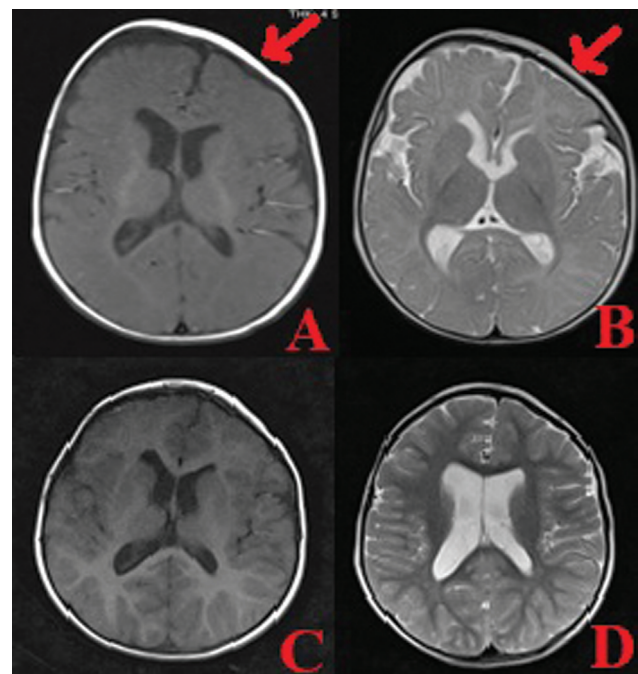
**Fig. 1** Preoperative images, 3D-CT, and postoperative 3D-CT of a 7-month-old boy diagnosed with Apert syndrome. The child was treated using the FOA procedure. (A, B) Preoperative photo demonstrating head malformation, (C) syndactyly, (D, E) bilateral preoperative 3D-CT images showing bilateral coronal synostosis suture (brachycephaly), and (F, G) the 9-month postoperative 3D-CT demonstrating satisfactory decompression. 3D-CT, three-dimensional computed tomography; FOA, fronto-orbital advancement.

### Surgical Strategies

The same neurosurgical team (at least one of two neurosurgeon authors) performed all surgeries. The FOA procedure was applied to the bicoronal (►Fig. 1), unicoronal (►Fig. 2), and metopic sutured craniosynostosis (►Fig. 3), which were the same as follows:

The child was placed in the supine position with general anesthesia. To reduce bleeding, a mixture of epinephrine and lidocaine (1:1) was injected at least 10 minutes before making the incision. The bicoronal zig-zag incision was performed to expose the calvarium (►Fig. 3). The bitemporal muscles were dissected. The subperiosteal dissection was then performed to reach the supraorbital rim. The dissection was continued to expose the medial orbital walls. The whole frontonasal bone was revealed appreciating the supraorbital nerve. To promote dural compatibility, the frontal bone segment was separated by dural attachments. The frontal craniotomy was achieved 1 cm above the orbital bar. By removing the orbital rim, midline osteotomy is started at the point of medial orbital walls that intersect with orbital ceilings. Before releasing the orbital bar, osteotomies were made 2 cm posterior from both lateral edges of the orbital bar. The triangular-shaped orbital bar was reshaped into its anatomical angles and curves (►Fig. 3F–G) and placed on the nasal root and fixed with absorbable plate screws. The freed frontal bone segment was fixed using the orbital bar. Remodeled fronto-orbital bone segments were fixed to the bitemporal areas using absorbable plate screws. The frontal bone was then stabilized to the parietal bones. Both dissected temporal muscles were sutured on the remodeled orbital bar and moved forward for mobilization.

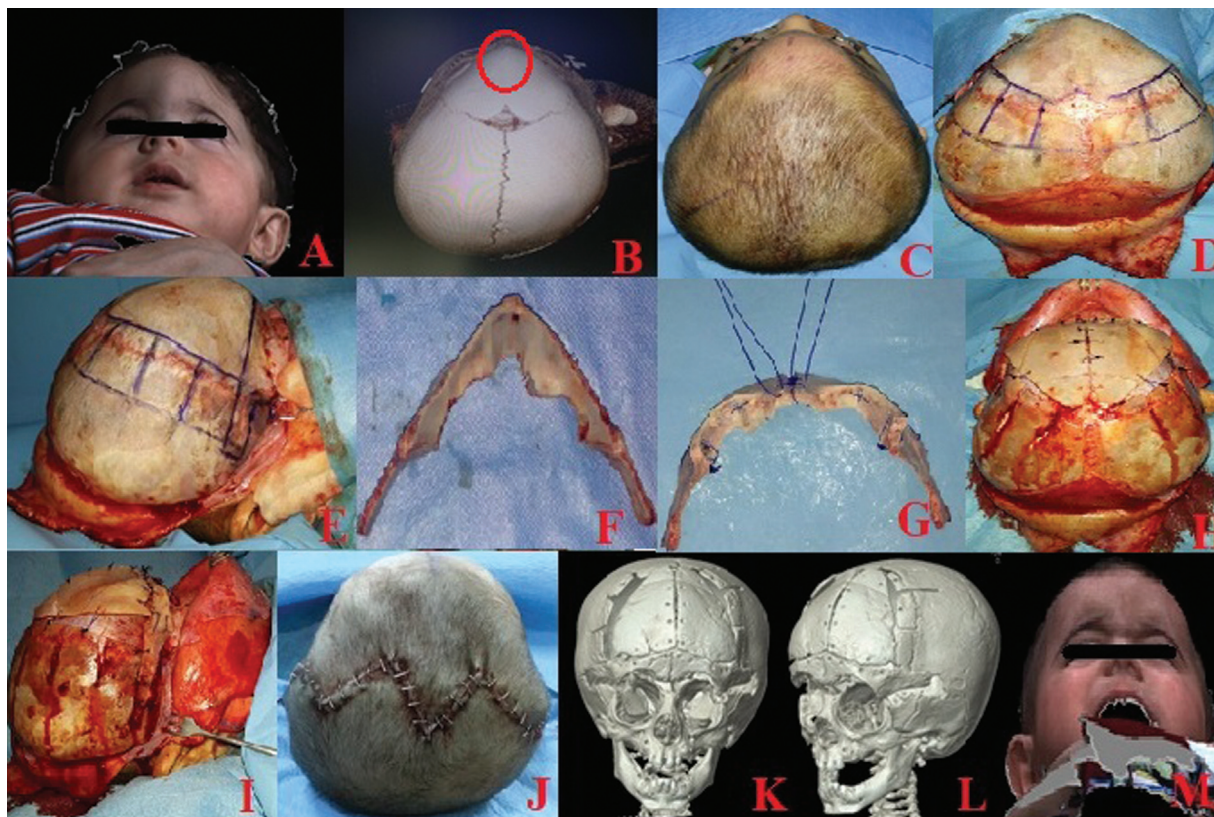
For sagittal synostosis (►Figs. 4 and 5), the total calvarial vault reconstruction (CVR) procedure was applied as follows:



**Fig. 2** The pre- and 27-month postoperative MRIs of a 10-month-old girl diagnosed with left coronal synostosis (unicoronal craniosynostosis). She was treated using the FOA procedure. (A) The preoperative T1WI. (B) In the preoperative T2WI, red arrows in panels (A) and (B) demonstrate the skull deformity. (C) The 27-month postoperative T1WI. (D) The 27-month postoperative T2WI. FOA, fronto-orbital advancement; MRI, magnetic resonance imaging.

The child was placed in the supine position with general anesthesia. To reduce bleeding, a mixture of epinephrine and lidocaine (1:1) was injected at least 10 minutes before making the incision. The bicoronal zig-zag incision was





**Fig. 3** A 9-month-old boy who was referred to our outpatient clinic due to head deformity. (A) The preoperative photo demonstrating a deformed (triangular) head. (B) The preoperative 3D-CT demonstrating trigonocephaly (red circle). (C) The perioperative photo showing the supine position of the child to prepare him for surgical intervention. (D–I) The FOA procedure planning, the posterior (D) and lateral (E) intraoperative photos. (F) The removed triangular-shaped orbital bar. (G) Remodeling the orbital bar on the operative table, the posterior (H) and lateral (I) intraoperative photos of the skull after the FOA procedure and before the scalp layer closure. (J) The 2-week postoperative image of the zig-zag incision was closed with staplers. The 9-month postoperative 3D-CT anterior (K) and lateral (L) images demonstrate postoperative changes. (M) The 9-month postoperative photo of the child. 3D-CT, three-dimensional computed tomography; FOA, fronto-orbital advancement.

performed to expose the calvarium. After dissecting the bitemporal muscles up to the squamous part of the temporal bone, at least four burr holes were made 2 cm lateral to the midline using a high-speed motor. Along the sagittal suture, a 1-cm-wide bilateral osteotomy was performed. The occipital and frontal bone segments were osteotomized and remodeled. The temporal and parietal bone segments (i.e., lateral barrel stave osteotomies) were osteotomized. Thus, the biparietal expansion was achieved (► Fig. 4H–I).

For uni/bilateral lambdoid synostosis, the whole CVR procedure was applied as follows:

The child was placed in a modified prone position. Up until the craniotomy procedure, all steps are the same as in those with sagittal synostosis. The biparieto-occipital craniotomy was achieved. Next, osteotomies were completed by reshaping the bone more symmetrically with radial osteotomies.

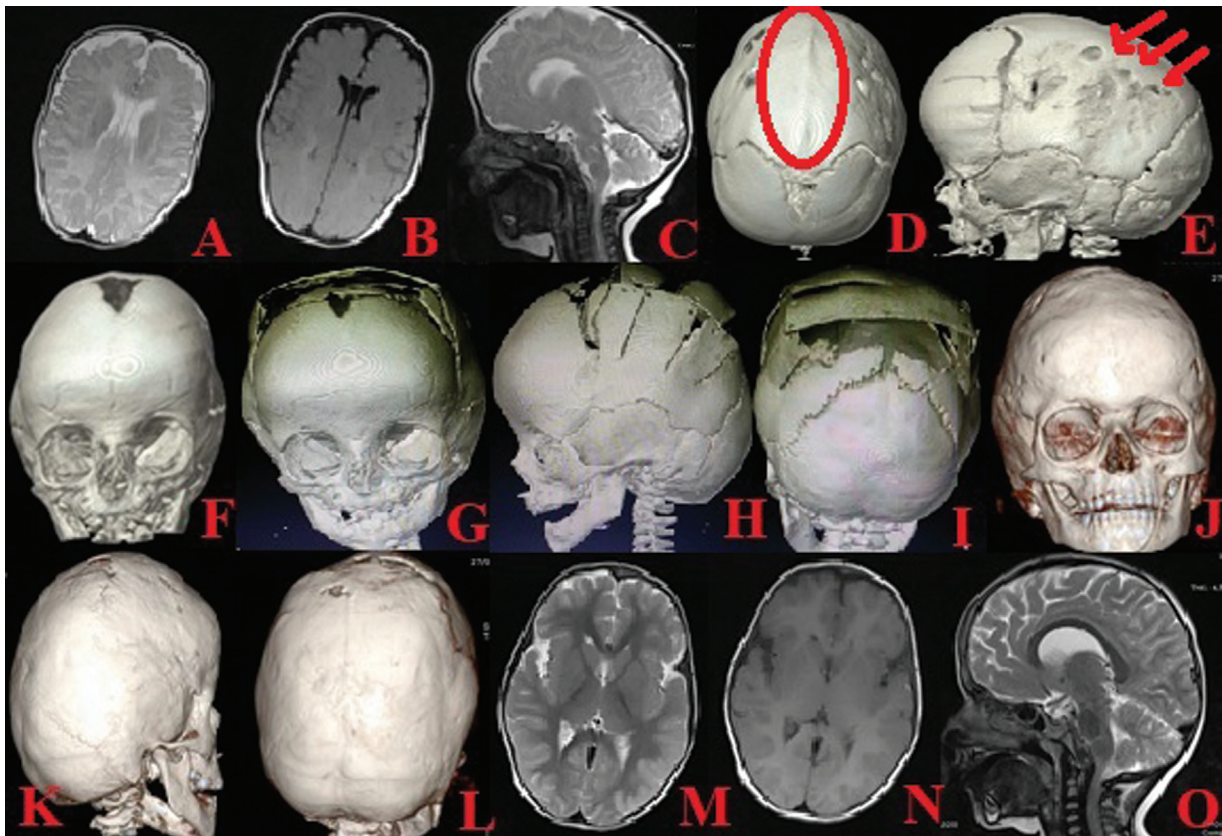
In all cases, a silicon drain was placed on the bones, and scalp layers were sutured according to their anatomical layers. After the sterile dressing, a head bandage was applied and terminated the operation. The child was followed up in the pediatric intensive care unit (PICU) postoperatively.

### Postoperative Care and Follow-Up

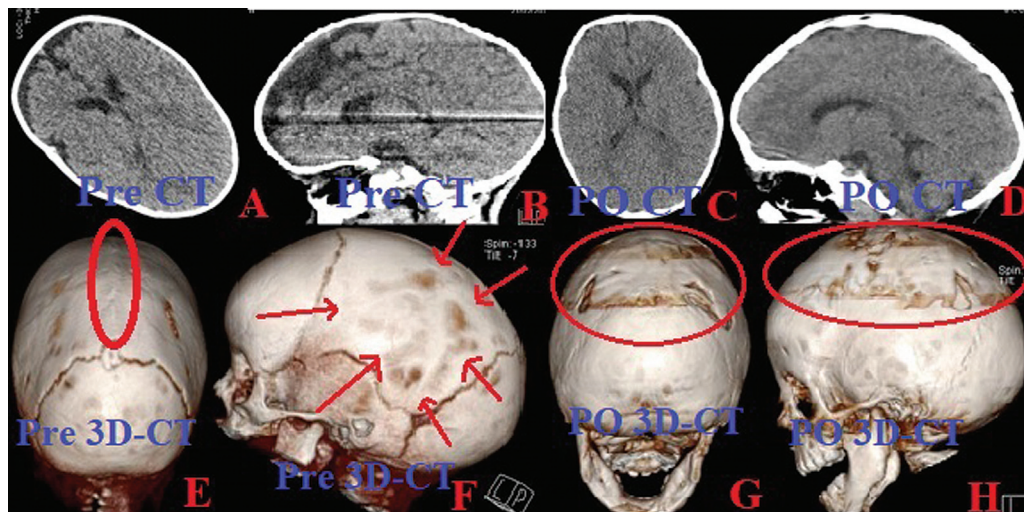
All children were followed up in the PICU within at least 24 hours postoperatively. Within the first 4 to 6 postoperative hours, the CT was requested to evaluate postoperative complications. Postoperative antibiotics were administered based on the child's weight for at least 3 days postoperatively. Corticosteroids were not used for any child. All patients who had uneventful postoperative courses without any surgical complications were discharged on postoperative day 3. The postoperative routine control visits were performed at the 3, 9, 21, and 33 months to follow up the children's neurological status, inspect skull shapes, measure their head circumferences, and check early and late surgery complications such as new neurological deficits, seizure, hydrocephalus, or other complications. If it was indicated, postoperative 3D-CT and/or MRI was requested. Early and late surgery-related complications including epidural hematomas, subdural hematomas, hydrocephalus, infections, or bones fused incorrectly were recorded.

To evaluate the cosmetic outcome, we modified the classification described by Sloan et al in 1997.<sup>2</sup> They defined a seven-category classification to analyze their surgical outcomes and applied this system on 115 of 250 treated children





**Fig. 4** A 7-month-old girl who was referred to our outpatient clinic due to head deformity. She was treated using the CVR procedure. (A–C) The preoperative MRI axial T2WI (A), T2WI (B), and sagittal T2WI (C) images demonstrating the compression in bi-temporal and biparietal areas. (D–F) The preoperative 3D-CT posterior (D), lateral (E), and anterior (F) images demonstrating the scaphocephaly (red circle) and “copper-beaten skull” (red arrows). (G–I) The 1-week postoperative 3D-CT anterior (G), lateral (H), and posterior (I) images demonstrating the bone grafts and the lateral barrel stave osteotomies. (J–L) The postoperative 33-month 3D-CT anterior (J), lateral (K), and posterior (L) images demonstrating the remodeled skull. (M–O) The postoperative 33-month MRI axial T2WI (M), T1WI (N), and the sagittal T2WI (O) images demonstrating adequate decompression. 3D-CT, three-dimensional computed tomography; CVR, calvarial vault reconstruction; MRI, magnetic resonance imaging.



**Fig. 5** A 6-month-old boy who was treated in our department for scaphocephaly. (A, B) The preoperative CT axial (A) and sagittal (B) images. (C, D) The 33-month postoperative CT axial (C) and sagittal (D) images demonstrating the compression in bi-temporal and biparietal areas. (E, F) The preoperative 3D-CT posterior (E) and lateral (F) demonstrating the scaphocephaly (red circle in panel E), “copper-beaten skull” (red arrows). (G, H) The 33-month postoperative 3D-CT posterior (G) and lateral (H) images demonstrating the remodeled skull and fused osteotomies (red circles in panels G and H). 3D-CT, three-dimensional computed tomography.

with craniosynostosis. According to their classification, classes 1 to 4 represent excellent to good overall correction of the deformity. These four classes vary in the degrees of palpable and/or visible irregularities. In class 1, none was observed, and reoperation-required irregularities were observed in class 4. Classes 5 to 7 represent compromised correction. In class 5, significantly compromised correction not requiring surgery was observed and requiring surgery in classes 6 and 7, with declining further surgery in class 7. To analyze their findings statistically, they used point system ranges between 0 and 4 points.<sup>2</sup> However, this system is complicated with several variables, and it does not evaluate surgery-related mortalities. We divided the cosmetic outcomes into five categories: good symmetrical outcome, good with minor irregularities that do not require surgery, good or compromised with reoperation-required major irregularities, bad outcomes requiring reoperation, and surgery-related death.

### Statistical Analysis

All statistical analyses were conducted using the SPSS 21.0 software (Microsoft Co., Chicago-IL, United States). To describe the demographic and descriptive data, frequency (percent) and mean  $\pm$  standard deviation with ranges in parenthesis were used. Normally distributed data were analyzed using an independent sample *t*-test. A *p*-value of  $<0.05$  was considered statistically significant. All tests were two-tailed.

### Results

Fifty-four (32 males and 22 females) consecutive children received OCVR for craniosynostosis with a mean age of  $12.6 \pm 7.1$  (range: 2–31) months. Eight children (14.8%) were diagnosed with syndromic craniosynostosis. Shunt-induced craniosynostosis was diagnosed in three children (5.6%) (two of them were brothers). The remaining 51 children (94.4%) were diagnosed with primary craniosynostosis (**►Table 1**). Syndromic children were four with Apert (**►Fig. 1**), two with Pfeiffer (**►Fig. 6**), and two with Crouzon syndrome (**►Fig. 7**). Twelve children (22.2%) were brothers/sisters. Four of them were twins from two families. The misshapen skull was the most commonly recorded symptom in 49 children (90.7%). The malformed head was the most observed clinical finding in 49 children (90.7%). Other symptoms and clinical findings are given in **►Table 2**. The most affected sutures were bicoronal craniosynostosis found in 20 children (37.0%) (**►Fig. 1**), followed by sagittal ( $n=14$ ) (**►Figs. 4** and **5**), metopic ( $n=12$ ) (**►Fig. 3**), unicoronal ( $n=5$ ) (**►Fig. 2**), multiple ( $n=2$ ), and bilateral lambdoid synostosis ( $n=1$ ). The complication rate was 9.3% ( $n=5$ ). Good cosmetic outcomes were seen in 51 (94.4%); good in 41 and good outcomes with irregularities not requiring reoperation in 10. Bad cosmetics requiring reoperation outcomes for optimal remodeling were seen in 2 (3.7%) children. One child (1.9%) died postoperatively in the intensive care unit (ICU) due to cardiac arrest. This child experienced intraoperatively profuse bleeding. Another patient experienced a dural tear that was repaired by primary

**Table 1** The studied children with craniosynostosis according to our study criteria ( $n=54$ )

Variables	The number of pts (%)
Study period	January 2010–December 2020
All pts diagnosed w/ CS	76 (100%)
Observed pts w/o surgeries (managed conservatively)	9 (11.8%)
Refused surgeries by families (managed conservatively)	4 (5.3%)
Lost data to follow-up	7 (9.2%)
Developed anaphylactic reaction (managed conservatively)	1 (1.3%)
Preoperative death (milk aspiration)	1 (1.3%)
Pts included in the study	54 (71.1%)

Abbreviations: CS, craniosynostosis; pts, patients; w/, with; w/o, without.

suturing, resulting in delayed surgical closure and paracetamol toxicity (**►Table 3**).

The mean operative time, intraoperative bleeding volume, blood transfusion volume, duration of PICU stay, and length of hospital stay (LOS) were  $180.5 \pm 66.2$  minutes (range: 115–265 minutes),  $278.8 \pm 130.8$  ccs (range: 90–420 ccs),  $210.2 \pm 50.8$  ccs (range: 130–340 ccs),  $1.4 \pm 1.1$  days (range: 1–5 days), and  $3.9 \pm 1.4$  days (range: 3–8 days) (**►Table 2**), respectively. The mean follow-up period was  $59.6 \pm 41.2$  months (range: 2–133 months).

### Illustrative Cases

#### Case 1

A 7-month-old boy diagnosed with Apert syndrome was brought to our outpatient clinic with a head malformation (**►Fig. 1A, B**). Scanning images (3D-CT and MRI) demonstrated bicoronal synostosis (brachycephaly) (**►Fig. 1D, E**). He had syndactyly (**►Fig. 1C**). The FOA procedure was performed. The 9-month postoperative 3D-CT revealed a satisfactory decompression and acceptable surgical outcome (**►Fig. 1F, G**).

#### Case 2

A 10-month-old girl diagnosed with left coronal synostosis (**►Fig. 2A, B**) was treated with the FOA procedure (**►Fig. 2C, D**).

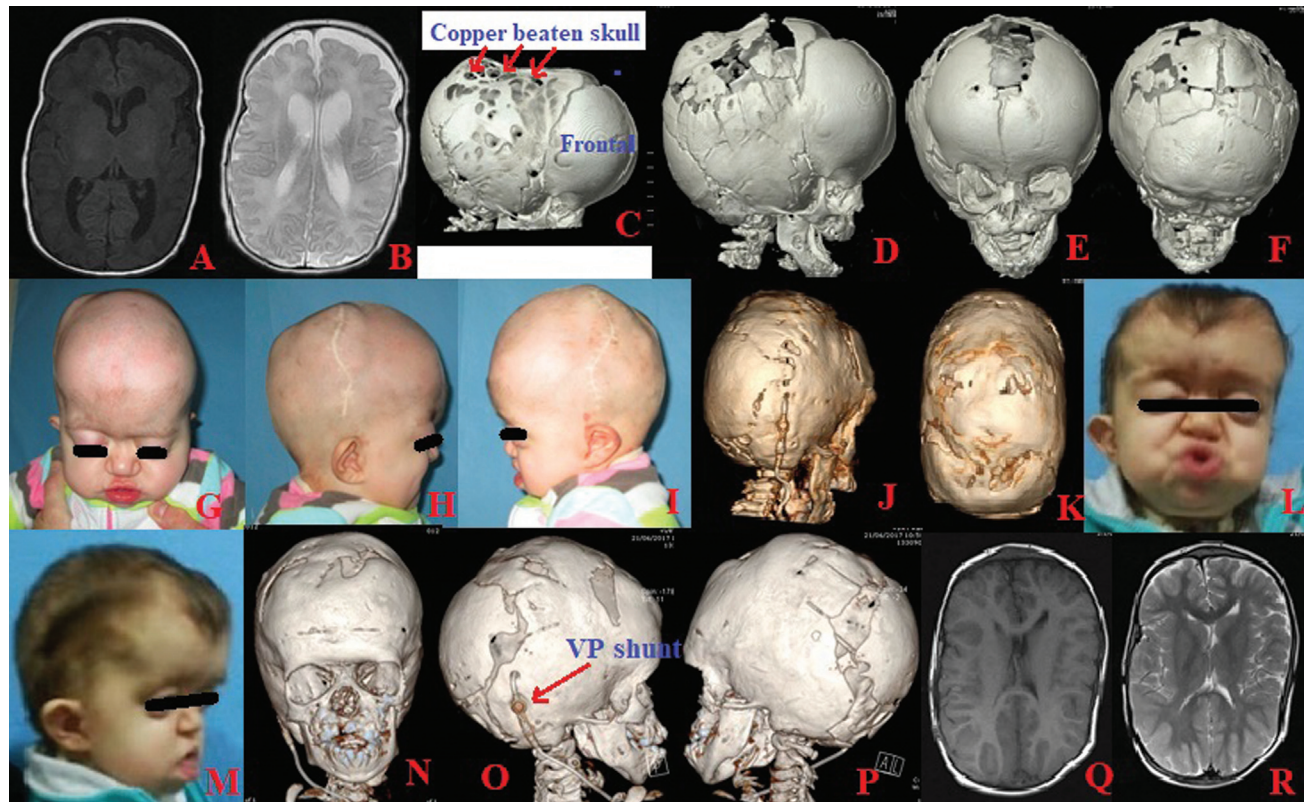
#### Case 3

A 9-month-old boy was referred to our outpatient clinic with a head deformity (**►Fig. 3A**). His preoperative images confirmed the diagnosis of metopic suture synostosis (trigonocephaly) (**►Fig. 3B**). The FOA procedure was performed (**►Fig. 3C–I**). His 9-month postoperative 3D-CT images demonstrated postoperative changes (**►Fig. 3K, L**).

#### Case 4

A 7-month-old girl presented to our outpatient clinic with a head deformity. Her preoperative scanning images





**Fig. 6** The child was diagnosed with Pfeiffer syndrome type 2. (A, B) The preoperative T1WI (A) and T2WI (B) images at the age of 1 month. (C) The preoperative 3D-CT lateral aspect at 3 months of age demonstrating a copper-beaten skull in parietotemporal bones (cloverleaf-shaped skull). (D–F) The 1-month postoperative 3D-CT lateral (D), anterior (E), and posterior (F) images (at 5 months of age) demonstrating the places of frontoparietal craniotomy and osteotomies. (G–I) The 1-month postoperative photos of the child. (J, K) The 3-month postoperative 3D-CT posterior (J) and apex (K) images after the occipital craniotomy procedure and 9 months after ventriculoperitoneal shunt insertion. (L, M) The 4-year age photos of the child. (N–R) The 6-year control-visit 3D-CT anterior (N), lateral (O), lateral posterior (P), T1WI, (Q) and T2WI (R) images. 3D-CT, three-dimensional computed tomography.

(►Fig. 4A–F) confirmed the diagnosis of sagittal suture synostosis (scaphocephaly). The child was treated with a CVR. The 1-week (►Fig. 4G–I) and 33-month postoperative 3D-CTs (►Fig. 4J–L) and MRI (►Fig. 4M–O) demonstrated postoperative changes and satisfactory brain decompression.

#### Case 5

A 6-month-old boy with scaphocephaly was treated with CVR in our department (►Fig. 5).

#### Case 6

In the third in vitro fertilization trial (with a 32-year-old mother and a 35-year-old father), the child who was born via cesarian section at 38 weeks of gestation, with the weight of 3,320 g and the height of 49 cm at birth, was brought to the neonatal ICU due to respiratory distress. The child was diagnosed with Pfeiffer syndrome type 2. The child had choanal atresia, proptosis, hypertelorism, maxillary hypoplasia, brachydactyly, and a cloverleaf-shaped skull (►Fig. 6). Then, the child was treated surgically for choanal atresia at 2 days old. At 4 months old, a remodeling procedure of the frontoparietal bone was performed. After 8 months, the FOA procedure was performed. In the 6th postoperative month, hydrocephalus was observed and treated by inserting a ventriculoperitoneal shunt. At 6 months posttreatment, an

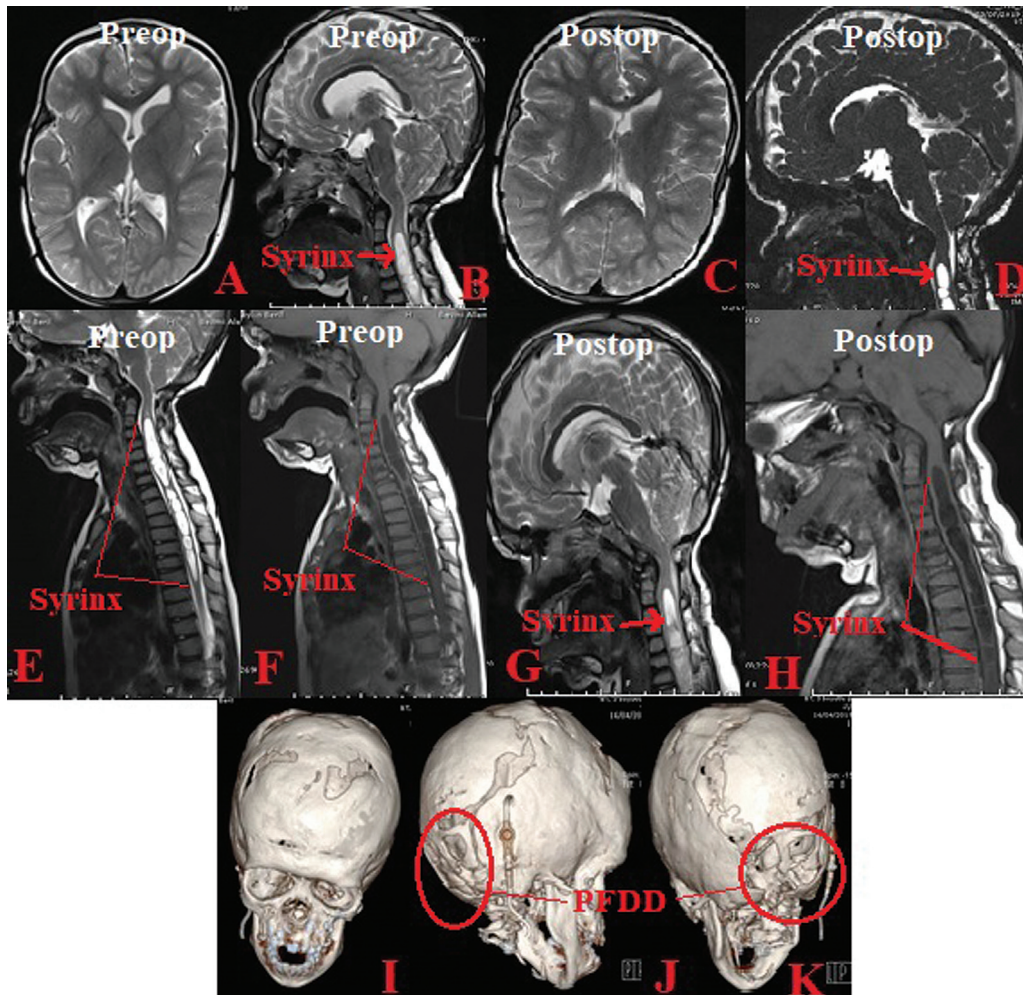
occipital craniotomy was performed to widen the posterior portion of the skull. Four years thereafter, she was operated on with posterior fossa decompression and duraplasty for Chiari malformation-induced syringomyelia at aged 6 years. She was followed with MRI periodically (►Fig. 7). Over the 10-year follow-up period, the ventriculoperitoneal shunt was revised twice.

#### Case 7

A 1-year-old girl was referred to us with head malformation and was diagnosed with Crouzon syndrome. The diagnosis of bicoronal synostosis (brachycephaly) was confirmed with scanning (3D-CT and MRI) images. The FOA procedure was performed (►Fig. 8).

## Discussion

In the current study, the authors reported a personal experience of their surgically treated craniosynostosis in <3-year-old children. The optimal operative procedure depended on the skull shape, early closed sutures, age at diagnosis, genetic diagnosis, the child's weight, and the surgeon's familiarity. The protocol was adopted for syndromic children or children with a high ICP to operate them early before their 3 months of age. Although early surgical intervention in such children



**Fig. 7** The same child described in ►Fig.6. The child received posterior fossa decompression with duraplasty (PFDD) for Chiari malformation-induced syringomyelia at 6 years of age. The preoperative T2WIs axial (A) and sagittal (B) images. The postoperative axial T2WI (C) and sagittal contrast-phase (D) images. The preoperative craniospinal T2WI (E) and T1WI (F) images. The postoperative craniospinal T2WI (G) and T1WI (H) images. The 2-year postoperative 3D-CT anterior (I), posterior lateral (J), and posterior (K) images at her 8 years of age. 3D-CT, three-dimensional computed tomography.

may associate with a high morbidity and mortality rate, early surgical intervention reduces irreversible complications and delayed development related to ICP and bony compression on the brain. For other craniosynostosis children, the surgeons wait till the children gain good weight. To reduce a possible complication due to abundant bleeding, physiological stress, and anesthesia induction, our team generally prefers to operate on children after having a weight of 10 kg. However, the mean age of this series at surgery (12.6 months) was higher than the literature value, due to particularly reluctant families and sometimes due to the delayed consultations from other departments, particularly genetic consultation.

One of the much-debatable points in craniosynostosis management is the timing of surgical intervention. It depends on the child's status, weight, the presence of the syndrome, the family's desire, the surgical approach, and presenting symptoms. For syndromic children, the immediate operation was recommended as soon as the family is ready for surgical intervention (within the first 2–3 months of life). For nonsyndromic children, surgical intervention

was recommended after the first 3 months of life (within the 4–6 months of age). The authors believe this is a better time to compensate for the physiologic stress of anesthesia induction and bleeding. In such children, all consultations and genetic analyses were completed before surgical intervention. In the literature, early surgery is defined as <1 year of age. Late surgery is defined as >1 year of age.<sup>1–4</sup> For endoscopic repair, intervention within the first 3 to 4 months of age is required. The majority of surgeons operate on at 3 to 12 months of life.<sup>1–4</sup> Early surgical intervention allows adequate brain growth on head shape and easily reshaped bone stock. It prevents further secondary craniofacial changes' progression. Several studies demonstrated that early intervened children have a high spontaneous tendency to ossify and cover any calvarial malformations.<sup>1–4</sup> However, some authors believe that late intervention may reduce the required revision in the early intervention cases.<sup>2,4</sup>

Several factors affected the timing of surgical intervention, such as the family's fear, the completeness of the consultations (pediatric, genetic, and others), child's status, weight, hematocrit value, the presence of any infection,



**Table 2** Demographic and clinical characteristics of 54 patients

Variables	The number of pts (%)
Number of pts	54 (100%)
Sex (F/M)	22/32 (40.7%)
Mean age	12.6 ± 7.1 (2–31) mo
Types	
Nonsyndromic	46 (85.2%)
Syndromic	8 (14.8%)
Apert syndrome	4 (7.4%)
Pfeiffer syndrome	2 (3.7%)
Crouzon syndrome	2 (3.7%)
Presenting symptoms	
Misshapen skull	49 (90.7%)
Increased irritability	43 (79.6%)
Sleepiness	36 (66.7%)
Projectile vomiting	32 (59.3%)
High-pitched crying	29 (53.7%)
Poor feeding	27 (51.9%)
Small skull	23 (42.6%)
Developmental delay	20 (37.0%)
Seizure	17 (31.4%)
Behavior changes	13 (24.1%)
Early anterior fontanel closure	11 (20.4%)
Clinical findings	
Malformed head	49 (90.7%)
Less alert than usual	36 (66.7%)
Disappeared/bulging fontanel	31 (57.4%)
Bulging eyes	29 (53.7%)
Inability to look upward with the head facing toward	24 (44.4%)
Failure to thrive	21 (38.9%)
Decreased head circumference	20 (37.0%)
Increased head circumference	13 (24.1%)
Sensorineural deficits	7 (13.0%)
Noticeable scalp veins	5 (9.2%)
Affected sutures	
Bicoronal	20 (37.0%)
Sagittal	14 (26.0%)
Metopic	12 (22.2%)
Unicoronal	5 (9.2%)
Multiple sutures	2 (3.7%)
Bilateral lambdoid	1 (1.9%)
Symptom duration (mo)	8.9 ± 5.4 (1–22)
Follow-up period (mo)	59.6 ± 41.2 (2–133)

**Table 2** (Continued)

Variables	The number of pts (%)
Mean operative time (minutes)	180.5 ± 66.2 (115.0–265.0)
Mean LOS (d)	3.9 ± 1.4 (3–8)
Mean PICU-LOS (d)	1.4 ± 1.1 (1–5)
Mean total estimated IP blood loss (ccs)	278.8 ± 130.8 (90–420)
Mean total transfused blood (ccs)	210.2 ± 50.8 (130–340)

Abbreviations: F, female; IP, intraoperative; LOS, length of hospital stay; M, male; PICU, pediatric intensive care unit; pts, patients.

**Table 3** Surgical complications

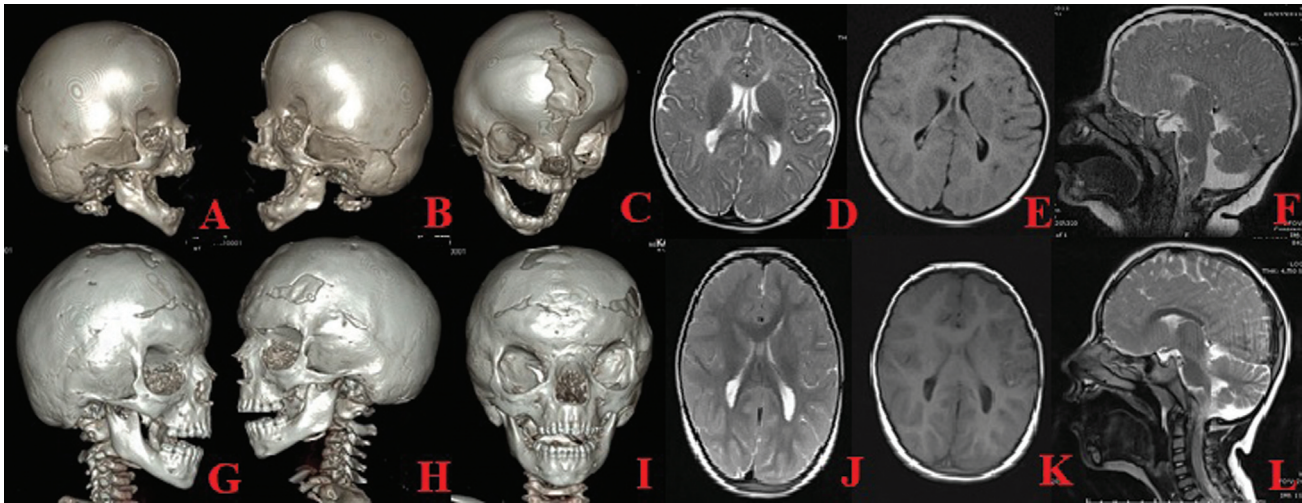
Complication	The number of pts (%)
Reoperation	2 (3.7%)
Died—cardiac arrest	1 (1.9%)
Seizure on his third postoperative month	1 (1.9%)
Dural tear	1 (1.9%)
Delayed surgical closure <sup>a</sup>	1 (1.9%)
Paracetamol toxicity <sup>a</sup>	1 (1.9%)

Abbreviation: pts, patients

<sup>a</sup>These both complications were seen in the same child.

associated health problems,<sup>1–7</sup> and the hospital issues such as PICU and operating room programs.

In surgical intervention, surgeons aimed to release sutures, decompress brain parenchymal, give simultaneous cranial vault, and reshape the cranial skeleton using osteotomies. Thus, the intracranial volume is increased and an acceptable head shape is achieved. In the surgical intervention for craniosynostosis, the coronal incision is a versatile option to access the cranial vault and upper part of the facial skeleton with several modifications, such as linear, sinusoidal, saw-tooth, or zig-zag.<sup>8</sup> The linear one was accused of the noticeable scar, and for that reason, Munro and Fearon presented a zig-zag incision known as stealth incision.<sup>9</sup> It was reported that the symmetrical design of this incision was impossible. Using templates has been recommended to make this zig-zag incision easier.<sup>8,10</sup> However, the difficulty in bending the steel wire was reported as a disadvantage; therefore, individual prebend templates could be made based on the surgeon's preference.<sup>10</sup> Fox and Tatum used a tape measure as a flexible template.<sup>8</sup> Although they reported that the height and width of the legs of the zig-zag incision could be modified individually, they did not discuss the reliability and reason for modifications in designing the zig-zag incision. Kim et al's study has presented V-Y advancement flaps in cranioplasties of pediatric patients.<sup>11</sup> The use of the V-Y pattern in the craniofacial skin is a reasonably safe



**Fig 8** A 1-year-old girl was referred to us due to head deformity. She was treated using the FOA procedure. (A–C) The preoperative 3D-CT right lateral (A), left lateral (B), and anterior (C) images. (D–F) The preoperative axial T2WI (D), axial T1WI (E), and sagittal T2-W1 (F) images. (G–I) The 2-year postoperative 3D-CT right lateral (G), left lateral (H), and anterior (I) images. (J–L) The 2-year postoperative MRI axial T2WI (J), axial T1WI (K), and sagittal T2-W1 (L) images. 3D-CT, three-dimensional computed tomography; FOA, fronto-orbital advancement.

option due to the profuse perfusion. The incision may be designed with a length-to-width ratio of up to 3:1.<sup>11</sup> In this series, the surgeons performed a zig-zag incision in all surgeries.

Craniosynostosis is one of the main challenges encountered during pediatric neurosurgical and plastic surgeries. Several approaches were recently described as alternative approaches to the OCVR procedure. Distraction osteogenesis, spring-mediated cranioplasty, and endoscopic suturectomy are increasingly performed using minimally invasive techniques as alternatives to classic OCVR.<sup>1</sup> The advantages of these minimally invasive techniques are lower rates of intraoperative bleeding, operative duration, blood transfusion requirement, morbidity, and mortality compared with OCVR techniques. A prospective study, which investigated endoscopic strip craniectomies in 100 children, reported a lower operative duration and intraoperative estimated bleeding with means of 52.7 minutes and 26.2 mL, respectively. It also mentioned no complications and a discharge rate of 97.0% on the first postoperative day.<sup>12</sup> Morrison et al analyzed data of 81 craniosynostosis patients with a mean age of 13.8 years.<sup>1</sup> The study pooled both children and adults in the same cohort and reported that the most affected sutures were unicoronal, which was observed in 28 (34.6%) patients, followed by metopic, sagittal, multiple, bicoronal, and lambdoid, which were observed in 24 (29.6%), 11 (13.6%), 9 (11.1%), 7 (8.6%), and 2 (2.5%) patients, respectively. Although our cohort included pediatric patients only and is not comparable with Morrison et al's study, the most affected sutures in our series were bicoronal, followed by sagittal, metopic, unicoronal, multiple, and bilateral lambdoid synostosis.<sup>1</sup> Previously published series have shown different ordinaries regarding the most affected sutures.<sup>1–6</sup> The most common type of craniosynostosis was sagittal synostosis (scaphocephaly), followed by coronal synostosis.<sup>2–6</sup> In the bicoronal synostosis (brachycephaly) cases, the coronal sutures on both sides of the child's head

close too early. Thus, the child's head will grow broad and short.<sup>3,4,6</sup> Pogliani et al reported 16 (57.1%) sagittal and 8 (28.6%) metopic synostoses among the true craniosynostosis group, who were first diagnosed with the USG.<sup>5</sup> Sloan et al reported 107 (42.8%) sagittal, 30 (12.0%) multiple suture, 30 (12.0%) unilateral lambdoid, and 28 (11.2%) unilateral coronal synostosis cases.<sup>2</sup> This ordinary was different from ours. It is believed this is related to the small number of syndromic and complicated children in our series. Most of such cases were children with sagittal synostosis and were treated by both neurosurgical and plastic teams. This study analyzed the children who were treated by a neurosurgeon team.

In this series, except for three shunt-induced cases, all children were with primary craniosynostosis. Secondary craniosynostosis (SCS) patients are those caused by other causes than genetic origin craniosynostosis. SCS results from metabolic, drug-related, hematologic diseases. Rarely, SCS had been reported in hydrocephalus children following shunt treatment due to over-drainage (shunt-induced) craniosynostosis. Pediatricians have to be aware of the possible association of metabolic diseases (such as rickets,<sup>13</sup> thyroid dysfunction-related,<sup>14</sup> osteopetrosis, and lysosomal storage disease) or hematologic disorders and craniosynostosis.<sup>13,14</sup> Children with these diseases should be carefully assessed and followed up for the association with craniosynostosis. To reduce the possible development of SCS, children shunted for myelomeningocele-related hydrocephalus also required assessment periodically.<sup>15</sup> SCS has to be distinguished from microcephaly. Microcephaly is a specific situation that is resulting from early sutures closure associated with failure of brain growth. In the microcephaly children, no surgical intervention was indicated. In this series, the SCS rate was 5.6%, which is consistent with the literature value.

Two major evaluation methods had been defined through the literature; one to evaluate cosmetic outcomes<sup>2</sup> and another to evaluate craniometric, volumetric, and morphologic outcomes.<sup>16</sup> The latter method requires postoperative



3D-CTs. In pediatric practice, we ought to avoid performing 3D-CTs except for complicated cases. During the follow-up period, we performed only 14 3D-CTs in nine treated children. Therefore, we used the first method with a mild modification. Our first two categories are good outcomes, the third and the fourth categories are required reoperation, and the fifth category was the worst outcome, indicating the complications resulting in death. Our outcomes were acceptable and better than those reported by Sloan et al, who reported 73 of 115 (63.5%) children with good outcomes, 28 (24.3%) with compromised outcomes requiring reoperation, and 14 (12.2%) with bad outcomes requiring reoperation.<sup>2</sup> They reported two deaths also. These satisfactory outcomes were believed that be related to developments and advances in surgical techniques and tools such as microscopes, mini-screws, and plates.

The literature review was conducted to compare our findings with long-term studies reporting OCVR. Sloan et al reported lower mortality, complication, and reoperation rates of 0.8, 6.8, and 7.2% in their large cohort that comprised 250 consecutive children.<sup>2</sup> Pearson et al's study reported the long-term surgical outcomes of OCVR in 314 patients with craniosynostosis.<sup>17</sup> They observed a higher reoperation rate of up to 36% over >20 years. The same study reported a complication rate of 3.3% without any deaths.<sup>17</sup> Another retrospective study reported similar complication and mortality rates with a lower reoperation rate of 10.5% in 140 classic OCVR and 72 primary extended synostectomies for >12 years.<sup>18</sup> One study reported a reoperation rate of 13.0% in 104 patients with isolated craniosynostosis.<sup>19</sup> The authors in the same study reported no deaths and a complication rate of 12.5% (5.0% perioperative and 7.7% follow-up) over >20 years with a follow-up period of 46 months.<sup>19</sup> The same authors in another study investigated a total of 76 patients with syndromic craniosynostosis. Over a 6-year follow-up period, they found higher reoperation and complication rates of 36.8 and 56% (11.3% perioperative and 44.7% follow-up), respectively.<sup>20</sup> In this series, there was no significant difference between syndromic and nonsyndromic children regarding complications, morbidity, mortality, or reoperation rates. However, the number of syndromic children in our study was relatively small and noncomparative with previously published large-sampled studies.

Bruegem et al followed up 92 patients with nonsyndromic craniosynostosis for >10 years. They observed perioperative mortality and postoperative infection rates of 1.1 and 3.5%, respectively.<sup>21</sup> A recently published study reported a lower complication rate of 1.2% without intraoperative complications or deaths.<sup>1</sup> Seruya et al reported the mean LOS, surgical period, and estimated intraoperative bleeding loss of 3.4 days, 205 minutes, and 33.4%, respectively.<sup>18</sup> Fearon et al reported no deaths and a shorter LOS with a mean of 2.5 days and lower complication and reoperation rates of 0.4 and 2.0%, respectively.<sup>22</sup> Another study also revealed a higher complication rate in 268 patients with craniosynostosis who underwent 306 surgical interventions. It reported the following complications: postoperative hyperthermia, subcutaneous hematoma, infection, dural tears, and CSF leakage occurring

in 13.17, 6.08, 8.1, 5.06, and 2.7% of patients, respectively.<sup>23</sup> The findings of this series were consistent with the literature. In this series, reoperation, mortality, and complication rates were 3.7, 1.9, and 9.3%, respectively. The mean surgical period, estimated intraoperative blood loss, blood transfusion volume, PICU duration, and LOS were 180.5 minute, 278.8 ccs, 210.2 ccs, 1.4 days, and 3.9 days, respectively.

The authors believe that a modified prone position is more appropriate for posterior synostoses. This position provides exposure from the midorbital line at the front to the foramen magnum at the back. The bicoronal zig-zag incision made behind the auricle is the preferred incision. This approach reduces the scar tissue and loss of surgeon orientation when reshaping in the rarest craniosynostosis type of this series.

This retrospective study suffers from a few limitations: (1) the retrospective nature of the study, (2) the small sample size to investigate subgroups, (3) the single neurosurgical team experience, and (4) the outcomes were not evaluated with craniometric and volumetric variables. In our institutes, the complicated craniosynostosis cases were referred to the plastic and reconstructive team. Therefore, the syndromic/nonsyndromic children ratio was relatively small. The complicated syndromic children require an expert plastic and reconstructive team that includes a maxillofacial surgeon. When compared with our cases, surgical approaches, LOS, complications, and follow-up are different in such cases. A longer follow-up period with a larger sample size is required to support these long-term results.

## Conclusion

These findings demonstrated that the OCVR approach is an efficient surgical method to get good outcomes. Satisfactory results with an acceptable complication rate can be obtained with expert hands. Further studies are warranted to support these findings.

### Author Contributions

Conception or design of the work: Anas Abdallah and Meliha Gündag Papaker; data collection: Meliha Gündag Papaker and Anas Abdallah; data analysis and interpretation: Anas Abdallah and Meliha Gündag Papaker; drafting the article: Anas Abdallah; critical revision of the article: Anas Abdallah, Meliha Gündag Papaker, and Gökhan Baloğlu; other (study supervision, fundings, materials, validation, etc.): Gökhan Baloğlu, Meliha Gündag Papaker, and Anas Abdallah.

All authors (Anas Abdallah, Meliha Gündag Papaker, and Gökhan Baloğlu) reviewed the results and approved the final version of the manuscript.

### Conflict of Interest

None declared.

### Acknowledgments

Permission has been obtained from the patient's parents for the presentation.

## References

- 1 Morrison KA, Lee JC, Souweidane MM, Feldstein NA, Ascherman JA. Twenty-year outcome experience with open craniosynostosis repairs: an analysis of reoperation and complication rates. *Ann Plast Surg* 2018;80(4, Suppl 4):S158–S163
- 2 Sloan GM, Wells KC, Raffel C, McComb JG. Surgical treatment of craniosynostosis: outcome analysis of 250 consecutive patients. *Pediatrics* 1997;100(01):E2
- 3 Garza RM, Khosla RK. Nonsyndromic craniosynostosis. *Semin Plast Surg* 2012;26(02):53–63
- 4 Sakamoto H, Matsusaka Y, Kunihiro N, Imai K. Physiological changes and clinical implications of syndromic craniosynostosis. *J Korean Neurosurg Soc* 2016;59(03):204–213
- 5 Pogliani L, Zuccotti GV, Furlanetto M, et al. Cranial ultrasound is a reliable first step imaging in children with suspected craniosynostosis. *Childs Nerv Syst* 2017;33(09):1545–1552
- 6 Shimoji T, Kimura T, Shimoji K, Miyajima M. The metopic-sagittal craniosynostosis-report of 35 operative cases. *Childs Nerv Syst* 2017;33(08):1335–1348
- 7 Taylor WJ, Hayward RD, Lasjaunias P, et al. Enigma of raised intracranial pressure in patients with complex craniosynostosis: the role of abnormal intracranial venous drainage. *J Neurosurg* 2001;94(03):377–385
- 8 Fox AJ, Tatum SA. The coronal incision: sinusoidal, sawtooth, and postauricular techniques. *Arch Facial Plast Surg* 2003;5(03):259–262
- 9 Munro IR, Fearon JA. The coronal incision revisited. *Plast Reconstr Surg* 1994;93(01):185–187
- 10 Fisher DM, Goldman BE, Mlakar JM. Template for a zigzag coronal incision. *Plast Reconstr Surg* 1995;95(03):614–615
- 11 Kim SW, Yun BM, Song JK, Kim SK, Wang KC. V-Y advancement flaps for scalp closure after acute cranial volume expansion. *Ann Plast Surg* 2011;66(03):249–252
- 12 Jimenez DF, Barone CM, Cartwright CC, Baker L. Early management of craniosynostosis using endoscopic-assisted strip craniectomies and cranial orthotic molding therapy. *Pediatrics* 2002;110(1, Pt 1):97–104
- 13 Jaszczuk P, Rogers GF, Guzman R, Proctor MR. X-linked hypophosphatemic rickets and sagittal craniosynostosis: three patients requiring operative cranial expansion: case series and literature review. *Childs Nerv Syst* 2016;32(05):887–891
- 14 Carmichael SL, Ma C, Rasmussen SA, et al. Craniosynostosis and risk factors related to thyroid dysfunction. *Am J Med Genet A* 2015;167A(04):701–707
- 15 Park DH, Chung J, Yoon SH. The role of distraction osteogenesis in children with secondary craniosynostosis after shunt operation in early infancy. *Pediatr Neurosurg* 2009;45(06):437–445
- 16 Fawzy HH, Choi JW, Ra YS. One-piece fronto-orbital distraction with midline splitting but without bandeau for metopic craniosynostosis: craniometric, volumetric, and morphologic evaluation. *Ann Plast Surg* 2019;83(03):285–292
- 17 Pearson GD, Havlik RJ, Eppley B, Nykiel M, Sadove AM. Craniosynostosis: a single institution's outcome assessment from surgical reconstruction. *J Craniofac Surg* 2008;19(01):65–71
- 18 Seruya M, Oh AK, Boyajian MJ, et al. Long-term outcomes of primary craniofacial reconstruction for craniosynostosis: a 12-year experience. *Plast Reconstr Surg* 2011;127(06):2397–2406
- 19 McCarthy JG, Glasberg SB, Cutting CB, et al. Twenty-year experience with early surgery for craniosynostosis: I. Isolated craniofacial synostosis—results and unsolved problems. *Plast Reconstr Surg* 1995;96(02):272–283
- 20 McCarthy JG, Glasberg SB, Cutting CB, et al. Twenty-year experience with early surgery for craniosynostosis: II. The craniofacial synostosis syndromes and pansynostosis—results and unsolved problems. *Plast Reconstr Surg* 1995;96(02):284–295, discussion 296–298
- 21 Breugem CC, van R Zeeman BJ. Retrospective study of nonsyndromic craniosynostosis treated over a 10-year period. *J Craniofac Surg* 1999;10(02):140–143
- 22 Fearon JA, Ruotolo RA, Kolar JC. Single sutural craniosynostoses: surgical outcomes and long-term growth. *Plast Reconstr Surg* 2009;123(02):635–642
- 23 Esparza J, Hinojosa J. Complications in the surgical treatment of craniosynostosis and craniofacial syndromes: apropos of 306 transcranial procedures. *Childs Nerv Syst* 2008;24(12):1421–1430