



Acceptance of Endoscopes in Otology – An Indian Perspective and Review of the Literature

Raman Sharma¹ Ravi Meher¹ Vikram Wadhwa¹ Sanjay Vikram Soni¹

¹Department of ENT and Head and Neck Surgery, Lok Nayak Hospital, Maulana Azad Medical College, New Delhi, India

Address for correspondence Raman Sharma, MS ENT, Department of ENT and Head and Neck Surgery, BL Taneja Block, Maulana Azad Medical College, New Delhi, India (e-mail: raman.96sharma@gmail.com).

Int Arch Otorhinolaryngol 2023;27(4):e713–e722.

Abstract

Introduction The role of endoscopes in the ear, nose, and throat (ENT) field has been described since the 1980s; It started with endoscopic nasal surgeries, followed by otological and laryngological procedures, and, since then, it has experienced a rapid evolution. Endoscopes help otologists understand how to approach difficult areas of middle ear, as well as the physiology of middle ear cleft.

Objectives Despite the introduction of endoscopes in the field of otology, microscopes are still widely used in clinics and in operation theaters either alone or with endoscopes. The present study, which was conducted amongst otologists in India, is on their experience with and knowledge of the use of the endoscope compared to microscopes.

Methods A Google form-based questionnaire comprising 18 questions was developed and sent online to otologist all over the country. The final dataset included responses from 354 active otologists.

Results Out of 354 participants, only 3% had more than 5 years of experience in endoscopic ear surgery (EES), and 16.1% had never worked with an endoscope. Endoscopes were used in clinics and in operation theaters by 74.9% of the participants.

Conclusion There has been a rise in the acceptance and use of endoscopes among Indian otologists and otology surgeons in last few decades.

Keywords

- ▶ endoscope
- ▶ otology
- ▶ ear surgery
- ▶ microscopes

Introduction

The last century witnessed a rapid advancement in otology surgery, especially over the past few decades, which was helped by the refinement in optics and lighting of microscopes. However, despite these advancement in microscopy, visualization of the deeper recesses of middle ear was still limited. The advent of the use of endoscopes in ear surgeries occurred in the 1980s, but it took time until endoscopes became widely accepted. Nonetheless, the recent development of various endoscopic surgical instruments coupled with high resolution cameras has resulted in a growing interest in otoendoscopy.

Therefore, the present study was conducted to assess the level of knowledge and use of endoscopes among otology surgeons in different parts of India. We have also made a comparison of their experience with the use of endoscopes and microscopes, alone or combined, in otological procedures.

Materials and Methods

We designed a questionnaire which was uploaded to a Google form. It contained 18 main questions (**Annex 1**) aimed at characterizing the experience of surgeons, the use of endoscopes in ear surgery, and the perceived advantages of

received
July 30, 2022
accepted after revision
September 14, 2022
article published online
March 29, 2023

DOI <https://doi.org/10.1055/s-0042-1759577>.
ISSN 1809-9777.

© 2023. Fundação Otorrinolaringologia. All rights reserved.
This is an open access article published by Thieme under the terms of the Creative Commons Attribution-NonDerivative-NonCommercial-License, permitting copying and reproduction so long as the original work is given appropriate credit. Contents may not be used for commercial purposes, or adapted, remixed, transformed or built upon. (<https://creativecommons.org/licenses/by-nc-nd/4.0/>)
Thieme Revinter Publicações Ltda., Rua do Matoso 170, Rio de Janeiro, RJ, CEP 20270-135, Brazil

Which the following best describes your current level of speciality training

354 responses

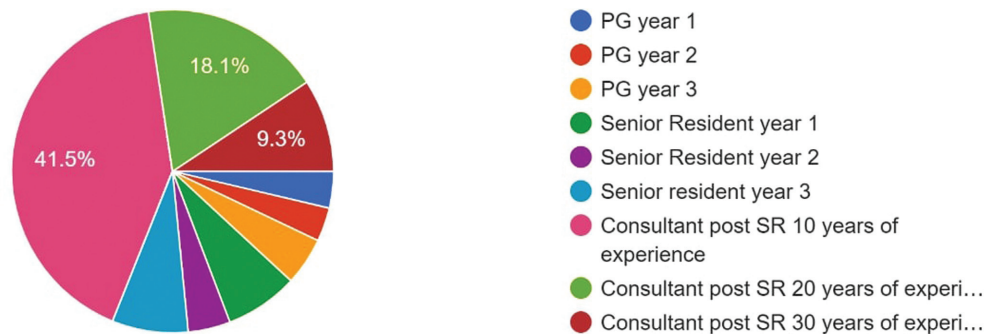


Fig. 1 Graph showing the participants' experience in the field of otology.

and concerns with endoscopic ear surgery (EES) techniques, as well as their preference for endoscopes over microscopic or vice versa based on their experience. After taking consent from the otologists and obtaining the approval of the institutional Ethics Committee (under no. MAMC/70/05/2022/No. 431), the questionnaire was administered through a link sent via email and WhatsApp to various otologists. The final dataset included the answers of 354 professionals from different parts of India, including ear, nose, and throat (ENT) surgeons, and experienced and novice otologists. The clinicians included were all performing ear surgery in their practices, and they were identified through ENT groups on social media.

Results

The study included 354 practitioners who shared their experience and opinions on the use of endoscopes in the field of otology. In total, 147 (41%) participants had become

consultants 10 years after their residency, 64 (18.1%), after 20 years, and 33 (9.3%), after 30 years (► **Fig. 1**). The remaining participants were senior residents and junior residents in different years of their training. Ear surgery was performed by 343 (97%) of the participants, but most of them had less than 5 years of experience in EES. The remaining 11 participants (3%) include junior residents in their initial period of postgraduate training. Almost 90% of the respondents believe that the endoscope has a role to play in ear surgeries (► **Fig. 2**). Endoscopes are used in the clinics and operation theaters (OTs) by 74.9% of the participants, commonly in outpatient procedures, such as like examination under microscope (endoscope), cauterization, suction-clearance, intratympanic injections, grommet insertion, and in surgeries like myringoplasty, ossiculoplasty, stapedotomy, skull base surgeries, and cochlear implantation (► **Fig. 3**). A total of 16.1% (57) of the participants, mostly first-year residents, had never performed EES or any endoscopic ear procedure. Endoscopes are widely used in cholesteatoma patients to

Do you feel there is a role of endoscope in otology surgery?

354 responses

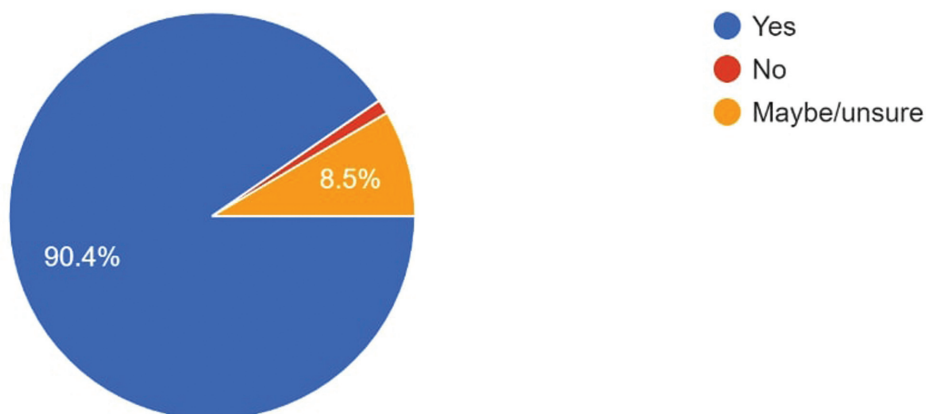


Fig. 2 Graph showing the surgeon's view of the role of the endoscope in otology.

How do you use endoscopes in your otology practice?

354 responses

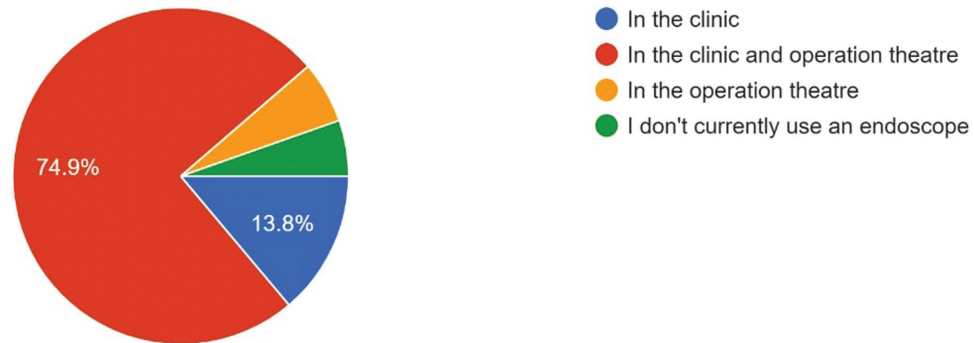


Fig. 3 Graph showing various uses of endoscopes in the clinical practice of otologists.

look for residual disease in areas that are difficult to reach, but, in the present study, 42.9% of the surgeons stated that endoscopes do not have a role in cholesteatoma clearance in ear surgery, and the remaining surgeons use endoscopes either at the beginning or the end of mastoid surgeries, in combination with microscopes (►Fig. 4). In the present study 42% of the surgeons said that there is less need for revision surgery in such cases in comparison to surgeries performed only with the aid of the microscope (►Fig. 5). According to the respondents, the main advantages of EES are the access to areas that are hard to reach, safety, early recovery, and cosmesis, and the common complications observed are injuries to the external auditory canal (EAC, with a rate of 39.3%), the tympanic membrane (TM; rate: 11.3%), and the facial nerve and chorda tympani. Endoscopes of various diameters and angulations have been used, but most surgeons (63%) prefer the 4-mm 0° straight forward HOPKINS telescope (KARL STORZ SE & Co. KG, Tuttlingen, Germany). The fact that EES is a one-handed surgery was the most common challenge mentioned by the otology surgeons (83.6%); other challenges reported were loss of depth per-

ception, fogging of the tip, obstruction in the work space, and issues with drilling (►Fig 6). The learning curve in EES is long and 45% of the participants believe it to be harder compared to microscopes. Almost 83% of the participants believe there should be specific training to use endoscopes, as well as measures to introduce or encourage their use.

Review of the Literature

Introduction of Endoscopes in Otology

In the 1950s, binocular microscopy revolutionized the field of medicine. In 1954, Hopkins and Kapany¹ first introduced what they termed *fibrescope*, and, in 1967, Mer et al.² used the endoscopes to examine the middle ear. Initially, endoscopes were used in the ear predominately as an adjunct to microscopes for diagnostic purposes.^{3,4} Better lighting, image clarity, and wide-angle view provided by endoscopes helped visualize the middle ear cavity via the transmastoid or transtympanic routes. In the 1990s, as an extension of these anatomic studies, researchers⁵ assessed the use of endoscopes as observational tools in cholesteatoma procedures to evaluate residual or

Please select the category which most appropriately describes your use of endoscope in cholesteatoma surgery. If you do not use the endos...teatoma surgery, please select "Not applicable"..!

354 responses

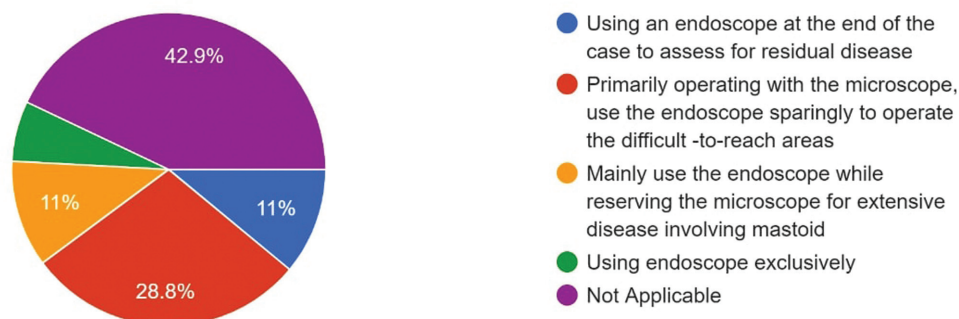


Fig. 4 Graph depicting the otologist's perception of the role of the endoscope in cholesteatoma surgery.

In your experience how much was the need of revision surgery in cases performed by endoscopes alone in comparison to microscopic ear surgeries.

354 responses

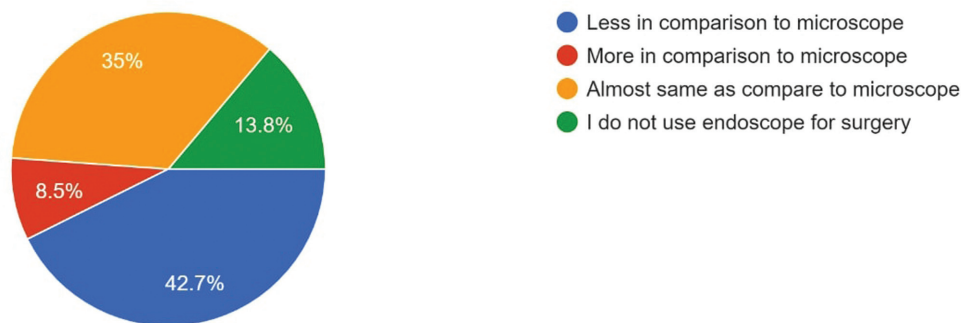


Fig. 5 Graph showing the need for revision in endoscopic surgery versus microscopic ear surgery.

What in your opinion are the challenges faced when switching from microscope to endoscope in ear surgeries.?

354 responses

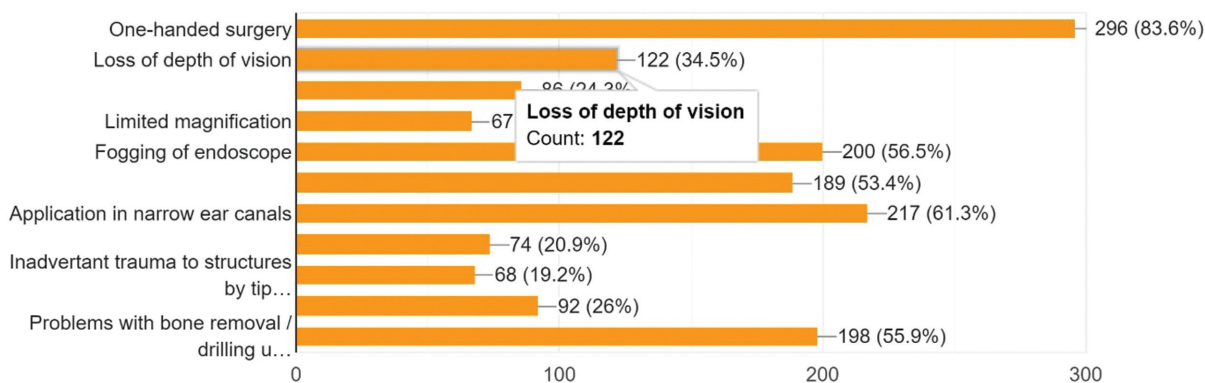


Fig. 6 Graph depicting the different challenges faced by surgeon's during endoscopic ear surgeries.

recurrent disease, particularly after canal wall up (CWU) procedures. Endoscopes were then used to examine the mastoid cavities a few months after surgery, mainly in CWU procedures as well, to look for any residual disease, which is known as *second look surgery* or *transcutaneous mastoidoscopy*.^{5,6} Later, flexible endoscopes with smaller diameters were employed to understand the normal anatomy and physiology of the eustachian tube (ET), and video endoscopy enabled a meticulous analysis of the tubal dilation process.^{7,8} In 1999, Klug et al.⁹ used the ET as a portal for the endoscope to describe the anatomy of the middle ear, and surgeons¹⁰ started performing endoscopic ET procedures such as balloon tuboplasty and laser eustachian tuboplasty.

Better Understanding of the Middle Ear Anatomy

The better understanding of the anatomy of middle ear with the advent of endoscopes made the surgery of mastoid less invasive and more physiological.¹¹ Otoendoscopy is the best way to explore and understand all the areas of the middle ear, especially the ventilation pathways to

restore ventilation, which is the main purpose of mastoid surgeries. Through endoscopy, Marchioni et al.¹¹ described in detail the anatomy of the middle ear, specifically the retrotympanic and epitympanic spaces.

Endoscopes – A Teaching Tool

A randomized study with the application of a questionnaire was conducted by Anschuetz et al.¹² to compare the suitability of using microscope- and endoscope-based methods to teach the anatomy of the middle ear. The authors¹² concluded that the endoscopic approach was associated with an improved gain in knowledge compared to the microscopic approach, and they stated that the participants subjectively preferred the endoscope for educational purposes.

Bowdler and Walsh¹³ compared the accessibility of various middle ear subsites using rigid otoendoscopes with angles of view of 0° and 70° and 4.0mm and 2.7mm in diameter respectively, and operative microscopes. In CWU procedures, 0° endoscopes provided

good visualization of the sinus tympani, facial recess, protympanum, attic, as well as for posterior tympanotomy, while 70° endoscopes are better for the sinus tympani and ET. Karhuketu¹⁴ reported similar advantages with endoscopes of angle of view of 0°, 30° and 90° (1.7 mm diameter). Otoendoscopy is often limited by the curvature of the EAC. Mackeith et al.¹⁵ conducted a study on the thermal properties of the endoscope in otology surgeries and found that the maximum recorded temperature was of 104.6°C at the tip of a 0° endoscope with 4 mm in diameter and 18 cm in length. The smallest recorded temperature rise was for the 30° endoscope with 3 mm in diameter, 11 cm in length, whose tip reached only 33.0° C. However, interestingly, the 70° endoscopes produced significantly more heat than the 30° endoscopes of the same diameter.

Microscopes Versus Endoscopes in Otology

Although modern microscopes provide excellent views of the surgical field, their role in the visualization of the deeper recesses of the middle ear is limited. These limitations (which are overcome with the use of endoscopes) include inadequate amount of light reaching the surgical plane, and the need to drill bone and/or retract soft tissue to adequately visualize or access the different areas. Transcanal EES (TEES) uses the EAC as a minimally-invasive surgical portal to access the middle (and inner) ear disease. When introduced in the 1960s, endoscopes had poor image resolution in comparison to the operative microscope, which limited its application.² But, with the introduction of high-definition (HD) video systems, endoscopes now provide ultra-high-resolution images of the middle ear, which has expanded their application in the field of otology.

At the Massachusetts Eye and Ear Infirmary, Cohen et al.¹⁶ introduced a system to classify the use of endoscopes during otologic surgery. **Class 1** pertains to the use of endoscopy for inspection without dissection; **class 2** involves the combined use of the endoscope and the microscope, and it is subdivided into classes 2a and 2b, in which the endoscope is used for less than 50% of the dissection and more than 50% of the dissection respectively; and **class 3** pertains to the use of the endoscope for the entire surgery.

Advantages of ESS

The many advantages of the EES, which have led to its increased preference, include:¹⁷⁻²⁰

1. A wide angle of view: the endoscopic view usually includes the whole tympanic ring and ear canal at the same time. This provides a complete view of the middle ear space, tympanic membrane, and ear canal without the need to continuously repositioning the patient's head, as in microscopic ear surgery (MES) (→ Fig 7A,B)
2. The endoscope provides better visualization of structures that are lateral to the viewing axis of the microscope. It is usually necessary to position these structures at a right angle to the axis of the microscope for adequate visualization, which is difficult to impose in certain situations. Due to the dynamic range of

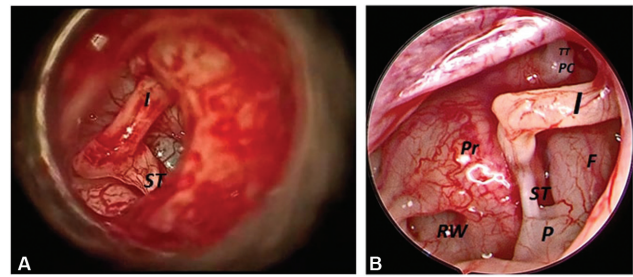


Fig. 7 (A) Microscopic view of middle ear on the left side. (b) Endoscopic view of the left ear after elevation of the tympanomeatal flap.

(Note: the wide-angle view obtained with the endoscope as compared to the microscopic view. Abbreviations: F, facial nerve; P, pyramid; PC, processus cochleariformis; Pr, promontory; RW, round window; ST, stapedial tendon; TT, tensor tympani tendon.)

endoscope movement, if required, the 30° scope and the wide-angle 0° scope provide excellent visualization of hidden structures and possible injuries to them, such as anterior tympanic membrane perforation, and the retrotympanum, attic and hypotympanum. This is also possible through a transcanal approach, even when using the 0°, because of the wide-angle view of the more recent endoscopes.

3. The ability to visualize past the shaft of larger surgical instruments such as drills. The handle of the instruments may obscure the visualization of structures in MES.
4. It is a great teaching tool.
5. The anatomical variations (tortuous or stenotic ear canal, anterior meatal overhang etc.) that hamper the view of the entire tympanic membrane during ear surgery can be overcome by the use of endoscopes.
6. Endoscopes enable close inspection and photodocumentation of the tympanic membrane perforation, the drum remnant, the ET orifice, the middle ear mucosa, and the ossicular chain without elevation of tympanomeatal flap.
7. Moreover, the perimeatal route renders postaural incision unnecessary, resulting in a shorter operative time and lower rates of postoperative pain and morbidity, when performed by experienced hands.

Disadvantages of ESS¹⁹⁻²¹

1. The loss of depth perception and binocular vision, which are easily compensated for with experience, are a disadvantage of ESS. Even though newer endoscopes might provide depth perception, this issue is more related to the currently available scopes.
2. The one-handed surgical technique: since one hand is holding the scope, bleeding will be a concern when proceeding with the next steps of surgery. It is always better to address the bleeding points at the beginning to make the subsequent surgical steps easier.
3. The need for surgeon training: acquiring the necessary skills should not be too difficult for the experienced nasal endoscopist, but it might be hard for established otologists who lack endoscopic training to make the necessary

transition. Training will prevent inadvertent injuries to middle ear structures and heat trauma.

4. Most of the equipment required is usually available in operating rooms; hence, the cost is only significant if the earlier nasal endoscopic surgeries are not performed at the concerned center.

Applications in the Field of Otolaryngology

1. Therapeutic Applications

➤ Tympanoplasty/Ossiculoplasty

Various studies²¹⁻²³ on endoscopic transcanal tympanoplasty and cholesteatoma surgeries were performed, with success rates similar to those of microscopic procedures.

Ravi et al.²⁴ compared the efficacy of endoscopy and microscopic transcanal inlay butterfly cartilage tympanoplasty, and the endoscopic groups showed great success rates and improvement in hearing.

➤ Mastoid Surgeries and Second-look Surgeries

Endoscopes have been used by many authors in mastoid surgeries to access the difficult-to-reach areas, and they help reduce the morbidity of second-look procedures using a postaural minimally-invasive approach.⁶

➤ Neurotology Surgeries

Endoscopes have been used in neurotologic surgeries such as those for vestibular schwannoma, trigeminal neuralgia, and hemifacial spasm in combination with the microscope.²⁵ They provide good visualization of the geniculate ganglion and intra-labyrinthine facial nerve.

➤ Endoscopic Stapedotomy

The use of endoscopes in stapedotomy is another novel application of TEES. The advantages of using endoscopes in stapes surgery include good exposure without drilling the EAC bone, avoiding chorda tympani manipulation, better visualization of the anterior crus of the stapes to enable its removal without blind manoeuvres.²⁶ Singh et al.²⁷ conducted a prospective study comparing endoscopic and microscopic stapedotomy, and they concluded that both techniques yield comparable audiological outcomes in terms of ABG closure, but that the endoscope has a few advantages, such as better visualization, decreased postoperative pain and dizziness, and minimal handling of chorda tympani and canal wall curettage.

➤ Endoscopic Cochlear Implantation

Cochlear implantation is one of the new applications of endoscopes in the field of otology, but there are few case series on this topic. In a recent study, Sharma et al.²⁸ concluded that the visualization of the round window niche improved with the use of an otoendoscope with 1.9 mm in diameter for cochleostomy and insertion of the electrode; a similar conclusion was reached in the study by Jain A et al.²⁹

2. Diagnostic Application

Because of their variable size and angulation, endoscopes have been used by otologists to diagnose and manage various

conditions, such as in the assessment of the extent of retraction pockets and cholesteatoma,³⁰ ossicular status through the perforation like ossicular discontinuity, and fixation.³¹ Endoscopes have negatively impacted the practice of young residents, as described by Ng et al.;³² in their study, 84.2% of the residents in programs with exposure to EES "felt that its introduction had adversely affected their training, with 88.3 per cent of residents agreeing that faculty members' learning of endoscopic ear surgery had decreased their hands-on surgical load".

Discussion

In the field of otorhinolaryngology, the performance of EES has been increasing rapidly. Looking at the trend for the previous ten years, endoscopes emerged as very promising tool in the management of ear diseases. In the present study, the 354 specialized and general ENT surgeons who participated stated that they performed various types of otological and skull base surgeries with the help of endoscopes. The present study shows that almost all the institutions in India have introduced endoscopes in their practice, both in clinics and operation theatres (74.9%). Regarding the perceived advantages and complications or challenges faced during EES, most of the participants (45.5%) find endoscopes harder to use than microscopes, while the remaining find endoscopes are as hard to use (24.9%) or easier (29.7%) to use than microscopes. Most of the participants believe there should be specific training in the use of endoscopes in ear surgery; for that, the following measures can be introduced: computer simulation training, endoscopic temporal bone dissection, and live surgery workshops. Various education models have shown that a real-time video-assisted modality and non-real-time surgical training are strongly favored, with an improved learning curve and greater future opportunities to perform critical aspects of procedures.³³

With the incorporation of suction into microinstruments, EES could become easier to learn and perform. However, although the use of the endoscope has been proven to be of value, particularly in procedures involving hard-to-reach areas with the microscope, it is still viewed as a complementary method of performing ear surgery, used to augment the existing methods. This has been demonstrated in the present study as 57% of the surgeons felt the endoscope plays a complementary role in relation to the microscope.

The present study shows an increasing trend towards the use of endoscopes in surgeries in the ear and base of the skull. Some of the participants have not yet used endoscopes, but they believe that they should be introduced in the practice, as well as various educational models. Several studies have shown that individuals trained with simulators experience a measurable improvement in terms of operating efficiency, speed, and number of errors.³⁴ Devices that use simulation technology could be used for residents to experience and train for EES.

Endoscopes may have advantages over microscopes in various aspects, but, presently, they cannot fully replace microscopes.

Conclusion

The present study shows that there has been a rapid increase in the use of endoscopes in the otology practice in the last few years in India. However, maximum number of participants showed interest in the learning or introduction of endoscopes in their practice and suggested the various methods of learning of endoscopes in ear surgery. So, we can conclude that there has been a definite increase in interest on the part of otologists in the use of endoscopes in ear surgery, and the future of otological procedures looks promising.

Conflict of Interests

The authors have no conflict of interests to declare.

References

- Hopkins H, Kapany N. A flexible fibroscope, using static scanning. *Nature* 1954;173:39–41
- Mer SB, Derbyshire AJ, Brushenko A, Pontarelli DA. Fiberoptic endoscopes for examining the middle ear. *Arch Otolaryngol* 1967;85(04):387–393
- Nomura Y. Effective photography in otolaryngology-head and neck surgery: endoscopic photography of the middle ear. *Otolaryngol Head Neck Surg* 1982;90(04):395–398
- Takahashi H, Honjo I, Fujita A, Kurata K. Transtympanic endoscopic findings in patients with otitis media with effusion. *Arch Otolaryngol Head Neck Surg* 1990;116(10):1186–1189
- Rosenberg SI, Silverstein H, Hoffer M, Nichols M. Use of endoscopes for chronic ear surgery in children. *Arch Otolaryngol Head Neck Surg* 1995;121(08):870–872
- McKenna KX. Endoscopic 'second look' mastoidectomy to rule out residual epitympanic/mastoid cholesteatoma. *Laryngoscope* 1993;103(07):810–814
- Takahashi H, Honjo I, Fujita A. Endoscopic findings at the pharyngeal orifice of the eustachian tube in otitis media with effusion. *Eur Arch Otorhinolaryngol* 1996;253(1-2):42–44
- Poe DS, Pyykkö I, Valtonen H, Silvola J. Analysis of eustachian tube function by video endoscopy. *Am J Otol* 2000;21(05):602–607
- Klug C, Fabinyi B, Tschabitscher M. Endoscopy of the middle ear through the eustachian tube: anatomic possibilities and limitations. *Am J Otol* 1999;20(03):299–303
- Randrup TS, Ovesen T. Balloon eustachian tuboplasty: a systematic review. *Otolaryngol Head Neck Surg* 2015;152(03):383–392
- Marchioni D, Molteni G, Presutti L. Endoscopic anatomy of the middle ear. *Indian J Otolaryngol Head Neck Surg* 2011;63(02):101–113
- Anschuetz L, Huwendiek S, Stricker D, Yacoub A, Wimmer W, Caversaccio M. Assessment of Middle Ear Anatomy Teaching Methodologies Using Microscopy versus Endoscopy: A Randomized Comparative Study. *Anat Sci Educ* 2019;12(05):507–517
- Bowdler DA, Walsh RM. Comparison of the otoendoscopic and microscopic anatomy of the middle ear cleft in canal wall-up and canal wall-down temporal bone dissections. *Clin Otolaryngol Allied Sci* 1995;20(05):418–422
- Karhuketo TS, Puhakka HJ, Laippala PJ. Endoscopy of the middle ear structures. *Acta Otolaryngol Suppl* 1997;529:34–39
- MacKeith SA, Frampton S, Pothier DD. Thermal properties of operative endoscopes used in otorhinolaryngology. *J Laryngol Otol* 2008;122(07):711–714
- Cohen MS, Landegger LD, Kozin ED, Lee DJ. Pediatric endoscopic ear surgery in clinical practice: Lessons learned and early outcomes. *Laryngoscope* 2016;126(03):732–738
- Kiringoda R, Kozin ED, Lee DJ. Outcomes in endoscopic ear surgery. *Otolaryngol Clin North Am* 2016;49(05):1271–1290
- Kozin ED, Daniel JL. Basic principles of endoscopic ear surgery. *Oper. Tech.Otolaryngol* 2017;28:2–10
- Kozin ED, Gulati S, Kaplan AB, et al. Systematic review of outcomes following observational and operative endoscopic middle ear surgery. *Laryngoscope* 2015;125(05):1205–1214
- Choi N, Noh Y, Park W, et al. Comparison of endoscopic tympanoplasty to microscopic tympanoplasty. *Clin Exp Otorhinolaryngol* 2017;10(01):44–49
- Raj A, Meher R. Endoscopic transcanal myringoplasty-A study. *Indian J Otolaryngol Head Neck Surg* 2001;53(01):47–49
- Emre IE, Cingi C, Bayar Muluk N, Nogueira JF. Endoscopic ear surgery. *J Otol* 2020;15(01):27–32
- Harugop AS, Mudhol RS, Godhi RA. A comparative study of endoscopic assisted myringoplasty and microscope assisted myringoplasty. *Indian J Otolaryngol Head Neck Surg* 2008;60(04):298–302
- Ravi N, Meher R, Rathore PK, Singh I. Comparison of efficacy of endoscopic versus microscopic transcanal inlay butterfly cartilage myringoplasty. *Am J Otolaryngol* 2021;42(04):102978
- Magnan J, Chays A, Lepetre C, Pencroffi E, Locatelli P. Surgical perspectives of the cerebellopontine angle. *Am J Otol* 1994;15(03):366–370
- Nogueira JF Junior, Martin MJB, Aguiar CV, Pinheiro AI. Fully endoscopic stapes surgery (stapedotomy): technique and preliminary results. *Rev Bras Otorrinolaringol (Engl Ed)* 2011;77:721–727
- Singh N, Meher R, Passey JC, Singh I. A Comparative Study of Endoscopic Stapedotomy and Microscopic Stapedotomy. *J Otol Rhinol* 2021;10(05):100411
- Sharma R, Meher R, Passey JC, Kumar J, Gupta A, Kharbada S. Comparative evaluation of round window niche accessibility pre-operatively on high-resolution computed tomography of the temporal bone with intra-operative findings. *J Laryngol Otol* 2019;133(07):575–579
- Jain A, Sharma R, Passey JC, Meher R, Bansal R. Endoscopic visualisation of the round window during cochlear implantation. *J Laryngol Otol* 2020;134(03):219–221
- Cassano M, Cassano P. Retraction pockets of pars tensa in pediatric patients: clinical evolution and treatment. *Int J Pediatr Otorhinolaryngol* 2010;74(02):178–182
- Nomura Y. A needle otoscope. An instrument of endoscopy of the middle ear. *Acta Otolaryngol* 1982;93(1-2):73–79
- Ng CL, Ong W, Ngo RYS. Otolaryngology residents' perceptions of endoscopic ear surgery during surgical training. *J Laryngol Otol* 2020;134(03):233–240
- Allori AC, Marcus JR, Daluvoy S, Bond J. Video-assisted palatopharyngeal surgery: a model for improved education and training. *Cleft Palate Craniofac J* 2014;51(05):605–612
- Chang L, Satava RM, Pellegrini CA, Sinanan MN. Robotic surgery: identifying the learning curve through objective measurement of skill. *Surg Endosc* 2003;17(11):1744–1748

ANNEX 1

- City/ State of practice:
- Do you perform ear surgery?
 - Yes
 - No
- Which of the following best describes your current level of specialty training:
 - PG year 1
 - PG year 2
 - PG year 3
 - Senior Resident year 1
 - Senior Resident year 2
 - Senior Resident year 3
 - Consultant post SR 10 years of experience
 - Consultant post SR 30 years of experience
- How long have you been performing endoscopic ear procedures?
 - Less than 5 years
 - 10-20 years
 - 20-30 years
 - More than 30 years
- In which setting do you use endoscopes in your practice?
 - In the clinic
 - In the clinic and operation theatre
 - In the operation theatre
 - I don't currently use an endoscope
- Please select the ear surgeries in which you use endoscopes. (Mark all that apply.)
 - Myringoplasty/Tympanoplasty
 - Cholesteatoma surgery
 - Ossiculoplasty
 - Stapedotomy
 - Cochlear Implant
 - Skull base surgery
 - None
 - Any other
- How many endoscopic ear procedures have you performed?
 - None
 - 1-10
 - 11-20
 - 21-30
 - 31-50
 - 51-100
 - More than 100
- Please select the category which most appropriately describes your use of the endoscope in cholesteatoma surgery. If you do not use it, please select "Not applicable".
 - I use an endoscope at the end of the case to assess for residual disease
 - I primarily operate with the microscope, and use the endoscope sparingly to operate in difficult-to-reach areas
 - I mainly use the endoscope, and reserve the microscope for cases of extensive disease involving the mastoid
 - I exclusively use the endoscope
 - Not applicable
- Do you feel the endoscope plays a role in otological surgery?
 - Yes
 - No
 - Maybe/Unsure

- Select all alternatives that apply regarding the perceived advantages of endoscopic ear surgery.
 - Safety
 - Cost
 - Ease of use
 - Superior visualization of the middle ear
 - More efficiency/Shorter operative time
 - Reduced recurrence/residual disease (cholesteatoma)
 - Better preservation of the ossicle and healthy tissue
 - Lower rate of postoperative morbidity
 - Better cosmesis
 - Faster patient recovery
 - Good teaching tool
 - Accessing difficult-to-reach areas
- Which of the following complications during endoscopic ear procedure have you come across? (Mark all that apply.)
 - Tympanic membrane rupture
 - Facial nerve injury
 - Injury to the wall of the external auditory canal
 - Chorda tympani nerve injury
 - Other
- Which endoscope do you commonly use in your ear surgeries? (Mark all that apply.)
 - 1.9-mm/Straight
 - 1.9-mm/Angled
 - 3-mm/Straight
 - 3-mm/Angled
 - 4-mm/Straight
 - 4mm/Angled
- In your opinion, what are the challenges faced when switching from the microscope to the endoscope in ear surgeries? (Mark all that apply.)
 - One-handed surgery
 - Loss of depth perception
 - “Fish Eye” effect/Distortion of field of vision
 - Limited magnification
 - Fogging of the endoscope
 - Obstruction of the working space by the endoscope
 - Application in narrow ear canals
 - Safety issues due to heat dissipation
 - Inadvertent trauma to structures by the tip of the endoscope
 - Access to specialized instruments
 - Problems with bone removal/drilling using the endoscope
- In your experience, compare the need for revision in procedures performed with endoscopes alone and with the microscope.
 - Lower in comparison to the microscope
 - Higher in comparison to the microscope
 - Almost same in comparison to the microscope
 - I do not use the endoscope in surgeries
- In comparison to the microscope, how would you describe your overall learning experience with the endoscope in ear surgery?
 - I find endoscopic ear surgeries harder than microscopic ear surgeries
 - I find endoscopic ear surgeries easier than microscopic ear surgeries
 - I find endoscopic and microscopic ear surgeries comparable in terms of difficulty
- Do you feel there is a need for specific technical training in the use of endoscopes in ENT surgeries?
 - Yes
 - No
 - Maybe/Unsure

➤ If you have answered “Yes” or “Maybe” to the previous question, please select as many of the measures mentioned below that you feel need to be introduced/encouraged.

- Computer simulation training
- Endoscopic temporal bone dissection
- Live surgical workshop
- Training opportunities under dedicated endoscopic ear surgeon
- Other

➤ Mark your opinion regarding the following statement: “I will use endoscopes in ear surgery in the future.”

- I am already using them
- Strongly agree
- Agree
- Neutral
- Disagree
- Strongly disagree