Article published online: 2022-12-04

Invasive Coronary Physiology Study in Multivessel Coronary Artery Disease

Agita Maryalda Zahidin[1] Amir Aziz Alkatiri[1] Arwin Saleh Mangkuanom[1] Nanda Iryuza[1] Doni Firman[1]

[1] Department of Cardiology and Vascular Medicine, Faculty of Medicine, Universitas Indonesia, National Cardiovascular Center Harapan Kita, Jakarta, Indonesia

Int J Angiol

Address for correspondence Agita Maryalda Zahidin, Department of Cardiology and Vascular Medicine, Universitas Indonesia, Jl. Letjen S. Parman No.Kav.87, RW.8, Kota Bambu Utara, Kec. Palmerah, Kota Jakarta Barat, Daerah Khusus Ibukota, Jakarta 11420, Indonesia (e-mail: amaryalda@gmail.com).

Abstract

Assessment of relationship between the angiographic stenosis severity and the coronary blood flow is complex. Coronary angiography has many limitations that may impair the judgment of stenosis severity and then affect decision-making regarding intervention. Myocardial perfusion imaging by single-photon emission tomography (MPI-SPECT) is used for a long time to help clinical decisions of interventions, but has limitations, such as issues with identification of extensive coronary artery disease (CAD). Fractional flow reserve (FFR) is a gold standard index for investigating the physiological significance of a coronary stenosis. The instantaneous wave-free ratio (iFR) is a hyperemia-free measurement and easier method to achieve physiological assessment to measure the severity of coronary stenosis. We present a case of multivessel coronary artery disease (MVCAD) patient who was treated with iFR-guided percutaneous coronary intervention (PCI) and emphasize the importance of physiological assessment in PCI.

A 63-year-old male with multiple cardiovascular risk factors came to our center with chief complaint of stable angina since 1 year. He underwent MPI-SPECT and the result showed 2.5% of ischemia burden. Coronary angiography showed MVCAD. Surgical conference decided to do PCI. iFR-guided PCI was performed in this case.

Our case highlights the importance of iFR as an important cardiology–physiology-based tool as a guide in management decisions for MVCAD. iFR as an alternative approach to physiological study is noninferior compared with FFR-guided PCI.

Keywords

- instantaneous wave-free ratio
- percutaneous coronary intervention
- multivessel coronary artery disease
- physiology study

Multivessel coronary artery disease (MVCAD) is defined by the presence of ≥50% diameter stenosis of two or more epicardial coronary arteries. The presence of MVCAD indicates poorer prognosis and a significantly higher mortality than single-vessel disease. In MVCAD, revascularization can be achieved by either PCI or coronary artery bypass grafting.[1] In MVCAD, revascularization modality should depend on a multifactorial evaluation, taking into account not only coronary anatomy, ischemic burden, myocardial function, age and the presence of comorbidities, but also the adequacy of myocardial revascularization.

Assessment of coronary stenosis with coronary angiography has several limitation. Although the benefit of coronary revascularization occurs mainly in patients with flow-limiting stenoses, the majority of stable patients are still managed on the basis of the coronary angiography alone, frequently without prior non-invasive functional assessment.

Functional assessment is an important tool that can guide management decisions for MVCAD determining whether the patient would benefit from revascularization or medical therapy. Owing to its wide availability, non-invasiveness, and high diagnostic performance, use of myocardial

© 2022. International College of Angiology. All rights reserved.
Thieme Medical Publishers, Inc., 333 Seventh Avenue, 18th Floor, New York, NY 10001, USA

DOI https://doi.org/10.1055/s-0042-1759620.
ISSN 1061-1711.

This document was downloaded for personal use only. Unauthorized distribution is strictly prohibited.

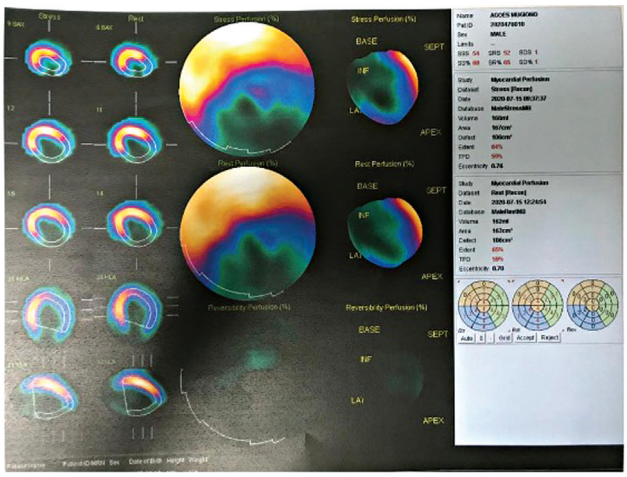

Fig. 1 MPI-SPECT. MPI-SPECT, myocardial perfusion imaging by single-photon emission tomography.

perfusion imaging by single-photon emission tomography (MPI-SPECT) has become a common practice for CAD screening, characterization, and follow-up.[2]

Fractional flow reserve (FFR) is now accepted as the reference standard to indicate whether a stenosis is likely to be responsible for ischemia. It is a pressure wire-based index that is used during coronary angiography to assess the potential of a coronary stenosis to induce myocardial ischemia. Vasodilator such as adenosine is used to achieved constant and minimal microvascular resistance in FFR procedure. Instantaneous wave-free ratio (iFR) is a pressure-only index that takes an alternative approach to the isolation of hemodynamic of a stenosis from the microcirculation without using vasodilator. It was introduced with the attempt to make the assessment of stenosis severity quicker and easier.[3,4]

Case Presentation

A 63-year-old male with multiple cardiovascular risk factors came to outpatient clinic of National Cardiovascular Center Harapan Kita after being referred from general hospital for further management of CAD. He came with chief complaint of stable angina 1 year ago. The patient had a history of admission due to inferior ST-elevation of myocardial infarction in 2019 at a general hospital and was undergo coronary angiography with the result of CAD with triple-vessels disease. Hypertension and history of smoking were his atherosclerotic risk factor.

Physical examination revealed the blood pressure of 124/82 mm Hg and other physical examination found no remarkable findings. Electrocardiography examination showed slight ST elevation III aVF, ST depression V5-V6, and Q wave II-III aVF. Echocardiography revealed reduced LV systolic function (LVEF) 17% with reduced RV contractility (TAPSE 10 mm) and regional wall motion abnormalities. MPI-SPECT was done with result ischemic burden 2.5% with reversible myocardial ischemia at mid anterior (left anterior descending [LAD]), partial reversible at apico anterior (LAD), and irreversible ischemia at apico-mid anteroseptal (LAD), mid-basal inferoseptal (RCA), basal inferolateral, and mid-basal anterolateral (left circumflex artery [LCx]) (►**Fig. 1**). Surgical conference decided to do PCI LAD with coronary physiology study.

Diagnostic coronary angiography revealed stenosis 30% at distal left main, diffuse stenosis from proximal-mid LAD with 70 to 80% stenosis, large caliber with diffuse stenosis from osteal-proximal diagonal 1 (D1) with 80% maximum lesion, 30 to 50% stenosis at proximal LCx, and 50 to 60% stenosis at obtuse marginal 2 (►**Fig. 2**). There are significant stenosis at distal LAD with instantaneous wave-free ratio (iFR) 0.78 and D1 with iFR 0.45. PCI 3 DES LAD-D1 with Culotte technique using Biomatrix Alpha 2.75 × 36 mm at D1, Biomatrix Alpha 2.75 × 29 mm at mid LAD, and Promus Element 3.0 × 20 mm in proximal LAD across diagonal were performed in this patient along with optimization of anti-ischemic therapy. After PCI was performed, iFR at distal LAD and D1 increased to 0.98 and 0.95, subsequently (►**Fig. 3**).

Discussion

FFR is defined as maximum myocardial blood flow in a stenotic territory, divided by normal maximum blood flow in that same territory in the hypothetical case that the supplying coronary artery would be completely normal.[5] The instant wave-free ratio (iFR) has been introduced as an alternative to FFR. iFR is a resting index of stenosis severity

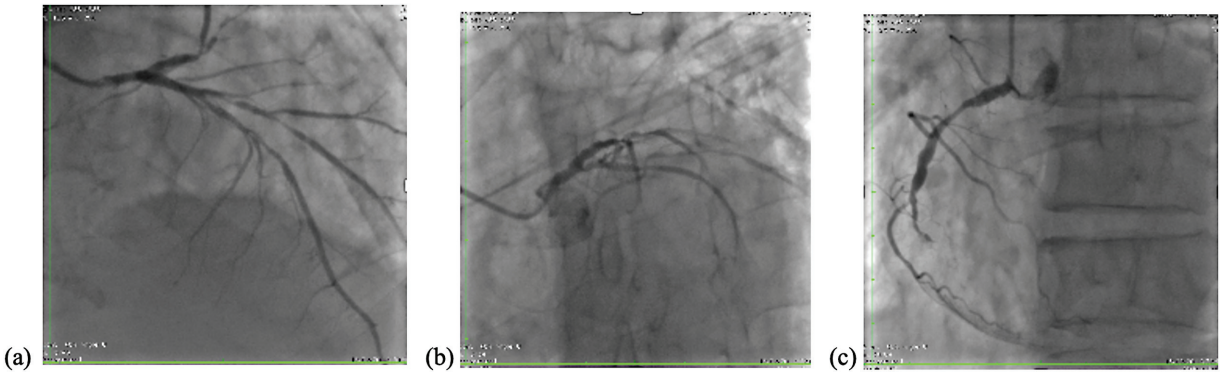

Fig. 2 Angiography showed diffused stenosis at proximal-mid with maximum stenosis of 70–80% and D1 at ostealproximal with maximum stenosis of 80% **(a)**, stenosis 40–50% at proximal LCx **(b)**, and total occlusion at distal RCA **(c)**.

 © 2022. International College of Angiology. All rights reserved.

This document was downloaded for personal use only. Unauthorized distribution is strictly prohibited.

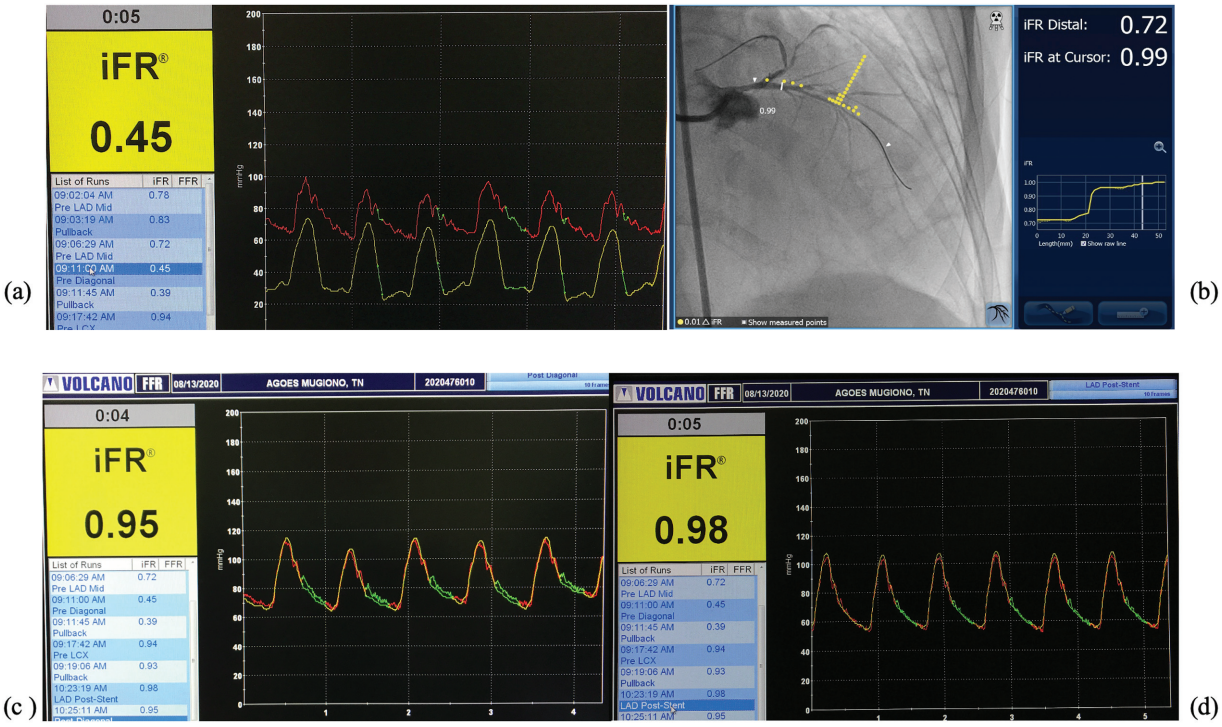

Fig. 3 Co-Registration in this case. Pre-stent iFR (**a**) D1 and (**b**) LAD. Post-stent iFR (**c**) D1 and (**d**) LAD. iFR, instantaneous wave-free ratio; instantaneous wave-free ratio; LAD, left anterior descending.

that provides physiological quantification of the effect of stenosis on the coronary circulation.[5]

In MVCAD patients with regional wall motion abnormalities or ventricular dysfunction, assessment of myocardial viability may be done to select patients that are more likely to benefit from myocardial revascularization.[6] In this case, patients complaint of angina. Most patients with significant stenosis are symptomatic due to disturbance of supply to large myocardial territory. However, visual estimates of intermediate and significant stenosis from coronary angiography have significant interobserver variability.

Non-invasive study using MPI-SPECT was done to evaluate the myocardial viability in approaching the indication of revascularization.[6,7] A low ischemic burden of 2.5% was calculated and felt to be unremarkable for revascularization. With chief complaint of angina that was provoked by activity and multivessel disease that was revealed by coronary angiography, the result of low ischemic burden was considered inconsistent. We decide to do further physiological assessment by iFR, consistent with ESC recommendation in approaching the indication of revascularization.[6]

As a resting index, iFR presents several advantages over hyperemic indices which could propel the use of coronary physiology well beyond their current use.[5] Adenosine, as also hyperemic agent, causes transient blood pressure reduction which can be of relevant magnitude in some cases. Individual response to adenosine is largely variable, higher concentrations should warrant an adequate response in a larger number of patients, but it may have a larger impact on hemodynamics which could negatively impact FFR measurements.[3]

Objective ischemia assessment can be performed with either modality because both FFR and iFR have been demonstrated to show no significant differences in the prediction of myocardial ischemia from 13N-ammonia positron emission tomography. Additionally, iFR-guided revascularization was noninferior to FFR-guided revascularization for major adverse cardiac events at 1-year follow-up in two separate, large randomized multicenter trials.[8]

In this case, iFR strongly supports decision-making regarding treatment selection in patients with multivessel disease.[3,9] iFR in LCx revealed the ratio of 0.93, so we decided to not perform PCI in this lesion because it was physiologically nonsignificant stenosis. In contrast, because of the significant stenosis in distal LAD with iFR 0.78 and D1 with iFR 0.41, PCI distal LAD and D1 were done in this patient to increase the estimated iFR to its optimal level. It was proven by an increase in iFR after stenting to 0.98 and 0.95 in the distal LAD and D1.

Conclusion

We reported a case of a 63-year-old man with multivessel disease treated with iFR-guided PCI. Coronary physiology is an important tool that can guide management decisions for intermediate lesions and MVCAD, determining whether the patient would benefit from revascularization or medical therapy. iFR as an alternative approach to physiological study

This document was downloaded for personal use only. Unauthorized distribution is strictly prohibited.

 © 2022. International College of Angiology. All rights reserved.

is noninferior compared with FFR-guided PCI. Co-registration of iFR measurements significantly simplified the overall examination and improved its accuracy.

Funding
This paper received no specific grant from any funding agency, commercial or not-for-profit sectors.

Conflict of Interest
None declared.

Acknowledgments
The authors would like to express special thanks of gratitude to Department of Cardiology and Vascular Medicine, Faculty of Medicine, Universitas Indonesia and to the National Cardiovascular Center Harapan Kita Jakarta.

References

1 Windecker S, Kolh P, Alfonso F, et al; Authors/Task Force members. 2014 ESC/EACTS Guidelines on myocardial revascularization: the Task Force on Myocardial Revascularization of the European Society of Cardiology (ESC) and the European Association for Cardio-Thoracic Surgery (EACTS)Developed with the special contribution of the European Association of Percutaneous Cardiovascular Interventions (EAPCI). Eur Heart J 2014;35(37): 2541–2619

2 Ben Bouallègue F, Roubille F, Lattuca B, et al. SPECT myocardial perfusion reserve in patients with multivessel coronary disease: correlation with angiographic findings and invasive fractional flow reserve measurements. J Nucl Med 2015;56(11):1712–1717

3 De Rosa S, Polimeni A, Petraco R, Davies JE, Indolfi C. Diagnostic performance of the instantaneous wave-free ratio: comparison with fractional flow reserve. Circ Cardiovasc Interv 2018;11(01): e004613

4 Sen S, Asrress KN, Nijjer S, et al. Diagnostic classification of the instantaneous wave-free ratio is equivalent to fractional flow reserve and is not improved with adenosine administration. Results of CLARIFY (Classification Accuracy of Pressure-Only Ratios Against Indices Using Flow Study). J Am Coll Cardiol 2013;61(13):1409–1420

5 Matsuo H, Kawase Y. FFR and iFR: similarities, differences, and clinical implication. Ann Nucl Cardiol 2017;3(01):53–60

6 Neumann FJ, Sousa-Uva M, Ahlsson A, et al; ESC Scientific Document Group. 2018 ESC/EACTS Guidelines on myocardial revascularization. Eur Heart J 2019;40(02):87–165

7 Amin OA, Hady YAA, Esmail MANE. Myocardial perfusion imaging by single-photon emission tomography (MPI SPECT) versus Instantaneous wave-free ratio (IFR) for assessment of functional significance of intermediate coronary artery lesions. Egypt Heart J 2019;71(01):35

8 Shlofmitz E, Jeremias A. FFR in 2017: current status in PCI management. J Am Coll Cardiol 2017 Accessed May 25, 2017, at: http://www.acc.org

9 Davies JE, Sen S, Dehbi HM, et al. Use of the Instantaneous Wave-free Ratio or Fractional Flow Reserve in PCI. N Engl J Med 2017; 376(19):1824–1834

This document was downloaded for personal use only. Unauthorized distribution is strictly prohibited.

 © 2022. International College of Angiology. All rights reserved.