



Sural Artery as a Recipient Vessel for Free Flaps

Prakash Panagatla¹ Parvathi Ravula¹ Patnala Chandrashekar² R. Srikanth¹ Nakka Alekya¹

¹Department of Plastic and Reconstructive Surgery, Nizam's Institute of Medical Sciences, Punjagutta, Hyderabad, Telangana, India

²Department of Orthopaedic Surgery, Nizam's Institute of Medical Sciences, Punjagutta, Hyderabad, Telangana, India

Address for correspondence Nakka Alekya, MCh, Department of Plastic and Reconstructive Surgery, Nizam's Institute of Medical Sciences, Punjagutta 500082, Hyderabad, Telangana, India (e-mail: alekyambbs@gmail.com).

Indian J Plast Surg 2023;56:31–38.

Abstract

Introduction The axial vessels like the anterior and posterior tibial emerge as the first choice of recipient vessels, in free flaps for lower limb trauma. When the defects are located more proximally in the leg, the deeper course of the axial vessels makes the dissection more tedious. Alternative vessels like the descending genicular, medial genicular, and distal end of the descending branch of the lateral circumflex femoral can be used for an end-to-end anastomosis, well away from the zone of trauma.

The objective of this study was to define the indications and technique of the use of the sural vessels as the recipient pedicle for proximal and middle third leg defects.

Patients and Methods For the period 2006 to 2022, 18 leg defects following road traffic accidents were covered with latissimus dorsi muscle flap using sural vessels as the recipient pedicle.

Results Among 18 patients, 8 patients had defect in proximal third, 8 had a combined defect in proximal and middle third leg, and 2 had defect in middle third leg. Two patients developed arterial thrombosis and one patient had venous thrombosis for which re-exploration was performed. Two flaps were lost and sixteen had successful wound coverage.

Conclusion The sural vessels as recipient pedicle are easier to access and can be considered as a reliable option for free flaps in limb defects of proximal and middle third leg. Using the submuscular part of the vessel ensures a better distal reach of the flap.

Keywords

- ▶ free flap
- ▶ lower limb trauma
- ▶ sural vessels
- ▶ leg defects
- ▶ recipient vessel

Introduction

Choosing a healthy, reliable recipient vessel is the mainstay of free tissue transfers in compound injuries of the leg; in addition, an attempt is made to stay away from the “zone of trauma” to prevent vascular compromise of the transferred flap.¹ This does put an emphasis on the choice of flap also, preference being given to flaps with a longer pedicle length. Though the concept of using vessels “distal

to the zone of trauma” has been considered to circumvent issues of pedicle length,² by and large proximal anastomosis is preferred.

Accessing the axial vessels, the anterior tibial or the posterior tibial is relatively simpler in the middle and lower thirds of the leg, but this is not so in the proximal third as they have a deeper course that may make the delivery more cumbersome. There may also be a bias in straying toward the

article published online
February 7, 2023

DOI <https://doi.org/10.1055/s-0042-1760094>.
ISSN 0970-0358.

© 2023. Association of Plastic Surgeons of India. All rights reserved. This is an open access article published by Thieme under the terms of the Creative Commons Attribution-NonDerivative-NonCommercial-License, permitting copying and reproduction so long as the original work is given appropriate credit. Contents may not be used for commercial purposes, or adapted, remixed, transformed or built upon. (<https://creativecommons.org/licenses/by-nc-nd/4.0/>)
Thieme Medical and Scientific Publishers Pvt. Ltd., A-12, 2nd Floor, Sector 2, Noida-201301 UP, India

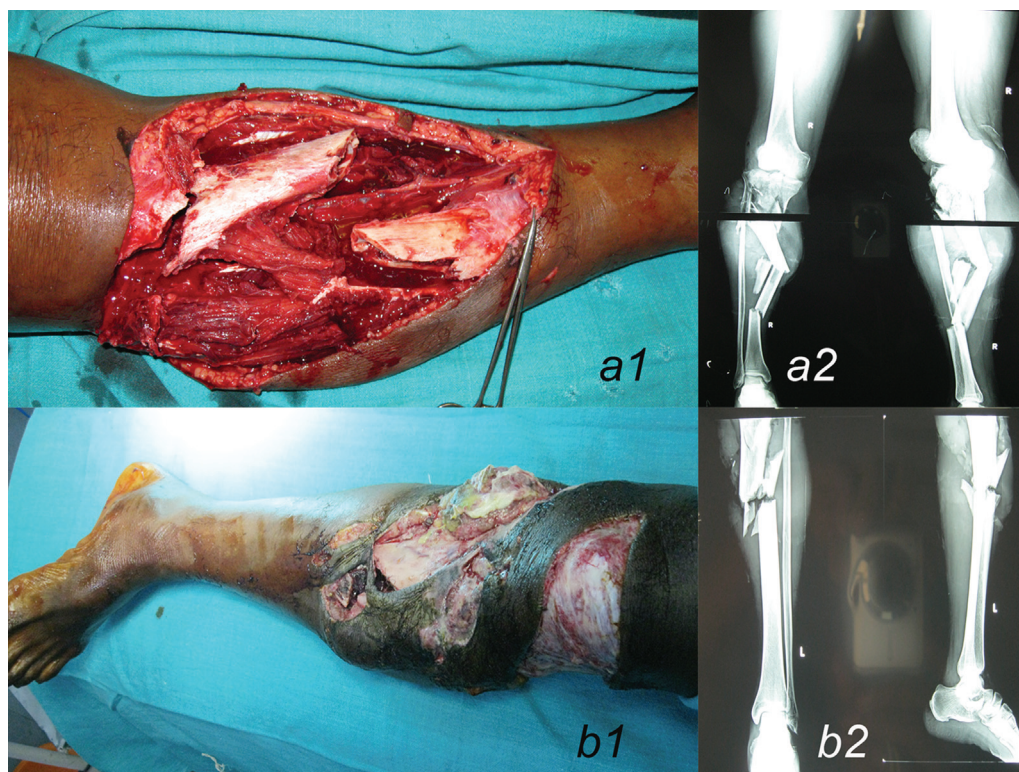


Fig. 1 Defects of the upper and/or middle third of the leg with paucity of reliable local flap options.

zone of trauma to facilitate the microvascular anastomosis (►Fig. 1).

Fractures with exposed bare tibial bone in the upper and middle third planned for free flap coverage need a good proximal recipient vessel; among the different recipient pedicles described for around the knee and proximal leg defects, the medial sural artery can provide an additional length of pedicle that aids in gaining the effective length of the flap to attain the distal most reach possible, without a need for vein grafts.

The medial sural artery is perhaps less frequently used as a recipient pedicle. For a long time, the concern was the potential negative impact on the function of the medial head of the gastrocnemius muscle as it was initially classified as type 1 muscle by Mathes and Nahai³; subsequently it has been reclassified as type 2 muscle after Taylor's studies, also being nourished by perforating branches of the posterior tibial and femoral arteries.⁴ In addition, Tsetsonis et al have also described communications between the lateral and medial heads of gastrocnemius suggesting further collateral supply to the medial head.⁵ The objective of this study was to define the indications and technique of the use of the sural vessels as the recipient pedicle for proximal and middle third leg defects.

Patients and Methods

This is a retrospective study of free flaps using the sural vessels as the recipient vessel between 2006 and 2022. The inclusion criterion was the presence of a compound fracture

in the upper and/or middle third of the leg. All the flaps were latissimus dorsi muscle flaps covered by split skin grafts.

Data pertaining to demography, location of the defect, size of the defect, adequacy of fracture site coverage, and distal flap reach were recorded based on data extraction from case sheets. Re-exploration and final outcome of flap success or failure (total or partial) were noted. All other complications like infection, hematoma formation and skin graft loss at the recipient site were noted.

Technique

All the reconstructions were performed under general anesthesia, following debridement and fracture stabilization using external fixation. The patients were placed in lateral decubitus position for the dissection of recipient vessels and simultaneous harvest of latissimus dorsi muscle. For medial defects contralateral muscle and for lateral defects, the ipsilateral muscle was chosen to facilitate a two-team approach (►Fig. 2).

Recipient vessels were explored through a midline incision in the popliteal fossa, extending from two inches above the crease to three inches below, in the palpable cleft between the two heads of the gastrocnemius muscle. Three parts can be made out in the course of the medial sural vessel—(1) the portion from origin to the point where the vessel dips under the gastrocnemius head, (2) the portion beneath the head, and (3) the intramuscular portion. In the initial reconstructions, the “free lying” portion of the sural vessels (1) was used for the anastomosis. In the last five cases, this

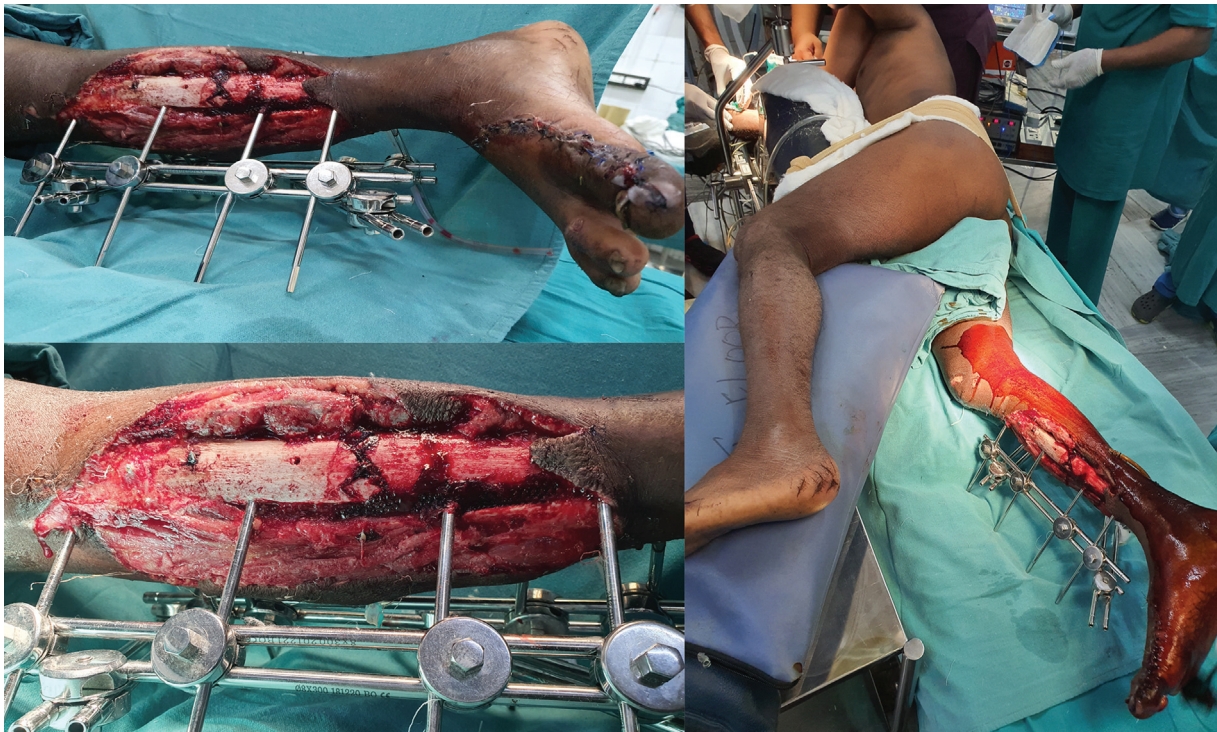


Fig. 2 Large defect extending across the upper and middle third of the leg with exposed fracture; the positioning to permit simultaneous access of medial sural vessel and harvest of latissimus dorsi flap.

dissection was carried more distally to use the submuscular portion of the medial sural vessels (2) as the site of anastomosis (► Fig. 3).

The short saphenous vein and sural nerve were retracted out of the way and also the motor nerves to the gastrocnemius were preserved. This incision was connected to the recipient defect, and tunnelling was not used for fear of compression. Microvascular anastomosis was done in the same lateral position. At the completion of the anastomosis,

the proximal tendinous end of the muscle was fixed to the proximal gastrocnemius muscle end as this would deflect any longitudinal tension from the anastomosis and would also form a “graftable bed”—as we always avoid reclosure of the access incision. Initial part of the flap inset was done in the same lateral decubitus position, and the final and most anterior part of the inset was done after changing to supine position. Postoperatively limb was hung with the support of external fixator to prevent compression at the anastomotic site and to avoid dependency.



Fig. 3 Five-centimeter pedicle length without any intramuscular dissection; good pulsatile flow in the artery; successful completed anastomosis using medial sural artery and venae comitantes.

Results

Of 18 patients, 17 were men and one female, aged between 19 and 47 years at the time of operation with mean age of 34 years. One was a diabetic on medical treatment.

Twelve of 18 cases were acute trauma defects with an average time interval of 2 days following the debridement and external fixation. Six were posttraumatic defects with subacute or chronic wounds and a time interval of 3.25 months. The mean defect size was 150 cm², the largest being 375 cm². Eight patients had defects in proximal third, eight patients had defect in the proximal and middle third leg and two patients had middle third defects (► Table 1).

The medial sural was the recipient vessel in 15 cases, and in three cases the lateral sural vessels were used (► Figs. 4–7).

There were two arterial and one venous thrombosis needing re-exploration, among which one venous thrombosis could be salvaged by a redo anastomosis with successful flap salvage. Two patients had complete flap loss. There was

Table 1 Clinical details and outcome of the cases discussed

Case no	Time	Defect location	Defect size	Rec. ped.	Re-exploration	Flap outcome
1	1 day	Upper and middle third, contused anterior tibial vessels	18 × 15 cm	Medial	–	Donor hematoma needing drainage
2	2 ½ months	Upper third with comminution and exposed dead bone	12 × 10 cm	Medial	–	Uneventful wound healing
3	2 days	Upper and middle third, fracture femur	14 × 10 cm	Medial	–	Partial distal necrosis; no critical exposure
4	2 days	Upper third	12 × 8 cm	Medial	–	
5	1 month	Upper and middle third fracture with tibial condyle implant exposed and failed local flap	20 × 15 cm	Medial	–	Uneventful wound healing
6	1 days	Upper and middle third	18 × 10 cm	Medial	–	Uneventful wound healing
7	3 days	Upper and middle third	14 × 8 cm	Medial		Uneventful wound healing
8	2 ½ months	Upper third fracture exposed implant; previously failed cross leg flap	20 × 15 cm	Lateral	–	Uneventful wound healing
9	6 months	Upper third fracture; 15 cm exposed tibia with partially skin grafted wound	15 × 10 cm	Medial	–	Donor hematoma needing drainage
10	2 days	Upper third with vertically split tibia, crushed anterior compartment muscles	15 × 12 cm	Medial	–	Uneventful wound healing
11	3 ½ months	Upper and middle third infective nonunion	10 × 10 cm	Medial	–	Uneventful wound healing
12	2 days	Upper third with anterior knee	15 × 8 cm	Medial	Arterial thrombosis	Interval cross leg flap
13	3 days	Upper third, cut distal third gastrocnemius	10 × 8 cm	Medial	Redo vein	Partial distal necrosis; no critical exposure
14	2 days	Upper third and patella fracture	20 × 10 cm	Lateral	–	Uneventful wound healing
15	4 months	Upper and middle third, implant exposed	15 × 8 cm	Medial	Arterial thrombosis	Interval cross leg flap
16	1 day	Upper and middle third	25 × 15 cm	Lateral	–	Donor site seroma
17	2 days	Middle third	12 × 12 cm	Medial		Uneventful wound healing
18	3 days	Middle third	15 × 12 cm	Medial		Uneventful wound healing

distal flap necrosis in two cases—one that had been re-explored and another. The wounds were dressed after debridement and secondarily skin grafted; there was no exposure of fracture site or the bone. There were two hematomas at the donor site needing surgical evacuation and one seroma needing aspiration and compression. One patient needed secondary split skin grafting for raw areas in the distal leg.

Discussion

The selection of recipient vessels in lower limb trauma by Yazar and Lin concluded that the selection depends on (1) the location and severity of soft tissue and bone defect, (2) the number of available vessels, (3) the location and distance of the vessels to the defect, and especially (4) the condition of the already injured vessels for microvascular anastomosis.⁶

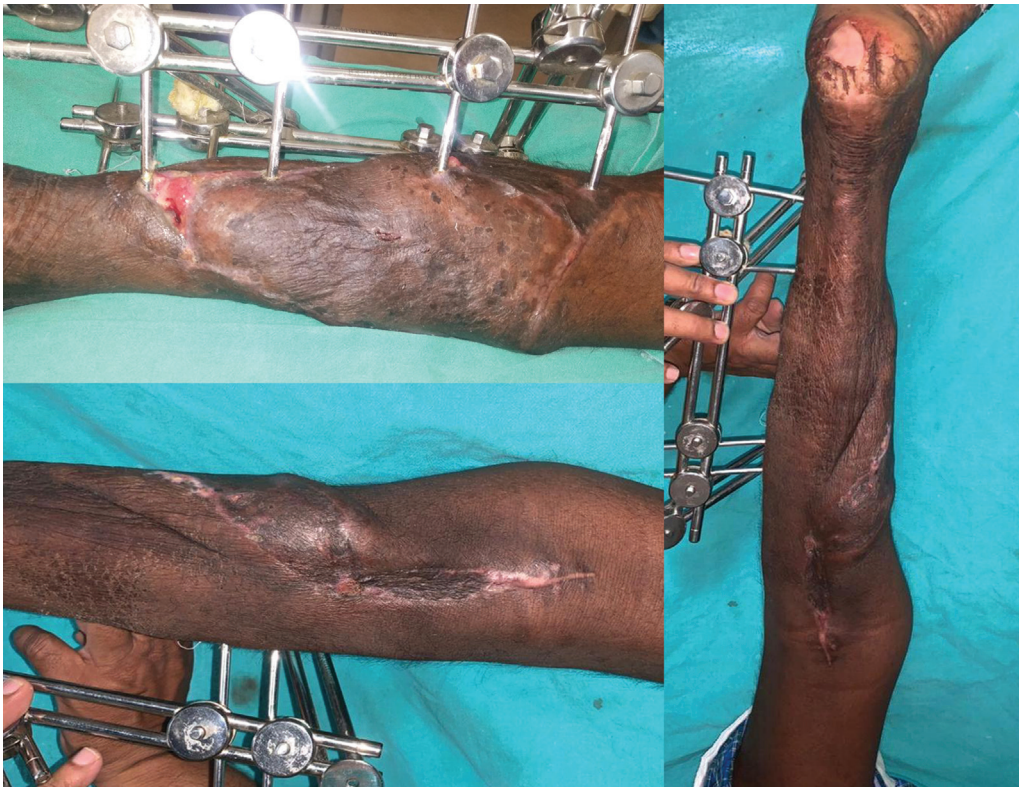

Fig. 4 Early follow-up images—anteromedial, posteromedial, and posterior aspect of leg to show the reconstruction (pre- and peroperative images shown in ►Figs. 2 and 3).

They reported use of medial sural artery as recipient vessel in approximately 1.9% cases with a failure rate of approximately 9% (1 of 11 cases) and mentioned that it could be used in peripheral vascular disease.

Vessels “distal to the zone of trauma” can also be used, with the possibility of retrograde flow in the artery and or the vein; though appealing, it must be ensured that there is flow “across the injury zone”—and it may necessitate a preoperative angiogram.^{7,8} A retrograde venous anastomosis could result in venous congestion also.

Fang et al⁹ discussed about different vessels around the knee for microsurgical reconstruction of knee and proximal leg defects. These include descending branch of superficial femoral artery,¹⁰ descending genicular vessels,¹¹ popliteal,

descending branch of lateral circumflex femoral artery,¹² and the medial sural artery.

When the defects are around the knee, there is no doubt that the genicular vessels or the descending branch of the lateral circumflex femoral serve well; the reach of these vessels is questionable for defects further down the leg. The origin and the course of the medial sural vessels give a more distal reach for the proximal and middle third leg defects without using any vein grafts.

Johnson et al¹³ in his cadaveric and clinical study first described medial sural artery as recipient vessel for nine defects around the knee using free latissimus dorsi muscle flap. An oblique incision between two heads of gastrocnemius was used; a reliable vessel diameter of 1.5 to 2mm and

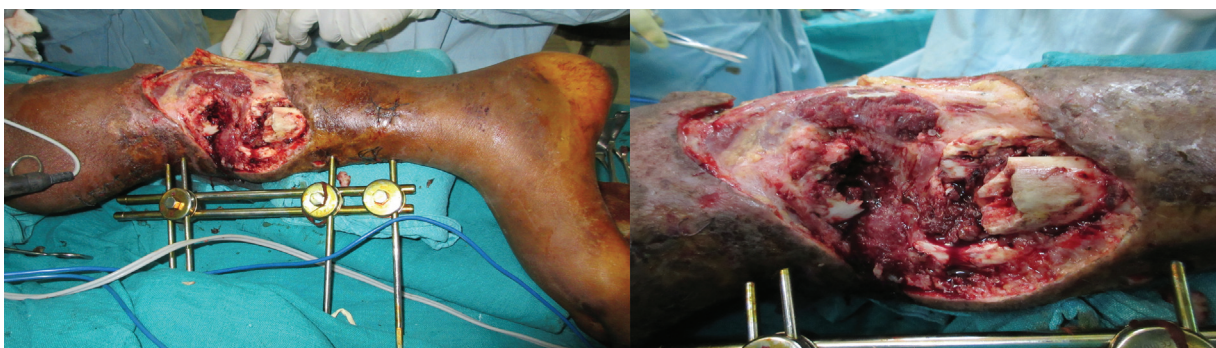

Fig. 5 Posttraumatic defect in the upper middle third leg with substantial scar; freshening of skeletal defect, docking, and external skeletal fixation.

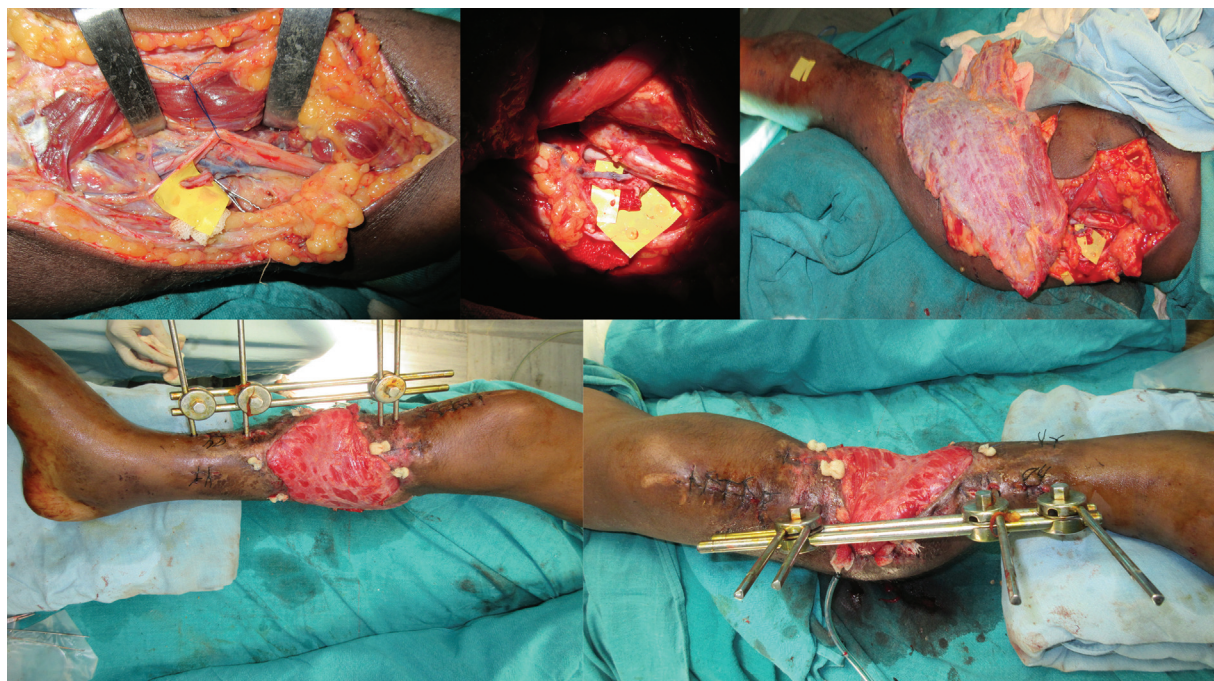


Fig. 6 Medial defect but using the lateral sural vessels and keeping the tibial nerve branches out of the way preventing kinking; immediate postoperative image with well-perfused flap.

length of approximately 5 to 7 cm was noted. It was noticed that medial vessel is larger and superficial compared with lateral vessel. He highlighted on the advantage of increasing the effective length of the distal flap reach, tension free end-

to-end anastomosis with a rapid exposure of the recipient pedicle.

Hallock¹⁴ described a medial approach to medial sural artery for anastomosis, detaching the semitendinosus and semimembranosus muscles, with patient in supine position.

Pyon et al¹⁵ described medial sural artery as a useful option for free flap reconstruction in “single vessel leg” situations—three latissimus dorsi muscle flaps were done and one failed.

We prefer a posterior approach to facilitate ease of dissection in the plane between the two heads of the muscle and the possibility of a simultaneous latissimus dorsi harvest.

Beumer et al¹⁶ in his clinical and radiological assessment using magnetic resonance imaging found little difference regarding the impact of using medial sural artery pedicle on the function of medial head of gastrocnemius, in four cases of knee and proximal leg defects.

The presence of a viable gastrocnemius muscle is our basis for choosing the pedicle as a recipient vessel and pulsatile flow on exploration confirms its health.

Smith et al¹⁷ reported retrograde dissection of distal medial sural artery after identifying the first cutaneous perforator in 20 vascularized lymph node transfers. Preoperative magnetic resonance angiogram was used to evaluate the vessels. Retrograde dissection offered the advantage of gain in pedicle length of up to 15 cm, and the more distal site of anastomosis implied a better diameter match in lymph node transfers. Since we used the latissimus dorsi flap, such distal dissection was not considered to prevent vessels diameter mismatch.

Baliarsing et al¹⁸ reported 10 microsurgical reconstructions in “vessel depleted” severe lower limb trauma and perivascular disease. Space between the medial head of

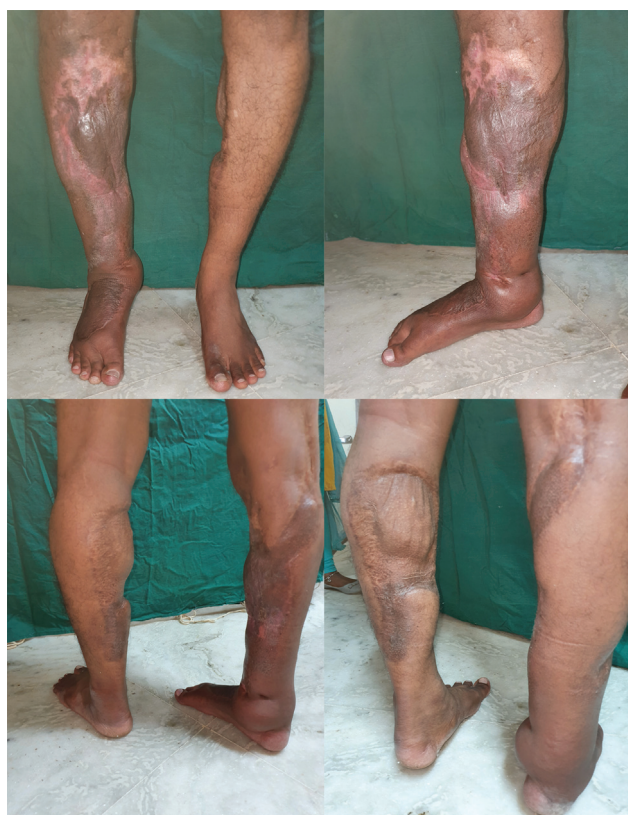

Fig. 7 Eight years follow-up images of ambulating patient after secondary Ilizarov procedure.

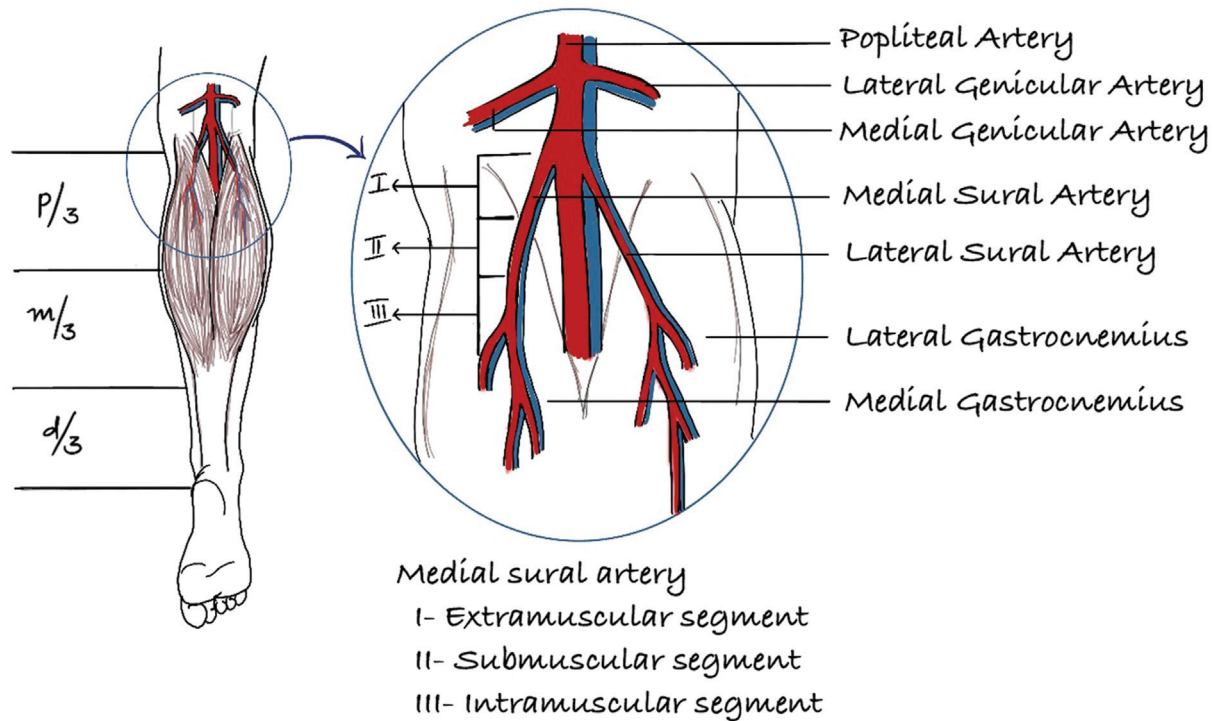


Fig. 8 Schematic depiction of the sural vessels and its parts to choose the anastomotic site appropriately.

the gastrocnemius and the tibia was used to expose and anastomose the medial sural artery; however, most of the cases required vein grafts.

Fu et al¹⁹ reported a similar approach without cutting the medial head of gastrocnemius muscle in seven cases of lower limb trauma. The distal flap could reach as far as talo-crural ligament in one case. They reported easy and direct visualization of vessel along medial border of the muscle. However, they cautioned about the small size of the vessel at this point and need for proximal dissection to improve vessels size; in fact, in one of their case, they had to shift from medial to posterior approach to ensure a sizeable artery for anastomosis. We have not preferred this vessel as a recipient vessel for defects extending beyond the distal third; for even in severe zone of trauma the anterior or posterior tibial arteries can be accessed reasonably safely at the junction of the upper and middle third of the leg.

The latissimus dorsi is the only large flap that can be elevated in the lateral position chosen for safely accessing the medial sural pedicle.

We used lateral position or semiprone position as discussed in the technique for the advantage of a two-team approach.

At a minimum, 5 cm of pedicle length below the popliteal crease could be dissected easily. Using the lateral gastrocnemius pedicle is an option for defects that are laterally placed, but one should be careful about the vessel kinking by the tibial nerve branches, if lateral vessel needs to be used for a medial defect.

Six of the eighteen cases had already been subjected to an unsuccessful primary operation without adequate wound coverage. There were two flaps that were lost: one was a diabetic with three attempts at arterial redo anastomosis on

table and in the other a possible cause was inadequacy of fixation across the knee that could have led to stretch of the arterial anastomosis causing thrombosis.

Despite the two failures, more than 88% of large proximal and middle third limb defects resulting from high velocity injuries had been successfully reconstructed, which we consider as a reasonably encouraging outcome to consider medial sural artery as a primary choice of recipient pedicle avoiding the need for other recipient pedicles and obligatory vein grafts.

Our experience reveals three portions to the medial sural vessel—a free-lying portion, the portion under the muscle (submuscular), and the intramuscular portion; coverage for middle third defects implies using the submuscular part of the vessel for assured distal flap reach (► Fig. 8).

Physical injury to the gastrocnemius muscle may preclude the use of this pedicle as a recipient pedicle and the smaller size of the vessel implies meticulous anastomotic technique to avoid occlusion.

Though our preference in free flaps for lower limb trauma is the anterolateral thigh flap, our technique of positioning for using the primary pedicle of the gastrocnemius restricts the choice of donor flap to the latissimus dorsi muscle, at least in the larger defects. We do agree that this could restrict the possibility of secondary flap elevation for the treatment of nonunions; when the defect is smaller, a thoracodorsal perforator flap is a possibility, with the provision that the donor site needs to be primarily closed.

Conclusion

Sural vessels are the lowest recipient pedicle among all the possible vessels described around the knee, to ensure

a more distal attainable flap reach for large proximal and middle third defects of the leg. The relatively superficial location of the vessel (in contrast to the proximal posterior tibial) implies easier access well away from the zone of trauma. Using the submuscular portion of the vessel makes flap reach to the junction of middle and lower third leg a certainty.

Lateral positioning permits simultaneous two-team approach, and either medial or lateral sural vessels can be approached through a common midline incision.

Conflict of Interest

None declared.

Acknowledgment

We would like to acknowledge procuring the ► **Fig. 8** from Dr B. Ashadeepthi.

References

- 1 Park S, Han SH, Lee TJ. Algorithm for recipient vessel selection in free tissue transfer to the lower extremity. *Plast Reconstr Surg* 1999;103(07):1937–1948
- 2 Stranix JT, Borab ZM, Rifkin WJ, et al. Proximal versus distal recipient vessels in lower extremity reconstruction: a retrospective series and systematic review. *J Reconstr Microsurg* 2018;34(05):334–340
- 3 Mathes SJ, Nahai F. Classification of the vascular anatomy of muscles: experimental and clinical correlation. *Plast Reconstr Surg* 1981;67(02):177–187
- 4 Taylor GI, Pan WR. Angiosomes of the leg: anatomic study and clinical implications. *Plast Reconstr Surg* 1998;102(03):599–616, discussion 617–618
- 5 Tsetsonis CH, Kaxira OS, Laoulakos DH, Spiliopoulou CA, Koutselinis AS. The arterial communication between the gastrocnemius muscle heads: a fresh cadaveric study and clinical implications. *Plast Reconstr Surg* 2000;105(01):94–98
- 6 Yazar S, Lin CH. Selection of recipient vessel in traumatic lower extremity. *J Reconstr Microsurg* 2012;28(03):199–204
- 7 Kolker AR, Kasabian AK, Karp NS, Gottlieb JJ. Fate of free flap microanastomosis distal to the zone of injury in lower extremity trauma. *Plast Reconstr Surg* 1997;99(04):1068–1073
- 8 Spector JA, Levine S, Levine JP. Free tissue transfer to the lower extremity distal to the zone of injury: indications and outcomes over a 25-year experience. *Plast Reconstr Surg* 2007;120(04):952–959
- 9 Fang T, Zhang EW, Lineaweaver WC, Zhang F. Recipient vessels in the free flap reconstruction around the knee. *Ann Plast Surg* 2013;71(04):429–433
- 10 Herrera FA, Lee CK, Kiehn MW, Hansen SL. The distal superficial femoral arterial branch to the sartorius muscle as a recipient vessel for soft tissue defects around the knee: anatomic study and clinical applications. *Microsurgery* 2009;29(06):425–429
- 11 Venkatramani H, Sabapathy SR, Nayak S. Free-flap cover of complex defects around the knee using the descending genicular artery as the recipient pedicle. *J Plast Reconstr Aesthet Surg* 2014;67(01):93–98
- 12 Dorfman DW, Pu LL. Using the descending branch of the lateral circumflex femoral artery and vein as recipient vessel for free tissue transfer to the difficult areas of the lower extremity. *Ann Plast Surg* 2013;70(04):397–400
- 13 Johnson PE, Harris GD, Nagle DJ, Lewis VL. The sural artery and vein as recipient vessels in free flap reconstruction about the knee. *J Reconstr Microsurg* 1987;3(03):233–241
- 14 Hallock GG. The medial approach to the sural vessels to facilitate microanastomosis about the knee. *Ann Plast Surg* 1994;32(04):388–393
- 15 Pyon JK, Ha BJ, Hyun WS, et al. Sural vessels as recipient vessels for free flap transfer to the single vessel leg. *J Korean Soc Plast Reconstr Surg* 1999;26:366–371
- 16 Beumer JD, Karoo R, Caplash Y, Semmler JG, Taylor J. The medial sural artery as recipient vessel and the impact on the medial gastrocnemius. *Ann Plast Surg* 2011;67(04):382–386
- 17 Smith ML, Molina BJ, Dayan E, Kim JN, Kagen A, Dayan JH. Use of distal medial sural vessels as recipient vessels in free tissue transfer. *J Reconstr Microsurg* 2017;33(01):59–62
- 18 Baliarsing A, Date S, Ciudad P, Ciudad P. Medial sural artery as a salvage recipient vessel for complex post traumatic microvascular lower limb reconstruction. *Microsurgery* 2018;38(02):157–163
- 19 Fu J, Gao J, Yi Y, et al. The clinical application of medial sural vessels as recipient vessels in repairing traumatic tissue defects in the lower limbs. *Ann Plast Surg* 2020;84(04):418–424