

A Rare Variant of Osteocutaneous Fibula Perforator from Posterior Tibial Artery

Shashank Lamba¹ Archa Kilikar¹ Amish J. Gohil¹ Ebenezer Asirvatham¹ Ashish K. Gupta¹

¹Department of Plastic and Reconstructive Surgery, Christian Medical College, The Tamilnadu Dr M.G.R. Medical University, Vellore, Tamil Nadu, India

Address for correspondence Shashank Lamba, MBBS, MS, MCH, Department of Plastic and Reconstructive Surgery, Christian Medical College, Vellore 632004, Tamil Nadu, India (e-mail: shashanklamba@gmail.com).

Indian J Plast Surg 2022;55:409–410.

The free fibula flap is one of the most versatile flaps with a skin paddle of variable blood supply. Here, we describe a rare anatomic variant of septocutaneous perforator and propose an addendum to the existing classification system to accommodate the variations of our case.

A 49-year-old gentleman with posttraumatic segmental defect of femur was planned for reconstruction with a vascularized free fibula flap. Intraoperatively, two perforators were identified, septocutaneous in the distal one-third and musculocutaneous in the middle one-third of the leg. Due to the long intramuscular course, the musculocutaneous perforator was ligated initially. After osteotomies, the septocutaneous perforator was dissected and was found to arise from posterior tibial artery (PTA), coursing between fibula and flexor hallucis longus (FHL) (► **Fig. 1**). The recipient site bony defect was reconstructed using 11-cm free vascularized fibula flap, fixed with plates, and anastomosed end-to-end with descending branch of lateral circumflex femoral artery.

To the best of our knowledge, this is the first report of a septocutaneous perforator in the distal half of the leg coursing through the posterior septum between the fibula and FHL and arising from the PTA. These variations require the surgeon to decide on the salvage options when encountered. In our case, as there was no skin defect, we decided to raise the flap as an osseous flap. The alternative option would have been a flow-through anastomosis in case skin paddle was required.

Yadav et al¹ proposed a classification system of the fibula skin vasculature which was based on the axial supply of the skin paddle into four types as follows: type A, supplied by peroneal vessels; type B, by peroneal vessels and posterior tibial vessels (PTV); type C, by PTV only; and type D, by popliteal artery only. This was further subcategorized by Parr et al² into subtypes A1, A2, A3, or B1, B2, B3, and C1, C2, and

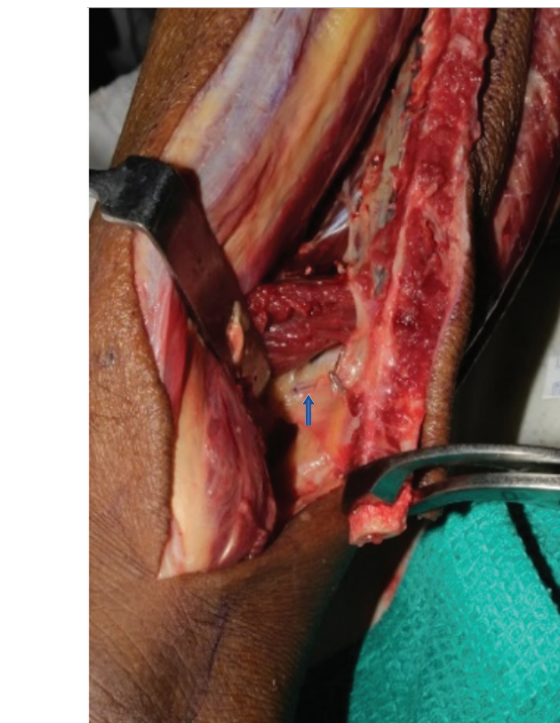

Fig. 1 Septocutaneous arising from the posterior tibial artery deep to FHL (blue arrow).

C3 based on the type of perforator (musculocutaneous and septocutaneous), source vessel of the skin paddle, and their variations and possible salvage measures.

Our case is an uncommon variant of septocutaneous perforator arising from the PTA coursing between the fibula and FHL (► **Fig. 2**). Based on existing classification systems, we were not able to classify any of them. Hence, we propose a new addition

article published online
December 22, 2022

DOI <https://doi.org/10.1055/s-0042-1760252>.
ISSN 0970-0358.

© 2022. Association of Plastic Surgeons of India. All rights reserved. This is an open access article published by Thieme under the terms of the Creative Commons Attribution-NonDerivative-NonCommercial-License, permitting copying and reproduction so long as the original work is given appropriate credit. Contents may not be used for commercial purposes, or adapted, remixed, transformed or built upon. (<https://creativecommons.org/licenses/by-nc-nd/4.0/>)

Thieme Medical and Scientific Publishers Pvt. Ltd., A-12, 2nd Floor, Sector 2, Noida-201301 UP, India

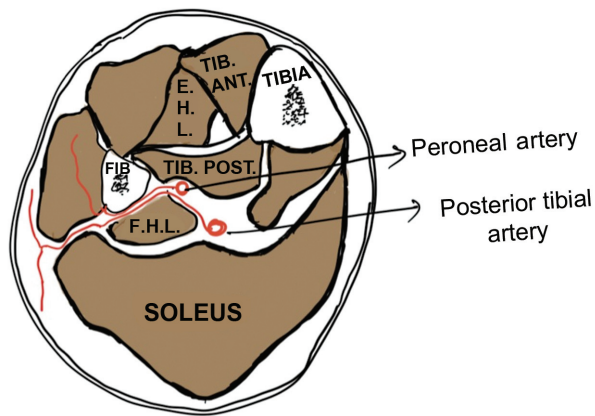


Fig. 2 Posterior tibial artery coursing between the fibula and FHL.

to the Parr classification of type C, subtype C4 as septocutaneous perforator running between fibula and FHL.

Posterior approach and awareness of all salvage options can help in avoiding a debacle.

Conflict of Interest
None declared.

References

- 1 Yadav PS, Ahmad QG, Shankhdhar VK, Nambi GI. Skin paddle vascularity of free fibula flap - A study of 386 cases and a classification based on contribution from axial vessels of the leg. *Indian J Plast Surg* 2012;45(01):58-61
- 2 Parr JM, Adams BM, Wagels M. Flow-through flap for salvage of fibula osseocutaneous vascular variations: a surgical approach and proposed modification of its classification. *J Oral Maxillofac Surg* 2014;72(06):1197-1202