



# Awake Aneurysm Clipping: Challenges Conquered

Kirandeep Kaur<sup>1</sup> Priya Thappa<sup>1</sup> Ankur Luthra<sup>2</sup> Rajeev Chauhan<sup>2</sup> Nidhi Panda<sup>1</sup>  
Sushanta K. Sahoo<sup>3</sup>

<sup>1</sup> Division of Neuroanaesthesia, Anaesthesia and Intensive Care, Post Graduate Institute of Medical Education & Research, Chandigarh, India

<sup>2</sup> Anaesthesia and Intensive Care, Post Graduate Institute of Medical Education & Research, Chandigarh, India

<sup>3</sup> Department of Neurosurgery, Post Graduate Institute of Medical Education & Research, Chandigarh, India

**Address for correspondence** Ankur Luthra, MD, DM, Anaesthesia and Intensive Care, Post Graduate Institute of Medical Education & Research, Chandigarh 160012, India  
(e-mail: zazzydude979@gmail.com).

J Neuroanaesthesiol Crit Care

## Abstract

Microsurgical aneurysm clipping under general anesthesia is considered a definitive procedure for the obliteration of unruptured and ruptured aneurysms. Aneurysm clipping can present with postoperative neurological complications, which can be missed under general anesthesia even with intraoperative neurophysiological monitoring. Real-time monitoring with awake patients can help prevent and treat these complications very early. The anesthesiologist has a vital role in awake aneurysm surgery from providing adequate surgical conditions to patient satisfaction and managing intraoperative complications. We report the first-hand experience as a neuroanesthesiology team managing awake craniotomy and aneurysm clipping.

## Keywords

- ▶ awake craniotomy
- ▶ dexmedetomidine
- ▶ unruptured and aneurysm clipping

## Introduction

Microsurgical clipping is the definitive procedure for the obliteration of unruptured and ruptured aneurysms. The inadvertent clipping of the parent and perforating vessels can lead to ischemia and postoperative deficits. The use of intraoperative electrophysiological (EP) monitoring has decreased the incidence of ischemic complications to 1 to 8%.<sup>1</sup> It is, however, associated with false-negative results.

An awake patient is the best monitor. Along with the motor deficits, we can also monitor for the nonmotor neurological deficits like altered mentation, aphasia, and lateral gaze limitation, which go undetected by EP monitoring. Unruptured aneurysm clipping in awake patients has been tried successfully, including the middle cerebral artery (MCA),<sup>2</sup> anterior choroidal artery,<sup>3</sup> and mycotic aneurysms.<sup>4</sup> Awake craniotomy is a surgical procedure performed for intracranial lesions where the patient is kept awake during the specific critical portions of the surgery. The aneurysm clipping is a challenging

chore and the patient being awake on the top of it makes it onerous. It requires allaying the anxiety, providing a comfortable environment, stringent hemodynamic control, and vigilant neurological and EP monitoring of the patient. We hereby report the first case in India for the awake craniotomy and clipping of unruptured MCA-bifurcation aneurysm under scalp block and conscious sedation.

## Case Report

A 37-year-old male weighing 60 kg with no known comorbidities had a history of rupture of right MCA-bifurcation aneurysm managed with microsurgical clipping 2 years ago. Additionally, one unruptured left MCA-B aneurysm, measuring 5.1\*4.3 mm (anteroposterior diameter\*transverse diameter) with a neck of 4 mm, was discovered at that time (▶ **Fig. 1**). The patient had now presented for clipping of this unruptured left MCA-B aneurysm. The patient was on tablet levetiracetam 500 mg twice daily. Considering the risk of inadvertent

DOI <https://doi.org/10.1055/s-0042-1760269>.  
ISSN 2348-0548.

© 2023. The Author(s).

This is an open access article published by Thieme under the terms of the Creative Commons Attribution License, permitting unrestricted use, distribution, and reproduction so long as the original work is properly cited. (<https://creativecommons.org/licenses/by/4.0/>)

Thieme Medical and Scientific Publishers Pvt. Ltd., A-12, 2nd Floor, Sector 2, Noida-201301 UP, India

clipping of the perforators leading to the infarction of the internal capsule and subsequent hemiplegia, the patient was planned for aneurysm clipping through a pterional approach using the awake technique.

A detailed preanesthetic check-up was done. The patient was conscious, oriented, and cooperative with his vitals, neurological examination, and blood investigations within normal limits. The patient was counselled regarding the plan of surgery and anesthesia and the need, benefit, and risks of awake surgical procedure. The awake technique was planned using a combination of scalp blocks and monitored anesthesia care. He was kept nil per oral as per standard American Society of Anesthesiologists (ASA) fasting guidelines. Tablet alprazolam 0.5 mg and ranitidine 50 mg were given orally at night and early morning of the surgery with a sip of water. He was wheeled into the operating room, and ASA standard monitors were attached. He had a baseline blood pressure of 128/72 mm Hg in right arm supine, and a heart rate of 66 bpm. Oxygen was delivered through nasal prongs at 2 l/min. Patient was sedated, targeting a BIS (bispectral index) of less than 70 using inj. fentanyl 60 µg and a loading dose of 60 µg of dexmedetomidine over 10 minutes followed by infusion at 30 µg/hr.

Under sedation, the left radial artery was cannulated, the urinary bladder was catheterized, and a dense scalp block was given. A total of 30 mL of the cocktail drug (15 mL bupivacaine 0.5% + 15 mL lignocaine 2% with adrenaline 1:200000 + ketamine 30 mg) was used for scalp block. Using the landmark technique, bilateral scalp block was given targeting the supratrochlear, supraorbital, zygomatic, auriculotemporal, posterior auricular, lesser and greater occipital nerve. The effect of the block was checked with a pinprick. A four-pin head frame was used, and the patient was positioned supine with a slight head flexion and rotation of 30 degrees to the right. All the pressure points were adequately padded, and a sandbag was placed under the left shoulder to prevent stretch on the brachial plexus.

A drape canopy was made to ensure adequate exposure of the patient's face for communication and monitoring. Inj. cefuroxime 3 gm was given after sensitivity testing, and inj. dexamethasone 8 mg, inj. ondansetron 4 mg, inj. mannitol 60 g, and inj. levetiracetam 500 mg were given intraoperatively. A total of 1.5 L of NaCl 0.9% was given as guided by the systolic pressure variation and pulse pressure variation. During the craniotomy, the dexmedetomidine infusion (0.2–0.7 µg/kg/hr) was continued and titrated according to the patient's response and we maintained a BIS of 70 to 80. Once the craniotomy was done, dexmedetomidine infusion was stopped, and communication with the patient was established. During the temporary clipping (TC), the patient was continuously monitored for any neurological deficit by looking for any movement abnormalities, monitoring his sensorium and checking his motor power in the right upper limb and right lower limb.

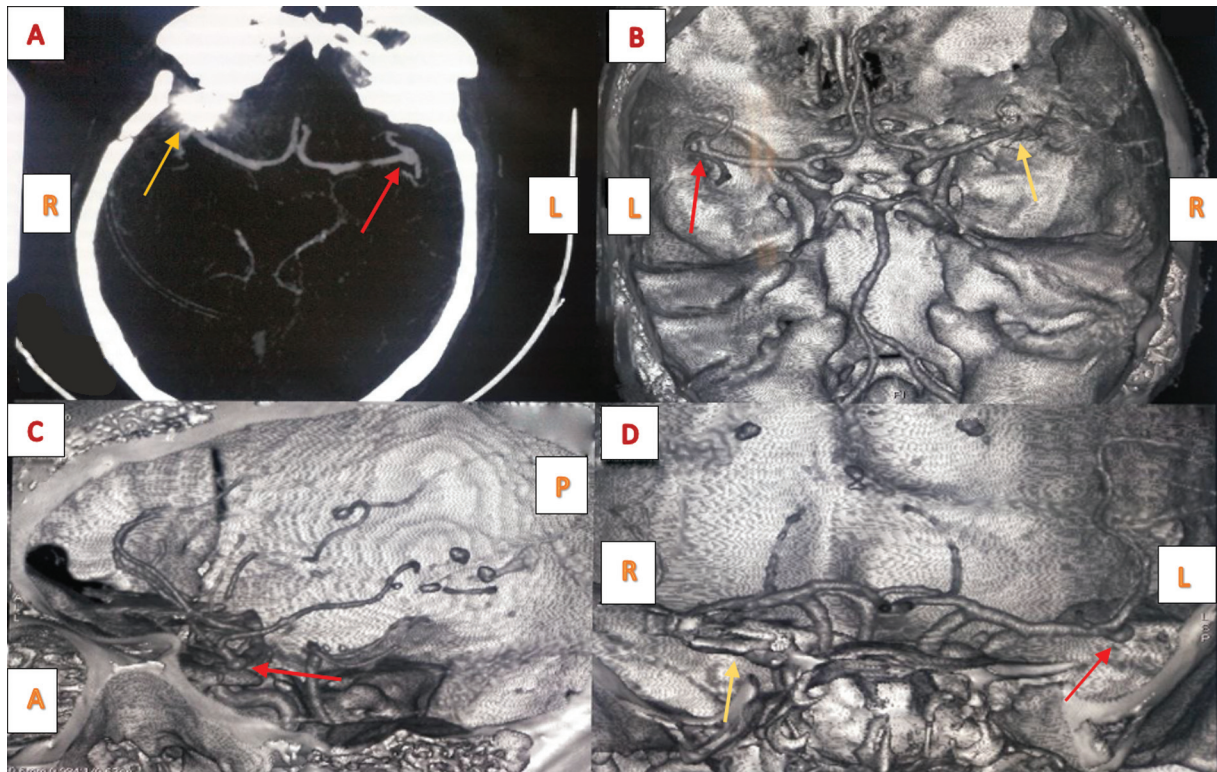
The TC was applied only once for 1 min, 25 sec. And during this time, the mean arterial pressure was raised about 15% above the baseline prophylactically. The patient responded normally during this time, having no changes in his sensorium or motor status. After applying the permanent clip, the patient was again closely monitored for any deficits for 10 minutes.

The intravenous bolus of indocyanine dye confirmed the adequate and correct placement of the permanent clip, and the craniotomy was closed. At the end of the surgery, the patient was alert and satisfied with the anesthesia technique and immediate surgical outcome and analgesia. Apart from the starting dose of fentanyl 60 µg, he did not require any opioid supplementation. He was shifted to postanesthesia care unit for observation for another 3 hours. During his stay in the postanesthesia care unit, his vitals, Glasgow coma scale, and motor power were monitored for 10 minutes. Postoperatively, the noncontrast computed tomography head was done as per the institutional protocol and was shifted to the high dependency unit (HDU). In HDU, the patient stayed comfortable without any complications. The postoperative pain was assessed using the numeric rating scale (NRS). The first analgesia requirement was at the 16th hour postoperatively with a maximum NRS of 6. We attributed the prolonged postoperative pain-free period to a well-applied scalp block with ketamine as the adjuvant. His further hospital stay of 3 days was uneventful, and he was discharged on postoperative day 4 without any neurological deficit.

## Discussion

About 14 to 43% of all cerebral aneurysms are MCA aneurysms<sup>5</sup>, and approximately 17.8% are found to have bilateral MCA aneurysms.<sup>6</sup> There is a 0 to 8% annual risk of spontaneous rupture, with the tendency of rupture increasing with the size of the aneurysm.<sup>7</sup> Unruptured aneurysms can also be an incidental finding and carry a good prognosis when taken care of early. Despite the development of neurosurgical techniques and the use of impeccable intra-operative EP monitoring, the inadvertent clipping of the parent vessels or the perforators can have devastating consequences.

Awake craniotomy and clipping offer the advantage over the clipping done under general anesthesia in terms of early detection of neuro deficits and timely intervention for the deficits that could have been missed otherwise. The goals of anesthesia in such patients are to maintain hemodynamic stability and cerebral homeostasis, provide adequate anxiolysis and analgesia to the patient, keep the patient awake for the neurological testing, especially at the time of clipping, and prevent and manage intraoperative complications of ischemia and intraoperative rupture. Utmost care must be taken in the anesthetic induction and surgery under general anesthesia as any undue hemodynamic surge can lead to intraoperative rupture. The risk is unduly high during the critical points of intense stimulation. Laryngoscopy and intubation, the first point of intense stimulation, can cause substantial hemodynamic perturbations, which can be avoided using the regional anesthesia technique. At the time of TC application, real-time monitoring of the patient instead of surrogates in the form of intra-operative neurophysiological monitoring (IONM) can be of immense use to improve the patient's outcome. Ketamine was added in the drug cocktail for scalp block as in ketamine subanesthetic dose of 0.2 mg/kg provides good analgesia and also when used as an adjuvant prevents the postcraniotomy pain.<sup>8</sup> We suggest that the



**Fig. 1** Postclipping status of right middle cerebral artery (MCA) bifurcation aneurysm with clip in situ and associated streak artefact (yellow arrow) and left MCA bifurcation aneurysm (red arrow) seen in maximum intensity projection reconstructed axial section (A) and volume-rendered reconstructed images in axial, sagittal, and coronal planes (B–D). L, left; R, right; A, anterior; P, posterior.

addition of ketamine in the local anesthetic might have prolonged the effect of the block keeping the patient pain-free till the 16th postoperative hours. Awake clipping under scalp block also decreases the poly-pharmacy during the intraoperative and postoperative course, decreasing the post-operative nausea and vomiting and allowing the earlier institution of feeding and ambulation. It also reduces mortality, morbidity, and hospital stay. It can also decrease the financial burden on the patient by shortening the hospital stay. EP monitoring under general anesthesia is another alternative being used to decrease the incidence of postoperative deficits. However, it is associated with false-negative results, which may be due to inadequate stimulation or high-intensity stimulation,<sup>9</sup> decreased signal transmission, and delayed perfusion deficits caused by hypotension and cerebral edema after the removal of EP monitoring.<sup>10</sup> Its use also increases the cost of treatment as compared to awake clipping that is inexpensive.

However, several challenges and complications can be encountered during this procedure. The anesthesiologist must know the anticipated difficulties and complications and have the necessary plans and equipment for troubleshooting. Since the successful management of such cases needs the patient's absolute cooperation, the patient needs to be calm, comfortable, and free of anxiety. Establishing a good rapport with the patient and prescribing antianxiety drugs can be helpful. Although the procedure is conducted under scalp block, general anesthesia and airway equipment drugs should be ready. The catastrophe of intraoperative rupture of an aneurysm should be anticipated, and readiness

for it should be ensured. It can lead to sudden neurological and hemodynamic deterioration. Securing the airway in a draped patient can be difficult. Supraglottic airway devices act as a rescue for such emergencies. As for any other awake craniotomy procedure, cold saline and benzodiazepines should be kept ready in case of seizures occur during surgery. To conclude, awake craniotomy with clipping of an aneurysm is a procedure that demands highly skilled multidisciplinary teamwork. Awake clipping of aneurysms should not be attempted in patients with complex aneurysm architecture, significant intraoperative rupture risk, uncooperative patients, or planned lengthy procedures. Hence, the optimum patient selection is of utmost importance and a successful procedure can bless the patient with deficit-free life.

#### Conflict of Interest

None declared.

#### References

- 1 Park D, Kim BH, Lee SE, et al. Usefulness of intraoperative neurophysiological monitoring during the clipping of unruptured intracranial aneurysm: diagnostic efficacy and detailed protocol. *Front Surg* 2021;8:631053
- 2 Passacantilli E, Anichini G, Cannizzaro D, et al. Awake craniotomy for trapping a giant fusiform aneurysm of the middle cerebral artery. *Surg Neurol Int* 2013;4:39
- 3 Suzuki K, Mikami T, Sugino T, et al. Discrepancy between voluntary movement and motor-evoked potentials in evaluation of motor function during clipping of anterior circulation aneurysms. *World Neurosurg* 2014;82(06):e739–e745

- 4 Lüders JC, Steinmetz MP, Mayberg MR. Awake craniotomy for microsurgical obliteration of mycotic aneurysms: technical report of three cases. *Neurosurgery* 2005;56 (1, Suppl):E201
- 5 Yang W, Huang J. Treatment of middle cerebral artery (MCA) aneurysms: a review of the literature. *Chin Neurosurg J.* 2015;1(01):1–7
- 6 Rinne J, Hernesniemi J, Niskanen M, Vapalahti M. Analysis of 561 patients with 690 middle cerebral artery aneurysms: anatomic and clinical features as correlated to management outcome. *Neurosurgery* 1996;38(01):2–11
- 7 Morita A, Kirino T, Hashi K, et al; UCAS Japan Investigators. The natural course of unruptured cerebral aneurysms in a Japanese cohort. *N Engl J Med* 2012;366(26):2474–2482
- 8 Luthra A, Rath GP. Ketamine: a neuroanesthesiologist's friend or foe? *J Neuroanaesth Crit Care* 2018;5(02):77–82
- 9 Rothwell J, Burke D, Hicks R, Stephen J, Woodforth I, Crawford M. Transcranial electrical stimulation of the motor cortex in man: further evidence for the site of activation. *J Physiol* 1994;481(Pt 1): 243–250
- 10 Choi HH, Ha EJ, Cho WS, Kang HS, Kim JE. Effectiveness and limitations of intraoperative monitoring with combined motor and somatosensory evoked potentials during surgical clipping of unruptured intracranial aneurysms. *World Neurosurg* 2017; 108:738–747