



Imaging Recommendations for Diagnosis, Staging, and Management of Hepatic and Biliary Tract Cancer

Argha Chatterjee¹ Sumit Mukhopadhyay¹ Priya Ghosh¹ Diva Shah² Anisha Gehani¹
Akshay Baheti³ Bharat Gupta¹ Aditi Chandra¹ Arvind K. Chaturvedi⁴ Jeevitesh Khoda⁵
Anurima Patra¹ Dayananda Lingegowda¹ Saugata Sen¹

¹ Department of Radiology and Imaging Sciences, Tata Medical Center, Kolkata, West Bengal, India

² Department of Radiology, HCG Cancer Centre, Ahmedabad, Gujarat, India

³ Department of Radiodiagnosis, Tata Memorial Hospital, Homi Bhabha National Institute, Mumbai, Maharashtra, India

⁴ Department of Radiology and Interventional Oncology, Rajiv Gandhi Cancer Institute and Research Center, New Delhi, India

⁵ Department of Radiology, Rajiv Gandhi Cancer Institute and Research Center, New Delhi, India

Address for correspondence Argha Chatterjee, MD, Department of Radiology and Imaging Sciences, Tata Medical Center, Kolkata, West Bengal, India (e-mail: arghachat84@gmail.com).

Ind J Med Paediatr Oncol 2023;44:241–250.

Abstract

Keywords

- ▶ cholangiocarcinoma
- ▶ computed tomography
- ▶ gallbladder carcinoma
- ▶ hepatocellular carcinoma
- ▶ magnetic resonance imaging

Major hepatobiliary cancers include hepatocellular carcinoma, gallbladder carcinoma, and cholangiocarcinoma. There are multiple guidelines and recommendations for the imaging evaluation of these cancers. This article reviews and summarizes principles and recommendations of imaging in hepatobiliary cancers. The cross-sectional imaging protocol is similar among these lesions and is discussed at first followed by the separate discussion of each cancer.

Introduction

Major hepatobiliary cancers include hepatocellular carcinoma (HCC), gallbladder carcinoma, and cholangiocarcinoma (CCA). There are multiple guidelines and recommendations for the imaging evaluation of these cancers. This article reviews and summarizes principles and recommendations of imaging in hepatobiliary cancers. The cross-sectional imaging protocol is similar among these lesions and is discussed at first followed by the separate discussion of each cancer. Authors have reviewed existing international and Indian guidelines includ-

ing but not limited to National Comprehensive Cancer Network (NCCN), American Society of Clinical Oncology (ASCO), American College of Radiology (ACR), Indian Council for Medical Research (ICMR), and Indian College of Radiology and Imaging (ICRI). Imaging recommendations that are unequivocally mentioned in the majority of guidelines are included in this article. In the presence of conflicting or absent recommendations, authors have reviewed the existing literature, achieved a consensus regarding the issue in question, and, based on current evidence and their experience, provided recommendations following a short discussion.

DOI <https://doi.org/10.1055/s-0042-1760320>.
ISSN 0971-5851.

© 2023. The Author(s).

This is an open access article published by Thieme under the terms of the Creative Commons Attribution License, permitting unrestricted use, distribution, and reproduction so long as the original work is properly cited. (<https://creativecommons.org/licenses/by/4.0/>)
Thieme Medical and Scientific Publishers Pvt. Ltd., A-12, 2nd Floor, Sector 2, Noida-201301 UP, India

Imaging Protocol in Hepatobiliary Cancer

Ultrasound of Whole Abdomen

Ultrasound of the upper abdomen is the modality of choice for screening of at-risk patients for liver cancer. Ultrasound does not have any role in diagnosis of liver lesions except as a guide to biopsy and other interventional procedures.

Computed Tomography Scan of the Whole Abdomen with Contrast

1. Noncontrast phase: For identification of fat, iron, calcification, blood products, and iodized oil (after chemoembolization). Necessary for generation of subtraction images.
2. Early arterial phase (15–20 seconds, for all cases): Identified by complete enhancement of aorta and hepatic arteries and no or minimal enhancement of portal vein. This is important for arterial anatomy that is essential for surgical planning.
3. Late arterial phase (35–40 seconds, for suspected hepatocellular cancers): Identified by complete enhancement of hepatic arteries and streaky partial enhancement of portal vein. Early arterial enhancement of HCC is best visualized in this phase.
4. Portal venous phase (75–90 seconds): Identified by complete enhancement of portal vein and partial enhancement of hepatic veins. Some enhancement of hepatic veins is essential for surgical planning and volumetry.
5. Delayed phase (120–300 seconds): Only necessary for hepatic venous anatomy and to rule out suspected hemangioma.
6. Contrast dose: A total of 1.8 to 2 mL/kg of 300 to 350 mg iodine/mL contrast through antecubital vein with a flow rate of at least 3 mL/s (Optimal contrast flow rate is crucial for arterial phase images. One may consider lower flow rate if the disease is already metastatic and information regarding vascular anatomy and vascular involvement is not critical).
7. Coverage of the whole abdomen from diaphragm to symphysis pubis is recommended to screen for peritoneal metastasis.
8. Slice thickness: 2/3 mm, slice interval: 0 mm.
9. Neutral oral contrast with 350 to 500 mL of water immediately to 15 minutes before computed tomography (CT) (optional). Positive oral contrast is discouraged.
10. Multiplanar reformat in coronal and sagittal is critical (thickness: 2 mm, interval: 0 mm).

Multiphasic Magnetic Resonance Imaging with Contrast

It is used as a problem solving tool in biliary tract cancers and can be used as a primary diagnostic modality in suspected HCC or intrahepatic cholangiocarcinoma (IHCC).

1. Minimum required sequences:
 - a. Axial and coronal T2-weighted.
 - b. Axial diffusion-weighted imaging.
 - c. Axial T1-weighted in and opposed phase images: for intralesional fat.

- d. Axial and coronal T1-weighted (VIBE/LAVA) precontrast, multiphasic arterial, portal venous, and delayed phase. In magnetic resonance imaging (MRI), multiple arterial phases are acquired in tandem. The timing of the rest of the phases is similar to that of CT. It is very important to generate subtraction images from post-contrast images to look for residual enhancement in treated liver nodules.
- e. Thin-slab and thick-slab magnetic resonance cholangiography (MRCP) (HASTE/SSFSE/RARE) and three-dimensional MRCP (for biliary tract tumors).
- f. If gadobenate dimeglumine is used as an intravenous contrast, then a hepatobiliary phase taken at 45 to 90 minutes is useful.
- g. Technical requirements:
 - i. High field strength magnet (> 1.5 Tesla).
 - ii. Phased array multichannel torso coil.
 - iii. Contrast: Both extracellular contrast agent (e.g., gadovist, gadobutrol, gadoterate, etc.) or hepatobiliary contrast agent (gadobenate dimeglumine) are acceptable. Contrast dose 0.1 mmol/kg.

Hepatocellular Carcinoma

Risk Factors and Etiopathogenesis

Cirrhosis of the liver is the single most important risk factor for HCC. In India, 70 to 97% of patients with HCC at the time of diagnosis had underlying cirrhosis of the liver.¹ Other important risk factors are chronic hepatitis B and C infection, alcoholic liver disease, and nonalcoholic fatty liver disease.² In India, hepatitis B virus (HBV), particularly genotype D is most commonly implicated in chronic hepatitis-related HCC.³

Epidemiology, Clinical Presentation in India and Global

Worldwide, HCC accounts for 90% of cancers of the liver. It is the third leading cause of cancer-related death annually and constitutes the fifth most common cancer globally.⁴ In India, age-adjusted incidence rate of liver cancer 0.7 to 7.5 in men and 0.2 to 2.2 in women per 100,000 population per year.¹ Based on a prospective observational study from North India, the annual incidence rate of HCC in cirrhotic patients is 1.6%.⁵ The incidence of liver cancer in India is increasing.⁶ The age standardized mortality rate is reported to be 6.8/100,000 population in men and 5.1/100,000 population in women.⁷ The incidence of liver cancer increased with increasing age, with a median age at presentation of 40 to 70 years. It is four times more common in men.

Imaging Referral Guidelines

The imaging referral algorithm for HCC in at-risk patients is demonstrated in **Fig. 1**.

Clinical/Diagnostic Workup Excluding Imaging

Along with estimation of functional status of the patient and staging of the tumor, the following workup is recommended:

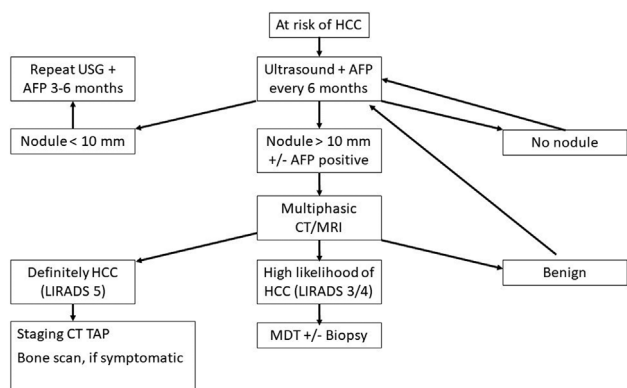


Fig. 1 Imaging referral algorithm in hepatocellular carcinoma (HCC) in at-risk patients. Modified from National Comprehensive Cancer Network (NCCN) guidelines.

- Serology for HBV and hepatitis C virus (HCV) (hepatitis B surface antigen [HBsAg], immunoglobulin G [IgG]/total-HBc, anti-HBs, anti-HCV). If HBsAg is positive, then hepatitis B e-antigen, anti-HBe antibody, and HBV-deoxyribonucleic acid levels are estimated. If anti-HCV is positive, then HCV genotype and HCV-ribonucleic acid levels are estimated.
- Liver function test (LFT), for assessment liver functional reserve (Child–Pugh score or Model for End-Stage Liver Disease score) and surgical planning.
- Assessment of portal hypertension (upper gastrointestinal endoscopy for varices and hepatic venous pressure gradient measurement).
- Chest CT, with or without contrast.
- Bone scan in presence of bone symptoms.
- Positron emission tomography (PET)-CT is not recommended.

Imaging Guidelines

Screening

ICMR has recommended surveillance with a 6-monthly ultrasound examination of the liver by an experienced radiologist. Doppler ultrasound may be added for better detection of new thrombus in hepatic or portal vein. Candidates for surveillance include those with Child A and B cirrhosis of any etiology and Child C patients on the waiting list for a liver transplantation. Non-cirrhotic patients with chronic hepatitis B (males > 40 years and females > 50 years), chronic HBV infection of any age with family history of HCC, or chronic HCV with advanced fibrosis are candidates for surveillance⁸ (ICMR 2019). Although

Chart 2 US-LIRADS category

Category	Description	Recommendation
US-LIRADS 1, negative	No or benign observation	Routine follow-up
US-LIRADS 2, subthreshold	Observation < 10 mm	Ultrasound at 3 mo
US-LIRADS 3, positive	Observation > 10 mm or new thrombus in a vein	Multiphasic CT or MRI

Abbreviations: CT, computed tomography; MRI, magnetic resonance imaging; US-LIRADS, Ultrasound Liver Reporting and Data System.

ICMR does not recommend serum alpha-fetoprotein (AFP) as a screening method, addition of serum AFP has been shown to increase sensitivity of HCC detection in at-risk patients and NCCN has recently recommended addition of AFP in their 2021 guidelines.^{9,10} ACR recommends use of a standard Ultrasound Liver Reporting and Data System (US-LIRADS) for the reporting of surveillance ultrasound examination. Quality or adequacy of the diagnostic ultrasound examination can be reported with a visualization score (**Chart 1**). If an observation of size > 10 mm is visualized on ultrasound, further evaluation with multiphasic CT or MRI is warranted. Final ultrasound can be reported with an US-LIRADS score (**Chart 2**).¹¹

Diagnosis (Including Interventions)

Noninvasive characterization of a liver nodule can lead to a definitive diagnosis of HCC if the patient is considered to have high risk of HCC, that is, cirrhosis, chronic hepatitis B infection, and current/prior HCC. For nodules < 1 cm in size, further characterization by imaging or biopsy is of limited value and follow-up at 3 to 6 monthly intervals for 2 years is recommended.

For nodules > 1 cm, multiphase CT (with iodinated contrast) or multiphase MRI with gadolinium-based contrast are investigations of choice. Use of hepatocyte-specific gadolinium-based agents (gadobenate dimeglumine) is not mandatory but may have additional value. Liver Imaging Reporting and Data System and American Association for the Study of Liver Diseases have adopted imaging criteria for diagnosis of HCC. In a nodule that shows non-rim arterial phase hyper-enhancement, presence of at least one major feature in nodules > 2 cm and presence of two or more major features in nodules measuring 1 to 1.9 cm is diagnostic of HCC in a

Chart 1 Ultrasound visualization score—US-LIRADS

Score	Description	Explanation
A	No or minimal limitation. No limitation to sensitivity of detecting small nodules.	Nearly the entire liver is visible with homogeneous echotexture
B	Moderately limited sensitivity to detect small nodules	Moderately echogenic liver when a part of liver or diaphragm is not visible
C	Severely limited sensitivity to detect liver nodules	Severely heterogeneous liver with ultrasound attenuation and > 50% liver or diaphragm is not visible

Abbreviation: US-LIRADS, Ultrasound Liver Reporting and Data System.

patient with high risk of HCC. Major features include wash-out in delayed phase, presence of enhancing capsule, and threshold growth.^{12,13} Specific criteria is described for major venous invasion by the tumor.

Calculation of liver remnant by CT volumetry is necessary in surgically resectable cases.

Tissue diagnosis is reserved for following situations:

- High suspicion of malignancy but the lesions does not meet imaging criteria for HCC.
- Lesion meets criteria for HCC but the patient is not considered high risk for HCC.
- Lesion meets criteria for HCC but the patient has cardiac cirrhosis, congenital hepatic fibrosis, or cirrhosis due to vascular disorders such as Budd–Chiari syndrome.
- Elevated CA19–9 or carcinoembryonic antigen (CEA) raising suspicion of IHCC.

Tissue diagnosis should be obtained by ultrasonography (USG) or CT-guided needle core biopsy. Multidisciplinary discussion is recommended before biopsy in patients who are candidates for hepatic resection, liver transplant (LT), or curative ablative therapy.¹⁰

Staging

The Barcelona Clinic Liver Cancer (BCLC) staging system is most widely used. It takes into account tumor number, size, liver function, and patients’ performance status. BCLC also recommends a treatment strategy (→ Fig. 2).

Management—Role of Interventional Radiology

Role of interventional radiology (IR) is increased in the 2022 update of the BCLC recommendations. In BCLC 0, ablation is the treatment of choice. Resection should be considered only when ablation is not feasible. Transarterial chemoembolization (TACE) and transarterial radioembolization (TARE) can also be considered. TARE is to be used in single lesions that are less than 8 cm.¹⁴ In BCLC-A with single lesions, resection is favored in tumors up to 2 cm in size. For larger lesions, TARE can be considered in case the remnant liver is small. In multiple lesions with increased portal pressure or high bilirubin, ablation is recommended. For patients with > 3 lesions, TACE and TARE may be indicated. In LT candidates with > 6 months waiting time, ablation, TACE, or TARE can be used for bridging. BCLC-B patients with preserved portal flow and well-defined lesions TACE is recommended. Some cases of BCLC-B can still be considered for LT if they meet local practice guidelines. Some advanced cases of stage B may be downstaged to become eligible for LT through TACE or TARE and systemic therapies.¹⁵

Response Assessment

For follow-up of locoregional and systemic therapy in HCC, modified Response Evaluation Criteria in Solid Tumors (mRECIST) is recommended over RECIST 1.1 guidelines in early and intermediate cases. In advanced cases, both methods can be used.¹⁶ mRECIST takes into account the concept of “viable” tumor. After locoregional and systemic therapy in HCC,

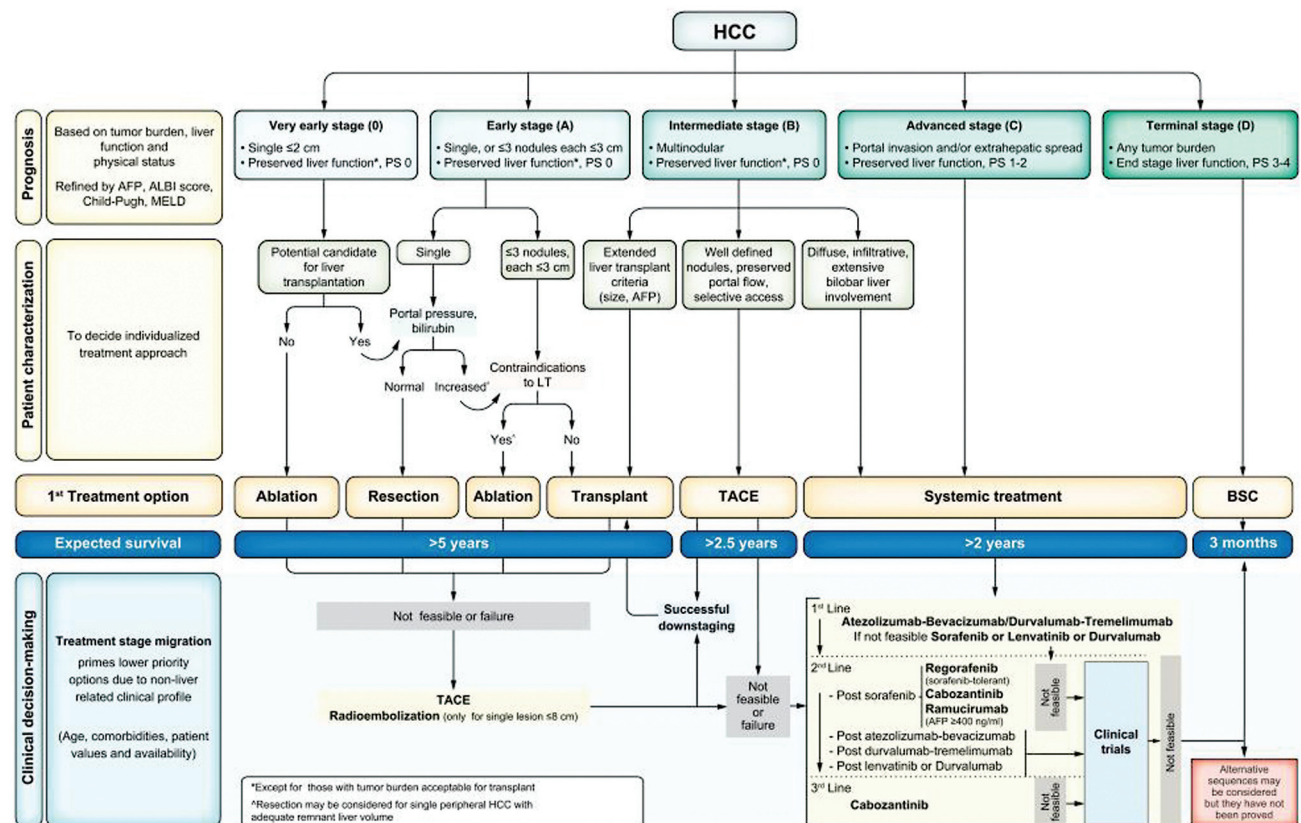


Fig. 2 Barcelona Clinic Liver Cancer (BCLC) staging system and treatment strategy.

many lesions do not show tumor shrinkage but show necrosis which is defined by loss of enhancement. mRECIST advocates measurement of enhancing or “viable” tumors only. Furthermore, enlargement of portal nodes and ascites/pleural effusion can also be a part of the chronic liver disease process and adjustments are made in this criteria to prevent overdiagnosis of disease progression.

mRECIST:

- Selection and measurement of target lesions:
 - Typical intrahepatic target lesion: ≥ 1 cm, intratumoral arterial phase enhancement.
 - Atypical intrahepatic target lesion: ≥ 1 cm, no arterial phase enhancement.
 - Extrahepatic target lesion, non-nodal: ≥ 1 cm longest axis.
 - Extrahepatic target lesion, nodal: ≥ 2 cm short axis if portal node, 1.5 cm short axis for nodes elsewhere.
 - Target lesions should be suitable for accurate and repeat measurement. Total number of target lesions should not exceed five with no more than two lesions per organ.
 - For hepatic targets, the longest diameter of the viable (arterially enhancing) tumor is measured. For extrahepatic non-nodal targets, the longest diameter is measured and for nodal lesions, the short axis diameter is measured.
- For baseline assessment sum of diameters of all target lesions are measured. The disease status on follow-up images is assessed using criteria similar to RECIST 1.1 (► **Table 1**). Follow-up is usually done at 6 to 8 weeks intervals.
- For immunotherapy, mRECIST criteria can be applied with a longer follow-up interval of 8 to 12 weeks since immunomodulating agents take longer to show tumor response.

Follow-Up

Resected lesions or post-LT cases should undergo multiphasic CT/MRI of upper abdomen, chest CT, and complete abdominopelvic CT/MRI every 3 to 6 months for 2 years and every 6 to 12 months thereafter along with serum AFP measurement.

Principles of Management

Imaging not only helps in local and metastatic staging of HCC, it also provides crucial information regarding the status of underlying liver disease. Presence of bland thrombus in the portal or superior mesenteric vein significantly alters surgical or local treatment decision. Presence of ascites and large

portosystemic shunt indicate hepatic decompensation and potentially high portal venous pressure. IR helps in direct measurement of portal venous pressure as well.

LT is indicated in BCLC 0, A, and some cases of B stage provided transplant is feasible. In stage B with multiple lesions TACE can be considered. For other cases of stage B and all cases of stage C are considered for systemic chemotherapy. ASCO recommends atezolizumab and bevacizumab combination as a first-line therapy after esophageal varices are managed.¹⁷ Sorafenib and lenvatinib is recommended as a second-line therapy. Stereotactic body radiotherapy is a treatment option in liver-limited disease with one to three lesions in cases with Child A or B cirrhosis that are unresectable. It can be used as an alternative to local ablative therapies or when these treatments have failed.¹⁸

Gallbladder Carcinoma

The most common histopathology of gallbladder cancer (GBC) is adenocarcinoma. The following discusses adenocarcinoma of gallbladder.

Risk Factors and Etiopathogenesis

Risk factors of GBC include gallstone, chronic inflammation, gallbladder polyp, primary sclerosing cholangitis, and obesity.¹⁹

Epidemiology, Clinical Presentation in India and Global

GBC is the only digestive cancer with a higher incidence in women. Women have two to six times higher risk of developing GBC than men.²⁰ It is more common in South American countries such as Chile and Bolivia and Asian countries such as Nepal and Bangladesh. In India, GBC is most common in North and Eastern India in the Gangetic plains and relatively less common in Western and Southern states. Incidence of GBC can be as high as 8.8 to 17.1/million population in Northern India. Age of presentation in Indian patients is earlier than that of Western population and it is usually in the 5th to 6th decade.²¹

Twenty-seven to 41% of patients of all GBC are incidentally detected during or after routine cholecystectomy (postop biopsy) for gallstone-related or benign gallbladder disease.²² This category is named *incidental GBC* (IGBC). Rest of the cancers can present with nonspecific abdominal symptoms such as dyspepsia and abdominal pain and a mass is detected at initial imaging. Advanced diseases can present with obstructive jaundice or ascites.

Table 1 mRECIST criteria

Complete response	No intraluminal arterial enhancement in all hepatic typical target and disappearance of atypical hepatic target and all extrahepatic target lesions
Partial response	$\geq 30\%$ reduction in sum of diameters of all viable (arterially enhancing) target lesions
Stable disease	Not classifiable as partial response or progressive disease
Progressive disease	$\geq 20\%$ increase in sum of diameters of all viable (arterially enhancing) target lesions

Abbreviation: mRECIST, modified Response Evaluation Criteria in Solid Tumors.

Imaging Referral Guidelines

Diagnosis of GBC is initially made by ultrasound as a gallbladder fossa mass or biliary obstruction. For assessment of operability and follow-up, CT or MRI or both are performed. Multiphasic contrast imaging is essential. For staging contrast-enhanced CT thorax is necessary. PET-CT has limited sensitivity in the detection of occult metastatic local or peritoneal metastatic disease when compared with surgical or laparoscopy findings.²³ PET-CT may have some role in detecting occult metastases in retroperitoneal nodes and liver in locally advanced GBC; however, data on predictive value in comparison to diagnostic laparoscopy is limited. In IGCB, PET-CT has similar positive predictive value compared with CT in the determination of resectability (HPB 2008;10:439). Therefore, the ICRI and NCCN do not recommend PET-CT for the staging of GBC and current authors concur.

Image-guided biopsy or fine-needle aspiration cytology (FNAC) are not performed in operable lesions to avoid tract dissemination. However, image-guided FNAC/biopsy is usually needed before any chemotherapy radiation in unresectable tumors.

Clinical/Diagnostic Workup Excluding Imaging

- LFT.
- Consider serum CEA, CA 19–9.
- Staging laparoscopy in operable lesions to rule out peritoneal metastases.

Imaging Guidelines

- USG is the initial modality of choice to image a suspected case of GBC. Once there is a mass detected, multiphasic CT is needed for initial staging and operability assessment.
- Multiphasic CT abdomen is the principal modality in the initial staging, preoperative planning, and follow-up of GBC.

- MRI with contrast and MRCP sequence is performed when knowledge of detailed biliary anatomy and nature and level of biliary obstruction is important in the management.
- Preoperative staging of GCB (► **Table 2**) needs delineation of local mass, nodal involvement, and distant metastases (see reporting format).
- Nodal disease: Nodes larger than 1 cm in short-axis dimension are considered abnormal. Round shape, heterogeneous enhancement, and irregular margin of nodes are also suspicious features.
- Regional nodes (definitely regional; N1/N2 as per the American Joint Committee on Cancer [AJCC]/TNM guideline): Cystic duct, pericholedochal, retroportal (posterior to portal vein up to uncinate process of pancreas), liver hilar, and common hepatic artery nodes.
- Watershed nodes (controversially regional as per the Japanese Society of Biliary Surgery): Posterior-superior pancreaticoduodenal (located in the posterior and superior portion of pancreatoduodenal groove) and right side of celiac artery nodes.
- Metastatic nodes (definitely nonregional): Left side of celiac or superior mesenteric artery, para-aortic, inter-aortocaval, and retrocaval nodes.

Detection of involved nonregional and watershed nodes is critical in imaging as they are missed in routine cancer surgery or staging laparoscopy.

Principles of Management

After initial staging in patients who are incidentally diagnosed with GBC at surgery and found to have resectable disease with no metastases, a completion cholecystectomy with en bloc liver resection, lymphadenectomy with/without bile duct resection is recommended. Unfortunately, 40 to 76% of patients of IGBC are found to have residual disease on surgical reexploration. Most symptomatic patients present

Table 2 TNM staging of gallbladder carcinoma—AJCC 8th edition

Category	Subcategory	Description	
T	Tis	Carcinoma in situ	
	T1	T1a	Limited to lamina propria
		T1b	Invasion of muscular layer
	T2	T2a	Invasion of perimuscular connective tissue on peritoneal side
		T2b	Invasion of perimuscular connective tissue on liver side
	T3	Perforates serosa and/or invades liver and/or one other adjacent [stomach, duodenum, colon, pancreas, omentum, extrahepatic bile ducts]	
T4	Invades main portal vein or hepatic artery or two or more extrahepatic organs		
N	N0	No regional node metastases	
	N1	Metastasis in 1–3 regional nodes	
	N2	Metastasis in ≥ 4 regional nodes	
M	M0	No distant metastases	
	M1	Distant metastases	

Abbreviation: AJCC, American Joint Committee on Cancer.

with inoperable and/or metastatic disease, principally in the liver. In such situations, palliative chemotherapy is the only option. In other cases, imaging helps to demarcate GBC into resectable and nonresectable cancers, which decides further treatment such as upfront surgery or neoadjuvant chemotherapy followed by surgery. In case of borderline resectable lesions, neoadjuvant chemotherapy followed by surgery is offered. In operable candidates, the surgery may vary from radical cholecystectomy to right or extended right hepatectomy. Prior to hepatectomy percutaneous transhepatic biliary drainage (PTBD) and portal vein embolization may be required.

Cholangiocarcinoma

Introduction

CCAs are usually adenocarcinomas arising from biliary epithelium. CCAs are characterized by slow growth, local invasion, and intense desmoplastic reaction. Metastases are not common. *Combined hepatocellular-CCA* (also called *biphenotypic primary liver cancer*) is a distinct type of CCA with histologic features of both cancers.²⁴

Based on its location it is classified into IHCC and extrahepatic CCA (ECCA). ECCA is much more common, accounting for approximately 90% of the CCA.²⁵

1. Intrahepatic: Tumors that arise peripheral to the secondary bifurcation of the left or right hepatic duct are considered IHCC.
2. Extrahepatic:
 - a. *Perihilar CCA* (pCCA): Tumors that arise anywhere from the bifurcation of right and left common hepatic duct (CHD) up to the insertion of the cystic duct are called pCCA. When the tumor involves the CHD bifurcation, they are called *Klatskin tumors*.
 - b. *Distal CCA* (dCCA): Cancers arising between cystic duct insertion and the ampulla, but not including the ampulla.

Risk factors and Etiopathogenesis

About 90% patients diagnosed with CCA do not have any identifiable risk factors, but commonly recognized risk factors are primary sclerosing cholangitis, hepatolithiasis, liver fluke infestation, choledochal cyst, and abnormal pancreaticobiliary junction.²⁶

There are two precursors to CCA: intraductal papillary mucinous neoplasm of the bile duct (IPN-B) and biliary intraepithelial neoplasia (BillIN).²⁷ BillIN is not visible on imaging.²⁸ IPN-B appears as solitary or multiple papillary lesions within the bile duct lumen and produces a variable degree of mucin.

Epidemiology, Clinical Presentation in India and Global

CCA is the second most common cancer of the hepatobiliary system worldwide after HCC. It is slightly more common in men, usually diagnosed within 50 to 70 years of age. Patients with ECCA present with painless progressive jaun-

dice, which may be associated with abdominal pain and weight loss. IHCC presents with a liver mass and jaundice is uncommon.

Imaging Referral Guidelines

1. Multiphasic CT or MRI is recommended for evaluation of local disease. CT or MR is especially critical in the evaluation of vascular invasion.
2. MRCP is preferred over endoscopic or percutaneous cholangiography for evaluation of biliary anatomy and level of obstruction.
3. CT thorax with or without contrast is necessary for evaluation of lung metastases.
4. 18-Fluorodeoxyglucose-PET may be considered in the evaluation of nodal staging, distant metastases, and cases with suspected relapse.²⁹ It has no role in the diagnosis of the primary tumor.
5. Biopsy: In case of suspected IHCC, percutaneous biopsy is indicated. In case of ECCA and some cases of IHCC in non-cirrhotic patients, who are candidates for surgery, biopsy may be not necessary if the index of suspicion is high. Biopsy is indicated in all other cases of ECCA. Biopsy and biliary drainage should be performed after all imaging necessary for staging are done as these can interfere with imaging appearance of the tumor.

Clinical/Diagnostic Workup Excluding Imaging

- CEA and CA 19-9.
- AFP, in case of IHCC if HCC is considered in differentials.
- LFT.
- Viral serology.
- Serum IgG4, to rule out possible autoimmune cholangitis.¹⁰
- Endoscopic ultrasound, in cases of ECCA.

Imaging guidelines

Screening

Patients with primary sclerosing cholangitis are recommended to undergo CCA surveillance with MRI/MRCP or ultrasound and serum CA 19-9 level every 6 to 12 months.³⁰ Screening recommendation for IHCC is the same as that of HCC.

Diagnosis

Intrahepatic Cholangiocarcinoma

Mass-forming IHCC appears as an irregular but well-defined mass, often associated with upstream peripheral biliary dilatation. It can invade the portal vein and adjacent liver forming satellite nodules. The typical multiphasic CT/MRI finding of IHCC is a well-defined mass that shows irregular continuous rim-like enhancement in the hepatic arterial phase with gradual centripetal enhancement on portal venous and delayed phases.³¹ Additionally, MRI with gadobenate agent shows peripheral hypointensity with contrast retention at the center in the hepatobiliary phase. Other characteristic findings include rim-like diffusion restriction and overlying liver capsular retraction.³²

Table 3 TNM staging of intrahepatic cholangiocarcinoma—AJCC 8th edition

Category	Subcategory	Description	
T	Tis	Carcinoma in situ	
	T1	T1a	Solitary tumor without vascular invasion, size < 5 cm
		T1b	Solitary tumor without vascular invasion, size > 5 cm
	T2	Solitary tumor with vascular invasion or multiple tumors	
	T3	Tumor perforating visceral peritoneum	
	T4	Tumor invading local extrahepatic structures	
N	N0	No regional node metastases	
	N1	Regional node metastases	
M	M0	No distant metastases	
	M1	Distant metastases	

Abbreviation: AJCC, American Joint Committee on Cancer.

Extrahepatic Cholangiocarcinoma

ECCA are often not seen on ultrasound but can be identified by presence of biliary dilatation. Klatskin tumor presents as focal hypoechoic mass at liver hilum with nonunion of right and left hepatic ducts. Distal cancers present as dilatation of common bile ducts (CBDs). CT shows the extent of ductal obstruction and vascular involvement by the tumor. CT has moderate diagnostic value in nodal staging. MRCP is preferred for demonstration of the bile duct anatomy. Both CT and MRI show an ill-defined mass and/or long segment asymmetric irregular wall thickening of bile duct. Progressive enhancement in delayed phases is characteristic.

Staging

The AJCC 8th edition recommended different staging strategies for ICCA, pCCA, and dCCA. The staging for ICCA and dCCA is given in **Tables 3** and **4**, respectively. The Memorial Sloan-Kettering Cancer Center classification for pCCA is discussed in **Table 5** as it takes into consideration vascular invasion, extension of biliary involvement, and degree of liver lobar atrophy which are surgically relevant information.

After resectability of pCCA is established liver volumetry is sometimes necessary to calculate the functional liver residue (FLR) after resection.

Management

Role of IR in biliary malignancy:

Biliary Procedures

Therapeutic access to the biliary system is mainly limited to endoscopic or percutaneous biliary procedures. Many percutaneous transhepatic biliary interventions are applicable for the diagnosis and treatment of biliary system pathologies. The fundamental procedures are:

- Percutaneous transhepatic cholangiography.
- Internal/external biliary drainage.
- Biliary stenting.
- Endobiliary biopsy techniques.
- Intraluminal brachytherapy.

PTBD is an image-guided therapeutic procedure where bile duct is cannulated followed by external or internal/external catheter drainage of bile. PTBD is usually reserved

Table 4 TNM staging of distal cholangiocarcinoma—AJCC 8th edition

Category	Subcategory	Description
T	Tis	Carcinoma in situ/high-grade dysplasia
	T1	Tumor invades bile duct wall with a depth of < 5 mm
	T2	Tumor invades bile duct wall with a depth of 5–12 mm
	T3	Tumor invades bile duct wall with a depth of > 12 mm
	T4	Tumor involves celiac axis, superior mesenteric or common hepatic artery
N	N0	No regional node metastases
	N1	Metastasis in 1–3 regional nodes
	N2	Metastasis in ≥ 4 regional nodes
M	M0	No distant metastases
	M1	Distant metastases

Abbreviation: AJCC, American Joint Committee on Cancer.

Table 5 MSKCC classification of perihilar cholangiocarcinoma

Classification	Biliary involvement	Portal vein invasion	Liver lobe atrophy
T1	Hilum ± unilateral second order bile ducts	No	No
T2	Hilum ± unilateral second order bile ducts	Ipsilateral	Ipsilateral
T3	Hilum ± bilateral second order bile ducts	Any	Any
	Hilum ± unilateral second order bile ducts	Contralateral	Any
	Hilum ± unilateral second order bile ducts	Any	Contralateral
	Hilum ± unilateral second order bile ducts	Bilateral	Any

Abbreviation: MSKCC, Memorial Sloan-Kettering Cancer Center.

for when endoscopic intervention fails or if there is high intrahepatic obstruction.³³

Biliary stenting usually follows percutaneous transhepatic biliary drainage. Plastic stents and self-expandable metal stents are available options, but selection varies on reintervention risk and life expectancy. Self-expanding metal stents are more commonly used malignant strictures.

Percutaneous transhepatic endobiliary biopsy can be performed with varying techniques that include exfoliative cytology of bile aspirates, intraluminal brush biopsy, and intraluminal forceps biopsy. They are generally reserved when endoscopic access is failed or unsuccessful. Endobiliary biopsy techniques are more successful in establishing a diagnosis of malignancy in small biliary tumors limited to CBD or periductal infiltrating CCA which are difficult for percutaneous access. Forceps biopsy has the highest sensitivity among all sampling techniques.^{34–36}

Intraluminal brachytherapy is a percutaneous palliative intervention that involves catheter-mediated delivery of radiation to malignant biliary strictures. Intraluminal brachytherapy can improve obstructive jaundice, stent patency, and increase patient survival.³⁷

Portal Vein Embolization

Portal vein embolization (PVE) of the segments to be resected may benefit patients who undergo aggressive liver resection so that the residual liver may hypertrophy before surgery.³⁸

Follow-Up

For patients undergoing chemotherapy or in postoperative period, surveillance imaging with multiphasic CT/MRI is recommended after treatment for every 3 to 6 months for the first 2 years and every 6 to 12 months for 5 years.

Follow-up imaging after biliary procedures is necessary for evaluation of stent function. A functioning stent usually shows reduction or resolution of biliary dilatation and pneumobilia of the drained portion of the liver. Common causes of stent blockage are tumor ingrowth and sludge.

Following PVE, a repeat volumetry is necessary to document hypertrophy of the contralateral liver and calculate FLR.

Summary of Recommendations

1. Ultrasound is a screening tool in hepatobiliary malignancy which includes screening for hepatocellular cancer in high-risk patients.
2. Multiphasic CT is the primary imaging modality for initial staging and preoperative evaluation of hepatobiliary malignancy.
3. MRI is used for problem solving; especially in the diagnosis of liver nodules and delineation of biliary anatomy.
4. Bone scan is recommended in suspected/diagnosed cases of HCC with bone symptoms. PET-CT scan has limited application in CCA.
5. For follow-up of treated hepatocellular cancer, measurement of viable lesions as per mRECIST criteria is recommended.
6. Volumetry is essential before liver resection in HCC and CCA.

References

- 1 Acharya SK. Epidemiology of hepatocellular carcinoma in India. *J Clin Exp Hepatol* 2014;4(Suppl 3):S27–S33
- 2 Herbst DA, Reddy KR. Risk factors for hepatocellular carcinoma. *Clin Liver Dis (Hoboken)* 2013;1(06):180–182
- 3 Asim M, Sarma MP, Kar P. Etiological and molecular profile of hepatocellular cancer from India. *Int J Cancer* 2013;133(02):437–445
- 4 European Association For The Study Of The Liver European Organisation For Research And Treatment Of Cancer. EASL-EORTC clinical practice guidelines: management of hepatocellular carcinoma. *J Hepatol* 2012;56(04):908–943
- 5 Paul SB, Sreenivas V, Gulati MS, et al. Incidence of hepatocellular carcinoma among Indian patients with cirrhosis of liver: an experience from a tertiary care center in northern India. *Indian J Gastroenterol* 2007;26(06):274–278
- 6 Yeole BB. Trends in cancer incidence in esophagus, stomach, colon, rectum and liver in males in India. *Asian Pac J Cancer Prev* 2008;9(01):97–100
- 7 Dikshit R, Gupta PC, Ramasundarahettige C, et al; Million Death Study Collaborators. Cancer mortality in India: a nationally representative survey. *Lancet* 2012;379(9828):1807–1816
- 8 Singal AG, Zhang E, Narasimman M, et al. HCC surveillance improves early detection, curative treatment receipt, and survival in patients with cirrhosis: a systematic review and meta-analysis. *J Hepatol* 2022;77(01):128–139
- 9 Tzartzeva K, Obi J, Rich NE, et al. Surveillance imaging and alpha fetoprotein for early detection of hepatocellular carcinoma in patients with cirrhosis: a meta-analysis. *Gastroenterology* 2018;154(06):1706–1718.e1

- 10 Benson AB, D'Angelica MI, Abbott DE, et al. Hepatobiliary Cancers, Version 2.2021, NCCN Clinical Practice Guidelines in Oncology. *J Natl Compr Canc Netw* 2021;19(05):541–565
- 11 American College of Radiology. Ultrasound LI-RADS v2017. Accessed December 23, 2022. <https://www.acr.org/Clinical-Resources/Reporting-and-Data-Systems/LI-RADS/LI-RADS-UI-trasound-v2017>
- 12 Marrero JA, Kulik LM, Sirlin CB, et al. Diagnosis, staging, and management of hepatocellular carcinoma: 2018 Practice Guidance by the American Association for the Study of Liver Diseases. *Hepatology* 2018;68(02):723–750
- 13 American College of Radiology. Liver imaging reporting and data system. American College of Radiology website. Accessed December 23, 2022 <https://www.acr.org/Quality-Safety/Resources/LIRADS>
- 14 Salem R, Johnson GE, Kim E, et al. Yttrium-90 radioembolization for the treatment of solitary, unresectable HCC: the LEGACY study. *Hepatology* 2021;74(05):2342–2352
- 15 Mazzaferro V, Citterio D, Bhoori S, et al. Liver transplantation in hepatocellular carcinoma after tumour downstaging (XXL): a randomised, controlled, phase 2b/3 trial. *Lancet Oncol* 2020;21(07):947–956
- 16 Llovet JM, Lencioni R. mRECIST for HCC: performance and novel refinements. *J Hepatol* 2020;72(02):288–306
- 17 Gordan JD, Kennedy EB, Abou-Alfa GK, et al. Systemic therapy for advanced hepatocellular carcinoma: ASCO guideline. *J Clin Oncol* 2020;38(36):4317–4345
- 18 Akinyemiju T, Abera S, Ahmed M, et al; Global Burden of Disease Liver Cancer Collaboration. The burden of primary liver cancer and underlying etiologies from 1990 to 2015 at the global, regional, and national level: results from the Global Burden of Disease Study 2015. *JAMA Oncol* 2017;3(12):1683–1691
- 19 Stinton LM, Shaffer EA. Epidemiology of gallbladder disease: cholelithiasis and cancer. *Gut Liver* 2012;6(02):172–187
- 20 Rawla P, Sunkara T, Thandra KC, Barsouk A. Epidemiology of gallbladder cancer. *Clin Exp Hepatol* 2019;5(02):93–102
- 21 Dutta U, Bush N, Kalsi D, Popli P, Kapoor VK. Epidemiology of gallbladder cancer in India. *Linchuang Zhongliuxue Zazhi* 2019;8(04):33
- 22 Rathanaswamy S, Misra S, Kumar V, et al. Incidentally detected gallbladder cancer- the controversies and algorithmic approach to management. *Indian J Surg* 2012;74(03):248–254
- 23 Rodríguez-Fernández A, Gómez-Río M, Medina-Benítez A, et al. Application of modern imaging methods in diagnosis of gallbladder cancer. *J Surg Oncol* 2006;93(08):650–664
- 24 Akiba J, Nakashima O, Hattori S, et al. Clinicopathologic analysis of combined hepatocellular-cholangiocarcinoma according to the latest WHO classification. *Am J Surg Pathol* 2013;37(04):496–505
- 25 DeOliveira ML, Cunningham SC, Cameron JL, et al. Cholangiocarcinoma: thirty-one-year experience with 564 patients at a single institution. *Ann Surg* 2007;245(05):755–762
- 26 Ben-Menachem T. Risk factors for cholangiocarcinoma. *Eur J Gastroenterol Hepatol* 2007;19(08):615–617
- 27 Chatterjee A, Lopes Vendrami C, Nikolaidis P, et al. Uncommon intraluminal tumors of the gallbladder and biliary tract: spectrum of imaging appearances. *Radiographics* 2019;39(02):388–412
- 28 Ainechi S, Lee H. Updates on precancerous lesions of the biliary tract: biliary precancerous lesion. *Arch Pathol Lab Med* 2016;140(11):1285–1289
- 29 Lamarca A, Barriuso J, Chander A, et al. ¹⁸F-fluorodeoxyglucose positron emission tomography (¹⁸FDG-PET) for patients with biliary tract cancer: systematic review and meta-analysis. *J Hepatol* 2019;71(01):115–129
- 30 Ahn JC, Yang JD. Screening indications and treatments for cholangiocarcinoma. *Curr Hepatol Rep* 2019;18:408–416
- 31 Lim JH. Cholangiocarcinoma: morphologic classification according to growth pattern and imaging findings. *AJR Am J Roentgenol* 2003;181(03):819–827
- 32 Kang Y, Lee JM, Kim SH, Han JK, Choi BI. Intrahepatic mass-forming cholangiocarcinoma: enhancement patterns on gadoteric acid-enhanced MR images. *Radiology* 2012;264(03):751–760
- 33 Watkinson AF, Adam A. *Interventional Radiology: A Practical Guide*. New York, USA: Radcliffe Publishing; 1996
- 34 Jung G-S, Huh J-D, Lee SU, Han BH, Chang H-K, Cho YD. Bile duct: analysis of percutaneous transluminal forceps biopsy in 130 patients suspected of having malignant biliary obstruction. *Radiology* 2002;224(03):725–730
- 35 Ahrar K, Gupta S. *Percutaneous Image-Guided Biopsy*. Springer Science & Business Media; 2013
- 36 Brugge WR, De Witt J, Klapman JB, et al. Techniques for cytologic sampling of pancreatic and bile duct lesions: the Papanicolaou Society of Cytopathology guidelines. *Cytojournal* 2014;11(Suppl 1):2
- 37 Madhusudhan KS, Gamanagatti S, Gupta AK. Imaging and interventions in hilar cholangiocarcinoma: a review. *World J Radiol* 2015;7(02):28–44
- 38 Nimura Y, Kamiya J, Kondo S, et al. Aggressive preoperative management and extended surgery for hilar cholangiocarcinoma: Nagoya experience. *J Hepatobiliary Pancreat Surg* 2000;7(02):155–162