Article published online: 2023-04-03

Solid Pseudopapillary Epithelial Neoplasm of the Pancreas: A Rare Entity with Diagnostic Dilemma

Sucheta Gandhe[1] Rahul Patil[1] Venkata Ramesh Yasam[2] Raj Nagarkar[3]

[1] Department of Pathology, HCG Manavata Cancer Centre, Nashik, Maharashtra, India
[2] Department of Academics, HCG Manavata Cancer Centre, Nashik, Maharashtra, India
[3] Department of Surgical Oncology, HCG Manavata Cancer Centre, Nashik, Maharashtra, India

Address for correspondence Dr. Sucheta Gandhe, MD, Department of Pathology, HCG Manavata Cancer Centre, Nashik 422011, Maharashtra, India (e-mail: academics@manavatacancercentre.com).

Ann Natl Acad Med Sci (India) 2023;59:115–120.

Abstract

The solid pseudopapillary epithelial neoplasm (SPEN) of the pancreas is a relatively uncommon entity. The aim of the present study was to summarize our experiences with regard to diagnostic dilemma, surgery, postoperative follow-up, and management. This retrospective data were collected during the period from January 1, 2018 to December 31, 2020. A total of four patients (three females and one male) were identified within an age range of 13 to 25 years. All the patients were presented with nonspecific symptoms such as abdomen lumps, swelling in the abdomen, and abdominal pain. To reach a definite diagnosis, imaging studies were conducted along with endoscopic ultrasound fine-needle aspiration (EUS-FNA) and biopsy. After confirmation of SPEN on biopsy, all the patients underwent surgery without any complications. Patients are on follow-up, and to date, no metastasis has been detected. SPEN is a rare pancreatic tumor with unusual pathological features leading to a diagnostic dilemma. The pathologist should be familiar with SPEN and its salient histological characteristics that differentiate it from other look-alike pancreatic tumors and can help in timely surgery and management.

Keywords
- pancreas
- solid pseudopapillary epithelial neoplasm
- diagnostic dilemma
- immunohistochemistry
- surgery

Introduction

Solid pseudopapillary epithelial neoplasm (SPEN) was first reported in 1959 by Dr. Frantz as a "papillary cystic tumor of the pancreas" and later described by multiple names in the literature reflecting its biology and histogenesis. In 2010, the World Health Organization (WHO) for the first time defined it as SPEN. It is a rare pancreatic tumor accounting for only 2 to 3% of all pancreatic neoplasms and 1 to 3% of exocrine pancreatic neoplasms.[1] SPEN is most commonly observed in young women (~90%) with a median age of ~30 years.[2] Despite unknown etiopathogenesis, its incidence was observed to be increasing rapidly in the past 10 years due to technological advancement. Due to such low incidence, its clinical and pathologic features have not been extensively studied. Even its etiology and differential status remained challenging. In practice, diagnosis of SPEN was also found to

article published online
April 3, 2023

DOI https://doi.org/10.1055/s-0042-1760354.
ISSN 0379-038X.

© 2023. National Academy of Medical Sciences (India). All rights reserved.
This is an open access article published by Thieme under the terms of the Creative Commons Attribution-NonDerivative-NonCommercial-License, permitting copying and reproduction so long as the original work is given appropriate credit. Contents may not be used for commercial purposes, or adapted, remixed, transformed or built upon. (https://creativecommons.org/licenses/by-nc-nd/4.0/)

Thieme Medical and Scientific Publishers Pvt. Ltd., A-12, 2nd Floor, Sector 2, Noida-201301 UP, India

be very difficult due to its vague and nonspecific abdominal symptoms.[3]

In the present study, we bring our experience with SPEN in Indian patients with its clinical, radiological, histopathological, and surgical findings to provide a reference for the management of this rare disease.

Case History

In this retrospective study, a total of four patients have undergone surgery for SPEN during the period from January 1, 2018 to December 31, 2020. All these patients' demographic, clinical, imaging, surgical, pathological, survival, and follow-up data were extracted from hospital medical records and evaluated. All the necessary ethical approvals were procured from the institutional ethics committee prior to study commencement.

From the records, a total of four patients were identified; three were females (75%) and 1 (25%) was male. The patients' age ranged from 13 to 25 years. Symptoms on presentation were largely varied and nonspecific. However, the most common symptoms were found to be pain and swelling in the abdomen with a palpable abdomen mass (in one patient). In all the patients, serum tumor marker tests like Ca19–9, carcinoembryonic antigen (CEA), and Ca-125 (in female patients) were done and reported as normal. Preoperative radiological examinations such as transabdominal ultrasonography and computed tomography (CT) were also performed. In these imaging studies, large complex solid cystic lesions in various regions of the pancreas were revealed. Axial contrast-enhanced CT images also revealed a large, enhancing solid heterogeneous, well-circumscribed mass originating in the pancreatic body and tail. No perilesional fat stranding and calcification were noted.

Later a positron emission tomography (PET) scan was done, revealing an abnormal and high F-18 fluorodeoxyglucose (FDG) uptake in the solid, enhancing part of the pancreatic lesions (►**Fig. 1**). The tumor location in two patients (50%) was found to be the head of the pancreas, followed by the head and body, and the tail of the pancreas, one in each patient. The mean diameter of the tumor was ~12 cm. Further, to determine the radiological findings in SPEN, all the suspected patients underwent endoscopic ultrasound fine-needle aspiration (EUS-FNA) and biopsy of the pancreas through the transduodenal approach or transgastric route. The cytology was reported as papillary neoplasm of the pancreas, while the biopsies were reported as SPEN. To confirm the diagnosis and to avoid any diagnostic dilemma, immunohistochemical staining (IHC) was performed on all biopsies. After confirmation of SPEN on IHC, three patients (75%) with tumors on the head, neck, and body of the pancreas underwent pancreaticoduodenectomy. The remaining one patient (25%) with a tumor on the tail of the pancreas underwent a distal pancreatectomy. The perioperative and postoperative periods were uneventful

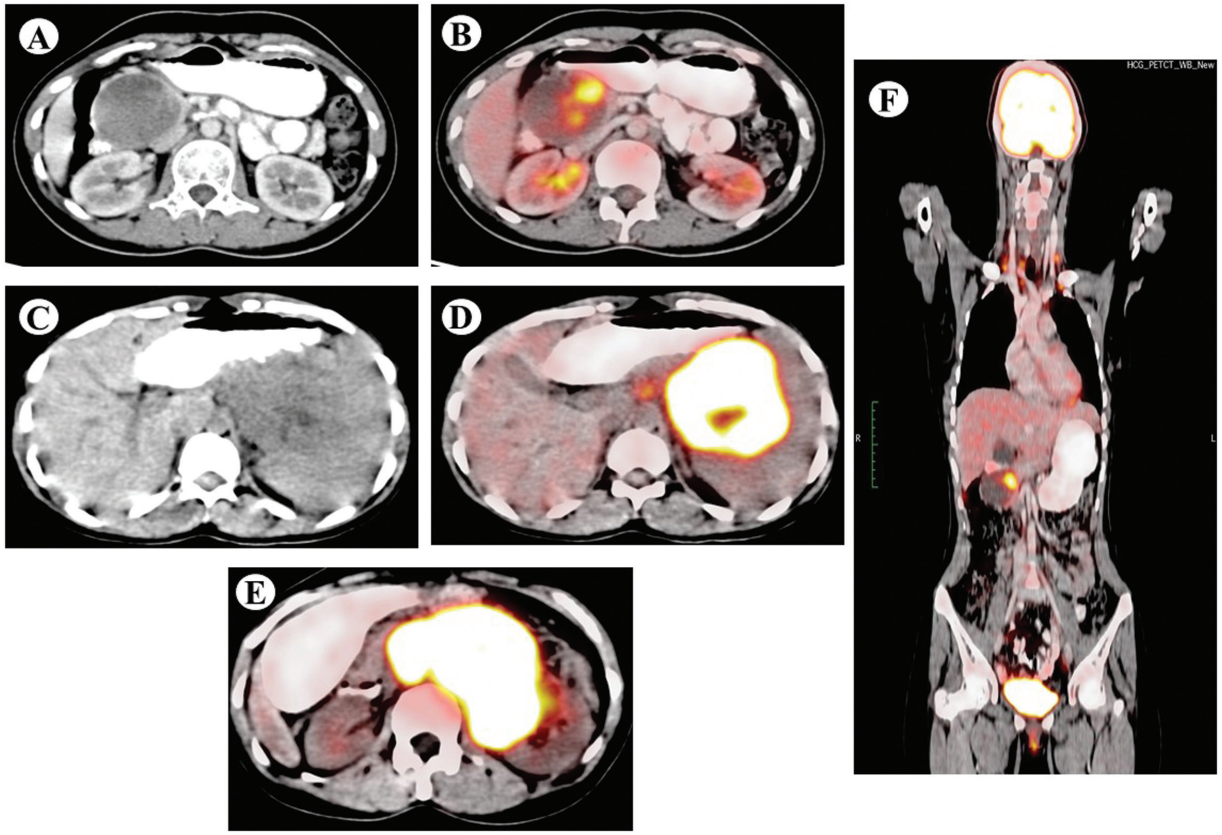

Fig. 1 **A** and **B**: FDG avid mixed solid cystic lesion in head of pancreas. **C** and **D**: FDG avid mass in pancreatic tail infiltrating into splenic hilum. **E**: Large FDG avid mass in body and tail of pancreas. **F**: FDG avid mass in body of pancreas.

 © 2023. National Academy of Medical Sciences (India). All rights reserved.

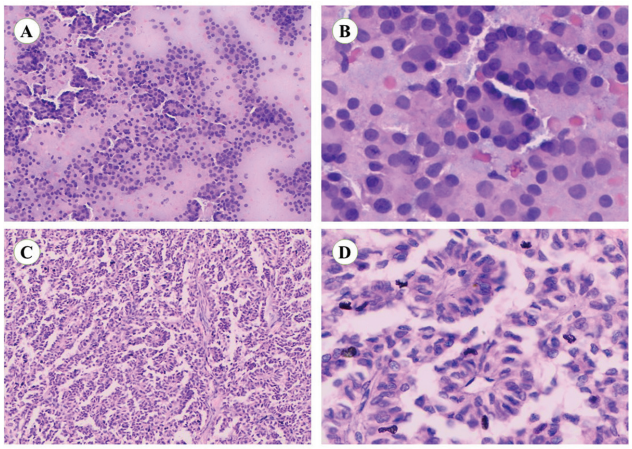

Fig. 2 **A** and **B** (PAP Stain): Cellular smear showing tumor cells with minimal cytological atypia forming rosettes. Cells are also showing eccentric nuclei with prominent granular cytoplasm. **C** (10x H and E): Solid nests of poorly cohesive tumor cells forming a cuff surrounding blood vessels, resulting in a pseudopapillary architecture. **D** (40x H and E): Tumor cells arranged around thin fibrovascular cores forming pseudo-rosettes. Tumor cells showing a moderate amount of eosinophilic cytoplasm with large intracytoplasmic hyaline globules and perinuclear vacuoles.

in all the patients. The radical specimens were reported as SPEN on final histopathology report. IHC revealed strong positivity for pancytokeratin (Pan CK), β-catenin, CD56, and synaptophysin. All the data related to clinical and pathological features of the patients with SPEN of the pancreas are presented in ►**Table 1**.

Papanicolaou's staining (Pap stain) of cellular smears showed tumor cells with minimal cytological atypia forming rosettes (►**Fig. 2A** and **2B**). Cells were also showing eccentric nuclei with prominent granular cytoplasm. Histology of the tissues (hematoxylin and eosin [H&E] staining) with 10X magnification revealed pseudopapillary architecture (►**Fig. 2C**). Whereas on 40X magnification, tumor cells were observed to be arranged around thin fibrovascular cores forming pseudorosettes (►**Fig. 2D**). Tumor cells also showed perinuclear vacuoles, large intracytoplasmic hyaline globules, and eosinophilic cytoplasm in moderate amount.

Discussion

With the advancement of technology and imaging modalities, early identification and accurate diagnosis of pancreatic tumors is helping patients to live longer compared with patients from the previous decade. Non-neoplastic and neoplastic pancreatic tumors present as encapsulated masses with a variable amount of hemorrhagic, cystic, and solid components. Pancreatic cystic lesions are further divided into four groups: intraductal pancreatic mucinous lesions, SPENs, mucinous cystic lesions, and serous cystic lesions.[4] Among all the pancreatic cystic lesions, SPEN is extremely rare.

Among these pancreatic tumors, non-neoplastic lesions include the intrapancreatic accessory spleen, congenital anomalies (annular pancreas, heterotopic pancreas, pancreatic lobulation, nesidioblastosis, and rare miscellaneous conditions), cysts, pseudocysts, granulomatous inflammation, and pancreatitis, whereas neoplastic lesions include metastatic tumors, mesenchymal tumors, lymphoid tumors, pancreatoblastoma, solid pseudopapillary tumor, acinar cell tumors, pancreatic intraepithelial neoplasia, intraductal papillary mucinous neoplasms, cystic pancreatic lesions, anaplastic carcinoma, ductal adenocarcinoma, pancreatic neuroendocrine tumor, pancreatic lymphoma, other epithelial exocrine tumors, and rare miscellaneous neoplasms.

Among all those cystic neoplasms, SPEN is an uncommon, indolent, low-grade malignant tumor of unknown etiology. SPEN was frequently reported in young females and the female-to-male ratio was generally observed to be 10:1.[5] In a systematic review conducted by Law et al,[6] the mean age of the patients was found to be 28.5 years (SD ± 13.7 years). Results from our study are in agreement with the previous studies, where 75% of our patient cohort were females. The average age was also observed to be 20.5 years. On clinical presentation, nonspecific symptoms were reported such as early satiety, vomiting, nausea, bloating, weight loss, palpable abdominal mass/discomfort, and abdominal pain. In many patients, SPENs are often identified incidentally. It was also reported that there is no correlation between tumor size and symptoms leading to patients presenting themselves to clinics in later stages of the disease. With respect to tumor localization, they were often found in the tail, followed by the head and body. However, in our patient series, the head followed by the tail and body of the pancreas was reported to be the most common tumor location. In some exceptional cases, multicentric tumors and extrapancreatic sites such as the duodenum, liver, omentum, retroperitoneum, and mesocolon were also found to show these tumors representing synchronous tumor spread. However, such multicentric, extrapancreatic tumors were not reported in our patients. Often, SPEN is misdiagnosed and usually there is no evidence of an endocrine syndrome, elevated pancreatic enzymes, cholestasis, abnormal liver function tests, serum tumor markers, and pancreatic insufficiency to determine it. Therefore, clinicians should always consider a differential diagnosis of SPEN, especially when the patient is young.[3]

Regular laboratory parameters, tumor markers, and clinical and radiological findings are proven to be of no help/unremarkable. In such scenarios, to reach a definite preoperative diagnosis, preoperative percutaneous biopsies, tissue sampling with EUS-FNA, and cytology should always be considered. Except for the tumor cell dissemination, EUS-FNA was proven to be a reliable tool for accurate diagnosis of SPEN by characterizing the cytomorphological features.[7] The characteristic features of SPEN can be diagnosed readily based on characteristic cytological and histological features.[3]

On cytology, cellular smears showed tumor cells with minimal cytological atypia forming rosettes. Cells had eccentric nucleus with prominent granular cytoplasm. On histology, SPENs can demonstrate various microscopic patterns such as solid, cystic, and pseudopapillary arrangements. In many patients, cells demonstrate solid nests of

 © 2023. National Academy of Medical Sciences (India). All rights reserved.

Table 1 Clinical and pathological characteristics of patients with solid pseudopapillary neoplasms of the pancreas

Gender	Age (y)	Symptoms	Tumor location on pancreas	Tumor size (mm)	Postoperative complication	Therapy/ intervention	IHC findings	Tumor markers	Metastasis
Female	25	Upper abdominal pain radiating to back	Tail	12.2 × 8.5 × 6.0 cm	None	Distal pancreatectomy	Pan CK: positive LCA: negative CD99: negative Beta catenin: positive CD56: positive Chromogranin: negative AR: negative ER: negative TFE 3: negative Synaptophysin: negative	Ca 19–9- 46.19; CEA: 1.1; AFP: 4.16	No
Female	20	Pain in abdomen	Head	5.4 × 5.2 × 8.3 cm	None	Whipple's surgery	AE1/AE3: positive Beta catenin: positive (nuclear), Synaptophysin: negative Chromogranin: negative, CD56: positive	Ca 19.9 <3.0 Ca125 5.31, CEA 1.67	No
Female	13	Pain and lump in abdomen	Head	11.1 × 7.5 cm	None	Whipple's surgery	Pan Ck: positive LCA: negative Synaptophysin: positive Chromogranin: negative CD56: positive Beta catenin: positive.	Ca 19.9 <3.0 CEA 1.67	No
Male	24	Pain and swelling in the abdomen	Head and body	14 × 15 × 17 cm	None	Whipple's surgery	CK7: negative CK20: negative PAX-8: negative Beta-catenin: positive ER: negative PR: negative	Ca 19.9–1.25	No

Abbreviations: AR, androgen receptor; CD, cluster of differentiation; CEA, carcinoembryonic antigen; CK, cytokeratin; ER, estrogen receptor; LCA, leukocyte common antigen; Pan CK, Pancytokeratin; PR, progesterone receptor; TFE3, transcription factor E3.

 © 2023. National Academy of Medical Sciences (India). All rights reserved.

uniform, polygonal cells with abundant cytoplasm (clear to granular). In our patient cohort, tumor cells have showed perinuclear vacuoles and large intracytoplasmic hyaline globules with moderate amount of eosinophilic cytoplasm. The characteristic pseudopapillary architecture or pseudorosettes were clearly visible in all our patients in accordance with the previous studies.[3,8] Such rosette formations generally contain degenerated cells, tumor cells, and viable cells arranged around the thin fibrovascular cores giving that typical pseudopapillary architecture. To confirm the diagnosis further, IHC tests were performed, where IHC analysis of the specimens was reported to have shown strong positivity for Pan CK, β-catenin, and CD56. Whereas synaptophysin was positive in a single case, progesterone receptor (PR) and estrogen receptor (ER) were negative in all cases. β-catenin localization was also reported to be strongly positive in these patients due to SPEN somatic point mutations in exon 3 of CTNNB1.[9] Runjan and Stefano[10] have also emphasized the importance of the β-catenin pathway to diagnose and differentiate SPEN from look-alike pancreatic endocrine tumors and have also confirmed its presence in 90% of cases.[8,10] On the other hand, with PR, all the patients in our study were reported negative contrary to multiple studies.[1,11,12] Although there is a female preponderance for SPEN, ER positivity is very uncommon and it was negative in all our patients.

After confirmation of SPEN, as a standard of care in the management protocol, all our patients have undergone a complete R0 resection (distal pancreatectomy or pancreaticoduodenectomy: Whipple's surgery). Generally, in unresectable cases, patients were recommended to undergo radiotherapy, chemotherapy, transarterial chemoembolization, alcohol injection, and/or liver transplantation. Postoperative samples have shown no metastasis or invasion to regional lymph nodes and our reports are consistent with previous studies.[13] Multiple studies have reported the prognosis, and the 5-year survival rate is excellent in ~97% of the patients even with metastasis, if treated from time to time. The strong prognostic factors for patients' prolonged survival include the level of surrounding tissue invasion, lymph node involvement, and vascular and perineural invasion, unbalanced translocation between chromosomes 13 and 17, trisomy of chromosome 3, double loss of X chromosomes, DNA aneuploidy, dedifferentiation, nuclear pleomorphism, high mitotic count, significant nuclear atypia, extensive tumor necrosis, and diffuse infiltrative growth pattern.[14] Regular follow-up is also a key for early detection of disease and prolonged survival. All the patients in our study were on regular follow-up and have shown no signs of recurrence or metastasis.

Conclusion

To summarize, SPEN is an uncommon, asymptomatic, low-grade malignant tumor that was typically seen in young women. Due to its diagnostic dilemma, preoperative percutaneous biopsies, tissue sampling EUS-FNA, cytology, and IHC should be strictly considered for a definite diagnosis. A multidisciplinary team approach will always improve treatment accuracy and will help in timely management. Complete R0 resection is the only effective option in all stages of the disease and the prognosis is also proven to be good. All the time, the pathologist should be familiar with the SPEN's salient clinical, microscopic, cytopathological, histopathological, and immunohistochemical features to differentiate them from other circumscribed pancreatic neoplasms such as neuroendocrine lesions. Finally, a minimum of 5-year follow-up after the surgical resection is highly recommended to identify the possible signs of recurrence of the SPEN.

Ethical Approval

The study followed the ethical guidelines of the Declaration of Helsinki. Written informed consent was taken from the patients for publication in the journal.

Funding

None.

Conflict of Interest

None declared.

Acknowledgment

The authors would like to thank Dr. Yasam Venkata Ramesh from HCG Manavata Cancer Centre, Centre for Difficult Cancers (CDC), Nashik, India, for his medical writing assistance.

References

1 Gandhi D, Sharma P, Parashar K, et al. Solid pseudopapillary tumor of the pancreas: radiological and surgical review. Clin Imaging 2020;67:101–107
2 Reddy S, Wolfgang CL. Solid pseudopapillary neoplasms of the pancreas. Adv Surg 2009;43(01):269–282
3 Guo N, Zhou QB, Chen RF, et al. Diagnosis and surgical treatment of solid pseudopapillary neoplasm of the pancreas: analysis of 24 cases. Can J Surg 2011;54(06):368–374
4 Vassos N, Agaimy A, Klein P, Hohenberger W, Croner RS. Solid-pseudopapillary neoplasm (SPN) of the pancreas: case series and literature review on an enigmatic entity. Int J Clin Exp Pathol 2013;6(06):1051–1059
5 Yu PF, Hu ZH, Wang XB, et al. Solid pseudopapillary tumor of the pancreas: a review of 553 cases in Chinese literature. World J Gastroenterol 2010;16(10):1209–1214
6 Law JK, Ahmed A, Singh VK, et al. A systematic review of solid-pseudopapillary neoplasms: Are these rare lesions? Pancreas 2014;43(03):331–337
7 Khashab MA, Kim K, Lennon AM, et al. Should we do EUS/FNA on patients with pancreatic cysts? The incremental diagnostic yield of EUS over CT/MRI for prediction of cystic neoplasms. Pancreas 2013;42(04):717–721
8 Vassos N, Agaimy A, Klein P, Hohenberger W, Croner RS. Solid-pseudopapillary neoplasm (SPN) of the pancreas: case series and literature review on an enigmatic entity. Int J Clin Exp Pathol 2013;6(06):1051–1059
9 Santini R, Poli F, Lega S. Solid-papillary tumors of the pancreas: histopathology. JOP 2006;7(01):131–136
10 Chetty R, Serra S. Loss of expression of E-cadherin in solid pseudopapillary tumors of the pancreas. Pancreas 2009;38(03): 338, author reply 338–339

 © 2023. National Academy of Medical Sciences (India). All rights reserved.

11 Song H, Dong M, Zhou J, Sheng W, Zhong B, Gao W. Solid pseudopapillary neoplasm of the pancreas: clinicopathologic feature, risk factors of malignancy, and survival analysis of 53 cases from a single center. BioMed Res Int 2017;2017:5465261
12 La Rosa S, Bongiovanni M. Pancreatic solid pseudopapillary neoplasm: key pathologic and genetic features. Arch Pathol Lab Med 2020;144(07):829–837
13 Machado MC, Machado MACC, Bacchella T, Jukemura J, Almeida JL, Cunha JEM. Solid pseudopapillary neoplasm of the pancreas: distinct patterns of onset, diagnosis, and prognosis for male versus female patients. Surgery 2008;143(01):29–34
14 Serra S, Chetty R. Revision 2: an immunohistochemical approach and evaluation of solid pseudopapillary tumour of the pancreas. J Clin Pathol 2008;61(11):1153–1159

 © 2023. National Academy of Medical Sciences (India). All rights reserved.