



# Imaging Recommendations for Diagnosis, Staging, and Management of Cancer of the Thyroid, Parathyroid, and Salivary Glands

Abhishek Mahajan<sup>1</sup> Shreya Shukla<sup>2</sup> Suman Kumar Ankathi<sup>3</sup> Anuradha Shukla<sup>2</sup> Richa Vaish<sup>4</sup>  
 Shubham Suryavanshi<sup>2</sup> Ujjwal Agarwal<sup>2</sup> Vasundhara Patil<sup>3</sup> Arpita Sahu<sup>2</sup> Shubham Padashetty<sup>2</sup>  
 Sarbani Ghosh Laskar<sup>5</sup> Vijay Patil<sup>6</sup> Vanita Noronha<sup>6</sup> Nandini Menon<sup>6</sup> Kumar Prabhash<sup>6</sup>  
 Asawari Patil<sup>7</sup> Pankaj Chaturvedi<sup>4</sup> Prathamesh S. Pai<sup>4</sup> Swapnil Rane<sup>7</sup> Munita Bal<sup>7</sup> A. K. Dcruz<sup>8</sup>

<sup>1</sup> Department of Radiodiagnosis, The Clatterbridge Cancer Centre NHS Foundation Trust, Liverpool, United Kingdom

<sup>2</sup> Department of Radiodiagnosis, Tata Memorial Hospital, Homi Bhabha National Institute, Mumbai, India

<sup>3</sup> Department of Radiodiagnosis and Imaging, Tata Memorial Hospital, Mumbai. Homi Bhabha National Institute, Parel, Mumbai, India

<sup>4</sup> Department of Head and Neck Oncology, Tata Memorial Hospital, Homi Bhabha National Institute, Mumbai, India

<sup>5</sup> Department of Radiation Oncology, Tata Memorial Hospital, Mumbai. Homi Bhabha National Institute Location: Mumbai

**Address for correspondence** Abhishek Mahajan, MD, Fellowship in Cancer Imaging, MRes (KCL, London), FRCR (UK), Department of Radiodiagnosis, The Clatterbridge Cancer Centre NHS Foundation Trust, Pembroke Place Liverpool, Liverpool L7 8YA, United Kingdom (e-mail: drabhishek.mahajan@yahoo.in).

<sup>6</sup> Department of Medical Oncology, Tata Memorial Hospital, Mumbai. Homi Bhabha National Institute, Mumbai, India

<sup>7</sup> Department of Pathology, Tata Memorial Hospital, Mumbai. Homi Bhabha National Institute Location: Mumbai, India

<sup>8</sup> Department of Head and Neck Oncosurgery, Oncology Apollo Hospitals, India

Ind J Med Paediatr Oncol 2023;44:159–174.

## Abstract

Thyroid cancer ranks as the leading endocrine malignancy in adults. The foundation for primary diagnosis of thyroid cancer is a high-resolution ultrasound (US) of the thyroid gland including US-guided fine-needle biopsy (FNB) of suspected thyroid nodules. Advanced cross-sectional imaging, including computed tomography (CT), magnetic resonance imaging, and positron emission tomography, can be useful in selected patients. The mainstay of treatment of thyroid cancer is surgery. It may be supplemented by radioactive iodine ablation/therapy in high-risk differentiated thyroid cancer. Radiology plays a crucial role in both diagnostic and posttreatment follow-up imaging. Primary hyperparathyroidism (PHPT) is the third most common endocrine disorder with single parathyroid adenoma being its most common cause. The radiologist's aim in parathyroid imaging is to provide the clinician with an illustrative picture of the neck, locating lesions with respect to landmarks. Imaging helps in the detection of solitary versus multiglandular disease, ectopic and supernumerary glands with precise localization. US, nuclear imaging, and four-dimensional CT are the most commonly used imaging modalities for the preoperative localization of the parathyroid disease. Salivary gland tumors account for approximately 0.5% of all neoplasms, the most common location being the parotid gland (70%). Imaging is crucial in salivary gland tumors by defining its location, detecting malignant features, assessing local extension and invasion, staging the tumors according to the tumor-node-metastasis classification, and assessing the feasibility of surgery.

## Keywords

- ▶ Computed tomography
- ▶ cross-sectional imaging
- ▶ guidelines
- ▶ head and neck cancer
- ▶ magnetic resonance imaging
- ▶ parathyroid imaging
- ▶ salivary gland tumor
- ▶ thyroid cancer
- ▶ thyroid gland
- ▶ ultrasound
- ▶ thyroid gland
- ▶ ultrasound

DOI <https://doi.org/10.1055/s-0042-1760403>.  
 ISSN 0971-5851.

© 2023. The Author(s).

This is an open access article published by Thieme under the terms of the Creative Commons Attribution License, permitting unrestricted use, distribution, and reproduction so long as the original work is properly cited. (<https://creativecommons.org/licenses/by/4.0/>)  
 Thieme Medical and Scientific Publishers Pvt. Ltd., A-12, 2nd Floor, Sector 2, Noida-201301 UP, India

## Thyroid Gland, Introduction, Risk Factors, and Etiopathogenesis

Thyroid cancer ranks as the leading endocrine malignancy in adults.<sup>1</sup> Thyroid cancer can arise from two chief cell types: follicular and parafollicular or C-cells. Papillary thyroid cancer (PTC) and follicular thyroid cancer (FTC) are grouped together as differentiated thyroid cancer (DTC) as they both arise from thyroid follicular cells. Medullary thyroid cancer arises from parafollicular cells. Anaplastic carcinomas (ATC) are the most undifferentiated type of thyroid cancer.<sup>2</sup> Papillary microcarcinoma (PMC) refers to papillary cancer smaller than 1 cm.<sup>3</sup>

Exposure to radiation, family history of thyroid cancer, and inherited genetic syndromes are some of the risk factors for thyroid cancer. Other risk factors include high iodine intake, increased thyroid-stimulating hormone (TSH) levels, obesity, and exposure to nitrate.<sup>4</sup> Sources of radiation exposure may be environmental nuclear disasters, radiological tests (e.g., computed tomography [CT] scans, X-rays), and medical treatment, including radiation therapy for head and neck cancer and radioactive iodine (RAI) treatment.<sup>5</sup> Thyroid cancer is known to have a high hereditary predisposition; however, more than 90% is sporadic in nature.<sup>6,7</sup> The autosomal dominant hereditary syndromes associated with thyroid cancer include familial adenomatous polyposis, Cowden syndrome, and Carney complex. The familial form of medullary thyroid carcinoma (MTC) is present in 20 to 25% of cases and is usually a component of MEN 2A or 2B or a part of familial medullary thyroid carcinoma syndrome.<sup>8</sup>

## Epidemiology, Clinical Presentation in India and Global

The GLOBOCAN 2020 estimates of cancer incidence and mortality produced by the International Agency for Research on Cancer show that there were 586,202 new cases of thyroid cancer with an estimated 43,646 deaths worldwide with an estimated incidence rate of 1.4 per 100,000 in India.<sup>9</sup> DTC accounts for 90% of all cases with PTC accounting for approximately 70 to 80% and FTC accounting for 10 to 15% of all cases.<sup>10</sup> PMC accounts for approximately 24% of thyroid cancer cases in the United States.<sup>11</sup> Most cases of DTC occur in adults ages 30 to 50 years.<sup>12</sup> The DTCs usually present as thyroid nodules which can be single or multiple. These cancers are more common in females. The findings which should alert the physician to thoroughly investigate the patients include extremes of age (<16 years and >55 years), male patients, history of radiation exposure, family history, and symptoms of involvement of surrounding structures like hoarseness, breathing difficulty, and hemoptysis.

## Imaging Referral Guidelines

The 2015 American Thyroid Association (ATA) management guidelines for adult patients with thyroid nodules are widely popular for DTC and MTC. The ATA guidelines for manage-

ment of patients with ATC have been revised in 2021. Korean Society of Thyroid Radiology (KSThR) through a collaboration with the National Evidence-based Healthcare Collaborating Agency has developed the 2020 Imaging guidelines for thyroid nodules and DTC using an adaptation process and has identified four clinical situations which mandate thyroid imaging.<sup>12</sup> They reviewed the previous existing guidelines including the 2015 ATA management guidelines for adult patients with thyroid nodules and DTC, American Association of Clinical Endocrinologists (AACE)/Italian Association of Clinical Endocrinologists/the European Thyroid Association medical guidelines for clinical practice for diagnosis and management of thyroid nodules, British Thyroid Association guidelines for the management of thyroid cancer, U.S. Diagnosis and Imaging-based Management of Thyroid Nodules: Revised KSThR Consensus Statement and Recommendations, American College of Radiology (ACR) Appropriateness Criteria Thyroid Disease, Revised Korean Thyroid Association Management Guidelines for Patients with Thyroid Nodules and Thyroid Cancer and National Comprehensive Cancer Network (NCCN) Clinical Practice Guidelines in Oncology, Thyroid Carcinoma, Version 1. 2019.<sup>13–18</sup> After a thorough discussion and comparison of the recommendations and the evidence in the literature for the selected guidelines, recommendations were prepared by the guideline committee.

The recommendations in four typical clinical situations include (1) *evaluation of known or suspected thyroid nodules*—neck US is usually appropriate for the evaluation of suspected thyroid nodules. US-guided biopsy of thyroid nodules is also appropriate for initial diagnostic workup. Contrast-enhanced CT or magnetic resonance imaging (MRI) of the neck can be additionally performed in advanced thyroid cancer. (2) *Preoperative evaluation of DTC*—neck US is usually appropriate for the preoperative evaluation of DTC. For the preoperative assessment of DTC, washout thyroglobulin (Tg) for neck lymph nodes (LNs) and/or ultrasound (US) guided biopsy are typically appropriate. In advanced disease, neck CT or MRI with IV contrast may be appropriate as an adjunct to US. Contrast-enhanced CT (CECT) chest may be appropriate to evaluate the lung parenchyma or the advanced mediastinum disease. (3) *Early imaging after surgery for DTC*—neck US is appropriate for the postoperative evaluation of DTC after definitive treatment. CECT neck may be appropriate for early imaging after definitive treatment of DTC. When the response to therapy cannot be adequately assessed by US and serum Tg, it may be taken into consideration in individuals with a high risk of persistent pathology. (4) *Suspected recurrence of DTC*—neck US is usually appropriate when recurrence of DTC is suspected. US-guided biopsy and/or washout Tg for neck LNs are usually appropriate when recurrence of DTC is suspected on imaging. Contrast-enhanced neck CT or MRI may be appropriate as a second-line imaging modality in cases of widely distributed recurrent disease, when aerodigestive tract invasion is suspected, or in cases of discrepancy between serum Tg and US results. Chest CT with or without IV contrast may be appropriate in high-risk patients with elevated serum Tg or rising anti-Tg antibodies.<sup>12</sup>

**2015 ATA guidelines for MTC:** US examination of the neck should be performed in all patients with MTC. Patients with significant neck disease and signs or symptoms of local or distant metastases might as well have CECT of the neck and chest, three-phase contrast-enhanced multidetector liver imaging, contrast-enhanced MRI of the liver, axial MRI, and bone scintigraphy. These studies should also be conducted in all patients with a serum Ctn level greater than 500 pe/mL. (C)<sup>19</sup>

**2021 ATA guidelines for ATC:** Initial radiological tumor staging should include cross-sectional imaging, in particular, CT neck, chest, abdomen, and pelvis with contrast (or MRI), and, if available, fluorodeoxyglucose positron emission tomography (FDG PET)/CT. If clinically necessary, contrast-enhanced brain imaging using an MRI should also be performed.<sup>20</sup>

## Clinical/Diagnostic Work-Up Excluding Imaging

The physical examination with neck palpation and US are the two techniques to screen for thyroid cancer. Neck palpation can identify palpable nodules, while US can identify both palpable and nonpalpable nodules. The clinical examination comprises meticulous palpation of the gland along with the neck nodes. Signs of extrathyroidal extension like the involvement of straps and retrosternal extension should be assessed. Determination of Tg in the case of DTC and calcitonin in the case of MTC is of vital significance.<sup>21</sup> The incidence of malignancy in this scenario is low. The ATA guidelines for the assessment of thyroid nodules recommend serum TSH measurement. DTC is more commonly associated with the euthyroid or hypothyroid state. If the TSH is below normal limits, thyroid scintigraphy should be done. Focal FDG uptake in >1 cm thyroid nodule raises concern and fine-needle aspiration (FNA) should be performed. If it measures <1 cm, the nodule may be monitored.<sup>22</sup> The 2015 ATA guidelines for MTC suggest that family history should be thoroughly elicited in suspected medullary thyroid cancers as 25% are hereditary. Fine-needle aspiration cytology (FNAC) from the thyroid nodule establishes the diagnosis in corroboration with serum calcitonin and CEA levels. Genetic testing and counseling should be performed to identify the RET germline mutation. The extent of the disease is established on imaging along with serum calcitonin levels. The family should be screened for the mutation and if present then prophylactic thyroidectomy should be offered to these patients.<sup>23,24</sup> Somatic alterations of BRAF are common in ATC with an incidence of 40 to 70%. Immunohistochemical detection of the most common BRAF mutation (BRAFV600E) is necessary novel mutation-specific therapies that are now available.<sup>20</sup>

## Imaging Guidelines

### Diagnosis (Including Interventions)

#### Imaging Thyroid Nodule

The foundation for primary diagnosis of thyroid cancer is a high-resolution US of the thyroid gland including US-guided

FNB of suspected thyroid nodules.<sup>4</sup> The US scanning technique involves the use of a high-frequency linear array probe. The scan is performed in the hyperextended position of the neck. The neck is scanned from the submental area to the sternal notch. The evaluation of the primary thyroid lesion is done along with the assessment of lateral and central compartment lymph nodes. The head is turned away from the side of interest to scan the tracheoesophageal groove. The transducer is angled inferiorly to examine the mediastinum and laterally to study lateral compartment lymph nodes (levels 2, 3, and 4). Neck is studied from mandible to clavicle and the transducer is angled inferiorly towards clavicle to image infraclavicular nodes at the base of level 4. Sweep laterally along the clavicle to posterior border of the sternocleidomastoid muscle, then trace posterior border superiorly to the mastoid process to image the posterior compartment nodes (level 5).

There are five criteria to identify malignancy on brightness-mode US that help identify malignancy in thyroid nodules: composition, hypoechogenicity, taller than wide shape (anterior-posterior diameter larger than the width in an axial scan), irregular margin, and macro- and micro-calcification.<sup>25</sup> Many simple classification systems have been lately developed for thyroid nodules on thyroid US. The most popular include the classifications proposed by the ATA<sup>26</sup> and AACE,<sup>27</sup> and the thyroid imaging reporting and data systems (TIRADS) released by the KSThR,<sup>28</sup> the European Thyroid Association,<sup>29</sup> and the American College of Radiology (ACR-TIRADS).<sup>30</sup> **Table 1** describes the US features of high, intermediate, and mild suspicion of malignancy according to ATA guidelines. **Table 2** describes the ACR-TIRADS US-based thyroid nodule reporting system (discussed in **Table 2**). The performance of the TIRADS was compared in a recent meta-analysis, wherein categories 4 and 5 had a sensitivity of approximately 90% for the detection of DTC with specificities between 50 and 60% and ACR-TIRADS was found to be the most specific system in a recent prospective study.<sup>31</sup> From a size of 10 mm and above, every suspicious thyroid nodule should undergo US-guided FNB.<sup>13</sup> ATA and AACE guidelines recommend performing thyroid scintigraphy in addition to ultrasound in all patients evaluated for thyroid nodules who have subnormal serum thyrotropin (TSH).<sup>13,27</sup>

The American College of Radiology proposed ACR-TIRADS which is an US -based thyroid nodule reporting system.<sup>32</sup> Five categories of US findings are used to score each thyroid nodule. The likelihood of malignancy increases with an increase in the TR (TIRADS) level with an increase in the cumulative score. TIRADS levels include TR1: 0 points (benign), TR2: 2 points (not suspicious), TR3: 3 points (mildly suspicious), TR4: 4 to 6 points (moderately suspicious), and TR5:  $\geq 7$  points (highly suspicious). Based on the TIRADS levels and the size of the thyroid nodule, recommendations are given to the patient: TR1: no FNA required; TR2: no FNA required; TR3:  $\geq 1.5$  cm follow up at 1, 3, and 5 years,  $\geq 2.5$  cm FNA; TR4:  $\geq 1.0$  cm follow up at 1, 3, and 5 years,  $\geq 1.5$  cm FNA; and TR5:  $\geq 0.5$  cm annual follow-up for up to 5 years,  $\geq 1.0$  cm FNA.<sup>32</sup>

**Table 1** Thyroid nodules with ultrasound features of high, intermediate, and mild suspicion of malignancy according to the American Thyroid Association guidelines.

Risk of malignancy	Ultrasound features
Benign pattern (0% risk)	Completely cystic nodules with well-defined walls
Very low suspicion pattern (<3% risk)	Spongiform nodules and nodules with interspersed cystic spaces, without any of the features in more suspicious patterns
Low suspicion pattern (5–10% risk)	Isoechoic or hyperechoic nodule partially cystic nodule with a peripheral solid component none of the following features: microcalcifications (see other points below*) irregular margins extrathyroidal extension taller than wide
Intermediate suspicion pattern (10–20% risk)	Hypoechoic solid nodule with smooth margins none of the following features: microcalcifications (see other points below*) irregular margins extrathyroidal extension taller than wide
High suspicion pattern (>70–90% risk)	Solid hypoechoic nodule (or solid hypoechoic component of a partially cystic nodule), with at least one of these features: microcalcifications (see other points below*) irregular margins (infiltrative, microlobulated) extrathyroidal extension taller than wide rim calcifications with an extrusive soft tissue component lymphadenopathy * Other points: - Dystrophic calcifications (e.g. coarse macrocalcification, rim calcifications) other than microcalcifications increase risk, but to a lesser degree than microcalcifications. - The cervical lymph nodes must be studied in all neck ultrasounds.

**Cross-sectional imaging:** Additional cross-sectional imaging, including CT, MRI, and PET, can be useful in a minority of select patients. The four common conditions in which cross-sectional imaging of thyroid carcinoma may be performed are as follows: detection of the incidental thyroid nodule, evaluation of thyroid nodal metastases, presurgical imaging for invasive disease, and evaluation for recurrence in the posttreatment neck. FDG-PET/CT is useful in the initial (postthyroidectomy) staging of high-risk patients with less differentiated (and thus less iodine-avid and clinically more aggressive) subtypes, such as tall cell variant and Hürthle cell carcinoma, poorly differentiated, and anaplastic carcinoma. FDG-PET/CT may help in defining the extent of disease in some patients with medullary thyroid carcinoma and rising postoperative calcitonin levels.<sup>33</sup>

**Imaging Nodal Metastases**

Metastasis to cervical nodes is common in papillary carcinoma with a reported incidence varying from 30 to 90%.<sup>34</sup> Spread to neck nodes is also common in medullary carcinoma (50%) and anaplastic carcinoma (40%), while lymphatic spread is less common with follicular carcinoma (10%).<sup>35</sup> US remains the imaging modality of choice for the evaluation of nodal metastases. It can be combined with US-guided FNAC, and the nodes and primary tumor can be evaluated in the same examination. US features of metastatic nodes from thyroid cancer are similar to those from other head and neck

cancers and include a round shape, loss of the nodal hilum, peripheral vascularity, necrosis, and extranodal tumor spread, the latter two features are commonly seen in metastatic nodes from anaplastic carcinoma.<sup>36</sup> Calcification (50–69%), increased echogenicity (87%), and cystic composition (20%) are the characteristic of metastatic nodes from papillary carcinoma with latter being the dominant feature.<sup>37</sup>

**Ultrasound-Guided Fine-Needle Aspiration of Thyroid Nodule/Cervical Lymph Nodes**

The criteria developed by the ATA (2015) are often used in clinical practice.<sup>13</sup> The ACR TIRADS system recommends FNA for TR3 lesions >25 mm, TR4 lesions >15 mm, and TR5 lesions >10 mm.<sup>32</sup> FNA is recommended for any nonbenign lesion (i.e., U3, U4, or U5) by the British Thyroid Association Ultrasound classification.<sup>15</sup> FNA is recommended for nodules <10 mm whenever clinical information or US features raise suspicion for malignancy. Additional recommendations for FNA by the American Association of Clinical Endocrinologists includes nodule of any size with patient history of neck irradiation in childhood or adolescence; papillary thyroid carcinoma, medullary thyroid carcinoma, or multiple endocrine neoplasia type 2 in first-degree relatives; previous thyroid surgery for cancer; increased calcitonin levels in the absence of interfering factors.<sup>14</sup> According to 2021 ATA guidelines, for the initial evaluation of anaplastic carcinoma, FNA cytology can play an important role, but a parallel core

**Table 2** The ultrasound-based thyroid nodule reporting system (TIRADS) proposed by the American College of Radiology including the five categories of ultrasound findings and the point given for each finding. A cumulative score determines the likelihood of malignancy.

Category	Ultrasound finding	Points
Composition (choose one)	Cystic or completely cystic	0
	Spongiform	0
	Mixed cystic and solid	1
	Solid or almost completely solid	2
Echogenicity (choose one)	Anechoic	0
	Hyper- or isoechoic	1
	Hypoechoic	2
	Very hypoechoic	3
Shape (assessed on the transverse plane; choose one)	Wider than tall	0
	Taller than wide	3
Margin (choose one)	Smooth	0
	Ill-defined	0
	Lobulated/irregular	2
	Extra-thyroidal Extension	3
Echogenic foci (choose one or more)	None	0
	Large comet-tail artifact	0
	Macrocalcifications	1
	Peripheral/rim calcifications	2
	Punctate echogenic foci	3

biopsy may be necessary for definitive diagnosis and to obtain a sufficient sample for molecular workup.<sup>13</sup> Once ATC diagnosis is confirmed, assessment of BRAF mutation should be expeditiously performed by IHC and confirmed by molecular testing.<sup>20</sup> Assuming that each thyroid nodule >1 cm carries an independent risk of malignancy and those numerous nodules may necessitate FNA, patients with multiple thyroid nodules >1 cm should be assessed in the same way as patients with a single nodule >1 cm. When multiple nodules >1 cm are present, those with suspicious US features should be aspirated preferentially.<sup>13</sup> It is reasonable to aspirate only the largest nodules (>2 cm) or to continue surveillance without FNA while monitoring the other nodules with serial US examinations if none of the nodules have a high or moderately suspicious sonographic pattern and multiple sonographically similar very low or low suspicion pattern nodules coalesce with no intervening normal parenchyma. In patients with numerous nodules, a low or low-normal serum TSH levels may imply that one or more nodules may be autonomous. To establish the functionality of any nodule larger than 1 cm in such circumstances, a radioactive thyroid scan should be considered and directly compared with the US pictures. FNA should then be considered only for those iso-functioning or nonfunctioning nodules, among which

those with high-suspicion sonographic pattern should be aspirated preferentially.<sup>13</sup>

**Procedure**

To ensure accuracy, the needle tip must be visualized within the target thyroid nodule/lymph node during the FNA. If the entire nodule/lymph node is morphologically abnormal on US, then the FNA specimen can be obtained by moving the needle tip throughout the lymph node. Else, the needle tip should be targeted to the suspicious component of the nodule/node. For solid/cystic nodules/lymph nodes, a solid vascular portion should be targeted (unless fluid is required for Tg analysis). For US-guided FNA, a parallel or a perpendicular approach can be employed. In the parallel approach, the needle is visualized along its entire length as it enters the lymph node. Only the needle's tip can be visible when using a perpendicular approach. Either a 25-gauge or a 27-gauge needle can be used. Confirm that the needle tip is within the suspicious component of the nodule/node and then obtain the cytology specimen by either the capillary or the aspiration technique. The needle tip is moved back and forth through the diameter of the target without suction, in the capillary technique. Suction is used in the aspiration technique as the needle tip is moved. For thyroid nodule FNA, the recent literature has shown low nondiagnostic rates using smaller gauge needles and the capillary action technique.<sup>38,39</sup> The cytology specimen can be prepared using a liquid preparation or by creating a slide smear. If on-site adequacy assessment by a trained cytologist is not available, the preferred number is three to four passes.<sup>40</sup> In addition to cytology analysis, Tg measurement from the FNA needle washout (FNA-Tg) has been shown to improve the sensitivity of US FNA cytology alone.<sup>41</sup> Published reports have suggested a cut-off FNA-Tg level in the 1 ng/mL range for washouts prepared with up to 1 mL of diluent, though the serum Tg level, which may be higher in patients with a large volume of residual cancer or an intact thyroid gland, must be considered.<sup>42</sup> The use of FNA-Tg is especially vital for cystic lymph nodes, only macrophages and no epithelial cells may be seen in cytology. FNA washout for calcitonin measurement can also be performed in MTC for the diagnosis of metastatic lymph nodes.<sup>22</sup>

For reporting thyroid cytopathological results, the Bethesda System for Reporting Thyroid Cytopathology developed a standardized, category-based reporting system for thyroid FNA specimens. The 2017 revision reaffirms that every thyroid FNA report should begin with one of six diagnostic categories: (1) nondiagnostic or unsatisfactory; (2) benign; (3) atypia of undetermined significance or follicular lesion of undetermined significance; (4) follicular neoplasm or suspicious for a follicular neoplasm; (5) suspicious for malignancy; and (6) malignant.<sup>43</sup>

**Staging**

The American Joint Committee on Cancer (AJCC) have developed different tumor-node-metastasis (TNM) classification for differentiated, anaplastic and for medullary thyroid cancer which have been discussed in ►Table 3–5 and 6.<sup>44–46</sup>



**Table 3** T (Tumor) classification of TNM classification for differentiated, medullary, and anaplastic thyroid cancer

Tx	Primary tumor cannot be assessed
T0	No evidence of primary tumor is found
T1	Tumor size ≤ 2 cm in greatest dimension and is limited to the thyroid
T1 a	Tumor ≤ 1 cm, limited to the thyroid
T1 b	Tumor > 1 cm but ≤ 2 cm in greatest dimension, limited to the thyroid
T2	Tumor size > 2 cm but ≤ 4 cm, limited to the thyroid
T3	Tumor size > 4 cm, limited to the thyroid or any tumor with gross extrathyroidal extension invading only strap muscles
T3 a	Tumor size > 4 cm, limited to the thyroid
T3 b	Any size tumor with gross extrathyroidal extension invading only strap muscles (e.g., extension to sternothyroid, sternohyoid, thyrohyoid, or omohyoid muscles)
T4 a	Any size tumor with gross extrathyroidal extension invading subcutaneous soft tissues, larynx, trachea, esophagus, or recurrent laryngeal nerve
T4 b	Any size tumor with gross extrathyroidal extension invading prevertebral fascia or encasing the carotid artery or mediastinal vessels

Abbreviation: TNM, tumor-node-metastasis.

**Table 4** N (Regional lymph nodes) classification of TNM Classification for differentiated, medullary, and anaplastic thyroid cancer: N include central compartment, lateral cervical, and upper mediastinal lymph nodes

NX	Regional nodes cannot be assessed
N0	No regional lymph node metastasis
N0a	One or more cytologically or histologically confirmed benign lymph nodes
N0b	No radiologic or clinical evidence of locoregional lymph node metastasis
N1	Regional lymph node metastasis
N1a	Metastases to level VI or VII (pretracheal, paratracheal, or prelaryngeal/Delphian or upper mediastinal) lymph nodes; can be unilateral or bilateral disease
N1b	Metastases to unilateral, bilateral, or contralateral neck lymph nodes (levels I, II, III, IV, or V) or retropharyngeal lymph nodes
NX	Regional nodes cannot be assessed

Abbreviation: TNM, tumor-node-metastasis.

**Table 5** M (Distant metastasis) classification of TNM classification for differentiated, medullary and anaplastic thyroid cancer

M0	No distant metastasis is found
M1	Distant metastasis is present

Abbreviation: TNM, tumor-node-metastasis.

**Management**

The mainstay of treatment of thyroid cancer is surgery. It may be supplemented by RAI ablation/therapy in high-risk DTC. Many risk stratification systems have been developed for patients with DTC including GAMES (grade, age, metastases, extrathyroidal extension, size) which was developed in the 1990s and is still used to predict cancer mortality.<sup>47</sup> Age, presence of distant metastases, presence of gross extrathyroidal extension, and aggressive histological features are some of the criteria used to prognosticate disease outcomes. A recent large cohort of patients from the National Cancer Data Base (NCDB) has suggested that nodal disease is also associated with poorer overall survival in young patient.<sup>47</sup>

**Principles of Management**

*2015 ATA guidelines for DTC*<sup>13</sup>: Hemithyroidectomy is recommended for low-risk tumor that are less than or equal to 1 cm. Diagnostic lobectomy should be considered for patients with a solitary, cytologically indeterminate nodule, as an initial surgical approach. The high-risk cases and tumors more than 4 cm in size should undergo total thyroidectomy. The incidence of regional metastasis is high in DTC, and the first draining node is level VI. Therapeutic neck dissection involves clearing level VI nodes in central compartment node-positive patients. Prophylactic central compartment dissection is not recommended routinely in low risk and T1/T2 tumors due to the associated morbidity of RLN injury or hypoparathyroidism. ATA recommends prophylactic central compartment dissection for locally advanced tumors, when the lateral compartment has metastasis or if such clearance helps in decision-making. Lateral compartment dissection involves clearing level II–V nodes in positive regional metastasis. Total thyroidectomy is preferred in patients with lesions >4 cm in size, multifocal disease,

**Table 6** Stage groups for DTC, ATC and MTC

Stage	T	N	M
Differentiated thyroid cancer (DTC)			
If age at diagnosis <55 y:			
I	Any T	Any N	M0
II	Any T	Any N	M1
If age at diagnosis ≥55 y:			
I	T1, T2	N0, Nx	M0
II	T1, T2	N1	M0
	T3	Any N	M0
III	T4a	Any N	M0
IV A	T4b	Any N	M0
IV B	Any T	Any N	M1
Anaplastic thyroid cancer (ATC)			
IV A	T1, T2, T3a	N0, Nx	M0
IV B	T1, T2, T3a	N1	M0
	T3b, T4	Any N	M0
IV C	Any T	Any M	M1
Medullary thyroid cancer (MTC)			
I	T1	N0	M0
II	T2, T3	N0	M0
III	T1, T2, T3	N1 a	M0
IV A	T1, T2, T3	N1 b	M0
	T4a	Any N	M0
IV B	T4b	Any N	M0
IV C	Any T	Any N	M1

positive for known mutations specific for carcinoma, cases of familial thyroid carcinoma or history of radiation exposure, and in cases with regional or distant metastasis which will be followed by RAI administration. Patients with indeterminate nodules who have the bilateral nodular disease, those with significant medical comorbidities, or those who prefer to undergo bilateral thyroidectomy to avoid the possibility of requiring a future surgery on the contralateral lobe, may undergo total thyroidectomy, assuming completion thyroidectomy would be recommended if the indeterminate nodule proved malignant following lobectomy. Surgery may be considered for growing nodules that are benign after repeat FNA if they are large (>4 cm), causing compressive or structural symptoms, or based upon clinical concern. Benign recurrent cystic thyroid nodules should be considered for surgical removal or percutaneous ethanol injection based on compressive symptoms and cosmetic concerns. Asymptomatic cystic nodules may be followed conservatively.<sup>13</sup> Management of MTC and ATC is as per the 2015 ATA guidelines for MTC and 2021 ATA guidelines for ATC.<sup>19,20</sup> The minimum surgery recommended for MTC is total thyroidectomy along with central compartment clearance. Therapeutic neck dissection clearing level II–V should be performed in cases with

regional metastasis. In the absence of regional metastasis, the decision regarding prophylactic neck dissection should be based on the calcitonin levels. For patients with confined (stage IVA/IVB) ATC in whom RO/R1 resection is anticipated, surgical resection is strongly recommended. Given the poor prognosis of ATC, radical resection (such as laryngectomy, tracheal/esophageal resections, and/or major vascular resections) is typically not advised and should only be considered very selectively after thorough discussion by the multidisciplinary team, as well as considering new information based upon present mutations and the availability of targeted therapies.

### Follow-up

Cases with raised Tg level should undergo US of the neck to detect any locoregional recurrence which is then confirmed by performing the FNAC. However, Tg antibodies cause falsely low serum Tg level that can mask the presence of recurrent disease.<sup>49</sup> The stimulated Tg testing for recurrent thyroid cancer generally provides effective surveillance against disease recurrence, with a high negative predictive value (NPV) of 99%.<sup>50</sup> US is a very sensitive modality for detecting abnormal lymph nodes and masses in the thyroid bed and may also demonstrate persistent disease despite a negative stimulated Tg measurement. Thus, the ATA guidelines have emphasized the role of neck US in the follow-up of patients with PTC.<sup>13</sup> The combination of stimulated Tg and neck US has been found to have a 96.3% sensitivity in detecting locoregional disease, as well as an NPV of 99.5%.<sup>51</sup> The US finding of nodularity in the post-thyroidectomy bed is generally suspicious. Benign lesions causing nodules in the thyroid bed may be due to postoperative fibrosis, suture granulomata, reactive lymph nodes, parathyroid adenoma, and remnant thyroid tissue.<sup>49</sup>

### Follow-up Imaging and Management of Recurrent Disease Including Specific Interventional and Palliative Measures

A patient's response to initial therapy is measured with careful clinical assessment and review of serial Tg and antibody levels and can be classified into four categories: excellent, biochemically incomplete, structurally incomplete, or indeterminate. Six monthly nonstimulated Tg measurements and 12-monthly neck US is done for low-risk patients. Tg values have the highest sensitivity and specificity for the detection of recurrent disease after total thyroidectomy and RAI ablation. Serum Tg levels should be very low after total thyroidectomy with (<1 to 2 ng/mL) or without RAI ablation (<5ng/mL). A progressive increase in serum Tg concentrations suggests recurrence and raises the need to perform imaging. High-resolution neck US can detect nodules as small as 2 to 3 mm in diameter. Only nodules 8 to 10 mm in size should be considered for biopsy. The sample should be sent for cytology and Tg measurement from the needle washout fluid. Suspicious lymph nodes less than 8 to 10 mm can be followed without biopsy with consideration for FNA or intervention if there is growth or if the node threatens vital structures such as a

functional recurrent laryngeal nerve. If there are no abnormalities within the first 2 years, patients are deemed to have an excellent response to therapy with a very low risk of recurrence and no additional surveillance is required. For the small group of patients with biochemical or structural persistent disease, surveillance beyond 2 years is needed. Surveillance of the intermediate-risk patients is 2 years in the absence of suspicious findings. Follow-up is similar to the low-risk group with the additional diagnostic RAI scan at 18 months to detect potential regional or distant disease. Routine cross-sectional imaging is limited to high-risk patients and those with raised Tg or abnormalities on the neck US. CECT of the neck and chest is advised for high-risk individuals and those who have growing Tg levels without obvious neck disease. MRI is recommended where CECT is contraindicated. Surveillance RAI scans can be useful in select patients if further RAI therapy is warranted. FDG-PET may be considered in patients in whom there is a suspicion of dedifferentiated disease.<sup>52</sup>

### Management of Recurrent Disease

Small volume suspicious nodes on US can be managed with serial follow-up US. FNA should be performed when there is evidence of disease progression or proximity to vital structures such as the recurrent laryngeal nerve with a view to revision surgery. For LNs more than 10 mm in size, in the previously undissected neck, a comprehensive neck dissection with preservation of uninvolved vital structures should be done. In the previously dissected neck, a limited neck dissection is performed in selected patients. Surgical resection in combination with RAI therapy is recommended for palpable nodal disease. At 5 years, subsequent nodal and distant recurrence-free survival are 89.2 and 93.7%, respectively.<sup>52</sup>

### Role of Ultrasound in Active Surveillance in Papillary Microcarcinoma

The recent update of the ATA guidelines (2015) incorporated active surveillance in management guidelines making it an acceptable option for appropriately selected patients with low-risk thyroid cancers to prevent overtreatment for PMCs.<sup>13</sup> Patients with low-risk PMC are those lacking the high-risk characteristics as outlined by Ito and Miyauchi, such as tumors next to the trachea, tumors on the thyroid lobe's dorsal surface, tumors that may have invaded the recurrent laryngeal nerve, high-grade malignancy suggested by FNA biopsy results, presence of regional node metastasis, or presence of distant metastasis. Additionally, the ATA 2015 guideline update includes a few other criteria including patients with multiple comorbid conditions and high surgical risk, patients with short life expectancy (significant cardiopulmonary disease, other malignancies, and advanced age), and patients with concurrent medical or surgical issues needing to be addressed prior to thyroid surgery.<sup>13</sup>

### Summary of Recommendations

- US is the imaging modality of choice for the evaluation of thyroid nodules.
- The American College of Radiology proposed ACRTI-RADS is a widely popular US-based thyroid nodule reporting system.
- ATA guidelines aid in classifying thyroid nodules based on US features into nodules with high, intermediate, and mild suspicion of malignancy.
- The detection of incidental thyroid nodules, assessment of thyroid nodal metastases, presurgical imaging for invasive disease, and evaluation for recurrence in the posttreatment neck are the four frequent circumstances in which cross-sectional imaging of thyroid cancer may be undertaken.

Synoptic reporting formats for radiograph, US, CT and MRI has been provided as **–Supplementary Appendix 1 and 2** at the end of the text.

### Parathyroid Gland, Introduction, Risk factors and Etiopathogenesis

PHPT is characterized by an abnormality in the parathyroid gland which causes excess production of parathyroid hormone and leads to an increase in serum calcium levels.<sup>53</sup> PHPT accounts for the leading cause of hypercalcemia. It is the third most prevalent endocrine condition.<sup>54</sup> A single parathyroid adenoma is the most common cause (85–90%) of PHPT. It may also result from multiglandular hyperplasia (approximately 6%), double parathyroid adenoma (approximately 4%), and parathyroid carcinoma (<1%) in the decreasing order of frequency.<sup>55</sup> The only definitive treatment for this condition remains surgical excision of the abnormal parathyroid.

Women are affected two to three times more often than men.<sup>56</sup> It is caused by the overproduction of PTH. Approximately, 5% of PHPT are part of hereditary syndromes, such as multiple endocrine neoplasia types 1, 2, and 4 (MEN-1, MEN-2, and MEN-4) and hyperparathyroidism-jaw tumor syndrome or as part of nonsyndromic familial pHPT. The rest (95%) are sporadic.<sup>57</sup> Radiation exposure has also been proposed as an etiology of pHPT, and this association was observed in subjects exposed to radiation fallout following the bombing in Hiroshima and the nuclear power plant accident in Chernobyl.<sup>58</sup>

### Epidemiology, Clinical Presentation in India and Global

Asymptomatic hypercalcemia diagnosed in routine blood investigations is the most common presentation of PHPT. “Bones, stones, abdominal moans, and psychic groans”—best describe the spectrum of clinical manifestations.<sup>58</sup> Skeletal disease, nephrolithiasis, and neurocognitive effects make the classic clinical presentations of PHPT.<sup>59</sup> Leading questions in otherwise asymptomatic subjects identify symptoms like



fatigue, decreased appetite, slowed cognition, and depression.<sup>58</sup> Symptoms including constipation, polydipsia, polyuria, and a decrease in appetite occur due to raised serum calcium levels. There is an association between hypertension, hyperlipidemia, diabetes, obesity, and PHPT.<sup>55</sup> There is an associated increased risk of cardiovascular disease, cerebrovascular disease, renal disease, fractures, and mortality.<sup>60–65</sup> PHPT, hence, poses a significant threat to overall health.<sup>66,67</sup>

## Imaging Referral Guidelines

### Clinical/ Diagnostic Work-Up Excluding Imaging

The evaluation of these patients comprises laboratory tests and localization which are based on imaging. PHPT is essentially diagnosed biochemically. Raised serum calcium levels along with high parathormone levels establish the diagnosis. However, these tests may be complemented with tests to confirm pHPT and rule out other causes of hypercalcemia. Serum phosphate levels are lowered in severe pHPT; 1,25-dihydroxyvitamin D levels either on the higher side of normal or slightly increased and few patients may develop hypomagnesaemia. All patients who undergo imaging should have biochemically proven PHPT.<sup>67</sup>

### Imaging Guidelines

The goal of imaging is to allow the precise localization of the adenoma not diagnosis. US, nuclear imaging, and multiphase (four-dimensional [4D]) CT are the most commonly used imaging modalities for the preoperative localization of the parathyroid disease.<sup>53</sup> Most comparative studies have shown the superiority of 4D CT over other imaging modalities including higher diagnostic accuracy. 4D CT can help locate the disease in challenging scenarios when US and/or nuclear medicine imaging cannot give definitive results in cases of multiglandular disease (MGD), and recurrent PHPT.<sup>68–73</sup> Minimally invasive parathyroidectomy (MIP) can be performed if single adenoma can be accurately localized on imaging. If on imaging MGD is diagnosed, bilateral neck

exploration (BNE) should be planned. If the disease cannot be localized on imaging, surgery can still be performed, but performing BNE might become necessary. Ectopic parathyroid glands have an incidence of approximately 16%.<sup>63</sup> There can be supernumerary glands which are known to exist in 3 to 13% of individuals with the total number of glands varying from 5 to 8.<sup>64,65</sup> The European Association of Nuclear Medicine issued the first edition of the guideline on parathyroid imaging, and several new insights and techniques have been developed since then.

### Parathyroid Four-Dimensional Computed Tomography Imaging

Radiologists play a crucial role in the surgical planning by helping clinicians in identifying and localizing the disease/ abnormal gland. The aim is to provide the clinician with an illustrative picture of the neck, locating lesions with respect to various surgical landmarks.

### Image Acquisition

A three-phase protocol is used, consisting of noncontrast material-enhanced, arterial (beginning 30 seconds after the start of contrast material injection), and venous (beginning 60 seconds after the start of contrast material injection) phases. To reduce beam-hardening artifacts which may obscure small lesions in the lower neck and upper mediastinum, the use of 140 kVp instead of 120 kVp is suggested. The recommended acquisition parameters for 4D CT are listed in **Table 7**.

### Imaging Findings

Parathyroid adenomas are lower in attenuation compared with the normal thyroid gland on noncontrast-enhanced images as normal thyroid parenchyma contains iodine (high density). However, parathyroid adenomas may appear similar in attenuation to abnormal thyroid gland on plain scan in cases of chronic hypothyroidism and autoimmune conditions like Hashimoto disease when the iodine content of the gland is low and thyroid gland shows low attenuation.

**Table 7** Parathyroid 4-D CT protocol<sup>15</sup>

Protocol features	Parameters
Coverage	Maxilla to carina
Iodinated contrast material administration	100 mL (370 mg iodine/mL) injected at 4 mL/s, followed by 40 mL saline flush
Phases	Noncontrast, arterial, venous
Arterial phase	30 s after start of injection
Venous phase	60 s after start of injection
Thickness	1.25 mm
Tube voltage (kVp)	140
Tube current (mA)	Minimum 180 and maximum 300
Noise index	10
Pitch	1.375
DFOV (cm)	25

Abbreviations: CT, computed tomography; DFOV, display field of view.

On contrast-enhanced images, adenomas are known to show higher attenuation in the arterial phase and demonstrate wash-out in the venous phase, consequently having lower attenuation compared with the thyroid gland. These typical imaging findings may be seen in only about one-fifth of adenomas.<sup>73</sup> Parathyroid adenomas may show cystic foci, fat deposition, or calcifications. Common understanding says that MGD is more likely when multiple parathyroid lesions are identified. On the contrary, MGD is also more likely when no lesions can be demonstrated. If the largest lesion picked up on 4D CT measures less than 7 mm, it is likely MGD (79% specificity), even when only a single lesion is identified as lesions in MGD tend to be smaller in size.<sup>74</sup> Significantly raised parathyroid hormone in a young patient with calcifications on imaging should raise suspicion of parathyroid carcinoma, especially in large lesions. Exophytic thyroid nodules are diagnostic mimics of parathyroid adenomas on contrast-enhanced images. This problem can however be solved by evaluating the noncontrast images, where thyroid appears of higher attenuation as compared with parathyroid lesions. Correlation of findings with US can be helpful, where parathyroid adenomas are typically hypoechoic in contrast to thyroid nodules which are either isoechoic or hyperechoic relative to the thyroid gland. Lymph nodes are other common diagnostic mimics of parathyroid adenomas on both contrast and noncontrast-enhanced images, as both are hypoattenuating relative to the thyroid gland. On contrast-enhanced images, lymph nodes exhibit progressive enhancement, whereas parathyroid adenomas show wash-out. Identification of a fatty hilum can also help in differentiation. In patients with pHPT, one or more hyperfunctioning parathyroid glands are localized by radionuclide parathyroid imaging. It can help in the detection of ectopic and supernumerary glands.<sup>75,76</sup>

## Principles of Management

The only definitive cure remains surgical excision of the abnormal parathyroid tissue. Since the most common presentation is a single adenoma, it is excised preserving all other glands. This approach of unilateral exploration is called focused or Minimally Invasive Parathyroidectomy (MIP).<sup>77</sup> Bilateral neck exploration (BNE) is adopted in cases with four gland hyperplasia or in cases where imaging fails to localize the diseased gland. In BNE, all parathyroid glands are examined and abnormal/diseased tissue is resected leaving behind enough remnants to maintain normal calcium homeostasis. This approach usually encompasses the excision of 3 or 3.5 glands.<sup>67</sup> The most normal gland determined after assessing all the parathyroids should be preserved. MEN 1 is usually associated with MGD, and hence, BNE is suggested in the management of these cases. These patients should undergo subtotal or total parathyroidectomy with reimplantation which can be in the sternocleidomastoid muscle or the forearm. These sites should be marked with nonabsorbable sutures or clips to identify in cases when resurgery should occur. On the contrary, MEN 2A is usually mild and more commonly associated with single gland adenoma; therefore,

MIP may be followed in these cases. A single small midline incision may be sufficient for this procedure. In cases of ectopic or supernumerary glands larger incision may be required; hence, their documentation in radiology reports is essential.<sup>67</sup> In BNE, there is risk of injury to both recurrent laryngeal nerves but morbidity caused is low in experienced hands. BNE has been known to provide excellent cure rates. MIP uses smaller incisions and, thus, provides better cosmetic results with lesser operating times, shorter hospital stays, and is less costly. MIP has been known to provide results as good as that of BNE.<sup>78-80</sup> The role of radiologists of ensuring patient undergoing MIP lies in providing precise localization of a solitary parathyroid adenoma. Preoperative imaging is preferred in all patients with PHPT where a surgeon can plan MIP for well-localized solitary adenoma. The recent international guidelines make preoperative localization of parathyroid disease mandatory in patients with persistent or recurrent PHPT after prior parathyroid surgery, in view of higher risks of morbidity with repeat parathyroid surgery.<sup>81</sup>

## Summary of Recommendations

- The radiologists' aim in parathyroid imaging is to provide the clinician with an illustrative picture of the neck, locating lesions with respect to landmarks.
- Imaging helps in the detection of solitary versus multi-glandular disease, ectopic, and supernumerary glands with precise localization.
- On 4DCT imaging, adenomas show higher attenuation than thyroid parenchyma in the arterial phase and demonstrate wash-out on in the venous phase.
- Imaging can help to decide the plan of management by detecting solitary parathyroid adenoma which can undergo Minimally Invasive Parathyroidectomy (MIP) or multi-glandular disease where BNE will have to be done.

## Salivary Glands, Introduction, Risk Factors, and Etiopathogenesis

The etiology of the salivary gland is poorly understood; however, one of the known risk factors of salivary gland neoplasms is irradiation to the head and neck.<sup>82</sup> For instance, an increased incidence was noted in the survivors from Hiroshima and Nagasaki. Male sex, obesity, human immunodeficiency virus infection, family history of cancer, industrial exposure to occupational radiation, formaldehyde, or nickel compounds are associated with an increased risk of salivary gland malignancies.<sup>83,84</sup>

## Epidemiology and Clinical Features

Salivary gland tumors account for approximately 0.5% of all neoplasms. The most common location is the parotid gland (70%), followed by submandibular gland, minor salivary glands, and sublingual gland, in descending order. In the parotid, approximately 80% of neoplasms are benign, while 20% are malignant. Benign pleomorphic adenomas comprise around 65% of all parotid tumors, followed by adenolymphoma

or Warthin's tumor (15–20%). Malignant epithelial salivary gland tumors encompass approximately 20% of parotid tumors, 40 to 50% of submandibular gland tumors, 50% of minor salivary gland tumors, and 90% of sublingual gland tumors. The commonest malignant neoplasms include adenoid cystic carcinoma and mucoepidermoid carcinoma.<sup>85,86</sup> In 2020, 7,850 new cases of salivary gland malignancies were detected in India (0.59%), while 5,127 patients died.<sup>87</sup> Painless palpable mass in the parotid or submandibular gland is the commonest symptom, and enlarged lymph nodes may be seen with malignancies. Pain and facial nerve palsy may be seen with parotid tumors.<sup>88</sup>

### Clinical/ Diagnostic Work-Up Excluding Imaging

The initial step in the workup of salivary gland neoplasms (SGNs) is a thorough history and physical examination. Both Benign and malignant SGNs may typically manifest as a painless lump in the preauricular or submandibular region. However, a prior history of pain, rapid growth, or symptoms suggesting cranial nerve abnormalities should warn of possible malignancy. A physical examination demonstrating severe tenderness, cranial neuropathy including facial or oral cavity weakness or numbness, lymphadenopathy, or fixation of masses to skin or other surrounding structures is usually associated with malignancy.<sup>89,90</sup> ASCO consensus guidelines suggest that FNAC should be performed to establish the tissue diagnosis and to determine the high-grade features. Core needle biopsy should be considered where the FNAC provides inadequate tissue or for deep-seated lesions.

### Imaging Referral Guidelines

Appropriate selection and use of imaging studies are crucial for the proper management of patients with SGNs. As per NCCN guidelines, initial evaluation with imaging of the primary site is to be done with CT and/or MRI. MRI is generally preferred over CT in patients with suspected SGNs because of the superior soft-tissue resolution and its ability to better delineate perineural invasion. Contrast enhanced MRI (CE-MRI) is the preferred modality if there is suspected intracranial extension. Diffusion weighted imaging (DWI) offers additional information that may increase the concern for malignancy. However, CT is complementary to MRI for the evaluation of bony erosion or cartilage invasion.<sup>91–93</sup>

Imaging recommendations by American Society of Clinical Oncology (ASCO) guidelines<sup>94</sup>:

1. Imaging with neck US, CT with intravenous contrast, and/or MRI of the neck and primary site should be performed in patients with a suspicion of a salivary gland tumor.
2. US may be used for the initial evaluation of a new mass in adult patients, differentiating extra from intraglandular masses and identifying features that are suspicious for malignancy.

3. When there is a concern for malignancy such as neck adenopathy or cranial nerve dysfunction or full tumor delineation is required for operative planning, CE-MRI of the glands and neck is recommended particularly when there is a concern for skull base invasion and/or perineural tumor spread along the large named nerves.
4. In patients with suspicion of salivary gland cancer and involvement of adjacent bone, CT of the neck with IV contrast should be performed.
5. CE-MRI with a diffusion sequence of the neck and skull base is recommended for patients with suspicion of salivary gland cancer with concern for perineural invasion and/or skull base involvement.
6. PET/CT from the skull base to mid-thighs may be performed for patients with advanced-stage high-grade salivary gland cancers. Although there is no literature to support the use of 18 F-FDG PET/CT for initial evaluation as it has poor spatial resolution, it most accurately predicts the extent of nodal and distant metastasis disease and identifies locoregional recurrence.<sup>95</sup>

### Imaging Recommendations for Diagnosis, Staging, and Management of Salivary Gland Tumors

Imaging plays a pivotal role in masses of salivary gland origin by defining its location, detecting malignant features, assessing local extension and invasion, staging the tumors according to the TNM classification, and also to assess the feasibility of surgery, being the primary treatment of most salivary gland tumors. It defines the location of the salivary gland tumors, whether it is intra- or extraglandular or is superficial or deep to the facial nerve, laterality (unilateral or bilateral), focality (unifocal or multifocal), characteristics of the tumor, the presence of perineural spread (PNS), and detects nodal metastasis and distant/systemic involvement. High-resolution US is the preferred initial imaging modality for lesions involving the superficial part of the parotid, submandibular, and sublingual gland as it provides excellent resolution and characterization of lesions as well as cervical node involvement without a radiation hazard. However, for all tumors detected in the sublingual gland, an MRI should be performed as the risk of malignancy is high. It is readily combined with FNAC. On the contrary, MRI is indicated in all patients with lesions of the deep lobe of parotid gland, minor salivary gland tumors, and a malignant tumor is suspected clinically.

#### Imaging in Diagnosis

##### Ultrasound

High-resolution US using a probe of frequency of 5 to 12 MHz with the Doppler technique plays an important role in the initial diagnostic workup for superficial parotid and submandibular swelling. It should be done bilaterally in paired glands in the same session. Benign tumors of the salivary gland are more common than the malignant lesions (3%).<sup>96</sup> US helps in the diagnosis of benign tumors by characterizing the size, echogenicity, margins, and vascularity of the lesion.

US is also an optimal tool to guide fine-needle aspiration cytology with its easy availability and ability to provide real-time image guidance and has two salient roles namely, diagnosis of primary and staging of lymph node metastases. The pitfall of US in diagnosis is its limited visualization of the deep lobe of the parotid gland.<sup>97</sup> The minor salivary glands are also located in the mucosa of the oral cavity, pharynx, and tracheobronchial tree, but these areas are inaccessible for the evaluation by US. Additionally, as the first station, nodal drainage from the oral cavity and pharyngeal mucosal space is retropharyngeal nodes, it is also not accessible by conventional US. High variability of results has been reported for US studies, with sensitivity ranging from 62 to 84%, specificity from 88 to 96%, and accuracy from 57 to 96%,<sup>19</sup> with the plausible reason being that US is an operator-dependent modality.

### Magnetic Resonance Imaging

MRI remains the favored imaging modality for staging and is indicated in all patients in whom a malignant tumor is suspected clinically because of its invaluable soft tissue contrast and multiplanar representation, detecting deep tissue extension, marrow infiltration, and importantly PNS and localizing parotid portion of facial nerve using high-resolution techniques. Routine locoregional tumor mapping is based on high-resolution multiplanar turbo spin-echo (TSE) T1, T2, and postcontrast (gadolinium) images with fat saturation (FS). With the administration of contrast, depiction of subtle tumor extension is possible, however, the main function is in the assessment of invasion into adjacent structures and demonstration of abnormal nodular enhancement along the facial or trigeminal nerves suggestive of PNS.<sup>98</sup> Typical imaging characteristics of high-grade malignant salivary gland tumors are ill-defined borders, low T2 SI, adjacent tissue or compartment invasion, heterogeneous enhancement, central necrosis, cystic changes, and bone erosion, whereas low-grade malignant tumors may resemble benign lesions showing well-defined borders, circumscribed margins, high T2 SI, and homogenous postcontrast enhancement.<sup>99</sup> Lymph node metastases are a feature of malignant tumors. DWI is also used for the differentiation of malignant from benign tumors as high-grade malignant tumors show an apparent diffusion coefficient value between 0.79 and 1.10, 103 /mm<sup>2</sup>/s, which is significantly lower than that of benign tumors.<sup>100</sup> Time-intensity curves are plotted with the help of dynamic contrast-enhanced MR, showing four different patterns: type A—persistent pattern (T-peak of >120 s without washout ratio—WR) representing benign disease, type B—plateau pattern (T-peak of >120 seconds with > 30% WR) representing Warthin's tumors, type C—washout pattern (T-peak of <120 seconds with < 30% WR) representing malignant and benign neoplasms, and type D—flat pattern which is flat curve representing cysts.<sup>101</sup>

### Contrast-Enhanced Computed Tomography

Indications of performing CECT are a contraindication to MRI (claustrophobia, cardiac pacemaker, or ferro metallic prosthesis) or as an adjunct to MRI with suspicious bone

erosion. Thin slices are acquired (0.6–1.0 mm) with both high kernel bone and soft tissue algorithms and multiplanar reconstruction.

### Fluorodeoxyglucose Positron Emission Tomography Computed Tomography

The role of FDG PET/CT in the initial staging of salivary gland tumors is currently controversial; however, early detection of distant metastasis is one of its advantages. Distant metastases are common at presentation with high-grade malignant tumors as compared with low grade and also they show low avidity for FDG PET CT is not routinely recommended for the evaluation of low-grade malignant tumors.<sup>102</sup>

### Imaging During Follow-Up

Clinical examination becomes onerous after curative treatment due to altered anatomy and fibrosis. Seventy percent of recurrences of high-grade malignant tumors are within three years; hence, follow-up periods are reported from 3 to 10 years or lifelong.<sup>103,104</sup> The most common sites of distant metastasis are located within the lung followed by bones, liver, and brain.

- US: It is a rapid, easily available modality to differentiate solid from cystic lesions in the superficial areas of the head and neck, look for its vascularity, and to rule out nodal recurrence. Additionally, US-guided FNAC helps in establishing the diagnosis of recurrent disease or nonmalignant complications.

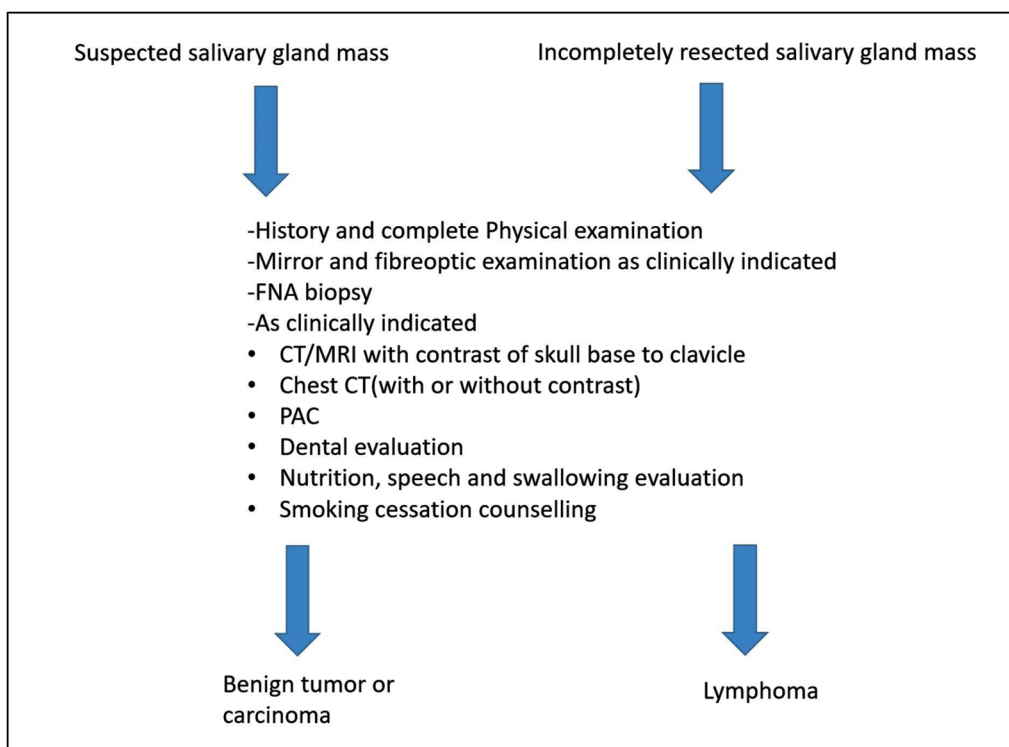
- MRI: MRI with DWI and DCE-MRI helps in the recognition of early recurrent disease during follow-up. It is recommended to have a baseline study at 3 months after the completion of therapy that serves as an invaluable road map and increases the level of confidence to demonstrate or exclude recurrent disease.<sup>105</sup> As per the ASCO consensus guidelines, serial MRI should be performed at 6 to 12 months for initial 2 years in cases where the probability of locoregional recurrence is high including high-grade tumors and locally advanced tumors. Subsequent to it, imaging should be performed in accordance with the symptoms and clinical examination findings. After the completion of 5 years, chest CT may be performed to detect distant metastasis in cases with high-risk histopathology features.

- FDG PET/CT: Recent papers do not demonstrate a significant contribution during surveillance due to a lot of false-positive and false-negative results.<sup>106</sup>

### Principles of Management

Surgery is the mainstay of treatment and should be offered to all patients with a resectable locoregional disease without distant metastasis. The surgery for the primary thyroid disease is determined by the extent of local disease. Superficial parotidectomy is done for small lesions confined to the superficial lobe, total conservative parotidectomy for tumors reaching or involving the deep lobe, T3/4 or high-grade





**Fig. 1** Imaging recommendations by NCCN guidelines.

tumors and radical or extended radical parotidectomy for extensive disease involving the surrounding structures. Every attempt should be made to preserve the functional facial nerve which should only be sacrificed if grossly infiltrated or involved by the disease. Elective neck dissection clearing level II–IV should be performed for high-grade tumors and locally advanced T3/4 lesions. Therapeutic neck dissection clearing level I–V should be done in cases with regional metastasis. Adjuvant radiotherapy should be administered based on the high-risk features on histopathology like high grade, T3/4 disease, regional metastasis, perineural invasion, lymphovascular emboli, etc. Any locoregional recurrence if completely resectable should be excised and adjuvant radiotherapy if feasible should be offered. Even if the patients develop distant metastasis locoregional disease clearance should be considered especially in low-grade tumors if the metastasis is not rapidly progressing or endangering life. Radiotherapy should be recommended for unresectable tumors. The role of upfront or adjuvant chemotherapy is not established and hence such an approach should be considered mainly in a trial setting (ref ASCO consensus guidelines).

Conventional follow-up surveillance regimens include a detailed history and clinical examination every 1 to 3 months for the 1st year after completion of treatment, every 2 to 6 months in the second year, and every 4 to 8 months for years 3 to 5. When 5 years have elapsed after the completion of treatment without evidence of recurrence, the patient may follow up on an annual basis. Reimaging of the primary site and neck may be considered for anatomic areas difficult to visualize or palpate on clinical examination. MRI is the

modality of choice for reimaging. PET/CT has limited utility in initial staging and has little utility in routine posttreatment surveillance. Chest imaging with CT with or without contrast should be obtained for surveillance imaging in ACC, due to the propensity for delayed distant metastatic disease.

#### Conflict Of Interest

None declared.

#### References

- 1 Tufano RP, Clayman G, Heller KS, et al; American Thyroid Association Surgical Affairs Committee Writing Task Force. Management of recurrent/persistent nodal disease in patients with differentiated thyroid cancer: a critical review of the risks and benefits of surgical intervention versus active surveillance. *Thyroid* 2015;25(01):15–27
- 2 Noone AM, Cronin KA, Altekruze SF, et al. Cancer incidence and survival trends by subtype using data from the surveillance epidemiology and end results program, 1992–2013. *Cancer Epidemiol Biomarkers Prev* 2017;26(04):632–641
- 3 John AM, Jacob PM, Oommen R, Nair S, Nair A, Rajaratnam S. Our experience with papillary thyroid microcancer. *Indian J Endocrinol Metab* 2014;18(03):410–413
- 4 Liu Y, Su L, Xiao H. Review of factors related to the thyroid cancer epidemic. *Int J Endocrinol* 2017;2017:5308635
- 5 Crnčić TB, Tomaš MI, Girotto N, Ivanković SG. Risk factors for thyroid cancer: what do we know so far? *Acta Clin Croat* 2020;59 (Suppl 1):66–72
- 6 Bonnefond S, Davies TF. Thyroid cancer-risks and causes. *Oncol Hematol Rev* 2014;10(02):14451
- 7 Xing M. Molecular pathogenesis and mechanisms of thyroid cancer. *Nat Rev Cancer* 2013;13(03):184–199
- 8 Patel KN, Yip L, Lubitz CC, et al. The American Association of Endocrine Surgeons Guidelines for the definitive surgical



- management of thyroid disease in adults. *Ann Surg* 2020;271(03):e21–e93
- 9 Sung H, Ferlay J, Siegel RL, et al. Global cancer statistics 2020: GLOBOCAN estimates of incidence and mortality worldwide for 36 cancers in 185 countries. *CA Cancer J Clin* 2021;71(03):209–249
  - 10 O'Neill CJ, Oucharek J, Learoyd D, Sidhu SB. Standard and emerging therapies for metastatic differentiated thyroid cancer. *Oncologist* 2010;15(02):146–156
  - 11 Lechner MG, Hershman JM. *Thyroid Nodules and Cancer in the Elderly*. In: *Endotext*. South Dartmouth, MA: MDText.com, Inc.; 2000 PMID: 25905203.
  - 12 Lee JY, Baek JH, Ha EJ, et al; Korean Society of Thyroid Radiology (KSThR) and Korean Society of Radiology. 2020 imaging guidelines for thyroid nodules and differentiated thyroid cancer: Korean Society of Thyroid Radiology. *Korean J Radiol* 2021;22(05):840–860
  - 13 Haugen BR, Alexander EK, Bible KC, et al. 2015 American Thyroid Association Management Guidelines for adult patients with thyroid nodules and differentiated thyroid cancer: The American Thyroid Association Guidelines task force on thyroid nodules and differentiated thyroid cancer. *Thyroid* 2016;26(01):1–133
  - 14 Gharib H, Papini E, Paschke R, et al; AACE/AME/ETA Task Force on Thyroid Nodules. American Association of Clinical Endocrinologists, Associazione Medici Endocrinologi, and European Thyroid Association medical guidelines for clinical practice for the diagnosis and management of thyroid nodules: executive Summary of recommendations. *J Endocrinol Invest* 2010;33(5, Suppl):287–291
  - 15 Perros P, Boelaert K, Colley S, et al; British Thyroid Association. Guidelines for the management of thyroid cancer. *Clin Endocrinol (Oxf)* 2014;81(Suppl 1):1–122
  - 16 Shin JH, Baek JH, Chung J, et al; Korean Society of Thyroid Radiology (KSThR) and Korean Society of Radiology. Ultrasonography diagnosis and imaging-based management of thyroid nodules: revised Korean Society of Thyroid Radiology Consensus Statement and Recommendations. *Korean J Radiol* 2016;17(03):370–395
  - 17 Yi KH, Park YJ, Koong SS, et al. Revised Korean Thyroid Association management guidelines for patients with thyroid nodules and thyroid cancer. *Endocrinol Metab (Seoul)* 2010;25(04):270–297
  - 18 www.nccn.org
  - 19 Wells SAJ Jr, Asa SL, Dralle H, et al; American Thyroid Association Guidelines Task Force on Medullary Thyroid Carcinoma. Revised American Thyroid Association guidelines for the management of medullary thyroid carcinoma. *Thyroid* 2015;25(06):567–610
  - 20 Bible KC, Kebebew E, Brierley J, et al. 2021 American thyroid association guidelines for management of patients with anaplastic thyroid cancer: American thyroid association anaplastic thyroid cancer guidelines task force. *Thyroid* 2021;31(03):337–386
  - 21 Seib CD, Harari A, Conte FA, Duh QY, Clark OH, Gosnell JE. Utility of serum thyroglobulin measurements after prophylactic thyroidectomy in patients with hereditary medullary thyroid cancer. *Surgery* 2014;156(02):394–398
  - 22 Cibas ES, Ali SZ. The 2017 Bethesda System for reporting thyroid cytopathology. *Thyroid* 2017;27(11):1341–1346
  - 23 Birtwhistle R, Morissette K, Dickinson JA, et al; Canadian Task Force on Preventive Health Care. Recommendation on screening adults for asymptomatic thyroid dysfunction in primary care. *CMAJ* 2019;191(46):E1274–E1280
  - 24 Morrison SA, Suh H, Hodin RA. The surgical management of thyroid cancer. *Rambam Maimonides Med J* 2014;5(02):e0008
  - 25 Wong KT, Ahuja AT. Ultrasound of thyroid cancer. *Cancer Imaging* 2005;5(01):157–166
  - 26 Chng CL, Tan HC, Too CW, et al. Diagnostic performance of ATA, BTA and TIRADS sonographic patterns in the prediction of malignancy in histologically proven thyroid nodules. *Singapore Med J* 2018;59(11):578–583
  - 27 Gharib H, Papini E, Garber JR, et al; American association of clinical endocrinologists, American college of endocrinology, and Associazione Medici Endocrinologi medical guidelines for clinical practice for the diagnosis and management of thyroid nodules-2016 update appendix. *Endocrine practice* 2016;22:1–60
  - 28 Lee YJ, Kim DW, Shin GW, et al. Comparison of ultrasonography features and K-TIRADS for isthmic and lobar papillary thyroid carcinomas: a single-center study. *Front Endocrinol (Lausanne)* 2020;11:328
  - 29 Russ G, Bonnema SJ, Erdogan MF, Durante C, Ngu R, Leenhardt L. European thyroid association guidelines for ultrasound malignancy risk stratification of thyroid nodules in adults: the EU-TIRADS. *Eur Thyroid J* 2017;6(05):225–237
  - 30 Tessler FN, Middleton WD, Grant EG, et al. ACR Thyroid Imaging, Reporting and Data System (TI-RADS): white paper of the ACR TI-RADS committee. *J Am Coll Radiol* 2017;14(05):587–595
  - 31 Grani G, Lamartina L, Ascoli V, et al. Reducing the number of unnecessary thyroid biopsies while improving diagnostic accuracy: toward the “right” TIRADS. *J Clin Endocrinol Metab* 2019;104(01):95–102
  - 32 Tessler FN, Middleton WD, Grant EG, et al. ACR Thyroid Imaging, Reporting and Data System (TI-RADS): white paper of the ACR TI-RADS Committee. *J Amer Coll Radiol* 2017;14(05):587–595
  - 33 Hoang JK, Branstetter BF IV, Gafton AR, Lee WK, Glastonbury CM. Imaging of thyroid carcinoma with CT and MRI: approaches to common scenarios. *Cancer Imaging* 2013;13(01):128–139
  - 34 Kebebew E, Clark OH. Differentiated thyroid cancer: “complete” rational approach. *World J Surg* 2000;24(08):942–951
  - 35 King AD. Imaging for staging and management of thyroid cancer. *Cancer Imaging* 2008;8(01):57–69
  - 36 Ahuja AT, Chow L, Chick W, King W, Metreweli C. Metastatic cervical nodes in papillary carcinoma of the thyroid: ultrasound and histological correlation. *Clin Radiol* 1995;50(04):229–231
  - 37 Yeh MW, Bauer AJ, Bernet VA, et al; American Thyroid Association Surgical Affairs Committee Writing Task Force. American Thyroid Association statement on preoperative imaging for thyroid cancer surgery. *Thyroid* 2015;25(01):3–14
  - 38 Kim MJ, Kim EK, Park SI, et al. US-guided fine-needle aspiration of thyroid nodules: indications, techniques, results. *Radiographics* 2008;28(07):1869–1886, discussion 1887
  - 39 Bhatki AM, Brewer B, Robinson-Smith T, Nikiforov Y, Steward DL. Adequacy of surgeon-performed ultrasound-guided thyroid fine-needle aspiration biopsy. *Otolaryngol Head Neck Surg* 2008;139(01):27–31
  - 40 Boi F, Baghino G, Atzeni F, Lai ML, Faa G, Mariotti S. The diagnostic value for differentiated thyroid carcinoma metastases of thyroglobulin (Tg) measurement in washout fluid from fine-needle aspiration biopsy of neck lymph nodes is maintained in the presence of circulating anti-Tg antibodies. *J Clin Endocrinol Metab* 2006;91(04):1364–1369
  - 41 Snozek CL, Chambers EP, Reading CC, et al. Serum thyroglobulin, high-resolution ultrasound, and lymph node thyroglobulin in diagnosis of differentiated thyroid carcinoma nodal metastases. *J Clin Endocrinol Metab* 2007;92(11):4278–4281
  - 42 Boi F, Maurelli I, Pinna G, et al. Calcitonin measurement in washout fluid from fine needle aspiration of neck masses in patients with primary and metastatic medullary thyroid carcinoma. *J Clin Endocrinol Metab* 2007;92(06):2115–2118
  - 43 Tran Cao HS, Johnston LE, Chang DC, Bouvet M. A critical analysis of the American Joint Committee on Cancer (AJCC) staging system for differentiated thyroid carcinoma in young patients on the basis of the Surveillance, Epidemiology, and End Results (SEER) registry. *Surgery* 2012;152(02):145–151
  - 44 Adam MA, Thomas S, Roman SA, Hyslop T, Sosa JA. Rethinking the current American Joint Committee on cancer TNM Staging

- system for medullary thyroid cancer. *JAMA Surg* 2017;152(09):869–876
- 45 Perrier ND, Brierley JD, Tuttle RM. Differentiated and anaplastic thyroid carcinoma: major changes in the American Joint Committee on Cancer eighth edition cancer staging manual. *CA Cancer J Clin* 2018;68(01):55–63
  - 46 Lang BH, Lo CY, Chan WF, Lam KY, Wan KY. Staging systems for papillary thyroid carcinoma: a review and comparison. *Ann Surg* 2007;245(03):366–378
  - 47 Adam MA, Pura J, Goffredo P, et al. Presence and number of lymph node metastases are associated with compromised survival for patients younger than age 45 years with papillary thyroid cancer. *J Clin Oncol* 2015;33(21):2370–2375
  - 48 Zaheer S, Tan A, Ang ES, et al. Post-thyroidectomy neck ultrasonography in patients with thyroid cancer and a review of the literature. *Singapore Med J* 2014;55(04):177–182, quiz 183
  - 49 Schlumberger M, Berg G, Cohen O, et al. Follow-up of low-risk patients with differentiated thyroid carcinoma: a European perspective. *Eur J Endocrinol* 2004;150(02):105–112
  - 50 Pacini F, Molinaro E, Castagna MG, et al. Recombinant human thyrotropin-stimulated serum thyroglobulin combined with neck ultrasonography has the highest sensitivity in monitoring differentiated thyroid carcinoma. *J Clin Endocrinol Metab* 2003;88(08):3668–3673
  - 51 Wang LY, Ganly I. Post-treatment surveillance of thyroid cancer. *Eur J Surg Oncol* 2018;44(03):357–366
  - 52 Ito Y, Miyauchi A. Active surveillance of low-risk papillary thyroid microcarcinomas. *Gland Surg* 2020;9(05):1663–1673
  - 53 Bunch PM, Kelly HR. Preoperative imaging techniques in primary hyperparathyroidism: a review. *JAMA Otolaryngol Head Neck Surg* 2018;144(10):929–937
  - 54 Fraser WD. Hyperparathyroidism. *Lancet* 2009;374(9684):145–158
  - 55 Ruda JM, Hollenbeak CS, Stack BC Jr. A systematic review of the diagnosis and treatment of primary hyperparathyroidism from 1995 to 2003. *Otolaryngol Head Neck Surg* 2005;132(03):359–372
  - 56 Yeh MW, Ituarte PH, Zhou HC, et al. Incidence and prevalence of primary hyperparathyroidism in a racially mixed population. *J Clin Endocrinol Metab* 2013;98(03):1122–1129
  - 57 Bilezikian JP, Bandeira L, Khan A, Cusano NE. Hyperparathyroidism. *Lancet* 2018;391(10116):168–178
  - 58 Machado NN, Wilhelm SM. Diagnosis and evaluation of primary hyperparathyroidism. *Surg Clin North Am* 2019;99(04):649–666
  - 59 Palmér M, Adami HO, Bergström R, Jakobsson S, Akerström G, Ljunghall S. Survival and renal function in untreated hypercalcaemia. Population-based cohort study with 14 years of follow-up. *Lancet* 1987;1(8524):59–62
  - 60 Palmér M, Adami HO, Bergström R, Akerström G, Ljunghall S. Mortality after surgery for primary hyperparathyroidism: a follow-up of 441 patients operated on from 1956 to 1979. *Surgery* 1987;102(01):1–7
  - 61 Hedbäck G, Tisell LE, Bengtsson BÅ, Hedman I, Oden A. Premature death in patients operated on for primary hyperparathyroidism. *World J Surg* 1990;14(06):829–835, discussion 836
  - 62 Leifsson BG, Ahrén B. Serum calcium and survival in a large health screening program. *J Clin Endocrinol Metab* 1996;81(06):2149–2153
  - 63 Hedbäck G, Odén A. Increased risk of death from primary hyperparathyroidism—an update. *Eur J Clin Invest* 1998;28(04):271–276
  - 64 Yu N, Donnan PT, Flynn RW, et al; The Parathyroid Epidemiology and Audit Research Study (PEARS) Increased mortality and morbidity in mild primary hyperparathyroid patients. *Clin Endocrinol (Oxf)* 2010;73(01):30–34
  - 65 Zanooco K, Angelos P, Sturgeon C. Cost-effectiveness analysis of parathyroidectomy for asymptomatic primary hyperparathyroidism. *Surgery* 2006;140(06):874–881, discussion 881–882
  - 66 Zanooco KA, Wu JX, Yeh MW. Parathyroidectomy for asymptomatic primary hyperparathyroidism: a revised cost-effectiveness analysis incorporating fracture risk reduction. *Surgery* 2017;161(01):16–24
  - 67 Bunch PM, Randolph GW, Brooks JA, George V, Cannon J, Kelly HR. Parathyroid 4D CT: what the surgeon wants to know. *Radiographics* 2020;40(05):1383–1394
  - 68 Rodgers SE, Hunter CJ, Hamberg LM, et al. Improved preoperative planning for directed parathyroidectomy with 4-dimensional computed tomography. *Surgery* 2006;140(06):932–940, discussion 940–941
  - 69 Suh YJ, Choi JY, Kim SJ, et al. Comparison of 4D CT, ultrasonography, and 99mTc sestamibi SPECT/CT in localizing single-gland primary hyperparathyroidism. *Otolaryngol Head Neck Surg* 2015;152(03):438–443
  - 70 Kelly HR, Hamberg LM, Hunter CJ. 4D-CT for preoperative localization of abnormal parathyroid glands in patients with hyperparathyroidism: accuracy and ability to stratify patients by unilateral versus bilateral disease in surgery-naïve and re-exploration patients. *AJNR Am J Neuroradiol* 2014;35(01):176–181
  - 71 Tian Y, Tanny ST, Einsiedel P, et al. Four-dimensional computed tomography: clinical impact for patients with primary hyperparathyroidism. *Ann Surg Oncol* 2018;25(01):117–121
  - 72 Yeh R, Tay YD, Tabacco G, et al. Diagnostic performance of 4D CT and Sestamibi SPECT/CT in localizing parathyroid adenomas in primary hyperparathyroidism. *Radiology* 2019;291(02):469–476
  - 73 Bahl M, Sepahdari AR, Sosa JA, Hoang JK. Parathyroid adenomas and hyperplasia on four-dimensional CT scans: three patterns of enhancement relative to the thyroid gland justify a three-phase protocol. *Radiology* 2015;277(02):454–462
  - 74 Sho S, Yilma M, Yeh MW, et al. Prospective validation of two 4D-CT-based scoring systems for prediction of multigland disease in primary hyperparathyroidism. *AJNR Am J Neuroradiol* 2016;37(12):2323–2327
  - 75 Raghavan P, Durst CR, Ornan DA, et al. Dynamic CT for parathyroid disease: are multiple phases necessary? *AJNR Am J Neuroradiol* 2014;35(10):1959–1964
  - 76 Griffith B, Chaudhary H, Mahmood G, et al. Accuracy of 2-phase parathyroid CT for the preoperative localization of parathyroid adenomas in primary hyperparathyroidism. *AJNR Am J Neuroradiol* 2015;36(12):2373–2379
  - 77 Jason DS, Balentine CJ. Intraoperative decision making in parathyroid surgery. *Surg Clin North Am* 2019;99(04):681–691
  - 78 Wilhelm SM, Wang TS, Ruan DT, et al. The American Association of Endocrine Surgeons guidelines for definitive management of primary hyperparathyroidism. *JAMA Surg* 2016;151(10):959–968
  - 79 Minisola S, Cipriani C, Diacinti D, et al. Imaging of the parathyroid glands in primary hyperparathyroidism. *Eur J Endocrinol* 2016;174(01):D1–D8
  - 80 Parangi S, Pandian TK, Thompson G. Minimally invasive single gland parathyroid exploration. *Surgery of the thyroid and parathyroid glands*. Amsterdam, the Netherlands: Elsevier; 2021:529–536
  - 81 Stack BC Jr, Tolley NS, Bartel TB, et al. AHNS Series: do you know your guidelines? Optimizing outcomes in reoperative parathyroid surgery: definitive multidisciplinary joint consensus guidelines of the American Head and Neck Society and the British Association of Endocrine and Thyroid Surgeons. *Head Neck* 2018;40(08):1617–1629
  - 82 Schneider AB, Lubin J, Ron E, et al. Salivary gland tumors after childhood radiation treatment for benign conditions of the head and neck: dose-response relationships. *Radiat Res* 1998;149(06):625–630
  - 83 Guzzo M, Locati LD, Prott FJ, Gatta G, McGurk M, Licitra L. Major and minor salivary gland tumors. *Crit Rev Oncol Hematol* 2010;74(02):134–148

- 84 Forrest J, Campbell P, Kreiger N, Sloan M. Salivary gland cancer: an exploratory analysis of dietary factors. *Nutr Cancer* 2008;60(04):469–473
- 85 Kessler AT, Bhatt AA. Review of the major and minor salivary glands, part 2: neoplasms and tumor-like lesions. *J Clin Imaging Sci* 2018;8:48
- 86 Freling N, Crippa F, Maroldi R. Staging and follow-up of high-grade malignant salivary gland tumours: the role of traditional versus functional imaging approaches—a review. *Oral Oncol* 2016;60:157–166
- 87 Ferlay J, Ervik M, Lam F, et al. *Global Cancer Observatory: Cancer Today*. Lyon, France: International Agency for Research on Cancer; 2020
- 88 Thoeny HC. Imaging of salivary gland tumours. *Cancer Imaging* 2007;7(01):52–62
- 89 Wierzbicka M, Kopeć T, Szyfter W, Kereiakes T, Bem G. The presence of facial nerve weakness on diagnosis of a parotid gland malignant process. *Eur Arch Otorhinolaryngol* 2012;269(04):1177–1182
- 90 Mantravadi AV, Moore MG, Rassekh CH. AHNS series: do you know your guidelines? Diagnosis and management of salivary gland tumors. *Head Neck* 2019;41(02):269–280
- 91 Pfister DG, Spencer S, Adelstein D, et al. Head and Neck Cancers, Version 2.2020, NCCN Clinical Practice Guidelines in Oncology. *J Natl Compr Canc Netw* 2020;18(07):873–898
- 92 Zheng N, Li R, Liu W, Shao S, Jiang S. The diagnostic value of combining conventional, diffusion-weighted imaging and dynamic contrast-enhanced MRI for salivary gland tumors. *Br J Radiol* 2018;91(1089):20170707
- 93 Ma G, Zhu LN, Su GY, et al. Histogram analysis of apparent diffusion coefficient maps for differentiating malignant from benign parotid gland tumors. *Eur Arch Otorhinolaryngol* 2018;275(08):2151–2157
- 94 Geiger JL, Ismaila N, Beadle B, et al. Management of salivary gland malignancy: ASCO guideline. *J Clin Oncol* 2021;39(17):1909–1941
- 95 Cermik TF, Mavi A, Acikgoz G, Houseni M, Dadparvar S, Alavi A. FDG PET in detecting primary and recurrent malignant salivary gland tumors. *Clin Nucl Med* 2007;32(04):286–291
- 96 WERING B. Neoplasms of the salivary glands. *Atlas of head and neck pathology*. 2008:582–91.
- 97 Lee YY, Wong KT, King AD, Ahuja AT. Imaging of salivary gland tumours. *Eur J Radiol* 2008;66(03):419–436
- 98 Terhaard CH, Lubsen H, Van der Tweel I, et al; Dutch Head and Neck Oncology Cooperative Group. Salivary gland carcinoma: independent prognostic factors for locoregional control, distant metastases, and overall survival: results of the Dutch head and neck oncology cooperative group. *Head Neck* 2004;26(08):681–692, discussion 692–693
- 99 Christe A, Waldherr C, Hallett R, Zbaeren P, Thoeny H. MR imaging of parotid tumors: typical lesion characteristics in MR imaging improve discrimination between benign and malignant disease. *AJNR Am J Neuroradiol* 2011;32(07):1202–1207
- 100 Habermann CR, Arndt C, Graessner J, et al. Diffusion-weighted echo-planar MR imaging of primary parotid gland tumors: is a prediction of different histologic subtypes possible? *AJNR Am J Neuroradiol* 2009;30(03):591–596
- 101 Yabuuchi H, Fukuya T, Tajima T, Hachitanda Y, Tomita K, Koga M. Salivary gland tumors: diagnostic value of gadolinium-enhanced dynamic MR imaging with histopathologic correlation. *Radiology* 2003;226(02):345–354
- 102 Kim JY, Lee SW, Kim JS, et al. Diagnostic value of neck node status using 18F-FDG PET for salivary duct carcinoma of the major salivary glands. *J Nucl Med* 2012;53(06):881–886
- 103 Digonnet A, Hamoir M, Andry G, et al. Follow-up strategies in head and neck cancer other than upper aerodigestive tract squamous cell carcinoma. *Eur Arch Otorhinolaryngol* 2013;270(07):1981–1989
- 104 Manikantan K, Khode S, Dwivedi RC, et al. Making sense of post-treatment surveillance in head and neck cancer: when and what of follow-up. *Cancer Treat Rev* 2009;35(08):744–753
- 105 Hermans R. Posttreatment imaging in head and neck cancer. *Eur J Radiol* 2008;66(03):501–511
- 106 Razfar A, Heron DE, Branstetter BF IV, Seethala RR, Ferris RL. Positron emission tomography-computed tomography adds to the management of salivary gland malignancies. *Laryngoscope* 2010;120(04):734–738