




# Imaging Recommendations for Diagnosis, Staging, and Management of Soft Tissue Sarcomas

Kenneth Lupton<sup>1</sup> Manjusha Salins<sup>2</sup> Bill Pass<sup>3</sup>  Raj Negi<sup>4</sup> Harun Gupta<sup>1</sup>

<sup>1</sup> Leeds Teaching Hospitals, Leeds, United Kingdom

<sup>2</sup> Department of Radiology, Leeds Teaching Hospitals, Leeds, United Kingdom

<sup>3</sup> Department of Musculoskeletal Radiology, Leeds Teaching Hospitals, Leeds, United Kingdom

<sup>4</sup> Department of Radiology and Imaging, University Hospital Lewisham, London, United Kingdom

**Address for correspondence** Harun Gupta, MBBS, MD, DNB, MRCP, FRCR, Leeds Teaching Hospitals, Leeds, LS1 3EX, United Kingdom (e-mail: harun.gupta@nhs.net).

Ind J Med Paediatr Oncol 2023;44:261–267.

## Abstract

### Keywords

- ▶ human gammaherpesvirus 8
- ▶ human immunodeficiency virus
- ▶ MFS
- ▶ soft tissue sarcoma

Soft tissue lesions are a wide range of tumors of mesenchymal cell origin, occurring anywhere in the body with a vast number of histological subtypes both benign and malignant. These are common in clinical practice and vast majority are benign. This article focuses on soft tissue sarcoma of the trunk and extremities and discusses their imaging guidelines.

## Introduction

Soft tissue sarcoma (STS) refers to a wide range of tumors of mesenchymal cell origin, occurring anywhere in the body with a vast number of histological subtypes both benign and malignant.<sup>1</sup> ▶ **Table 1** summarizes the main subtypes sarcoma that are comprehensively described by Bansal et al.<sup>2</sup> The study of STS is a constantly evolving field and regularly updated guidelines exist to summate the most up to date evidence providing a framework against which STS can be managed. This article will focus on imaging STS of the trunk and extremities and will not specifically address retroperitoneal sarcoma, aggressive fibromatosis, or neurofibromatosis.

## Risk Factors and Etiopathogenesis

As with most malignancies, there is no single causative factor for STS. Instead, the etiology is multifactorial with both genetic

and environmental factors known to increase the risk of disease. These factors include viral infections (human gamma-herpesvirus 8 and human immunodeficiency virus), previous radiation therapy, chronic lymphoedema, and environmental carcinogens. Several genetic conditions including but not limited to Li-Fraumeni syndrome, neurofibromatosis-1, and Gardner syndrome are also known to increase the risk.<sup>3–5</sup>

## Epidemiology and Clinical Presentation

The disease is rare making up approximately 1% of adult and 15% of childhood malignancies and in 75% of cases occurs in the extremities.<sup>3,4</sup> The clinical presentation is variable but is typically of a growing soft tissue lump that in some cases may have been present for many years. Constitutional symptoms (weight loss, fever, etc.) are rare but can occur and the disease will often present late.<sup>6</sup>

DOI <https://doi.org/10.1055/s-0042-1760404>.  
ISSN 0971-5851.

© 2023. The Author(s).

This is an open access article published by Thieme under the terms of the Creative Commons Attribution License, permitting unrestricted use, distribution, and reproduction so long as the original work is properly cited. (<https://creativecommons.org/licenses/by/4.0/>)

Thieme Medical and Scientific Publishers Pvt. Ltd., A-12, 2nd Floor, Sector 2, Noida-201301 UP, India

**Table 1** Selected sarcoma subtypes excluding peripheral nerve sheath tumors, gastrointestinal stromal tumors, and chondro-osseous tumors. Adapted from article by Bansal et al<sup>2</sup>

Sarcoma subtype	Benign	Malignant
Adipocytic	Lipoma Lipoma variant	Liposarcoma
Fibroblastic and myofibroblastic	Nodular fasciitis Elastofibroma	Solitary fibrous tumor Myxofibrosarcoma Fibrosarcoma
Fibrohistiocytic tumors	Tenosynovial giant cell tumor	Malignant tenosynovial giant cell tumor
Vascular	Hemangioma Epithelioid hemangioma	Angiosarcoma Epithelioid hemangioendothelioma
Pericytic	Glomus tumor Angioleiomyoma	Malignant glomus tumor
Smooth muscle	Leiomyoma	Leiomyosarcoma
Skeletal muscle	Rhabdomyoma	Rhabdomyosarcoma
Tumors of uncertain differentiation	Myxoma Angiomyolipoma	Synovial sarcoma Alveolar soft part sarcoma Clear cell sarcoma Undifferentiated pleomorphic Sarcoma Undifferentiated spindle cell sarcoma
Neural	Schwannoma Neurofibroma	Malignant peripheral nerve sheath tumor

## Imaging Referral Guidelines

The referral for investigation of STS is of paramount importance to ensure that the correct diagnosis can be obtained and appropriate treatment initiated as soon as possible. Patients (both children and adults) should be urgently referred for further investigation in all suspicious soft tissue lumps.<sup>7</sup> The referral pathway utilised at the authors institution is summarized in ► **Fig. 1**.

Imaging plays a central role in the workup of STS in terms of early diagnosis, through assessment of treatment response and monitoring for disease recurrence. The choice of initial investigation will depend on clinical factors including site of concern and examination findings. In general, investigation of the head, neck, mediastinum, and retroperitoneum is best served by computed tomography (CT), while ultrasound is considered the optimum initial investigation for clinically palpable lesions. This is reflected in several guidelines that recommended ultrasound as the initial investigation.<sup>1,2,8</sup> Plain radiographs also have a role in the workup particularly in lesions affecting the extremities. Magnetic resonance imaging (MRI) is considered the gold standard investigation; however, its role as an initial investigation is not supported and instead it is used to further and more accurately characterize lesions.<sup>2,9</sup>

## Clinical/ Diagnostic work-up Excluding Imaging

The variable presentation of sarcoma coupled with its rarity and heterogeneity as a disease entity poses a diagnostic challenge for the clinician at the time of patient presentation. While almost all cases will require imaging to further investi-

gate, it is important to remember that the vast majority will be benign.<sup>1,10,11</sup> A detailed clinical history and thorough clinical examination should therefore be performed to triage those cases in which there is a higher suspicion of malignancy. This will enable appropriate onward referral.<sup>7</sup> The clinical history should detail the site, pain symptoms, duration of lump, and any history of malignancy or previous surgery. Further information on the rate of growth and any associated symptoms should also be elucidated. Examination should confirm the size, depth, consistency, mobility, skin alterations, and presence of lesions elsewhere as well as confirm the presence or absence of tenderness. Clinical findings that raise the concern of malignancy include but are not limited to a size of more than 5cm, pain/tenderness, and lesion growth.<sup>10,11</sup>

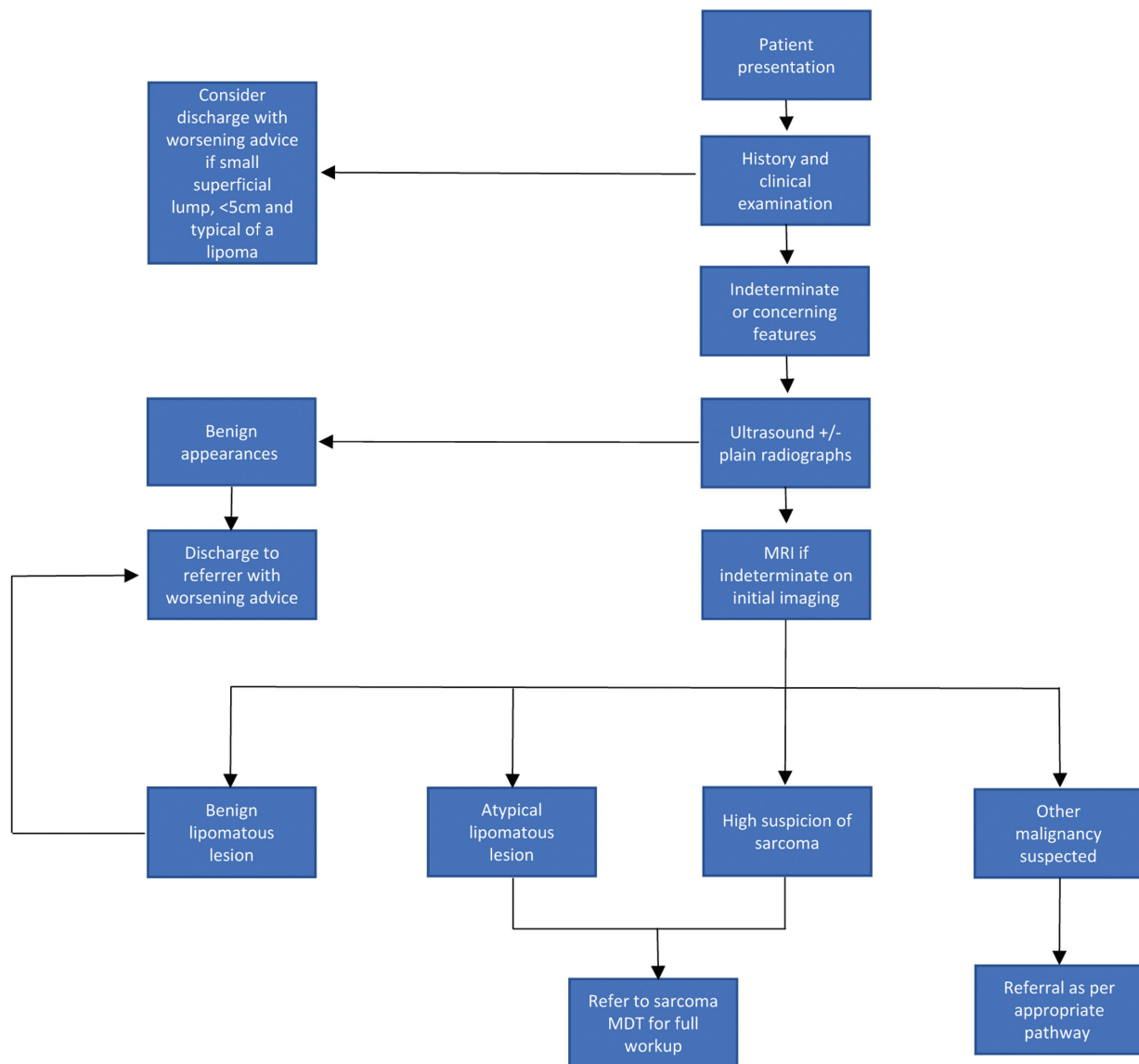
## Imaging Guidelines

### Screening

There is no specific screening program for STS. While in some conditions known to increase the risk—such as Li-Fraumeni syndrome—there may be specific individualized guidance in relation to the detection of malignancy; the broad aim is to encourage early presentation at the development of concerning symptoms.<sup>4,12</sup>

### Diagnosis

As already discussed, imaging is a fundamental component of patient workup for STS and essentially all patients will undergo some form of radiological investigation. The full range of modalities can be utilized, ranging from traditional plain film radiography to newer and less well-established techniques such as positron emission tomography/



**Fig. 1** A simplified referral pathway utilized by the authors institution in combination with relevant recommendations in the literature.

magnetic resonance imaging (PET/MRI). Imaging can be considered in terms of the advantages and disadvantages of the specific modality in question, the clinical presentation, and also the histological subtype of sarcoma that will determine the disease course.<sup>2,9,13</sup> Detailed below is a summary of the commonly used modalities and their role in the investigation of STS.

Plain radiographs are a cheap and widely available test that can be of use in the initial workup of a soft tissue lump—indeed the American College of Radiologists recommend them as part of the initial evaluation of a superficial lesion.<sup>9</sup> They are, however, limited by poor soft tissue contrast. For this reason, use is limited to the assessment of any relevant bony or mineralization changes at the site of concern (e.g., periosteal reaction, bony destruction). In certain situations, they may provide a diagnosis or significantly narrow the differential such as a lump corresponding to normal bony

anatomy or reveal the presence of phleboliths indicating a hemangiomatous lesion.<sup>14,15</sup>

Ultrasound has been shown to be an effective investigation for the initial evaluation of a soft tissue lump.<sup>16,17</sup> In contrast to plain radiographs, ultrasound provides good soft tissue resolution and is a useful triage test to differentiate benign pathology such as simple lipomas, ganglion cysts, muscle hernias, and uncomplicated vascular malformations from more sinister lesions.<sup>11,17</sup> The easy access of ultrasound to most primary care physicians has the advantage of providing patients reassurance and reducing the referral burden on local tertiary referral centers.<sup>10</sup> It is, however, limited by several factors, including but not limited to operator experience and patient body habitus. Location is also an important factor to consider as deeper lesions tend not to be easily amenable to assessment, particularly when a large geographical body area is required to be assessed.

**Table 2** MRI findings associated with specific sarcoma subtypes. Adapted from article by Scalas et al<sup>13,20,21,24</sup>

Sign	Sarcoma subtype	Significance
Tail sign	Undifferentiated pleomorphic sarcoma, myxofibrosarcoma	Higher risk of local recurrence and distant metastases at diagnosis
Water like appearance	Myxofibrosarcoma	Increased likelihood of local recurrence with increasing percentage of water like signal within lesion
Triple sign	Synovial sarcoma	Reduced disease-free survival
Absence of calcifications	Synovial sarcoma	Reduced disease-free survival
Signal heterogeneity	Myxoid liposarcoma	High-grade lesions and poorer prognosis

Similarly, bony lesions/bony involvement is not easily assessed.<sup>17,18</sup>

MRI provides high spatial resolution, optimum soft tissue contrast, and allows accurate assessment of not just lesion size and morphology but also the relationship of the lesion to other structures (including local neurovasculature anatomy) enabling accurate local staging.<sup>9,13</sup> Studies have assessed the utility of MRI in predicting the eventual grade of lesion and clinical outcome.<sup>19–23</sup> Crombé et al found that MRI features of tumor necrosis, heterogeneity, and peritumoral enhancement were associated with higher grade lesions. They also found that two or more of these features in combination were associated with a worse metastasis-free survival (MFS) as well as overall survival (OS). Interestingly, when the same principle of the presence of two or more of these features was applied to lower grade lesions (1 and 2), the MFS and OS were the same as for grade 3 lesions with the authors surmising that these MRI features could be used to predict prognosis on the baseline scan.<sup>19</sup> Other features that have been found to correlate with poor outcomes include lesion heterogeneity and size more than 10cm (in all STS subtypes) as well as features specific to individual sarcoma subtypes of which there are several. Scalas et al comprehensively describe several of these features which include the tail sign adjacent to the lesion in undifferentiated pleomorphic sarcoma and myxofibrosarcoma and the so-called triple sign in synovial sarcoma. This reflects the presence of low, intermediate, and high signal within the lesion. These features and others are summarized in ► **Table 2** along with their significance.<sup>13,20,21,24</sup>

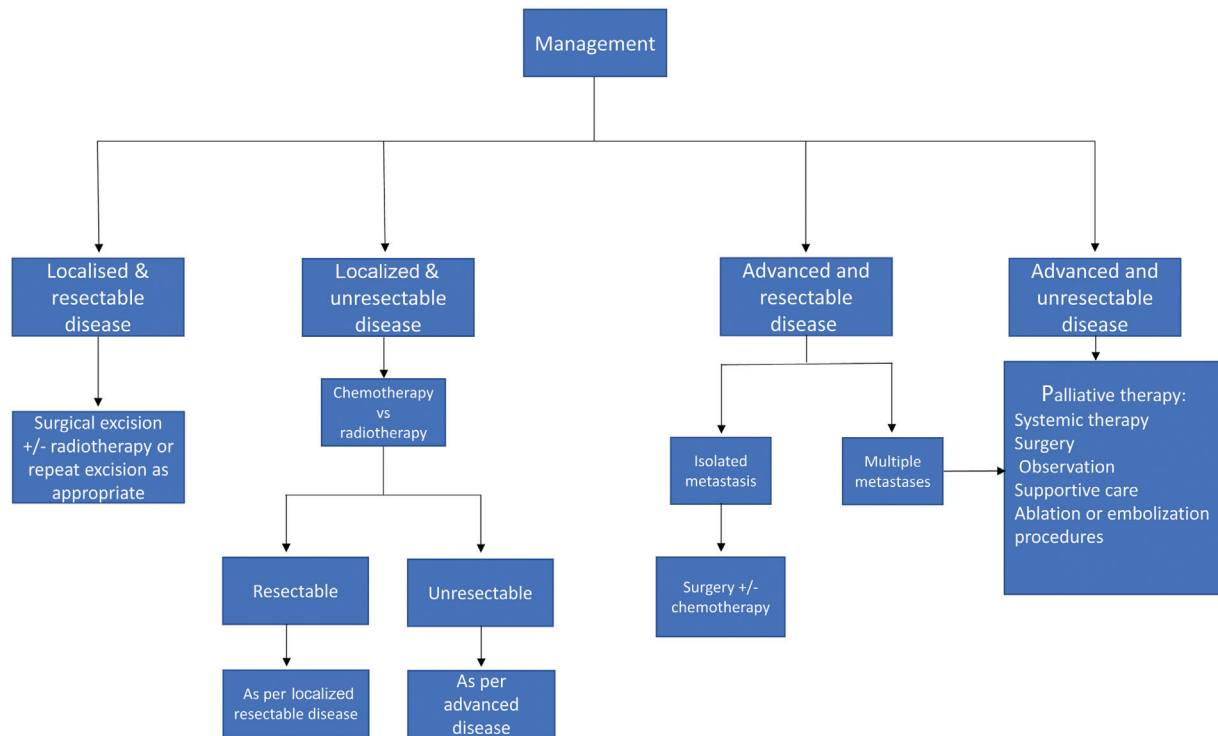
CT can be useful in patients unable to undergo MRI assessment (e.g., incompatible pacemakers and severe claustrophobia) or in cases where plain radiographs are unlikely to provide sufficient information on bony anatomy, bony involvement, or matrix mineralization.<sup>9,14</sup> Indeed, a historic study by Panicek et al acknowledged the superior soft tissue contrast of MRI over CT; however, it did not show an advantage of MRI over CT for local staging translating into improved clinical outcomes.<sup>25</sup> It is worth considering that this study was performed over two decades ago and it is at least theoretically possible that with improved imaging techniques, the results could be different were a similar more up to date study performed. It is, therefore, the author's view that every effort should be made to perform an MRI where possible.

FDG-PET-CT is a well-established investigation for the workup of many malignancies. However, its role in the assessment of STS is less so. Several studies have assessed its utility in the workup of STS specifically in terms of the ability to predict tumor behavior and prognosis.<sup>26–30</sup> Generally, higher maximum standardized uptake value values have tended to correlate with higher grade disease/malignant disease.<sup>26–28</sup> Caution is, however, advised as there are several limitations, including the low uptake of fluorodeoxyglucose (FDG) in certain tumor subtypes including myxoid liposarcoma and synovial sarcoma that inherently limit the application of PET in these specific subtypes.<sup>26</sup> Conversely, there is also a considerable issue of false positives that may arise as the result of inflammatory pathology and benign soft tissue lesions that are FDG avid.<sup>27,28</sup> Irrespective of these limitations, FDG-PET-CT has been shown to lead to a change in management in a not insignificant number of patients as demonstrated by Lee et al, although this was not necessarily in direct relation to the known diagnosis of STS.<sup>29</sup>

Percutaneous biopsy is the standard/preferred method by which to obtain a definitive diagnosis. Although this is now a well-established technique, there are pitfalls that the clinician must be aware of including the potential for under grading the lesion. It is recognized that lesions may harbor areas of higher-grade tumor or dedifferentiation that the biopsy can miss.<sup>24</sup> For obvious reasons this may have significant treatment repercussions and may only come to light on subsequent analysis of a surgically excised lesion at which point the tumor is upgraded. To gain as representative sample as possible, it is, therefore, recommended that the biopsy be undertaken by a clinician experienced in sarcoma imaging, usually a radiologist. In addition, guidelines suggest planning the biopsy in conjunction with the operative surgeon such that the biopsy tract can be excised to reduce the likelihood of tumor seeding. While this is common practice, there seems to be relatively little evidence base for this in the literature.<sup>31</sup> In cases where a percutaneous biopsy is either not possible (e.g., due to anatomical constraints) or has failed, open biopsy can be performed. Small (typically <3cm) lesions can be considered for excisional biopsy.<sup>1,4,8,32</sup>

### Staging

The staging of STS typically follows the American Joint Committee on Cancer (8th edition) guidelines. This provides



**Fig. 2** Summarized flow chart showing the broad principles of management as per the UK, EU and US guidelines.

a tumor, node, and metastasis (TNM) classification, according to lesion size, nodal involvement and distant metastases. The Fédération Nationale des Centres de Lutte Contre Le Cancer (FNCLCC) criteria take into account tumor differentiation, mitotic activity, and extent of necrosis to provide a tumor grade. The TNM score and the tumor grade are used in combination to assign disease stage (I–IV).<sup>33</sup> The approach to staging in terms of imaging will vary somewhat depending on the histology of the tumor. Typical staging consists of CT chest for STS and others include CT abdomen and pelvis for myxoid liposarcoma, and central nervous system imaging is usually performed in cases of alveolar soft part and also clear cell sarcoma as a result of a higher likelihood of metastatic disease to these regions, respectively.<sup>1,8</sup> Whole body MRI is recommended as part of staging for myxoid liposarcomas due to the possibility of bone metastasis.

### Follow-Up

The follow-up of STS is important given the risk of local recurrence (LR) and of distant metastases. While there is no universally agreed regimen, in practice this usually combines clinical examination, imaging to assess the site of primary tumor, and a chest X-ray (CXR) or CT chest to exclude metastatic disease (the lungs being the most common site). It is also important to consider the original grade of tumor as local recurrence is more likely with the higher-grade lesions. It is, therefore, reasonable to follow up such groups more aggressively and this is reflected in various guidelines. Typically, lower grade lesions can be followed up with yearly clinical exam  $\pm$  MRI, while higher grade lesions are followed up more regularly—intervals ranging from 3 to 6 months initially and gradually tapered down if no recurrent

disease is discovered. Particular attention is paid to the first 2 to 3 years, where the risk of recurrence is at its highest with the risk of recurrence after 10 years considered small.<sup>1,4,8</sup> It is worth noting that there is dubiety as to the value of imaging follow-up versus clinical examination. Rothermundt et al demonstrated that most local recurrences were picked up clinically, either by the patient or physician on follow-up.<sup>34</sup> However, more recent studies have shown improved detection of LR with the use of MRI versus clinical examination alone.<sup>35,36</sup> The role of CT over CXR has also been questioned in the detection of pulmonary metastases with a study by Puri et al showing that the use of CT neither conferred a survival advantage nor an improvement in the detection of pulmonary metastatic disease.<sup>37</sup>

### Principles of Management

As emphasized in all major guidelines, the cornerstone of good sarcoma care is management through a dedicated and formalized multidisciplinary team meeting. This enables a team of professionals including but not limited to surgeons, oncologists, radiologists, and specialist nurse practitioners to gain sufficient exposure to this rare disease to be in a position to offer the latest evidence-based care to patients. A detailed discussion on the treatment of STS is beyond the scope of this article, but the standard treatment is surgical excision for localized disease. Supplementary therapies are often given and in particular pre/postoperative radiotherapy. Chemotherapy has a role in certain chemosensitive subtypes but in general its use is limited in STS. The specific therapy offered to patients depends on a vast array of factors including histological subtype, amenability to resection, grade of



tumor, co-morbid status/goals of therapy, lesion size, and anatomical location. The management of recurrent disease depends of whether this is localized or metastatic with palliative care often appropriate in the latter. This may take the form of best supportive care, or in specific scenarios ablation/embolization procedures or metastasectomy as appropriate.<sup>1,4,8</sup> **Fig. 2** summarizes the main points in relation to the management of STS according to the UK, US, and European guidelines for illustrative purposes only.<sup>1,4,8</sup> The reader is advised to refer directly to local guidance according to their area of practice.

## Summary of Recommendations

- STS encompasses a heterogenous group of tumors making investigation and management a challenge.
- All patients with a soft tissue lump more than 5cm, rapidly enlarging, or in any way suspicious of sarcoma should be referred for further investigation.
- Ultrasound and plain radiographs are usual baseline tests often able to identify benign pathology and reassure patients.
- MRI is the gold standard investigation and is best able to characterize the lesion with other investigations such as PET-CT utilized on a problem-solving basis.
- The core theme of good sarcoma care is management through a dedicated multidisciplinary team meeting.

### Conflict of Interest

None declared.

## References

- Dangoor A, Seddon B, Gerrand C, Grimer R, Whelan J, Judson I. UK guidelines for the management of soft tissue sarcomas. *Clin Sarcoma Res* 2016;6(01):20
- Bansal A, Goyal S, Goyal A, Jana M. WHO classification of soft tissue tumours 2020: An update and simplified approach for radiologists. *Eur J Radiol* 2021;143:109937. Doi: 10.1016/j.ejrad.2021.109937
- van Vliet M, Kliffen M, Krestin GP, van Dijke CF. Soft tissue sarcomas at a glance: clinical, histological, and MR imaging features of malignant extremity soft tissue tumors. *Eur Radiol* 2009;19(06):1499–1511
- von Mehren M, Kane JM, Agulnik M, et al. NCCN Clinical Practice Guidelines in Oncology (NCCN guidelines®). Soft Tissue Sarcoma. Version 2.2022 - 17/05/2022. NCCN.org. Accessed 23/05/2022. [https://www.nccn.org/professionals/physician\\_gls/pdf/sarcoma.pdf](https://www.nccn.org/professionals/physician_gls/pdf/sarcoma.pdf)
- PDQ Adult Treatment Editorial Board. PDQ Soft Tissue Sarcoma Treatment. Bethesda MD. National Cancer Institute. Updated 19/01/2022. Accessed December 23, 2022, at: <http://www.cancer.gov/types/soft-tissue-sarcoma/hp/adult-soft-tissue-treatment-pdq>
- Ilaslan H, Schiis J, Nageotte W, Lietman SA, Sundaram M. Clinical presentation and imaging of bone and soft-tissue sarcomas. *Cleve Clin J Med* 2010;77(1, Suppl 1):S2–S7
- NICE has updated NICE Guideline 12, Suspected cancer: recognition and referral. Guidelines in Practice [Internet]. 2020 Oct [cited 2022 Jun 6];23(10):8. Accessed December 23, 2022, at: <https://search.ebscohost.com/login.aspx?direct=true&AuthType=sso&db=edo&AN=146957423&site=eds-live>
- Gronchi A, Miah AB, Dei Tos AP, et al; ESMO Guidelines Committee, EURACAN and GENTURIS. Electronic address: [clinicalguidelines@esmo.org](mailto:clinicalguidelines@esmo.org). Soft tissue and visceral sarcomas: ESMO-EURACAN-GENTURIS Clinical Practice Guidelines for diagnosis, treatment and follow-up\*. *Ann Oncol* 2021;32(11):1348–1365
- Kransdorf MJ, Murphey MD, Wessell DE, et al; Expert Panel on Musculoskeletal Imaging. ACR Appropriateness Criteria® Soft-Tissue Masses. *J Am Coll Radiol* 2018;15(5S):S189–S197
- Bradley M, Robinson P, Gerrand C, Hayes A, et al. Ultrasound screening of soft tissue masses in the trunk and extremity. A British sarcoma group guide for ultrasonographers and primary care British Sarcoma Group. January 2019. Accessed Dec 2022. <https://britishsarcomagroup.org.uk/news/ultrasound-screening-of-soft-tissue-masses-in-the-trunk-and-extremity/>
- Noebauer-Huhmann IM, Weber MA, Lalam RK, et al. Soft tissue tumors in adults: ESSR-approved guidelines for diagnostic imaging. *Semin Musculoskelet Radiol* 2015;19(05):475–482
- American Cancer Society. Soft Tissue Sarcoma Early Detection, Diagnosis, and Staging [Internet]. Revised 06/04/2018. Cited 06/06/2022. Accessed December 23, 2022, at: <https://www.cancer.org/cancer/soft-tissue-sarcoma/detection-diagnosis-staging/detection.html>
- Scalas G, Parmeggiani A, Martella C, et al. Magnetic resonance imaging of soft tissue sarcoma: features related to prognosis. *Eur J Orthop Surg Traumatol* 2021;31(08):1567–1575
- Aga P, Singh R, Parihar A, Parashari U. Imaging spectrum in soft tissue sarcomas. *Indian J Surg Oncol* 2011;2(04):271–279
- Gartner L, Pearce CJ, Saifuddin A. The role of the plain radiograph in the characterisation of soft tissue tumours. *Skeletal Radiol* 2009;38(06):549–558 cited 2022Jun6 [Internet]
- Rowbotham E, Bhuvu S, Gupta H, Robinson P. Assessment of referrals into the soft tissue sarcoma service: evaluation of imaging early in the pathway process. *Sarcoma* 2012;2012:781723
- Lakkaraju A, Sinha R, Garikipati R, Edward S, Robinson P. Ultrasound for initial evaluation and triage of clinically suspicious soft-tissue masses. *Clin Radiol* 2009;64(06):615–621
- Singer AD, Wong P, Umpierrez M, et al. The accuracy of a novel sonographic scanning and reporting protocol to survey for soft tissue sarcoma local recurrence. *Skeletal Radiol* 2020;49(12):2039–2049
- Crombé A, Marcellin PJ, Buy X, et al. Soft-tissue sarcomas: assessment of MRI features correlating with histologic grade and patient outcome. *Radiology* 2019;291(03):710–721
- Spinnato P, Clinca R, Vara G, et al. MRI features as prognostic factors in myxofibrosarcoma: proposal of MRI grading system. *Acad Radiol* 2021;28(11):1524–1529
- Yoo HJ, Hong SH, Kang Y, et al. MR imaging of myxofibrosarcoma and undifferentiated sarcoma with emphasis on tail sign; diagnostic and prognostic value. *Eur Radiol* 2014;24(08):1749–1757
- Sambri A, Spinnato P, Bazzocchi A, Tuzzato GM, Donati D, Bianchi G. Does pre-operative MRI predict the risk of local recurrence in primary myxofibrosarcoma of the extremities? *Asia Pac J Clin Oncol* 2019;15(05):e181–e186
- Tateishi U, Hasegawa T, Beppu Y, Satake M, Moriyama N. Synovial sarcoma of the soft tissues: prognostic significance of imaging features. *J Comput Assist Tomogr* 2004;28(01):140–148
- Gimber LH, Montgomery EA, Morris CD, Krupinski EA, Fayad LM. MRI characteristics associated with high-grade myxoid liposarcoma. *Clin Radiol* 2017;72(07):613.e1–613.e6
- Panicek DM, Gatsonis C, Rosenthal DI, et al. CT and MR imaging in the local staging of primary malignant musculoskeletal neoplasms: report of the Radiology Diagnostic Oncology Group. *Radiology* 1997;202(01):237–246
- Sambri A, Bianchi G, Longhi A, et al. The role of 18F-FDG PET/CT in soft tissue sarcoma. *Nucl Med Commun* 2019;40(06):626–631
- Bischoff M, Bischoff G, Buck A, et al. Integrated FDG-PET-CT: its role in the assessment of bone and soft tissue tumors. *Arch Orthop Trauma Surg* 2010;130(07):819–827
- Shin DS, Shon OJ, Han DS, Choi JH, Chun KA, Cho IH. The clinical efficacy of (18)F-FDG-PET/CT in benign and malignant musculoskeletal tumors. *Ann Nucl Med* 2008;22(07):603–609

- 29 Lee L, Kazmer A, Colman MW, Gitelis S, Batus M, Blank AT. What is the clinical impact of staging and surveillance PET-CT scan findings in patients with bone and soft tissue sarcoma? *J Surg Oncol* 2022;125(05):901–906
- 30 Kassem TW, Abdelaziz O, Emad-Eldin S. Diagnostic value of <sup>18</sup>F-FDG-PET/CT for the follow-up and restaging of soft tissue sarcomas in adults. *Diagn Interv Imaging* 2017;98(10):693–698
- 31 Seeger LL. Revisiting Tract Seeding and Compartmental Anatomy for Percutaneous Image-Guided Musculoskeletal Biopsies. Vol. 48, *Skeletal Radiology*. Springer Verlag; 2019:499–501
- 32 Veltri A, Bargellini I, Giorgi L, Almeida PAMS, Akhan O. CIRSE guidelines on percutaneous needle biopsy (PNB). *Cardiovasc Intervent Radiol* 2017;40(10):1501–1513
- 33 Cates JMM. The AJCC 8th edition staging system for soft tissue sarcoma of the extremities or trunk: a cohort study of the SEER database. *J Natl Compr Canc Netw* 2018;16(02):144–152 cited 2022Jun7 [Internet]
- 34 Rothermundt C, Whelan JS, Dileo P, et al. What is the role of routine follow-up for localised limb soft tissue sarcomas? A retrospective analysis of 174 patients. *Br J Cancer* 2014;110(10):2420–2426
- 35 Hovgaard TB, Nymark T, Skov O, Petersen MM. Follow-up after initial surgical treatment of soft tissue sarcomas in the extremities and trunk wall. *Acta Oncol* 2017;56(07):1004–1012
- 36 Park JW, Yoo HJ, Kim HS, et al. MRI surveillance for local recurrence in extremity soft tissue sarcoma. *Eur J Surg Oncol* 2019;45(02):268–274
- 37 Puri A, Gulia A, Hawaldar R, Ranganathan P, Badwe RA. Does intensity of surveillance affect survival after surgery for sarcomas? Results of a randomized noninferiority trial. *Clin Orthop Relat Res* 2014;472(05):1568–1575