Fetal Pathology of Neural Tube Defects – An Overview of 68 Cases

Fetalpathologie der Neuralrohrdefekte – ein Überblick über 68 NTD-Fälle

Authors
Katharina Schoner[1], Roland Axt-Fliedner[2], Rainer Bald[3], Barbara Fritz[4], Juergen Kohlhase[5], Thomas Kohl[6], Helga Rehder[1,7]

Affiliations
1 Institute of Pathology, WG Fetal Pathology, University of Gießen and Marburg, Philipps University of Marburg, Marburg, Germany
2 Department of Prenatal Medicine, University Hospital of Gießen and Marburg, Gießen, Germany
3 Department of Gynecology and Obstetrics, Klinikum Leverkusen, Leverkusen, Germany
4 Center of Human Genetics, University of Gießen and Marburg, Philipps University of Marburg, Marburg, Germany
5 Praxis for Human Genetics – Center of Preimplantation Genetic Diagnosis, Freiburg, Germany
6 German Center for Fetal Surgery & minimal-invasive Therapy, University Hospital of Gießen and Marburg, Gießen, Germany
7 Institute of Medical Genetics, Medical University Vienna, Vienna, Austria

Key words
neural tube defects, spina bifida, encephalocele, Chiari II malformation, fetal pathology

Schlüsselwörter
Neuralrohrdefekte, Spina bifida, Enzephalozele, Chiari-II-Malformation, Fetalpathologie

received 3.12.2016
revised 7.2.2017
accepted 10.2.2017

Bibliography
DOI https://doi.org/10.1055/s-0043-103459
Geburtsh Frauenheilk 2017; 77: 495–507 © Georg Thieme Verlag KG Stuttgart · New York | ISSN 0016-5751

Correspondence
Dr. med. Katharina Schoner
Institute of Pathology, WG Fetal Pathology,
Philipps University of Marburg
Baldingerstraße, 35043 Marburg, Germany
schoner@med.uni-marburg.de

Deutsche Version unter:
https:/doi.org/10.1055/s-0043-103459
Supporting Information:
https://doi.org/10.1055/s-0043-103459

ABSTRACT

Introduction The prevalence of neural tube defects worldwide is 1–2 per 1000 neonates. Neural tube defects result from a disturbance of neurulation in the 3rd or 4th week of development and thus represent the earliest manifestation of organ malformation. Neural tube defects (NTD) are classified into cranial dysraphism leading to anencephaly or meningoencephalocele and spinal dysraphism with or without meningomyelocele. In isolated form they have multifactorial causes, and the empirical risk of recurrence in Central Europe is 2%. As associated malformations they tend to occur sporadically, and in monogenic syndromes they follow Mendelian inheritance patterns with a high risk of recurrence.

Patients Autopsies were performed on 68 fetuses following a prenatal diagnosis of NTD and induced abortion.

Results The incidence of NTDs in our autopsied fetuses was 8% and 11% in fetuses with malformations. The percentage of fetuses with anencephaly, encephalocele or spina bifida was 24, 18, and 60%*, respectively. Analysis of the sex distribution showed a female preponderance in cranial dysraphisms but the sex distribution of spina bifida cases was equal. The extent and localization of NTDs varied, with lumbosacral cases clearly predominating. The proportion of isolated, associated and syndromic neural tube defects was 56, 23.5 and 20.6% respectively. In the majority of syndromes, the neural tube defect represented a not previously observed syndromic feature.

Conclusion The high proportion of NTDs with monogenic background underlines the importance of a syndrome oriented fetal pathology. At the very least it requires a thourough photographic and radiographic documentation of the fetal phenotype to enable the genetic counsellor to identify a syndromic disorder. This is necessary to determine the risk of recurrence, arrange confirming mutation analyses and offer targeted prenatal diagnosis in subsequent pregnancies.

ZUSAMMENFASSUNG

Einleitung Neuralrohrdefekte zeigen weltweit eine Prävalenz von 1–2 : 1000 unter Neugeborenen. Sie beruhen auf einer gestörten Neurulation in der 3.–4. Entwicklungswoche und stellen damit die früheste Manifestation einer Organfehlbildung

dar. Neuralrohrdefekte lassen sich in kraniale Dysraphien mit Anenzephalie oder Meningoenzephalozele und spinale Dysraphien mit oder ohne Meningomyelozele einteilen. In isolierter Form sind sie multifaktoriell bedingt und in Mitteleuropa mit einem empirischen Wiederholungsrisiko von 2% behaftet. Als assoziierte Fehlbildung treten sie zumeist sporadisch auf und in monogenen Syndromen folgen sie einem Mendel-Erbgang mit hohem Wiederholungsrisiko.

Patienten Die Untersuchungen erfolgten an 68 Feten, die uns nach Pränataldiagnose eines Neuralrohrdefekts und Schwangerschaftsabbruch zur Obduktion überstellt worden waren.

Ergebnisse Die Rate von Neuralrohrdefekten in unserem fetalpathologischen Obduktionsgut betrug 8%, bezogen auf die Feten mit Fehlbildungen 11%. Der Anteil der Anenzephalien, Enzephalozelen und Spinae bifidae lag bei 24:18:60%*. Das Geschlechtsverhältnis ergab eine deutliche Bevorzugung des weiblichen Geschlechts bei den kranialen Dysraphien und war ausgeglichen unter den Spina-bifida-Fällen. Die Neuralrohrdefekte variierten in Ausdehnung und Lokalisation. In der großen Mehrzahl der Fälle waren sie lumbosakral gelegen. Isolierte, assoziierte und syndromale Neuralrohrdefekte traten mit einer Häufigkeit von 56:23,5:20,6% auf. Bei der Mehrzahl der Syndrome stellte der Neuralrohrdefekt ein bisher nicht beobachtetes Merkmal dar.

Schlussfolgerungen Eine syndromorientierte fetalpathologische Untersuchung oder zumindest eine fotografische und röntgenologische Dokumentation des fetalen Phänotyps zur Syndromerkennung durch den genetischen Berater sind die Voraussetzungen für die Bestimmung des Wiederholungsrisikos und eine gezielte pränatale Diagnostik bei nachfolgenden Schwangerschaften.

Introduction

Neural tube defects (NTD) are failures of parts of the neural tube to close. They originate during the 3rd and 4th week of development. As dorsal dysraphisms they represent the earliest organ malformation in humans [1–3]. Neural tube closure starts in the mid-section and continues outward in cranial and caudal directions with midline fusion of the neural fold, and ends with closure of the rostral and caudal neuropore on the 25th and 27th developmental day. While open NTDs result from failure of neural tube closure during neurulation, skin-covered NTDs are considered "post-neurulation defects" resulting from non-separation of the neural tube from the overlying ectoderm after the 4th week of development [2,4]. The type and localization of an NTD will therefore indicate its determination period. The caudal third develops into the spinal cord, while the rostral two thirds develop into the brain. Depending on the localization, extent and resulting complications, NTDs can be lethal perinatally or may be associated with functional defects post partum such as incontinence, paresis and sensory deficits below the level of the lesion [3].

NTDs develop from primary genetic, secondary teratogenic or multifactorial disorders of organogenesis [4–6]. They present as exencephaly or anencephaly (AC), iniencephaly, meningoencephalocele (MEC) or spina bifida (SB) with or without meningomyelocele (MMC) in association with cranioschisis, rachischisis or combined craniorachischisis. Because of the exposed position of the defect NTDs are often detected early on prenatal ultrasound [7, 8]. Maternal folic acid supply pre- and post-conception has been found to be effective in primary prevention [9]. Fetal surgery to close spina bifida aperta (SBA) and prevent complications has also been carried out successfully. Infants operated in utero show improved motor and sensory functions in the lower limbs and a lower incidence of type II Chiari malformations (CM-II); surgery reduces the necessity of ventriculo-peritoneal shunt to treat hydrocephalus by half and improves psychomotor development compared to infants with SBA who were operated postnatally [10–12].

Chiari malformation is the most significant condition associated with spina bifida. It occurs as one of four types and refers to a downward displacement and herniation of parts of the cerebellum, the brain stem and the medulla oblongata through an extended occipital foramen magnum into the spinal canal [13]. It may be followed by obstruction of cerebrospinal fluid outflow and thus causes non-communicating hydrocephalus [3]. In contrast to CM-I, CM-III and IV, CM-II is associated with caudal spina bifida and is present in around 75% of lumbosacral NTDs, of which 85.4% have associated hydrocephalus [8]. The increased cerebral pressure with compression of the cerebellum, brainstem and cervical spinal cord can result in nerve palsy, dyspnea and dysphagia [14]. In fetuses, the so-called "lemon and/or banana sign" is a sonographic indication of CM-II. The pathogenesis of CM-II is still not clear [13]. One of the oldest theories is the traction theory. It postulates that normal ascension of the caudal spinal cord is prevented by fixation at the level of the lumbosacral spina bifida. Another theory proposes that hydrocephalus is the primary event and that herniation and even spina bifida are secondary to pressure-related rupture of the neural tube. A third theory has focused on the hindrances to normal distension of the embryonic ventricular system because of the early loss of cerebrospinal fluid following failure of neural tube closure. This limits normal basicranial growth, leading to hypoplasia of the posterior fossa, and herniation in fetuses with normal brain growth. The lack of space prevents expansion of the medulla oblongata and pons and is responsible for its elongation and the characteristic Z-shaped kink. But none of the theories can provide a comprehensive explanation of the complex relationships at the cranio-cervical junction [15, 16].

In the 1970s, the prevalence of NTDs in Europe was still ~ 2 per 1000 births [17]. Following improvements in prenatal diagnosis, the prevalence of NTDs at birth dropped to < 1‰ [18, 19]. However, the prevalence of NTDs varies across different geographical regions and populations, as has been demonstrated impressively by a ninefold difference found in the frequency of NTDs between 8‰ in Ireland and 0.9‰ in Japan [3, 18, 20, 21]. Nasofrontal encephaloceles are rare in Europe with a prevalence at birth of 1:40–50000 but are 10 times more common in Southeast Asia. In the

population of North Thailand the reported incidence even reaches 1/3500 [22]. A higher rate of NTDs is expected in the early stages of pregnancy [17, 23]. A Japanese study found a 4 times higher incidence of NTD (3.4–6.7‰) in first-trimester embryos who were aborted for socio-medical reasons [24]. NTDs were found in 3.6–8.8% of cases of early spontaneous miscarriage. The majority of them had chromosomal anomalies [18, 25, 26].

We report here on 68 fetal neural tube defects out of a total of 815 autopsied fetuses. The main focus is put on phenotypical distribution patterns, the syndromic classification and the consequences for recurrence risks and prenatal diagnosability.

Material and Method

Fetopathological studies were carried out in 68 fetuses diagnosed with neural tube defects on prenatal ultrasound. The catchment area for the fetuses included prenatal centers in the "old" federal states of Germany; however, after 2010 most of the fetuses were obtained from the department of prenatal medicine of the University Hospital of Gießen and Marburg (UKGM).

Fetopathological examination included body measurement, careful inspection of the external appearance, in particular of the facial aspect, opening of the body cavity with removal of the organs, magnifier-assisted macroscopic preparation of the organs (LUXO WAVE PLUS magnifier lamp 3.5 dpt, Glamox Luxo Lighting GmbH, Hildesheim, Germany), microscopic examination and separate neuropathological examination of the central nervous system. The separate stages of the examination were documented photographically using a repro stand with a motorized height-adjustable camera mount (Kaiser Fototechnik GmbH & Co. KG, Buchen, Germany). All photographs were taken with a digital camera (Canon Power Shot G5). The camera was linked to a PC with a monitor showing an enlarged display to monitor the quality of the images and for further image processing (Adobe Photoshop); data were stored on a central server.

Radiological examinations were carried out using a cabinet X-ray system (Faxitron X-ray LX-60, Rohde & Schwarz GmbH & Co. KG, Cologne, Germany). The fetuses were fixed to the X-ray plates with adhesive tape. The exposure time for images of the entire body (posterior-anterior or anterior-posterior view and from the side) was 3–4.5 s at 20–35 kV depending on the size of the fetus.

Genetic investigations required the parents' informed consent. This was obtained together with their consent to the fetopathological examination. Chromosome analysis was carried out after short and long-term culturing. Analysis was done using chorionic villi or amnion cells prenatally or using umbilical cord or fetal tissue, preferably obtained from the fetal Achilles tendon, post abortion. Umbilical cord, fetal Achilles tendon and muscle tissue was frozen and stored for use in molecular genetic analysis. Genomic DNA was extracted using standard procedures [28]. DNA was sent to a molecular genetic laboratory for mutation analysis. Sequencing of coding exons and adjacent intronic regions of the analyzed genes was done after amplification with PCR (polymerase chain reaction) by Sanger sequencing. If a syndrome was diagnosed clinically based on mutations in different genes, analysis was carried out using an NGS mutation panel [29].

Results

A total of 618 out of 815 cases autopsied for fetopathological examination in Marburg between 2004 and 5/2016 had malformations; 68 of these fetuses had a neural tube defect. In the majority of cases (64/68), the pregnancy was terminated by induced abortion. Fetal ages ranged from the 13th to the 36th week of gestation. Distribution of maternal age for the age groups < 20/21–25/26–30/**31–35**/36–40/41–45 years was 3/14/17/**25**/5/4. The ratio of "isolated" to "associated" to "syndromic" forms was 38 : 16 : 14. The NTD rate in our autopsied fetuses was 8%. It was 11% for the cases with malformations (▶ **Tables 1**, **2** and **3S**).

Anencephalies (AC)

There were 16 cases (23.5%) with anencephaly and cranio(rachi)-schisis among the 68 cases with NTDs, two of which were delivered by cesarean section because of discordant monochorionic diamniotic and dichorionic triamniotic multiple pregnancy. The female to male ratio was f : m = 10 : 6. Findings for the 12 cytogenetically investigated fetuses were unremarkable. The 16 fetuses with anencephaly were grouped into 8 cases with meroacrania, 3 cases with holoacrania and 5 cases with craniorachischisis. On the fetogram the meroacrania presented as partial defects of the parietal and temporal bones and of the frontal bone; holocrania additionally presented with partial defects of the occipital bone and a split foramen magnum (▶ **Figs. 1 a** to **d**). Craniorachischisis was accompanied by defects of adjacent vertebral arches and an open vertebral canal. In 2 cases, the opening extended to L1, in 1 case to L2 and in a further 2 cases to L5 (▶ **Fig. 1 e**). Craniorachischisis was accompanied by kyphoscoliosis or lordosis. Facial dysmorphisms included long nose, macrognathia and a proptosis in cases with defects of the orbital roof (▶ **Fig. 1 c**). Overlength of the limbs was another characteristic feature. Histological examination of the cerebrovascular membrane overlying the skull base showed islands of neural tissue and strongly vascularized arachnoid membranes. Eyes and optic nerves distal to the chiasm were unremarkable. Secondary renal gland hypoplasia can be explained by hypoplasia or necrosis of the pituitary gland.

Classification into clinical entities

There were 10 cases with "isolated" anencephaly. Schisis association was diagnosed in 4 cases with additional omphalocele, diaphragmatic defect, and cleft lip and palate. One of these cases additionally had amniotic rupture sequence. One case had associated pseudo-median cleft lip and palate and cebocephaly-holoprosencephaly, probably of genetic origin. One case corresponded to a TRAP sequence. One isolated case was a recurrence.

Meningoencephalocele (MEC)

Meningoencephalocele was found in 12 of the 68 NTD cases (17.7%) with a female to male ratio of f : m = 8 : 4. Occipital MEC was present in 10 cases. One case presented with isolated nasofrontal MEC next to a defect of the frontal and ethmoid bone, visi-

▶ **Table 1** Syndromic and associated neural tube defects.

Case no.	Gestational week	Sex	Type	Diagnosis	Malformations consequent to NTD	Cause	Syndrome-specific and other concomitant malformations
AC associated monogenic?							
AC 5	14	m	M-AC	midline development defect? HPE syndrome?	∅	**monogenic?**	Cebocephaly, pseudo-median cleft lip and palate (holoprosencephaly complex)
AC association							
AC 6	15 + 4	f	M-AC	schisis association	∅	**sporadic**	Bilateral cleft lip and palate
AC 7	15 + 5	f	M-AC	schisis association/ **amn. rupture seq.**	∅	**sporadic**	Congenital limb defects, omphalocele
AC 8	16 + 2	m	M-AC	schisis association	∅	**sporadic**	Bilateral CDH
AC 15	23	f	CRS frontal – L5	schisis association	∅	**sporadic**	Bilateral cleft lip and palate, rib and vertebral defects, scoliosis of the cervical spine
AC 16	19 + 4	m	CRS frontal – L1	**TRAP sequence** discord. Twins	∅	**sporadic**	Acardia, defects of the liver, spleen, kidneys, pancreas, facial and abdominal cleft, limb defects, kyphoscoliosis
n = 6		**f : m = 3 : 3**		**1 × genetic?** **4 × schisis association** **1/4 amn. rupture seq.** **1× TRAP seq.**		**1 × monogenic?** **5 × sporadic**	
MEC syndrome							
MEC 8	21 + 5	f	high occ. large	**13q syndrome**	micro-cephaly	**chromosomal sporadic** Ring 13	Defects of the 1st finger and toe ray, cardiac and renal malformations et al.
MEC 9	18 + 5	m	**double MEC** high + low occ. covered	**Meckel-Gruber syndrome**	DWC	**AR monogenic** *MKS3* mutation	MEC + polycystic kidneys et al. (MKS without polydactyly)
MEC 10	18 + 4	m	high occ., small	**Peters-plus syndrome**	DWC + H	**AR monogenic** *B3GALTL* mutation Rec.	Peters anomaly of the anterior chamber of the eye, cleft lip and palate, PLSVC
MEC 11 + SB 41	16	f	**Double** high occ. covered + SB occulta L5–S1	**Noonan syndrome**	SB occ.	**AD monogenic** *PTPN11* mutation c.226G>C	Hydrops, cystic hygroma, cardiac defect (HLH) et al.
MEC 12	18	m	low occ. small, covered	**OFD 6**	DWC + H	**AR monogenic** Rec.	Brachymelia, mesoaxial hexadactyly, HLH, incomplete midline lower cleft lip, hypothalamic hamartoma et al.
MEC associated monogenic?							
MEC 5 + SB 42	24 + 5	f	**Double** low occ. + MMC, Th2–5	Dandy-Walker malformation + occ. cephalocele? (# 6092222)	DWC + H + SB thor	**monogenic (AD)?**	Wedge-shaped thoracic vertebrae and thoracic hemivertebrae
MEC 6	21	m	high occ. small, covered	congenital malformation omplex?	DWC + H	**monogenic?** Rec.	Agenesis of corpus callosum
MEC 7	19	f	low occ. small, covered	# 6092222?	DWC + H	**monogenic (AD)?**	Shortened 1st metacarpal bones, cervical ribs

Continued next page

▶ **Table 1** Syndromic and associated neural tube defects. *(Continued)*

Case no.	Gestational week	Sex	Type	Diagnosis	Malformations consequent to NTD	Cause	Syndrome-specific and other concomitant malformations
MEC association							
MEC 3	15 + 5	f	nasopharyngeal	schisis association (pentalogy of Cantrell)	H?	**unknown sporadic?**	Thoracogastroschisis, partial defects of the sternum, diaphragm and pericardium, cardiac defect, ectopy of the lung + abdominal organs, cleft lip and palate, unilateral dysmelia
MEC 4	14 + 5	f	occipito-cervical, large	schisis association	? unclear	Sporadic	Iniencephaly, omphalocele, VSD, CoA
n = 10		**f : m = 6 : 4**		**5 × syndrome** **3 × ass. monogenic?** **2 × schisis association**		**1 × chromosomal** **4 × monogenic** **3 × monogenic?** **2 × sporadic**	
SB syndrome							
SB 32	18	m	**LS**-MMC L2–S2	**trisomy 18 (Ts 18)**	**CM-II** + H?	**chromosomal *47,XY,+18***	Left thumb ray defect, cleft palate, facial dysmorphisms, VSD, 2-Ao valve et al.
SB 33	20 + 4	f	**CTLS-SB** C1–S3	**Ts 18**	**CM-II + H**	**chromosomal *47,XX,+18***	Lumbar gibbus, right-sided CDH, omphalocele, VSD, 2-pulm valve et al.
SB 34	25	m	**LS**-SB L1–S2	**Ts 18**	**CM-II** + H?	**chromosomal *47,XY,+18***	Kyphosis of the lumbar spine, bilateral radial aplasia, right-sided cleft lip and palate, VSD, 2-pulm + 2-Ao valve et al.
SB 35	21 + 4	f	**LS-SB** L2–S2	**Triploidy**	**CM-II HPE**	**chromosomal *69,XXX***	Holoprosencephaly and cebocephaly, syndactyly of 3rd–4th fingers and 2nd–3rd toes, left cystic kidney et al.
SB 36	21	m	**LS-SB** L2–S1	**Bardet-Biedl syndrome (BBS)**	**CM-II, micro-ceph.**, H ∅	**AR monogenic *BBS4* mutation Rec.**	Meckel syndrome: postaxial polydactyly of the right hand and feet (bilateral), medullary cystic kidneys
SB 37	19	f	**LS-MMC** L2–S1 + **CT-SB occulta**	**CMNS**	**CM-II** H ∅	**AR monogenic**	SCDO, thoracic kyphoscoliosis, omphalocele, urogenital malformation et al.
SB 38	21 + 5	m	**L–MMC** L2–L5	**CMNS**	CM-II ∅ H ∅	**AR monogenic**	SCDO, urogenital malformation, bilateral talipes et al.
SB 39	20	m	**LS-MMC** L2–S4	**Fryns syndrome** (FS)	CM-II ∅ H ∅	**AR monogenic gene unknown**	Fryns syndrome-like appearance, hydrops, bilateral CDH, omphalocele, complex cardiac, GI and urogenital malformations
SB 40	20	m	**presacral/ anterior MMC** L5–S5	**Robinow syndrome** (RS)	CM-II ∅ H ∅	**AD/AR monogenic**	Cystic hygroma, cleft palate, preauricular appendages, complex cardiac defect, hypospadias, anal atresia et al.
n = 9		**f : m = 3 : 6**		**3 × Ts 18** **1 × triploidy** **1 × BBS/1 × FS** **2 × CMNS/1 × RS**		**4 × chromosomal** **5 × monogenic**	

Continued next page

▶ **Table 1** Syndromic and associated neural tube defects. *(Continued)*

Case no.	Gestational week	Sex	Type	Diagnosis	Malformations consequent to NTD	Cause	Syndrome-specific and other concomitant malformations
SB association							
SB 27	15 + 5	m	**LS-MMC** L2–S1	**OEIS**	CM-II ∅ HC ∅	**sporadic/ multifactorial**	Omphalocele, cloacal exstrophy, imperforate anus, SB, scoliosis
SB 28	16	f	**LS-MMC** L4–S5	**OEIS**	**CM-II** H ∅	**sporadic/ multifactorial**	Omphalocele, cloacal exstrophy, imperforate anus, SB, kyphoscoliosis
SB 29	20 + 5	f	S-MMC S1–S5	**OEIS**	CM-II ∅ H ∅	**sporadic/ multifactorial**	Omphalocele, cloacal exstrophy, imperforate anus, SB
SB 30	19	m	**TLS-MMC** Th9–S2	**CDFD**	**CM-II + H**	**sporadic**	Right-sided renal agenesis
SB 31	19	f	**LS-MMC** L2–S2	**CDFD**	**CM-II + H**	**sporadic**	Bilateral renal agenesis, anorectal atresia, Mullerian duct anomalies, vertebral anomalies
n = 5		**f : m = 3 : 2**		**3 × OEIS 2 × CDFD**		**3 × sporad./ multif. 2 × sporadic**	

AC = anencephaly; **amn. rupture seq.** = amnion rupture sequence; **AD** = autosomal dominant; **ass. monogenic** = associated monogenic; **2-Ao/pulm valve** = bicuspid aortic/pulmonary valve; **AR** = autosomal recessive; **CDH** = congenital diaphragmatic hernia; **CDFD** = caudal developmental field defect; **CMNS** = Casamassima-Morton-Nance syndrome; **CoA** = coarctation of the aorta; **CTLS/TLS/LS** = cervico-thoraco-lumbo-sacral; **GI** = gastrointestinal; **H(?)** = hydrocephalus (unclear); **HLH** = hypoplastic left heart; **HPE** = holoprosencephaly; **M-AC** = meroacrania; **MEC** = meningoencephalocele; **MMC** = meningomyelocele; **MKS** = Meckel-Gruber syndrome; **NTD** = neural tube defect; **occ.** = occipital; **OEIS** = omphalocele-(cloacal) exstrophy-imperforate anus-spina bifida complex; **OFD 6** = orofaciodigital syndrome type 6; **PLSVC** = persistent left superior vena cava; **Rec.** = recurrence; **SB** = spina bifida; **SCDO** = spondylocostal dysostosis; **VSD** = ventricular septal defect

▶ **Table 2** Numerical distribution of NTD groups.

Σ	w : m	Syndrome	Ass. monogenic?	Associations	∅-isolated	isolated
AC n = 16 = 23.5%	10 : 6	0/16 = 0%	1/16 = 6.25%	5/16 = 31.25%	6/16 = 37.5%	10/16 = 62.5%
MEC n = 12 = 17.7%	8 : 4	5/12 = 41.6%	3/12 = 25%	2/12 = 16.66%	10/12 = 83.3%	2/12 = 16.7%
SB n = 40 = 58.8%	20 : 20	9/40 = 22.5%	0/40 = 0%	5/40 = 12.5%	14/40 = 35%	26/40 = 65%
NTD n = 68 = 100%	38 : 30	14/68 = 20.6%	4/68 = 5.9%	12/68 = 17.64%	30/68 = 44%	38/68 = 56%

AC = anencephaly; **ass. monogenic** = associated monogenic; **MEC** = meningoencephalocele; **NTD** = neural tube defect; **SB** = spina bifida

ble as an uncovered cord-like prolapse of a ruptured encephalocele sac. One case presented as nasopharyngeal MEC with schisis association (pentalogy of Cantrell) over a transsphenoidal defect.

MEC is a liquor-filled sac like herniation of meningeal and/or brain tissue through a circumscribed cranial defect. Occipital MECs are located in the upper or lower squamous occipital bone with involvement of the posterior fontanelle or of the foramen magnum. They can lead to microcephaly depending on their size (▶ **Figs. 2 b** and **d**). In 5 cases, the MEC was covered by skin. One case with Meckel-Gruber syndrome (MKS) presented with a "double MEC" at the level of the upper and lower occipital bone (▶ **Figs. 2 a** and **c**). Double NTDs presented as MEC + MMC (meningomyelocele) in a case with Noonan syndrome and in one case with associated Dandy-Walker cyst (▶ **Figs. 3 a** to **d**). A case with iniencephaly showed craniorachischisis with progression of the MEC into MMC.

Classification into clinical entities

Two cases corresponded to "isolated" MEC, with one case associated with maternal pre-gestational diabetes (PGD) and cardiac malformation in a sibling. Associated cleft lip and palate and abdominal clefts or malformations and dysmorphisms allowed 2 cases to be classified as schisis association or pentalogy of Cantrell and 5 cases as syndromal disorders. The diagnosed syndromes included del(13q) syndrome (▶ **Fig. 2 d**), MKS, Peters-plus syndrome (PPS) [30], Noonan syndrome (NS) and orofaciodigital syndrome (OFD6), with the latter diagnosed after molecular analysis had excluded Pallister-Hall syndrome (▶ **Tables 1** and **2**). The

▶ **Fig. 1** Anencephaly with meroacrania in a female fetus of 18 weeks of gestation (**a**); anencephaly with holoacrania involving the occipital foramen magnum in a male fetus of 17 + 2 weeks of gestation (**b**) compared with ultrasound image (**d**); typical appearance of anencephaly and proptosis caused by defects of the orbital roof, long nose and macrognathia in the fetus shown in Fig. **a** (**c**); extensive craniorachischisis with involvement of the skull and the entire spine in a female fetus of 16 weeks of gestation (**e**).

diagnoses were confirmed by cytogenetic identification of ring chromosome 13 or by molecular genetic identification of mutations in the *MKS3*, *B3GALTL* and *PTPN11* gene in 3 cases. In 3 syndromic (MKS, PPS, OFD6) and 3 non-syndromic cases, occipital MEC was associated with Dandy-Walker cyst (DWC) and hydrocephalus. Four cases (3 of them syndromic) were recurrences (▶ **Tables 1** and **2**).

Spina bifida (SB)

Spina bifida with and without MMC was the biggest group of neural tube defects with an incidence of 61.8% (n = 40 + 2*). In 2 of these cases* SB was associated with MEC (see above). The sex ratio was almost even at f : m = 20 + 2* : 20. One syndromic case was a recurrence. There was a familial predisposition in 3 isolated cases. The extent of non-closure ranged from 2 vertebrae (L5–S1) in SB occulta to a maximum of 10 vertebrae (L1–S5) in spina bifida aperta (SBA). Affected locations were 1× cervico-thoraco-lumbo-sacral, 1× thoracic*, 1× thoracolumbar (2,38% each), 4× thoracolumbosacral (9,52%), 2× lumbar (5%), 30 + 1*× lumbosacral (77,5%), 1× sacral and 1× presacral in 1 syndromic case (RS see below). In 29 of 42 cases, SB occurred in combination with MMC, i.e. the cystocele was elevated above skin level. X-ray images of the concomitant rachischisis showed separation of the vertebral arches (▶ **Fig. 5 b**). The MMC was covered by a delicate membrane over an oval skin defect with raised edges (▶ **Figs. 4 a** and **5 c**). In 7 cases with pronounced forms of spina bifida it was accompanied by partially gibbus-like kyphoscoliosis (▶ **Figs. 5 a** and **c**). Vertebral anomalies were present in 7 cases; 1 case presented with diastematomyelia. Type II Chiari malformation (CM-II) was found on autopsy in all 26 cases with isolated SB, 24 of whom had hydrocephalus. CM-II was also found in 6 of the 9 syndromic cases – 3× with hydrocephalus – and in 3 of the 5 association cases, 2 of which had hydrocephalus. Hypoplasia of the posterior cranial fossa and elongation and kinking of the medulla oblongata caused by inhibition of pontine expansion were already visible in the NTD fetus (▶ **Fig. 6**). Histological examination showed prolapsing meninges on SB cross-section and parts of the neural plate with an open central canal and an open subarachnoid space (▶ **Figs. 4 b** and **c**). There were no signs of inflammation.

* Two NTD cases with double NTD (MEC + MMC) were listed in both the MEC and the SB groups, increasing the number of SB cases to 40 + 2.

▶ **Fig. 2** Double meningoencephalocele in a male fetus with Meckel-Gruber syndrome in the 19th week of gestation (**a**); small covered encephalocele at the occipitocervical junction in a female fetus with associated Dandy-Walker cyst in the 19th week of gestation (**b**); double meningoencephalocele with MKS – see Fig. **a** – after exposure of the posterior skull (**c**); large occipital encephalocele on prenatal ultrasound (transverse plane) with prolapse of parts of the cerebrum and subsequent microcephaly in a female fetus with del(13q) syndrome at 21 + 5 weeks of gestation (Thomas v. Ostrowski, Praenatalmedizin Dorsten) (**d**).

Classification into clinical entities

Isolated SB was found in 26 of the 42 cases with spina bifida. Five SB cases were present as associated forms occurring concomitantly with OEIS complex (omphalocele, cloacal exstrophy, imperforate anus, spinal anomalies) (3×) or caudal developmental field defect (2×). 9 + 1* cases with SB could be attributed to a chromosomal (3× Ts 18, 1× triploidy) or monogenic syndrome. The latter included the autosomal recessive Bardet-Biedl syndrome (BBS) [29], Fryns syndrome (FS) and the autosomal dominant Robinow syndrome (RS) and Noonan syndrome (NS) (see above under MEC*). Two cases presented with severe spondylocostal dysostosis and concomitant urogenital malformations as part of the autosomal recessive Casamassima-Morton-Nance syndrome (CMNS). In the cases with BBS and NS, syndrome diagnosis was confirmed by the detection of mutations of the *BBS4* and *PTPN11* genes.

Prenatal findings on ultrasound

Exencephaly and anencephaly were already detectable on sonography in the first trimester of pregnancy. Characteristic features found in the longitudinal view included reduced crown-rump length, absent cranial vault and, in some cases, exposed neural tissue with cystic/solid parts floating in the amniotic fluid. Because of the absence of the bony skullcap, in the frontal view the fetal face is limited cranially by the orbits ("frog-eye sign"). Measurement of the biparietal diameter is not possible.

In cases with MEC, ultrasound showed the bony defect through which brain tissue (MEC) or meninges (MC) herniated, and the connection between the contents of the herniated sac and the intracranial space.

Diagnosis of SBA was based on imaging of the fetal spine in all three planes. In the transverse and longitudinal planes, MMC or MC presented as a protrusion over the ossification centers with elevation of the neural placode above the level of the skin. In ruptured MMCs this was located at skin level with interruption of the skin contour. A neurological deficit was documented as pes equinovarus with reduced leg motor activity. In open spinal NTDs, typical intracranial signs were found in the horizontal plane in the second trimester of pregnancy; they included CM-II, obliterated cisterna magna and caudally displaced, usually hypoplastic cerebellum. The typical "banana sign" was visible in almost all cases.

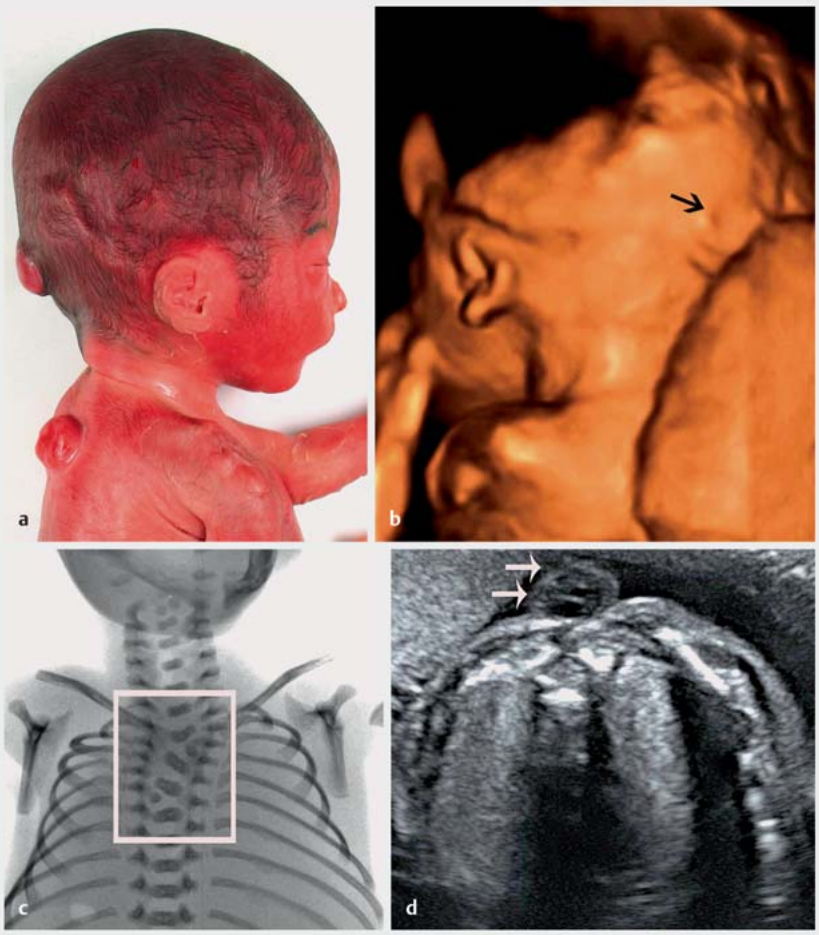

▶ **Fig. 3** Double neural tube defect with small, partially skin-covered occipital meningoencephalocele (MEC) and thoracic meningomyelocele (MMC) in a female fetus in the 25th week of gestation (**a**); MEC on three-dimensional prenatal ultrasound (**b** ↘) and MMC in the horizontal plane (**d** ↘↘); X-ray showing vertebral malformation at Th2–Th5 in the region of the MMC (**c**).

Liquor circulation disorders resulted in a concavity of the parietal bones ("lemon sign"). Microcephaly was also often present. The severity of the concomitant hydrocephalus ranged from "borderline" to pronounced internal hydrocephalus. Closed spinal dysraphism, which occurs with diastematomyelia, was more difficult to detect as there are no secondary cranial changes. One open NTD was already detectable in the first trimester of pregnancy, based on the measurement of "intracranial translucency" (IT, 4th ventricle) and further parameters of the posterior fossa, e.g. the cisterna magna.

Discussion

Malformations were found in 618 of 815 autopsied fetuses. 68 of the 618 fetuses with malformations (11%) had neural tube defects (NTD). 23.5% of NTDs were anencephalies (AC), 17.7% were meningoencephaloceles (MEC) and 61.8%* had spina bifida (SB) with or without meningomyelocele (MMC). A comparable study from Copenhagen reported a rate of 14% NTDs in 693 fetuses with malformations. The ratio of AC:MEC:SB in their study was 43.3:17.5:39.2%, similar to the ratio of 44:7:49% reported in a Canadian study [31,32]. The discrepancies in the distribution reported in their studies and our autopsied cohort could be explained by the high prenatal detection rate of smaller NTDs. When related to the overall figure of 20363 pregnancies monitored by ultrasound by the Prenatal Center Gießen/Marburg between 2004–5/2016, the figure of 38 fetuses with NTD in this cohort gives an NTD rate of 0.19%. This corresponds to the overall prevalence rates reported above.

While the sex ratio for SB was evenly distributed (f:m = 22*:20), the rate of cranial NTDs was almost twice as high in female fetuses compared to males (f:m = 19:9). This was confirmed by a retrospective analysis of 85 cranial NTDs from the years 1976–1983 with a sex ratio of f:m = 56:29 [personal communication H.R.]. One explanation could be that many of the affected male embryos with severe cranial defects are miscarried in early pregnancy and are therefore not documented. This assumption is supported by the balanced gender ratio reported for early NTD embryos [27] In the literature, the higher risk of cranial

▶ **Fig. 4** "In-plane" view of lumbosacral spina bifida (L2–S1) in a female fetus at 19 + 2 weeks of gestation showing an oval soft tissue skin defect with strongly raised edges, a wide vertebral arch (Wb) fissure, exposed spinal canal with exposed non-closed neural plate (**a**) and cross-sectional view of the spina bifida (**c**). Cross-sectional histological image showing a flat neural plate with an open neural groove and open subarachnoid space (HE × 1.25) (**b**).

NTDs in female fetuses has been explained by the hypothesis that female embryos have a slower growth during neurulation, thus exposing them to harmful environmental effects over a longer period of time [33–36].

Three fetuses had double NTDs with MEC + MMC in one case each of Noonan syndrome (NS) and of associated Dandy-Walker cyst (DWC). Characteristic double upper and lower occipital MEC was observed in a case of Meckel syndrome (MKS) [37]. The extent of the neural tube defect in spina bifida ranged from 2 (spina bifida occulta) to 10 vertebrae and in total craniorachischisis included the entire spine. As reported in the literature, the largest group of NTDs concerned lumbosacral NTDs in 77.5 % of the cases [31, 32]. Spina bifida occulta is usually asymptomatic and skin covered. It may represent an incidental finding on X-ray – as in our Noonan case – or it may become apparent postnatally by a circumscribed hypertrichosis or pigmented nevus. An anterior sacral meningocele may initially be suggestive of the Currarino triad (ASP association = anorectal and sacral malformations and mass in the presacral space with meningocele or teratoma). In our case, however, the fetus had Robinow syndrome (RS). In almost all cases, the NTD was diagnosed prenatally on ultrasound, in some cases already in the 1st trimester of pregnancy, and was subsequently confirmed at autopsy. In only 2 cases the MEC was not detected on ultrasound. In the fetus with Peters-plus syndrome (PPS) the MEC and SB occulta were too small, and in the fetus with Noonan syndrome (NS) the MEC was hidden in the nuchal hygroma.

The ratio of isolated to associated and syndromic NTDs was 55.9 : 23.5 : 20.6 %. One case was classified as embryopathy associated with maternal pre-gestational diabetes. While "association" is defined as a "non-random co-occurrence of certain anomalies of unknown cause", the term "syndrome" refers to a "relatively constant and characteristic malformation pattern of genetic origin" – as long as "teratogenic syndrome like phenotypes" are correctly designated as "embryopathies". Associations should also be differentiated from "sequential changes" such as CM-II and hydrocephalus. For non-syndromic NTDs we have to refer to an empirical risk of recurrence (RR), which is reported to be 2 % for isolated forms, i.e. 10 times the geographical prevalence if only one child is affected and 20 times the geographical prevalence with two affected children [3, 36, 38]. Associations and non-hereditary structural chromosomal anomalies, such as ring chromosome 13, are sporadic. Numerical chromosome anomalies resulting from meiotic failure are largely determined by maternal age. Triploidies in diandry and digyny have a RR of 1–1.5 %, independant of maternal age. In contrast, monogenic syndromes follow the pattern of Mendelian inheritance with a high RR. For autosomal recessive disorders such as MKS it is 25 %. Autosomal dominant disorders like Noonan syndrome (NS) usually result from new mutations, and their RR in sibs is therefore not increased. However, if one parent is affected, the RR is 50 %; if germ cell mosaicism is present in one of the parents the RR is ~ 1 %. Diagnosing the syndrome makes it possible to carry out goal directed prenatal ultrasound investigations in subsequent pregnancies which go beyond the search for a single feature such as NTD. Targeted gene analyses can be carried out prenatally to detect or exclude known gene mutations. This underlines the importance or even necessity for syndrome-based diagnostic investigations at fetal autopsies and

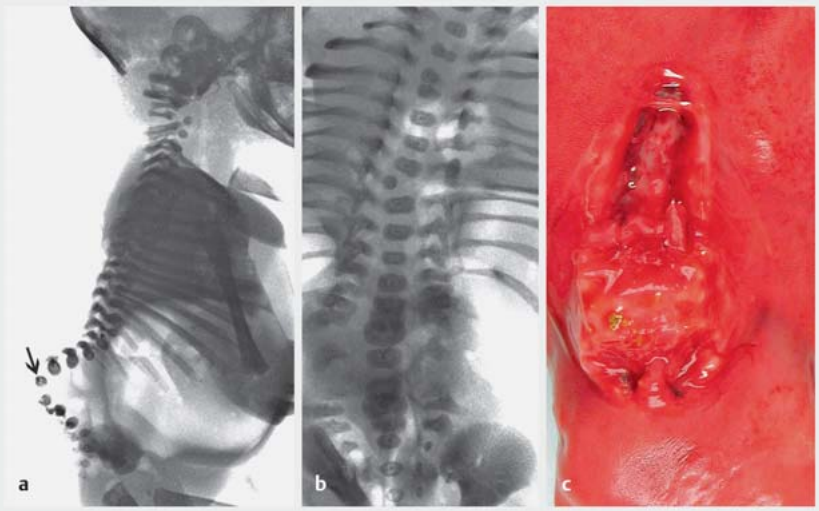

▶ **Fig. 5** Thoraco-lumbo-sacral spina bifida in a male fetus of 21 + 6 weeks of gestation. The fetus shows gibbus-like kyphosis (↘), wide median fissure at the spinal arches Th8–S2, wedged vertebrae and hemivertebrae in the thoraco-lumbo-sacral region on lateral and posterior-anterior X-ray (**a** and **b**). Dorsal view of the open spinal canal with exposed necrotic neural tissue (**c**).

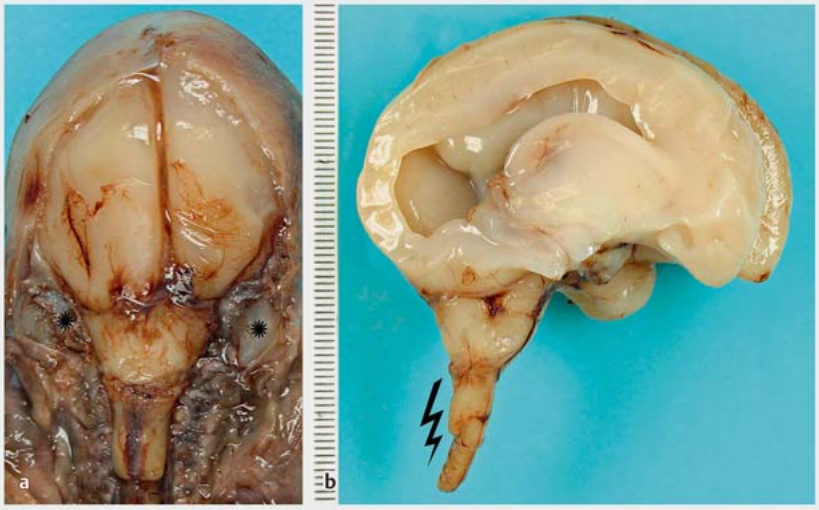

▶ **Fig. 6** Chiari II malformation (CM-II) in the female fetus (20th week of gestation) shown in ▶ **Fig. 4**. The skull and spinal canal have been opened dorsally; there is herniation of parts of the cerebellum and medulla oblongata through the distended occipital foramen magnum (* edge) into the spinal canal (**a**). Brainstem and upper spinal cord show distinct elongation and Z-shaped kinking and lateral ventricles are dilated due to hydrocephalus as shown by a longitudinal section through the right cerebral hemisphere (**b**).

the targeted search for mutations, or at least for a photographic and radiographic documentation of anomalies which will allow retrospective syndrome assignment.

Our 14 syndromic NTDs included 5 chromosomal in part prenatally diagnosed cases [Ts 18, triploidy, del (13q)]. The rate of 7.4% for chromosomal NTDs equals the rates of 6.5–7% reported in the literature. The percentage of spina bifida with a chromosomal anomaly among our NTDs was 12.5% compared to the reported rates of 9–10% [31, 32, 39]. In the 9 monogenic syndromes, most NTDs and associated malformations had been detected on prenatal ultrasound. However, assignment to specific syndromal entities was made only after abortion during assessment of the autopsy findings.

The only syndrome in our cohort where the NTD was a syndrome-specific feature was MKS [37]. NTD is fairly common in Ts 18 and was found in 12% of all of our Ts 18 cases. NTD occasionally

is observed with triploidy, del(13q) and spondylocostal dysostosis (SCDO) or Casamassima-Morton-Nance syndrome (CMNS). A case of Fryns syndrome (FS) with associated craniorachischisis was recently described for the first time [40]. NTDs had not previously been reported for any of the other syndromic cases in our cohort. According to the "London Dysmorphology Database" around 88 syndromes include MEC among their characteristics and 62 include MMC [41]. However, this list does not enclose the syndromes PPS, NS, orofaciodigital syndrome (OFD6), Bardet-Biedl syndrome (BBS), FS and RS which we observed in our cohort and which could therefore be added to the list. It is worth noting that fetuses with syndromic disease can be severely affected and present with unusual features, since syndromes are defined by their postnatal appearance and fetuses with severe manifestation of the disorder often die prenatally. In 4 cases (MKS, PPS, NS, BBS) the clinical diagnosis of the syndrome was confirmed by molecular genetic analysis. No molecular analysis was carried out in the remaining cases.

Schisis association, OEIS and caudal developmental field defect as observed in our cohort, represent well-known sporadic disorders. The association of MEC and DWC and of AC with cebocephaly, which we found in non-syndromic form in 3 cases and 1 case respectively, points to a genetic or monogenic background with a higher RR and would increase the percentage of genetic NTDs to 26.5%. In fact, one of these 4 cases was a recurrence. The malformation risk of maternal PGD is 2–9 times higher compared to non-diabetic women. It involves cardiac malformations in the first instance, followed by malformations of the CNS, such as NTD. It is noteworthy that there appeared to be a connection between PGD and anencephaly or encephalocele but not between PGD and SB [6, 42]. Our case of isolated occipital encephalocele coupled with maternal PGD and a sibling with cardiac malformation emphasizes this concomitance.

Conclusion

In this study of the pathologies of 68 fetuses with neural tube defects (NTD), the NTD rate calculated for a total of 618 fetuses with malformations was 11% which is comparable to the rates reported in the literature. When the study investigated the frequency distribution of anencephaly (AC), meningoencephalocele (MEC) or spina bifida (SB), the number of fetuses with SB or MEC found in our cohort was significantly higher. This could be partly explained by the higher rate of detection of smaller defects. The evenly balanced ratio of females to males among the cases with caudal NTD and the clear female predominance in the cases with severe cranial NTDs would be consistent with a higher death rate of severely affected male fetuses in early pregnancy. The most significant finding in our study was the high percentage of NTDs of genetic origin (26.5%). Monogenic syndromes predominated, while only 7.4% of cases with NTD were caused by pre- or postnatally detectable chromosome anomalies. The high risk of recurrence for monogenic disorders and the finding that NTD was often not included in the spectrum of features reported for a specific syndrome and that therefore ultrasound investigations in subsequent pregnancies, focusing on NTDs only, will not be useful, emphasize the importance and necessity of syndrome-based investigation in fetal pathology, a targeted search for syndrome-related mutations, and careful photographic and radiographic documentation of fetal malformations and dysmorphisms. It would be very much in the interest of pregnant women and their family planning if a fetal pathologist with experience in syndromology would be more closely involved into prenatal medicine.

Acknowledgement

Our thanks go to the staff of the Institute of Pathology, Lucia Goldhammer and Elke Reitter (medical technical assistants), Petra Krupitza (photo lab), Andrea Hofmann (administration) for their technical assistance, to Dr. Anette Rode (Lohfelden) for contacts with patients (▶ **Fig. 3a**). We would like to thank Dr. G. Pantazis (Neuropathology) and Prof. Dr. R. Moll, Director of the Institute, for their support. Special thanks go to Astrid Becker (Leverkusen) for her excellent organizational and advisory contributions.

Conflict of Interest

The authors declare that during compilation of the article no conflicts of interest were present as defined in the recommendations of the International Committee of Medical Journal Editors.

References

[1] Larsen W. Human Embryology. 3rd ed. Philadelphia: Churchill Livingstone; 2001: 98–102

[2] Copp AJ, Greene ND. Genetics and development of neural tube defects. J Pathol 2010; 220: 217–230

[3] Copp AJ, Stanier P, Greene ND. Neural tube defects: recent advances, unsolved questions, and controversies. Lancet Neurol 2013; 12: 799–810

[4] Bassuk AG, Kibar Z. Genetic basis of neural tube defects. Semin Pediatr Neurol 2009; 16: 101–110

[5] Kibar Z, Torban E, McDearmid JR et al. Mutations in VANGL1 associated with neural-tube defects. N Engl J Med 2007; 356: 1432–1437

[6] Gabbay-Benziv R, Reece EA, Wang F et al. Birth defects in pregestational diabetes: defect range, glycemic threshold and pathogenesis. World J Diabetes 2015; 6: 481–488

[7] Wilson RD; SOGC Genetics Committee; special contributor. Prenatal screening, diagnosis, and pregnancy management of fetal neural tube defects. J Obstet Gynaecol Can 2014; 36: 927–939

[8] Amari F, Junkers W, Hartge D et al. Prenatal course and outcome in 103 cases of fetal spina bifida: a single center experience. Acta Obstet Gynecol Scand 2010; 89: 1276–1283

[9] Wilson RD, Wilson RD et al.; Genetics Committee. Pre-conception folic acid and multivitamin supplementation for the primary and secondary prevention of neural tube defects and other folic acid-sensitive congenital anomalies. J Obstet Gynaecol Can 2015; 37: 534–552

[10] Graf K, Kohl T, Neubauer BA et al. Percutaneous minimally invasive fetoscopic surgery for spina bifida aperta. Part III: neurosurgical intervention in the first postnatal year. Ultrasound Obstet Gynecol 2016; 47: 158–161

[11] Johnson MP, Bennett KA, Rand L et al. The Management of Myelomeningocele Study: obstetrical outcomes and risk factors for obstetrical complications following prenatal surgery. Am J Obstet Gynecol 2016; 215: 778.e1–778.e9

[12] Kohl T. Percutaneous minimally invasive fetoscopic surgery for spina bifida aperta. Part I: surgical technique and perioperative outcome. Ultrasound Obstet Gynecol 2014; 44: 515–524

[13] Chiari H. Über Veränderungen des Kleinhirns, des Pons und der Medulla oblongata infolge von Hydrocephalie des Grosshirns. Dtsch Med Wochenschr 1891; 27: 1172–1175

[14] McLone DG, Dias MS. The Chiari II malformation: cause and impact. Childs Nerv Syst 2003; 19: 540–550

[15] Januschek E, Röhrig A, Kunze S et al. Myelomeningocele – a single institute analysis of the years 2007 to 2015. Childs Nerv Syst 2016; 32: 1281–1287

[16] Norman MG, Ludwin SK. Congenital Malformations of the nervous System. In: Davis RL, Robertson DM, eds. Textbook of Neuropathology. 2nd ed. Baltimore: Williams & Wilkins; 1991: 207–280

[17] Creasy MR, Alberman ED. Congenital malformations of the central nervous system in spontaneous abortions. J Med Genet 1976; 13: 9–16

[18] Khoshnood B, Loane M, de Walle H et al. Long term trends in prevalence of neural tube defects in Europe: population based study. BMJ 2015; 351: h5949

[19] Frey L, Hauser WA. Epidemiology of neural tube defects. Epilepsia 2003; 44 (Suppl. 3): 4–13

[20] Laurence KM. The Genetics and Prevention of neural Tube Defects. In: Emery AEH, Rimoin DI, eds. Principles and Practices of medical Genetics. Vol. I. Edinburgh: Churchill Livingstone; 1983: 232–245

[21] Dolk H, De Wals P, Gillerot Y et al. Heterogeneity of neural tube defects in Europe: the significance of site of defect and presence of other major anomalies in relation to geographic differences in prevalence. Teratology 1991; 44: 547–559

[22] Flatz G, Sukthomya C. Frontoethmoidal encephalomeningoceles in the population of Northern Thailand. Hum Genet 1970; DOI: 10.1007/BF00296297

[23] Fuhrmann W, Weitzel HK. Maternal serum alpha-fetoprotein screening for neural tube defects. Report of a combined study in Germany and short overview on screening in populations with low birth prevalence of neural tube defects. Hum Genet 1985; 69: 47–61

[24] Nishimura H, Takano K, Tanimura T et al. Normal and abnormal development of human embryos: first report of the analysis of 1,213 intact embryos. Teratology 1968; 1: 281–290

[25] Shepard TH, Fantel AG, Fitsimmons J. Congenital defect rates among spontaneous abortuses: twenty years of monitoring. Teratology 1989; 39: 325–331

[26] McFadden DE, Kalousek DK. Survey of neural tube defects in spontaneously aborted embryos. Am J Med Genet 1989; 32: 356–358

[27] Coerdt W, Miller K, Holzgreve W et al. Neural tube defects in chromosomally normal and abnormal human embryos. Ultrasound Obstet Gynecol 1997; 10: 410–415

[28] Sambrook J, Russel D. Molecular Cloning. A Laboratory Manual. New York: Cold Spring Harbor; 2001: 6.28–6.30

[29] Knopp C, Rudnik-Schöneborn S, Eggermann T et al. Syndromic ciliopathies: from single gene to multigene analysis by SNP arrays and next generation sequencing. Mol Cell Probes 2015; 29: 299–307

[30] Schoner K, Kohlhase J, Müller AM et al. Hydrocephalus, agenesis of the corpus callosum, and cleft lip/palate represent frequent associations in fetuses with Peters' plus syndrome and B3GALTL mutations. Fetal PPS phenotypes, expanded by Dandy Walker cyst and encephalocele. Prenat Diagn 2013; 33: 75–80

[31] Nielsen LA, Maroun LL, Broholm H et al. Neural tube defects and associated anomalies in a fetal and perinatal autopsy series. APMIS 2006; 114: 239–246

[32] Kennedy D, Chitayat D, Winsor EJT et al. Prenatally diagnosed neural tube defects: ultrasound, chromosome, and autopsy or postnatal findings in 212 cases. AJMG 1998; 77: 317–321

[33] Lary JM, Paulozzi LJ. Sex differences in the prevalence of human birth defects: a population-based study. Teratology 2001; 64: 237–251

[34] Seller MJ. Sex, neural tube defects, and multisite closure of the human neural tube. AJMG 1995; 58: 332–336

[35] Martinez Frias ML, Parallo JA, Salvador J et al. Sex ratios in neural tube defects. Lancet 1986; 2: 871–872

[36] Copp AJ, Greene ND. Neural tube defects–disorders of neurulation and related embryonic processes. Wiley Interdiscip Rev Dev Biol 2013; 2: 213–227

[37] Rehder H, Labbé F. Prenatal morphology in Meckel's syndrome (with special reference to polycystic kidneys and double encephalocele). Prenat Diagn 1981; 1: 161–171

[38] Harper PS. Practical genetic Counselling. 7. Aufl. London: Edward Arnold (Publishers) Ltd.; 2010: 194–196

[39] Sepulveda W, Corral E, Ayala C et al. Chromosomal abnormalities in fetuses with open neural tube defect: Prenatal identification with ultrasound. Ultrasound Obstet Gynecol 2004; 23: 352–356

[40] Singh A, Pilli GS, Bannur H. Craniorachischisis totalis with congenital diaphragmatic hernia – a rare presentation of Fryns syndrome. Fetal Pediatr Pathol 2016; 35: 192–198

[41] Winter RM, Baraitser M. London Medical Database (LMD) – Dysmorphology Photo Library on CD-Rom Version 3.0. London: Oxford University Press; 2001

[42] Garne E, Loane M, Dolk H et al. Spectrum of congenital anomalies in pregnancies with pregestational diabetes. Birth Defects Res A Clin Mol Teratol 2012; 94: 134–140