Endoscopic ultrasound of duodenal heterotopic gastric mucosa

A 50-year-old woman presented with dyspepsia but no history of weight loss or gastrointestinal bleeding. Esophagogastroduodenoscopy (EGD) showed a sessile polypoidal submucosal lesion in the second part of the duodenum close to the ampulla with a central opening (fish-mouth appearance) (▶ **Fig. 1**). The contour of this lesion was smooth and there was no disruption of the surrounding folds, nor ulceration or bleeding. Linear endoscopic ultrasound (EUS) was performed for evaluation of the lesion. This revealed that the lesion was arising from the mucosa/submucosa of the duodenum and had a cystic anechoic central core in the submucosa with no solid component and well-demarcated margins (▶ **Fig. 2**; ▶ **Video 1**).

On the basis of the EUS images, it was suspected that this was heterotopic gastric mucosa (HGM) and therefore the decision was made to resect the lesion endoscopically. The patient underwent polypectomy and the submucosal lesion was sent for histopathology. The histopathological examination confirmed the presence of HGM revealing fundal and pyloric glands covered by duodenal epithelium (▶ **Fig. 3**).

HGM is common in all organs of the gastrointestinal tract, particularly in the esophagus and duodenum [1]. A recent study found duodenal HGM appearing as solitary or multiple small nodules in 1.9 % of 28 210 patients who underwent EGD with duodenal biopsy [2].

EUS for the evaluation of submucosal lesions is a well-established entity, but literature with regard to the EUS description of duodenal HGM is rare. Hizawa et al. [3] described duodenal HGM presenting as a simple anechoic mass within the submucosa. In a recent series of six patients with duodenal HGM, the lesions appeared as solitary, sessile submucosal lesions with a depression at the top [1]. On EUS, these lesions had a heterogeneous pattern with or without an anechoic area and were located within the mucosa/submucosa.

Although HGM is a benign entity, it may require laparoscopic or endoscopic resection if the lesion is large in size.

▶ **Fig. 1** Esophagogastroduodenoscopy (EGD) showing a sessile polypoidal submucosal lesion in the second part of the duodenum close to the ampulla with a central opening (fish-mouth appearance). The contour of this lesion was smooth and there was no disruption of the surrounding folds, and no ulceration, bleeding, hyperemia, or adjacent mucosal edema.

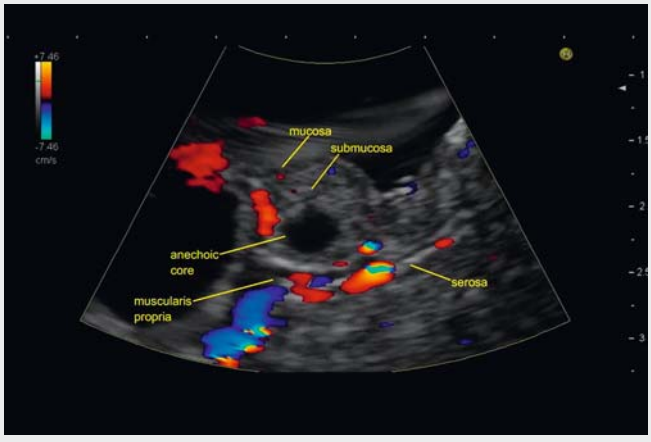

Video 1 Esophagogastroduodenoscopy (EGD) showing a sessile polypoidal submucosal lesion in the second part of the duodenum close to the ampulla with a central opening (fish-mouth appearance). The lesion is grasped by biopsy forceps and the duodenum is filled with water for endoscopic ultrasound (EUS) imaging. Linear EUS shows that the heterogeneous lesion is arising from the mucosa and submucosa of the duodenum and has a cystic anechoic central core in the submucosa without any solid component. On zoom endoscopy and color Doppler imaging, the layers of the duodenal wall are well demarcated and the lesion is avascular. Polypectomy is performed with a snare.

Endoscopy_UCTN_Code_CCL_1AB_2AZ_3AB

Competing interests

None

This document was downloaded for personal use only. Unauthorized distribution is strictly prohibited.

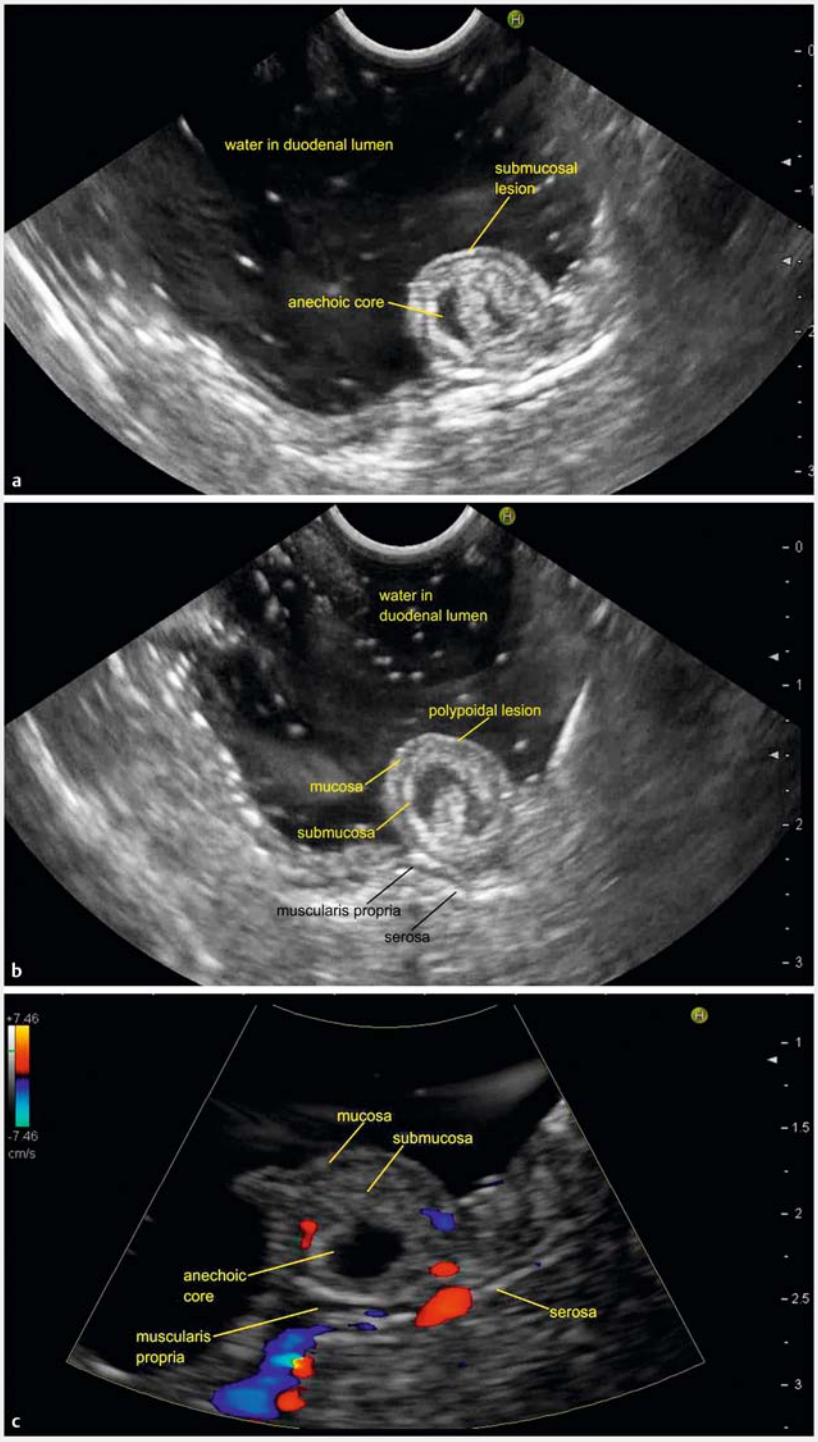

▶ **Fig. 2** Linear endoscopic ultrasound (EUS) images showing: **a** a submucosal polypoid lesion with a cystic anechoic core, seen from the duodenum filled with water; **b** the polypoidal lesion arising from the mucosa and submucosa of the duodenum; **c** a cystic anechoic central core in the submucosa without any solid component, along with well-demarcated margins on zoom imaging, and no blood flow on color Doppler imaging.

The Authors

Malay Sharma[1], Piyush Somani[1], Krishnaveni Janarthanan[2], Saurabh Jindal[1], Rajendra Prasad[1], Ruth Shifa Hari[1]

1 Department of Gastroenterology, Jaswant Rai Speciality Hospital, Meerut, Uttar Pradesh, India

2 Department of Gastroenterology, PSG Institute of Medical Sciences & Research, Coimbatore, India

Corresponding author

Malay Sharma, MD, DM
Department of Gastroenterology, Jaswant Rai Speciality Hospital, Saket, Meerut, PIN-250 001, Uttar Pradesh, India
Fax: +91-121-2657154
sharmamalay@hotmail.com

This document was downloaded for personal use only. Unauthorized distribution is strictly prohibited.

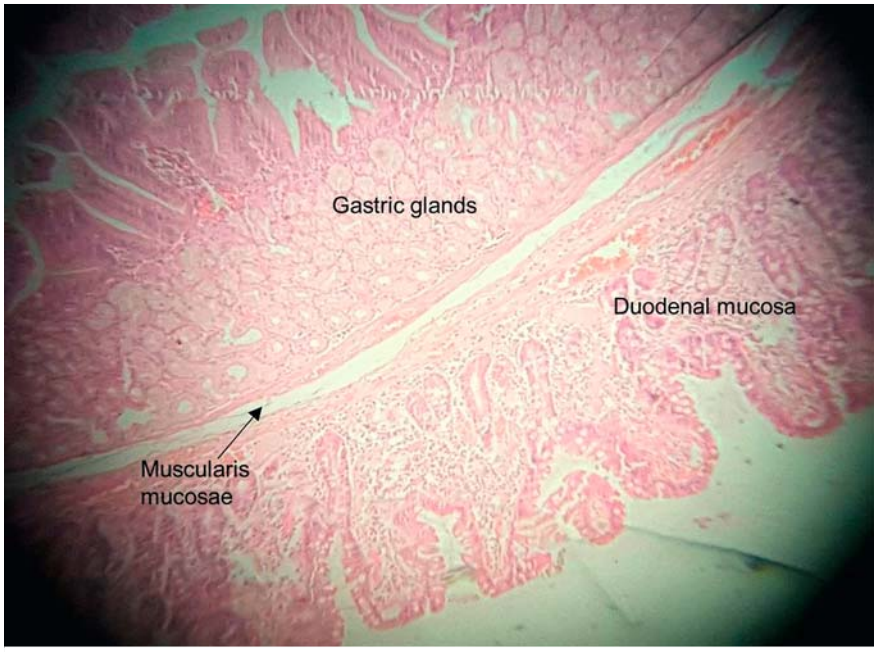

▶ **Fig. 3** Histological examination of the polypectomy specimen showing the lesion covered by normal duodenal mucosa consisting of gastric type foveolar epithelium, gastric fundal glands, and pyloric glands consistent with heterotopic gastric mucosa.

References

[1] Eguchi K, Aoyagi K, Nimura S et al. Diagnostic value of endoscopic and endoscopic ultrasound characteristics of duodenal submucosal tumour-like heterotopic gastric mucosa. Can J Gastroenterol 2011; 25: 365 – 367

[2] Genta RM, Kinsey RS, Singhal A et al. Gastric foveolar metaplasia and gastric heterotopia in the duodenum: no evidence of an etiologic role for *Helicobacter pylori*. Hum Pathol 2010; 41: 1593 – 1600

[3] Hizawa K, Matsumoto T, Kouzuki T et al. Cystic submucosal tumors in the gastrointestinal tract: endosonographic findings and endoscopic removal. Endoscopy 2000; 32: 712 – 714

Bibliography
DOI https://doi.org/10.1055/s-0043-105569
Endoscopy 2017; 49: E168–E170
© Georg Thieme Verlag KG
Stuttgart · New York
ISSN 0013-726X

ENDOSCOPY E-VIDEOS
https://eref.thieme.de/e-videos

Endoscopy E-Videos is a free access online section, reporting on interesting cases and new techniques in gastroenterological endoscopy. All papers include a high quality video and all contributions are freely accessible online.

This section has its own submission website at https://mc.manuscriptcentral.com/e-videos

This document was downloaded for personal use only. Unauthorized distribution is strictly prohibited.