

Retrospective analysis of large bowel obstruction or perforation caused by oral preparation for colonoscopy



Authors

Akihiro Yamauchi, Shin-ei Kudo, Yuichi Mori, Hideyuki Miyachi, Masashi Misawa, Hatsumi Kamo, Tomokazu Hisayuki, Toyoki Kudo, Takemasa Hayashi, Kunihiko Wakamura, Atsushi Katagiri, Toshiyuki Baba, Eiji Hidaka, Fumio Ishida

Institution

Digestive Disease Center, Showa University Northern Yokohama Hospital

submitted 15.8.2016

accepted after revision 9.2.2017

Bibliography

DOI <https://doi.org/10.1055/s-0043-106200> | Endoscopy International Open 2017; 05: E471–E476
© Georg Thieme Verlag KG Stuttgart · New York
ISSN 2364-3722

Corresponding author

Shin-ei Kudo, MD, Digestive Disease Center, Showa University Northern Yokohama Hospital, 35-1 Chigasaki-Chuo, Tsuzuki-ku, Yokohama, Kanagawa 224-8503, Japan
Fax: +81-45-949-7263
kudos@med.showa-u.ac.jp

ABSTRACT

Background and study aims Patients undergoing bowel preparation for colonoscopy are at risk of potentially severe adverse events such as large-bowel obstruction (LBO) and perforation. These patients usually need emergency surgery and the consequences may be fatal. Little is known about the risk factors for LBO and perforation in these cir-

cumstances. We sought to establish the natural history of LBO and perforation caused by oral preparation for colonoscopy.

Patients and methods We retrospectively analyzed data from 20 patients with LBO or perforation associated with oral preparation for colonoscopy. All patients were treated at the Showa University Northern Yokohama Hospital (SUNYH) between April 2001 and December 2015. Drugs used for bowel preparation, age, sex, indication for colonoscopy, pathogenesis and treatment were recorded.

Results Eighteen of the patients had LBO and 2 had perforation. Fourteen events occurred at SUNYH, which accounted for 0.016% of patients who underwent bowel preparation during this period. Seventeen patients were symptomatic when the decision to undertake colonoscopy was made (including 7 who complained of constipation and 4 who complained of abdominal pain; 3e were asymptomatic). Nineteen patients ultimately required surgery, 13 within 3 days of presentation. Eleven patients ultimately required colostomy. There was no perioperative mortality in our cases.

Conclusion Large bowel obstruction and perforation are rare events associated with oral preparation for colonoscopy, but frequently require surgery. Exacerbation of constipation might be a risk factor for LBO or perforation. Potentially catastrophic situations can be avoided by early detection and treatment.

Introduction

Colorectal cancer is a common disease. According to the Ministry of Health, Labour and Welfare, cancer has been the most common cause of death in Japan since 2013; colorectal cancer is the most frequent cause of cancer-related death in women. Colonoscopy plays a critical role in the early detection and treatment of colorectal cancer [1, 2].

Oral polyethylene glycol (PEG) is the most popular means of preparing the bowel for colonoscopy in Japan, but magnesium citrate (MC) and sodium phosphate (sodium dihydrogen phosphate monohydrate/sodium dihydrogen phosphate anhydrous)

are also widely used. Oral bowel preparation for colonoscopy is associated with potential adverse events [3].

Many studies have reported adverse events (AEs) associated with colonoscopy, but most have focused on those caused by the conduct of colonoscopy or by endoscopic treatment of the abnormalities detected rather than those caused by bowel preparation for colonoscopy [4].

The most severe AEs associated with oral bowel preparation are large bowel obstruction (LBO) and perforation [5]. Acute, complete LBO requires emergency abdominal surgery, and is associated with high morbidity and mortality rates if left untreated.

In September 2003, an emergency safety bulletin was issued by the Ministry of Health, Labour and Welfare in Japan highlighting the risks of LBO and perforation caused by oral bowel preparation for colonoscopy [6]. According to this bulletin, LBO occurred in 7 patients between July 1993 and September 2003 (1 of whom died [14.3%]) and perforation occurred in 11 patients (5 of whom died [45.5%]).

This report had a profound impact on routine clinical practice in Japan. When a patient had severe constipation or standard preparation was suboptimal, we always used additional preparation. Nevertheless, the risk of LBO or perforation may be elevated by the use of additional bowel preparation drugs.

Consequently, clinicians must have a high index of suspicion that complications might arise in patients with severe constipation, or in whom bowel preparation is inadequate with standard techniques.

But it contained no scientific analysis of the likely pathogenesis of the adverse events documented. Consequently, the risk factors for LBO and perforation during bowel preparation for colonoscopy are not fully understood. We undertook a retrospective analysis of patients who had developed LBO or a bowel perforation associated with oral preparation drugs, to inform the development of a suite of preventive measures for patients undergoing colonoscopy. We sought to clarify the causes and risk factors for LBO and perforation.

Patients and methods

We undertook a retrospective analysis of patients' clinical records at Showa University Northern Yokohama Hospital (SUNYH), Japan. The subjects of the study were patients of SUNYH treated between April 2001 and December 2015, who were diagnosed with LBO or perforation caused by oral drugs for bowel preparation.

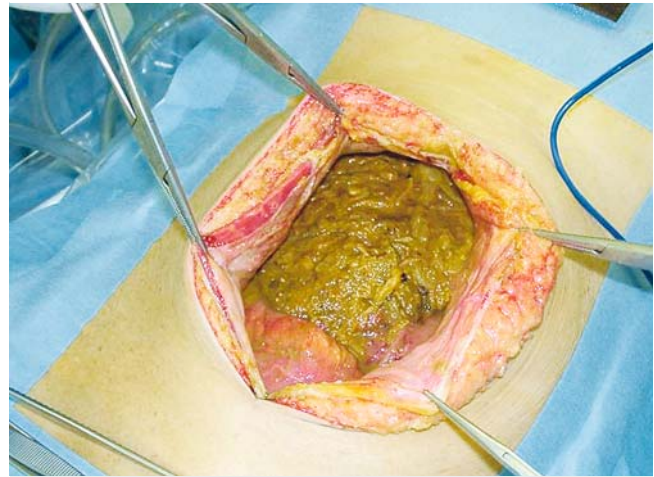
We recorded the following for each patient: age, sex, indications for colonoscopy, preparation drug or drugs used, location of LBO/perforation, pathogenesis, requirement for surgery, requirement for emergency surgery, requirement for colostomy and mortality. From these data, we analyzed the pathogenesis of LBO and perforation, and we propose prophylactic measures for the prevention of these AEs.

Results

We identified 20 patients (13 men and 7 women) diagnosed with LBO or perforation associated with oral bowel preparation drugs, who were treated at SUNYH in the study period. Fourteen cases underwent colonoscopy at SUNYH, while six occurred at other hospitals and were referred to SUNYH for treatment. The frequency of LBO or perforation associated with oral bowel preparation at SUNYH was 0.016% (14 out of 86,463 colonoscopies).

Among the 14 patients of SUNYH, 12 were diagnosed with LBO and two were diagnosed with perforation. A representative case of bowel perforation is illustrated in ► Fig. 1.

► Table 1 shows the demographic and clinical details of the cohort. The mean age was 64.9 years (\pm standard deviation 12.4



► **Fig. 1** A representative case of a patient with large bowel perforation. The reported symptom at the first hospital visit was narrowing of the stool. There had been defecation on the day of examination. The patient drank 2800 mL polyethylene glycol and defecated 7 times, and subsequently reported sudden-onset abdominal pain and cold sweats. We performed computed tomography and confirmed the presence of free air, ascites and rectal cancer. Emergency surgery was undertaken and at laparotomy, a large amount of intraperitoneal stool was present.

years). The mean duration of symptoms before colonoscopy was undertaken was 70.7 ± 92.4 days; 8 patients had presented with constipation, 6 with abdominal pain and 2 with anorexia; 3 were asymptomatic.

The drug used for bowel preparation was PEG in 15 cases and MC in 1 case; 1 patient was given both, 2 were given sodium picosulfate hydrate (SPH) and 1 patient was given SPH and MC the day before colonoscopy.

The cause of the AE was judged to be advanced cancer in 18 patients, transverse colon stenosis resulting from inflammation that had spread from an inflamed gallbladder in 1 patient, and bowel obstruction by feces in 1 patient.

For patients with cancer, the mean maximum tumor diameter was 55.6 ± 21.8 mm. The tumor was situated in the sigmoid colon in 10 patients, the rectum in 4 patients, the transverse colon in 2 patients and the ascending colon in 2 patients. All patients with perforation underwent urgent surgery. Patients with LBO were treated in 1 of 3 ways: urgent surgery within 3 days (8 patients); elective surgery (3 patients); or decompression by placement of a long intestinal tube (LIT) or self-expanding metallic stent (SEMS) followed by surgery (7 patients; 5 had a LIT and 2 a SEMS). Nineteen patients required surgery; 11 (57.9%) required a colostomy. There was no perioperative mortality.

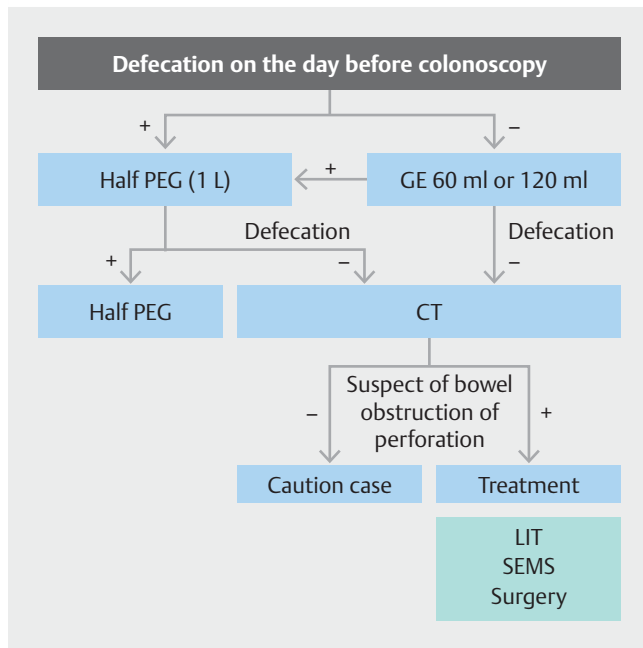
We have used a strategic protocol for colonoscopy preparation since 2004 (► Fig. 2), to prevent LBO and perforation. A detailed history of defecation status during preparation taken by specialist endoscopy nurses can contribute to early prevention and detection of AEs. After we started using the protocol, the incidence of AEs was reduced from 0.044% (2001–2003, 4 out of 9,175 patients) to 0.013% (2004–2015 10 out of 77,288 patients). This difference was not statistically significant ($P=$

► Table 1 Clinicopathological features.

Institution at which complication occurred	No.	Sex	Age (yrs)	Symptom	Preparation drug		Disease	Cause	Location	T	Treatment
					on the day before	on the day of					
SUNYH	1	M	65	Constipation	-	PEG	LBO	Cancer	A/C	T3	LIT → surgery
	2	M	62	Stool narrowing, abdominal pain	+	PEG	LBO	Cancer	A/C	T3	LIT → emergency surgery + stoma
	3	M	70	Stool narrowing	-	PEG	P	Cancer	R ¹	T4a	Emergency surgery + stoma
	4	M	62	Constipation	+	-	LBO	Cancer	R	T2	LIT → emergency surgery + stoma
	5	F	81	Constipation, rectal bleeding	+	-	LBO	Cancer	S/C	T3	Surgery
	6	M	91	Constipation, abdominal pain	+	MC	LBO	Cancer	T/C	T4a	LIT → emergency surgery
Other	7	F	39	Jaundice, abdominal pain	-	PEG	LBO	Cancer	S/C	T3	Surgery + stoma
	8	M	69	Abdominal pain	-	PEG	LBO	Cholecystitis	T/C	-	LIT → surgery + stoma
	9	F	71	None	+	PEG	LBO	Feces	S/C	-	Observation
	10	F	71	None	+	PEG	P	Cancer	S/C	T3	Emergency surgery + stoma
	11	M	72	None	+	PEG	LBO	Cancer	T/C	T3	LIT → emergency surgery + stoma
	12	F	68	Constipation	+	PEG MC	LBO	Cancer	R	T3	Surgery
	13	M	68	Diarrhea	+	PEG	LBO	Cancer	S/C	T3	SEMS → surgery + stoma
	14	M	57	Abdominal pain, stool narrowing	-	PEG	LBO	Cancer	S/C	T3	SEMS → surgery
	15	M	57	Constipation	+	PEG	LBO	Cancer	R	T4a	Emergency surgery + stoma
	16	M	61	Diarrhea, abdominal pain	+	PEG	LBO	Cancer	S/C	T4b	Emergency surgery + stoma
	17	F	35	Constipation	+	PEG	LBO	Cancer	S/C	T3	Emergency surgery
	18	F	69	Abdominal pain	+	-	LBO	Cancer	S/C	T3	LIT → surgery
	19	M	70	Constipation, abdominal fullness	-	PEG	LBO	Cancer	S/C	T3	Emergency surgery
	20	M	60	Stool narrowing	-	PEG	LBO	Cancer	S/C	T3	Emergency surgery + stoma

MC, magnesium citrate; LBO, obstruction; P, perforation; T, tumor (AJCC T classification); R, rectal; S/C, sigmoid colon; T/C, transverse colon; LIT, long intestinal tube; SUNYH, Showa University Northern Yokohama Hospital; PEG, polyethylene glycol; SEMS, self-expandable metallic stent.

¹ There were three types of cancer: 1 S/C and 2 R cancer. The large bowel perforation was considered to be caused by R cancer.



► **Fig. 2** Strategy for colonoscopy preparation at the Showa University Northern Yokohama Hospital for preventing bowel obstruction and perforation. Caution case means Conservative management and observation. PEG, polyethylene glycol; CT, computed tomography; GE, glycerin enema; LIT, long intestinal tube; SEMS, self-expandable metallic stent.

0.053), but might suggest the presence of a trend towards fewer AEs since introduction of the protocol ($P < 0.05$ was considered significant).

Discussion

Large bowel obstruction and perforation associated with oral preparation for colonoscopy are rare, but they can be fatal and, thus, require early recognition and prompt treatment.

AEs that have been reported include: Mallory-Weiss syndrome and esophageal perforation caused by vomiting [7–10]; acute respiratory distress syndrome caused by aspiration pneumonia [11]; allergy and anaphylactic shock [12–14]; hyperphosphatemia [15, 16] and ischemic colitis caused by peroral preparation drugs [17–19]. There have also been a few reports of LBO and perforation caused by bowel preparation. [5] A previous report of bowel perforation in 2 patients (1 of whom died from colon perforation caused by colorectal cancer, the other underwent emergency colostomy) suggested that use of magnesium sulfate, an osmotic laxative that creates hypertonic pressure in the intestine after oral administration, might have contributed. [5] Magnesium sulfate prevents water reabsorption, mechanically stimulates intestinal peristalsis and facilitates bowel movement, thereby softening the stool and cleansing the intestinal tract. In this case, it was judged that magnesium sulfate had increased the intraluminal pressure of the obstructed colon until it ruptured.

Ours was a retrospective review of patients with LBO or perforation. In both cases of perforation, PEG was used. Although

PEG is excreted in the feces without disturbing serum and urinary electrolyte concentrations or urine volume, it nonetheless increases intraluminal pressure in the intestinal tract. As with the reported cases with magnesium sulfate, we judge increased pressure within the intestine – and the presence of a vulnerable lesion – to have been the cause of bowel perforation on our cohort.

The preparation strategy outlined in ► **Fig. 2** also informs clinical decision-making and ensures patient safety. Prompt use of imaging, administration of enemas and adjustment of drug doses can mitigate against precipitous increases in intestinal pressure, and contributes to the early detection and management of LBO and perforation.

In addition, LBO and perforation rarely occur in the absence of malignancy. We should pay attention to the cases if the existence of malignant tumor is known or strongly suspected by previous doctor's introduction, computed tomography (CT) or high tumor marker.

In LBO and perforation caused by cancer cases, 11 cases (61%) had increased levels of the tumor marker carcinoembryonic antigen (CEA). The average was 43.9 ng/mL. Seven patients had CEA levels less than 5 ng/mL. About LBO or perforation cases, even though it is difficult to predict LBO or perforation, it may have been possible to suspect the presence of a tumor in more than half the cases.

We also judge exacerbation of constipation to be a risk factor for bowel perforation, given that 7 patients who subsequently developed LBO had initially presented with disturbance of bowel movement. Indeed, a total of 12 patients had reported abnormal bowel movement if stool narrowing and diarrhea were included, both of which may accompany severe constipation. Both patients with perforation presented with stool narrowing, not constipation.

Strict confirmation of the defecation state before bowel preparation may have the potential to avert AEs. In routine clinical practice, we attempt to diagnose AEs as promptly as possible using imaging tests such as x-ray and CT if patients report lack of defecation and abdominal symptoms after bowel preparation has been administered. Nevertheless, it is not possible to prevent all AEs, as some occur with sudden onset and some patients are asymptomatic when the decision to undertake colonoscopy is made. An appreciation of the risks of oral preparation for colonoscopy and a high index of suspicion among healthcare professionals can ensure that AEs are detected and treated promptly to avoid the need for surgery and to prevent deaths.

In 8 patients in our cohort large tumors had been identified on CT before colon preparation. We suggest that non-oral bowel preparation should be used (for example, glycerin enema) when massive tumors are detected before colonoscopy.

Patients' medical history and serum albumin concentrations are presented in ► **Table 2**. The mean serum albumin concentration was 3.7 g/dL. Hypoalbuminemia (serum albumin concentration < 3.8 g/dL) was evident in 11 cases (61.1%). Mean body mass index (BMI) was 21.0 kg/m², and was below 18.5 kg/m² in 4 cases (22.2%). Three patients (16.7%) were found to have colonic diverticular disease. We judge that nutri-

► **Table 2** Medical history of colorectal cancer patient occurred large bowel obstruction and perforation caused by preparation.

No.	BMI	Serum albumin (g/dL)	CEA (ng/mL)	Medical history	Surgical history
1	14.0	2.9	<5.0	None	None
2	18.9	3.6	6.4	None	None
3	22.5	3.5	23.7	Diabetes mellitus, hypertension	None
4	25.7	3.0	<5.0	Colon diverticulum	Appendicitis
5	25.4	4.1	<5.0	None	None
6	23.4	3.5	23.4	Hypertension, hyperuricemia, dementia	Gallbladder stone
7	22.7	3.3	180.5	None	None
10	18.6	4.3	7.4	None	None
11	17.1	3.7	<5.0	Cerebral infarction, diabetes mellitus, hypertension, paroxysmal atrial fibrillation	Lung carcinoma
12	17.9	3.4	<5.0	Diabetes mellitus, angina pectoris, lipid metabolism disorders	Appendicitis
13	25.1	4.0	158.8	Myocardial infarction	Appendicitis
14	20.6	4.3	<5.0	None	Appendicitis
15	19.2	4.2	38.4	Heart failure	Appendicitis
16	25.5	3.6	6.2	Colon diverticulum	None
17	15.8	3.4	<5.0	Gastric ulcer	None
18	24.3	4.4	11.1	None	Uterine prolapse
19	19.3	3.4	9.2	None	None
20	21.2	4.6	18.3	Colon diverticulum	None

BMI, body mass index; CEA, carcinoembryonic antigen

tional condition, colonic diverticular disease and BMI did not strongly influence our findings. The number of control groups was too large, it was difficult to evaluate the risk factor of this study, and it became a one arm evaluation. In future, larger, prospective observational or retrospective case-controlled studies may help to illuminate the risk factors for LBO and perforation.

Conclusion

In conclusion, LBO and perforation associated with an oral preparation for colonoscopy are rare, but can have severe consequences. LBO or perforation cannot accurately be predicted from bowel habit and abdominal findings alone. Potentially catastrophic situations can be avoided by early detection and treatment. All staff working in endoscopy units should have an appreciation of the adverse events associated with preparation for colonoscopy.

Competing interests

None

References

- [1] Zauber AG, Winawer SJ, O'Brien MJ et al. Colonoscopic polypectomy and long-term prevention of colorectal-cancer deaths. *N Engl J Med* 2012; 366: 687–696
- [2] Winawer SJ, Zauber AG, Ho MN et al. Prevention of colorectal cancer by colonoscopic polypectomy. The National Polyp Study Workgroup. *N Engl J Med* 1993; 329: 1977–1981
- [3] Hasan AG, Brown WR. Colonic cleansing for colonoscopy: a risk to be taken seriously. *Gastrointest Endosc* 2011; 73: 616–618
- [4] Gavin DR, Valori RM, Anderson JT et al. The national colonoscopy audit: a nationwide assessment of the quality and safety of colonoscopy in the UK. *Gut* 2013; 62: 242–249
- [5] Ji D. Oral magnesium sulfate causes perforation during bowel preparation for fiberoptic colonoscopy in patients with colorectal cancer. *J Emerg Med* 2012; 43: 716–717
- [6] Japanese Ministry of Health, Labour and Welfare. Statement of caution for perforation and obstruction by oral drugs of bowel preparation. 2003
- [7] Nishida Y, Hamaro M, Sakaguchi H. Mallory-Weiss syndrome with colonic lavage. *J Gastroenterol Surg* 1999; 32: 997–1001
- [8] Hroncich ME. Mallory Weiss tears due to colonoscopy preps. *Am J Gastroenterol* 1994; 89: 292
- [9] Santoro MJ, Chen YK, Collen MJ. Polyethylene glycol electrolyte lavage solution-induced Mallory-Weiss tears. *Am J Gastroenterol* 1993; 88: 1292–1293

- [10] McBride MA, Vanagunas A. Esophageal perforation associated with polyethylene glycol electrolyte lavage solution. *Gastrointest Endosc* 1993; 39: 856–857
- [11] Mosquera RA, McDonald M, Samuels C. Aspiration pneumonitis caused by polyethylene glycol-electrolyte solution treated with conservative management. *Case Rep Pediatr* 2014; DOI: 10.1155/2014/872634
- [12] Lee SH, Cha JM, Lee JI et al. Anaphylactic shock caused by ingestion of polyethylene glycol. *Ann Pharmacother* 2015; 13: 90–94
- [13] Brullet E, Moron A, Calvet X et al. Urticarial reaction to oral polyethylene glycol electrolyte lavage solution. *Gastrointest Endosc* 1992; 38: 400–401
- [14] Stollman N, Manten HD. Angioedema from oral polyethylene glycol electrolyte lavage solution. *Gastrointest Endosc* 1996; 44: 209–210
- [15] Vukasin P, Weston LA, Beart RW. Oral Fleet Phospho-Soda laxative-induced hyperphosphatemia and hypocalcemic tetany in an adult: report of a case. *Dis Colon Rectum* 1997; 40: 497–499
- [16] Ullah N, Yeh R, Ehrinpreis M. Fatal hyperphosphatemia from a phosphosoda bowel preparation. *J Clin Gastroenterol* 2002; 34: 457–458
- [17] Munekata M, Kasai M, Kon K. A case of ischemic colitis induced by preparation in colonoscopic examination. *J Japan Soc Gastroenterol* 2002; 99: 1334–1338
- [18] Oh JK, Meiselman M, Lataif LEJr. Ischemic colitis caused by oral hyperosmotic saline laxatives. *Gastrointest Endosc* 1997; 45: 319–322
- [19] Rex DK, Schwartz H, Goldstein M et al. Safety and colon-cleansing efficacy of a new residue-free formulation of sodium phosphate tablets. *Am J Gastroenterol* 2006; 101: 2594–2604