Thermal Ablation of Lung Tumors: Focus on Microwave Ablation

Thermoablation von Lungentumoren: Mikrowellenablation im Fokus

Authors

Thomas J. Vogl[1], Nour-Eldin A. Nour-Eldin[1], Moritz Hans Albrecht[1], Benjamin Kaltenbach[1], Wolfgang Hohenforst-Schmidt[2], Han Lin[3], Bita Panahi[1], Kathrin Eichler[1], Tatjana Gruber-Rouh[1], Andrei Roman[1, 4]

Affiliations

1 Institute for Diagnostic and Interventional Radiology, Goethe-Universitat Frankfurt am Main, Germany
2 Medical Clinic I, "Fuerth'' Hospital, Friedrich-Alexander-University Erlangen-Nurnberg, Fuerth, Germany
3 Department of Radiology and Radiological Sciences, Medical University of South Carolina, Charleston, United States
4 Department of Radiology, Iuliu Hatieganu University of Medicine and Pharmacy, Cluj-Napoca, Romania

Key words

ablation procedures, lung, metastases, NSCLC

received 09.01.2017
accepted 27.03.2017

Bibliography

DOI https://doi.org/10.1055/s-0043-109010
Published online: 16.5.2017 | Fortschr Röntgenstr 2017; 189: 828–843 © Georg Thieme Verlag KG, Stuttgart · New York, ISSN 1438-9029

Correspondence

Andrei Roman
Department of Radiology, Iuliu Hatieganu University of Medicine and Pharmacy, Victor Babeş Nr. 8,
400012 Cluj-Napoca, Romania
Tel.: +40/7 40/02 14 54
andrei.roman@umfcluj.ro

ZUSAMMENFASSUNG

Hintergrund Bild-gesteuerte thermische Ablationen können zur Behandlung von inoperablem primärem und metastatischem Lungenkrebs eingesetzt werden. Diese Techniken basieren auf der Erwärmung oder Abkühlung (Kryotherapie) eines Gewebevolumens um einen perkutanen Applikator, der eine Nekrose des Tumors induziert.

Methode Die englischsprachige Literatur betreffend Thermalablation der Lunge wurde durchgesehen. Die Radiofrequenz-Ablation (RFA) ist das am weitesten verbreitete und erforschte Verfahren dieser Ablationstechniken. Die Mikrowellenablation (MWA) stellt eine relativ neue Alternative dar, die unter gleichen Indikationen und in ähnlicher Weise wie die RFA durchgeführt wird. Es wurde experimentell und klinisch gezeigt, dass mittels MWA größere und sphärischere Ablationszonen über kürzere Zeiträume im Vergleich zu RFA erreicht werden können. In Europa und den USA stehen sieben verschiedene MWA-Systeme zur Verfügung, die signifikante Unterschiede in Größe und Form der erzeugten Ablationszonen aufweisen.

Ergebnisse Die mit der MWA assoziierten Komplikationen, sowie deren Häufigkeiten, sind denen der RFA sehr ähnlich. Die lokalen Progressionsraten nach MWA von Lungentumoren variieren zwischen 0 % und 34 % die mit den Daten der RFA-Literatur vergleichbar sind.

Schlussfolgerung Trotz technischer Verbesserungen hat die aktuelle Generation von MWA-Systemen ähnliche klinische Ergebnisse wie die RFA.

Kernaussagen

- Bei der MWA handelt es ich um ein sicheres Therapieverfahren welches daher als Behandlungsalternative bei nicht operablen Lungentumoren in Erwägung gezogen werden sollte.
- Da die Thermoablation von Lungentumoren immer mehr Anwendung findet, sollten Radiologen mit dem Erscheinungsbild der Ablation in der Bildgebung vertraut sein.
- Obwohl die MWA theoretische Vorteile gegenüber der RFA hat, ist der Therapieerfolg vergleichbar.

ABSTRACT

Background Image-guided thermal ablation can be used for the treatment of medically inoperable primary and metastatic lung cancer. These techniques are based on the heating up or freezing (cryoablation) of a volume of tissue around a percutaneous applicator that induces necrosis of the tumor.

Method The English-language literature concerning thermal ablation of the lung was reviewed. Radiofrequency ablation (RFA) is the most widely performed and investigated of these techniques. Microwave ablation (MWA) represents a relatively new alternative that shares the same indications and is conducted in a very similar fashion as RFA. It has been experimentally and clinically shown that MWA produces larger, more spherical ablation zones over shorter periods of time compar-

This document was downloaded for personal use only. Unauthorized distribution is strictly prohibited.

ed to RFA. Seven different MWA systems are available in Europe and the USA with significant differences in the size and shape of the produced ablation zones.

Results The types of complications caused by MWA and their rates of occurrence are very similar to those caused by RFA. The local progression rates after MWA of lung malignancies vary between 0 % and 34 % and are similar to those in the RFA literature.

Conclusion Despite technical improvements, the current generation of MWA systems has comparable clinical outcomes to those of RFA.

Key Points

- MWA is a safe technique that should be considered one of the treatment options for medically inoperable lung tumors
- As thermal ablations of lung tumors are becoming more frequent, radiologists should be acquainted with the post-ablation imaging characteristics
- Although MWA has some theoretical advantages over RFA, the clinical outcomes are similar

Citation Format

- Vogl TJ, Nour-Eldin NA, Albrecht MH et al. Thermal Ablation of Lung Tumors: Focus on Microwave Ablation. Fortschr Röntgenstr 2017; 189: 828–843

Introduction

The curative treatment of lung tumors, both primary and metastatic, has undergone substantial diversification in the last two decades. New treatment techniques provide a range of options from parenchyma-sparing surgical resection techniques and video-assisted thoracoscopic surgery (VATS) to the highly efficient radiation delivery method represented by stereotactic body radiation therapy (SBRT) and image-guided thermal ablation therapies, such as radiofrequency (RFA), microwave (MWA), and cryoablation. The multitude of techniques and their constant improvement raise the question of which approach is most beneficial for optimal patient outcome. Although SBRT and the thermal ablation therapies have shown lower control rates compared to surgical resection, their main advantage is their reduced invasiveness and impact on respiratory function. Therefore, they offer patients with medically inoperable early-stage NSCLC or oligometastatic disease a potentially curative treatment option. In comparison to RFA which has been in use since the early 2000 s and is currently the most widely performed and evaluated thermal ablation technique, MWA is a relatively new treatment option, with the first large patient series study being published in 2008 by Wolf et al. [1]. Since then, more than 20 articles have been published in the literature concerning the MW treatment of NSCLC and lung metastases with a main focus on outcome and complications [2 – 22]. The purpose of this paper is to review the literature regarding MWA in the broader context of thermal ablation. RFA and MWA are the most widely used techniques that are based on inducing necrosis through high temperatures with both procedures performed in a similar fashion. Other techniques that are used less often, such as cryoablation and irreversible electroporation, will only be briefly discussed. The imaging follow-up, indications and some of the complications are identical between MWA and RFA. Therefore, complication management is based on the more abundant RFA literature, with differences being highlighted accordingly.

Technical considerations

MWA systems generate an ellipsoidal microwave field around a needle-like applicator that is introduced into the tissue. Microwaves are part of the electromagnetic spectrum with frequencies between 300 MHz and 300 GHz. Since water molecules have a positively and a negatively charged pole, they tend to align with the electromagnetic waves. The oscillation of the electromagnetic wave therefore causes a rapid flip motion of the water molecules which results in heating of the adjacent tissue through the mechanism of dielectric hysteresis. If the MW frequency perfectly matched the molecule-specific resonance frequency of the water molecules, all energy would be transformed into heat, but the penetrability into the tissue would be low. The frequencies used by the current MW manufacturers (915 MHz and 2450 MHz) only partially match the resonance frequency of the water molecules and therefore assure efficient energy conversion into heat with satisfactory tissue penetrability [23 – 25].

RFA is based on electromagnetic radio waves with frequencies of less than 1 MHz. An electric field is generated within the body between the active applicator and a grounding pad (monopolar systems) or between two electrodes located within the applicator. The alternating electric field, which is stronger in the vicinity of the applicator, induces the oscillation of ions, which, in turn, induces frictional tissue heating. In contrast to MW, RF energy deposition is dependent on the electrical permittivity of the tissue. Therefore, tissues with increased resistivity such as the aerated lung have an insulating effect by limiting the transformation of RF energy into heat energy to the close proximity of the applicator [26 – 28]. Although the vast majority of RFA ablations are performed percutaneously, bronchoscopy-guided RFA has also been reported. This technique might lead to fewer complications such as pneumothorax, but is limited by the need of having a bronchus in the close proximity of the tumor [29].

Cryoablation is a technique based on generating temperatures as low as –160° C around an applicator that spread by convection in the surrounding tissue. The ablation process lasts 25 – 30 minutes and consists of successive freezing-thawing cycles which induce cell death by protein denaturation, membrane disruption and microvascular thrombosis. The main advantage of cryoabla-

This document was downloaded for personal use only. Unauthorized distribution is strictly prohibited.

tion is better real-time CT monitoring of the ablation zone in comparison to the other techniques [28, 30, 31].

Irreversible electroporation (IRE) is the most recent ablation technique that induces cell death by irreversibly increasing the cell membrane permeability through the application of a high-voltage electrical field. General anesthesia is always necessary because of the neuromuscular blockade required to prevent current-induced muscular contractions. The utility of IRE in the treatment of lung tumors remains to be proven [32].

Advantages of microwave ablation

Despite the differences between MWA and RFA, both techniques induce coagulation necrosis of the tissue caused by temperatures over 60 °C, even if the shape and size of the ablation zone, as well as the speed at which the desired ablation volume is reached differ between the two techniques. MWA generally produces larger, more spherical and predictable ablation zones because the microwave field uniformly penetrates the tissue and is less dependent on its properties. In contrast, RFA is hampered by the high electrical resistivity of lung tissue which limits energy deposition. Tissue changes caused by ablation, such as carbonization and desiccation, also increase tissue resistivity, thus further hindering the expansion of the ablation zone [33, 34]. The high electrical resistivity of a ventilated lung and the ablation-induced tissue inhomogeneity make the expansion of the ablation zone particularly reliant on thermal conduction, especially at its periphery. This fact renders the heat produced by RFA vulnerable to being washed out by vessels as small as 3 mm, a phenomenon known as the heat sink effect [35, 36]. In contrast, MWA, whose heating deposition ability is favored by the presence of water, has been proven to be less susceptible to the heat sink effect by inducing complete thrombosis of most vessels with a diameter < 6 mm [37, 38].

While discussing the performance of MWA, it should be taken into account that seven different MWA systems are presently on the European and American markets without considering those that are available only on Asian markets. The individual characteristics of these devices have been thoroughly described elsewhere [23, 24, 39]. These are either low-frequency (915 MHz) or high-frequency (2450 MHz) devices, with the maximum output power varying between 32 W and 140 W and some of them allowing the concomitant use of up to three antennas. The size and shape of the ablation zone created by MWA is most likely the complex result of multiple factors such as the MW frequency, the design and cooling system of the antenna, the power setting and the total ablation time. The combination of these factors leads to significant differences between devices regarding the characteristics of the ablation zones (▶ **Fig. 1**). This has been demonstrated by Hoffmann et al. who directly compared four different MWA systems under the same conditions using an ex-vivo liver model [40]. Therefore, upon deciding in favor of a specific MWA system, one should be well informed about its performance and how it compares to the other devices on the market.

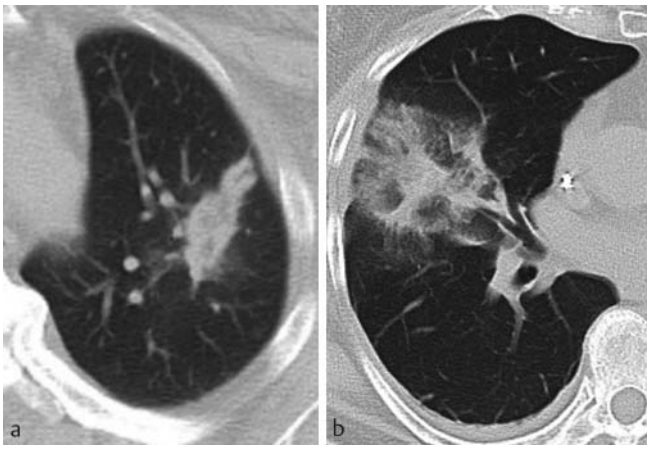

▶ **Fig. 1** Example of ablation zones created by two different MWA systems. **a** Ablation using a low-frequency (915 MHz) MWA system with a duration of 10 minutes and a power of 45 W. **b** Ablation using a high-frequency (2450 MHz) system with a duration of 8 minutes and an average power of 92 W. Notice the difference between the size and shape of the ablation zones.

▶ **Abb. 1** Beispiel für Ablationszonen, die von zwei verschiedenen MWA-Systemen erzeugt wurden. **a** Ablation unter Verwendung eines niederfrequenten (915 MHz) MWA-Systems mit einer Dauer von 10 Minuten und einer Leistung von 45 W. **b** Ablation unter Verwendung eines Hochfrequenzsystems (2450 MHz) mit einer Dauer von 8 Minuten und einer durchschnittlichen Leistung von 92 W. Die Größe und Form der Ablationszonen variieren deutlich.

Ablation technique

Thermal ablation of a lung malignancy must be proposed to the patient after prior consultation in an interdisciplinary tumor board. The patient will be informed about alternative treatment options while highlighting their advantages and disadvantages. Besides uncorrectable or severe coagulopathies, there is no absolute contraindication regarding thermal ablation of lung tumors. Therefore, the coagulation status has to be verified before the intervention. Anticoagulation and antiplatelet drugs have to be ceased at least 5 days prior to the intervention. The following values are recommended by the consensus guidelines for the periprocedural management of coagulation status and hemostasis risk in percutaneous image-guided interventions: INR < 1.5; aPTT > 1.5x control if heparin is administered; and platelet count > 50 000 [41].

The intervention may be performed under conscious sedation or general anesthesia. Hoffmann et al. concluded that neither approach was associated with different tumor control or complication rates [42]. General anesthesia might prove useful for anxious patients or when multiple tumors are to be ablated during the same session. General anesthesia might also help when the tumor is located in the mobile lower segments of the lung, since a longer breath-hold can be triggered by the anesthetist thus allowing more accurate targeting [42, 43]. At our institution, analgosedation using a combination of Piritramide and Diazepam administered shortly before the intervention is preferred, with additional administration of Piritramide if the need arises.

This document was downloaded for personal use only. Unauthorized distribution is strictly prohibited.

The antenna insertion technique is almost identical to that of CT-guided biopsies. Immediately prior to the intervention, an unenhanced CT scan of the chest is performed in order to plan the best puncture approach. Intravenous contrast agent might sometimes be necessary in order to visualize intratumoral blood vessels or to differentiate tumor from atelectasis. The patient position will be chosen depending on the location of the lesion, but the prone position is recommended whenever possible, since it is associated with less chest wall motion. Lateral decubitus should be avoided because of the unstable position and the more pronounced chest wall motion [44]. The antenna insertion path should be chosen above the cranial margin of the rib and away from higher caliber intrapulmonary blood vessels in order to prevent intra-pleural and intra-parenchymatous bleeding. Crossing of lung fissures or emphysematous areas should also be avoided to prevent a pneumothorax. After choosing the best path, the skin entry point can be marked with the help of a metallic marker placed on the skin using single-slice scans. The puncture site will then be disinfected and isolated with sterile drapes and local anesthesia will be applied to the skin and pleura. Following a small skin incision using a scalpel, the antenna will be inserted under breath-hold as close as possible to the center of the tumor. Single-slice scans or CT fluoroscopy will be used to verify the position of the antenna and to correct it if necessary [45 – 47].

The success of the ablation depends mainly on the size of the ablation margin which depends on the size of the tumor, the size of the ablation zone and the position of the antenna relative to the tumor. A tumor is likely to be successfully ablated if it is completely engulfed by the ablation zone with a sufficiently wide safety margin. The importance of the ablation margin has been proven after thermal ablation of both the liver and the lung and most authors agree that an ablation margin of at least 5 mm and, whenever possible, up to 10 mm is required for complete ablation [48 – 52]. Therefore, as long as a sufficient ablation margin is achieved, it is not necessary for the antenna to be placed in the center of the tumor. However, larger tumors which often have an irregular shape, require a higher level of precision and might necessitate the concomitant placement of multiple antennas or subsequent reablation [43]. Based mainly on the tumor size, but also on other factors such as the distance to the chest wall, mediastinum or large vessels, ablation time and power should be carefully adjusted in order to produce a large enough ablation zone without doing unnecessary damage to the adjacent structures. As previously discussed, the shape and size of the ablation zone is different between the various MWA devices and depends on the power setting and duration of the ablation [40]. For each device, the relationship between ablation time/power and the size of the ablation zone is documented and made available by the manufacturer. These parameters should be well known by the user because the true extent of the ablation zone often cannot be assessed on the scans performed during ablation. Despite the lower susceptibility of MWA to the heat sink effect, it should not be ignored and higher power settings or longer ablation times might be considered if larger blood vessels are close to the tumor. Although it is a rare occurrence, needle-tract seeding can be prevented by ablating the puncture tract while slowly removing the antenna after the treatment is considered to be complete [17, 53, 54].

Imaging follow-up

As local ablative techniques become more widely used, radiologists, even those not working in specialized centers, are more likely to encounter patients who have undergone such therapies and should be familiar with the evolution of ablated lesions. The post-procedural evolution of the ablation zone is usually divided into three continuous phases with corresponding histologic and imaging findings [55 – 57]. The features of the thermally ablated lung tissue have first been described after RFA, but are similar to those after MWA [37, 38].

The early phase (< 1 week)

The post-ablation histological and CT findings remain largely unchanged over the first week [58]. The ablation zone is described by most authors as a succession of three concentric layers of tissue with different histological characteristics. The cells in the innermost layer show signs of thermal damage but the tissue maintains a seemingly intact alveolar structure. The middle layer has a similar appearance as the inner one but the alveolar spaces are filled with effusion and some degree of congestion can be noticed. The outer layer shows strong congestion and hemorrhage and consists of both damaged and viable cells [37, 58, 59].

On CT images acquired at this phase, the ablated lesion appears surrounded by an inner zone of ground glass opacity (GGO) which corresponds to the inner and middle histopathological layers and by a thin, dense outer rim which corresponds to the outer layer (▶ **Fig. 1 – 4**) [33, 55, 58, 59]. If contrast agent is administered, the outer rim usually shows circular benign periablational enhancement [60]. The ablated tumor is often still visible within the ablation zone but does not show any contrast enhancement. The ablation should be considered successful if the tumor is completely surrounded by the GGO and a sufficient ablation margin was achieved. The outer hyperdense rim should not be counted as part of the completely ablated area as it might contain viable cells. Incomplete ablation should be considered if the tumor exceeds the GGO and/or continues to show contrast enhancement [55, 58].

Non-contrast or contrast-enhanced CT should be performed within one day after ablation in order to evaluate the completeness of the ablation and to evaluate the potential necessity for an additional procedure. The CT examination also allows for the detection of early complications such as a broncho-pleural fistula that might require a prolonged hospital stay.

The intermediate phase (1 week to 3 months)

During the first 2 – 3 months after the procedure, the necrotic tissue within the ablation zone undergoes a process of granulation and fibrosis [57, 58]. As this process takes place, the GGO pattern gradually changes into a nodular or fibrotic pattern while the ablation zone steadily decreases in size. At this stage, the vast majority of ablation zones will still exceed the size of the initial tumor. In some cases, it might stagnate in size and in other cases increase in size over time, due to accompanying obstructive pneumonitis (▶ **Fig. 2**) [58, 61]. Furthermore, the necrotic tissue may be directly evacuated through a bronchus leading to the forma-

This document was downloaded for personal use only. Unauthorized distribution is strictly prohibited.

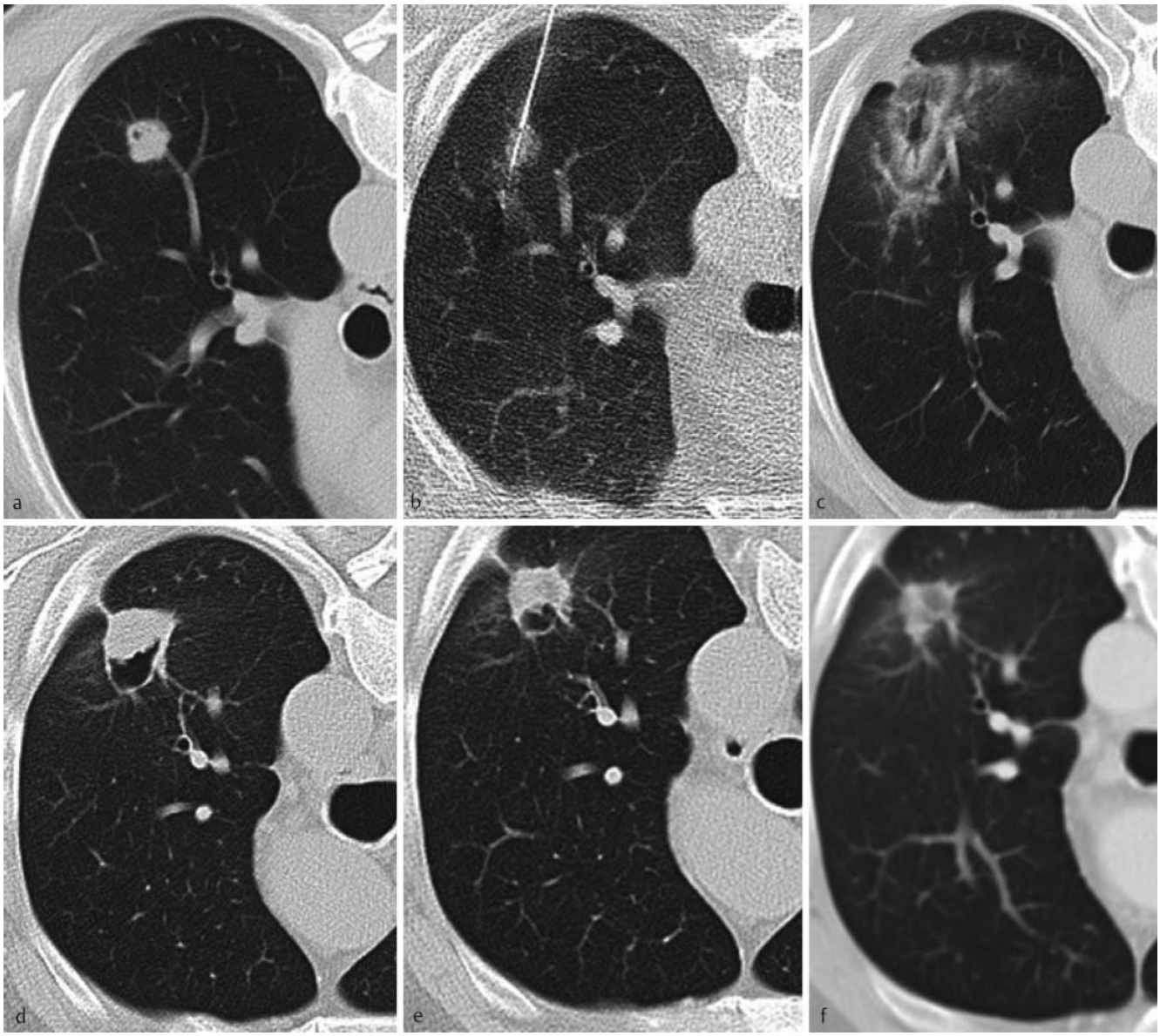

▶ **Fig. 2** High-frequency ablation of a lung metastasis originating from a colorectal carcinoma (10 minutes; 96 W). Typical evolution of the ablation zone after successful ablation. **a** Preinterventional aspect of the tumor. **b** Image obtained during ablation. Correct position of the antenna. **c** Image obtained 24 hours after ablation showing the typical concentric rings. **d** Image obtained 3 months after ablation showing cavity formation, feature known to be associated with a lack of progression. **e** Images obtained 7 months and **f** 16 months after ablation show continuous contraction of the ablation zone.

▶ **Abb. 2** Hochfrequenzablation einer Lungenmetastase eines kolorektalen Karzinoms (10 Minuten, 96 W). Dargestellt ist die typische Entwicklung der Ablationszone nach erfolgreicher Ablation. **a** Präinterventioneller Aspekt des Tumors. **b** Die korrekte Position der Antenne wurde durch periinterventionelle Bilder sicher gestellt. **c** Das Bild 24 Stunden nach der Ablation zeigte die typischen konzentrischen Ringe. **d** Das Bild 3 Monate nach der Ablation zeigte eine Hohlraumbildung. Dieses günstige Zeichen ist mit geringer bis keiner Progression assoziiert. **e** Die Bilder, die 7 Monate und **f** 16 Monate nach der Ablation acquiriert wurden, zeigen eine kontinuierliche Kontraktion der Ablationszone.

tion of a cavity which has been shown to be related to an increased risk of superinfection [1, 58, 62]. Most cavities disappear on follow-up, but some remain unchanged or even increase in size (▶ **Fig. 2, 3**) [57, 62, 63]. Completely ablated tumors will normally not show contrast enhancement besides the persisting benign periablational enhancement pattern [55]. Except for procedures in which a large part of the tumor remains unablated, local tumor progression will rarely be detected within the intermediate phase.

The late phase (> 3 months)

Three months after the procedure, the fibrous transformation is nearly complete, resulting in a stagnation or further decrease of

This document was downloaded for personal use only. Unauthorized distribution is strictly prohibited.

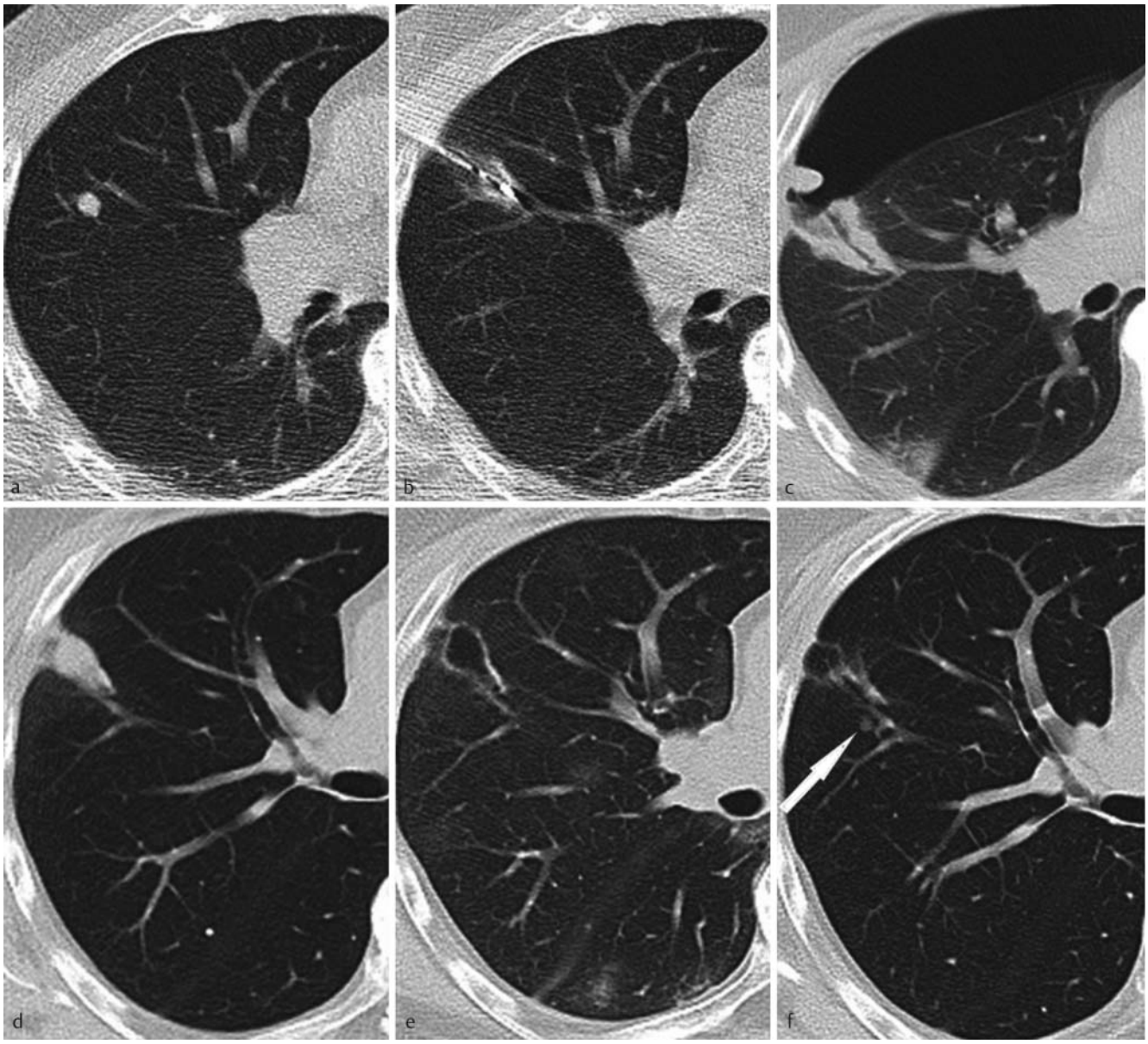

▶ **Fig. 3** High-frequency ablation of a pulmonary metastasis deriving from a colorectal carcinoma (8 minutes; 62 W). Aspect of the tumor shortly before **a** and during ablation **b**. **c** Image obtained 24 hours after ablation showing a delayed pneumothorax that was successfully managed using pleural drainage. After 3 months the ablation zone has a nodular aspect **d**, and there were changes into a cavity at 6 months **e**. **f** 9 months after ablation, the cavity is replaced by a fibrous pattern, but a new periablational nodularity can be noticed representing local progression of the tumor.

▶ **Abb. 3** Hochfrequenzablation einer kolorektalen Lungenmetastase (8 Minuten, 62 W). Gezeigt ist der Aspekt des Tumors kurz vor **a** und während der Ablation **b**. **c** Das Bild, das 24 Stunden nach der Ablation akquiriert wurde, zeigte einen verzögerten Pneumothorax, der erfolgreich mit einer Pleuradrainage behandelt wurde. Nach 3 Monaten hat die Ablationszone einen knotigen Aspekt **d** und wandelt sich nach 6 Monaten **e** in einen Hohlraum um. **f** Neun Monate nach der Ablation wird der Hohlraum durch fibröses Gewebe ersetzt. Zusätzlich jedoch zeigte sich eine neue periablatorische Nodularität, die die lokale Progression des Tumors darstellt.

the ablation zone (▶ **Fig. 2 – 4**). At this point, the size can be smaller, larger or similar to that of the tumor prior to ablative treatment [64]. The pattern of the ablation zone can be fibrous, nodular or cavitary [57]. The CT examination performed 3 months after the ablation should be taken as a baseline for subsequent examinations and any further growth of the ablation zone should be considered as local progression [55, 64].

After 3 months, the ablation zone might show slight contrast enhancement which corresponds to a revascularization phenomenon but it should remain weaker than the initial tumor enhancement [65]. The benign periablational enhancement might also persist for up to 6 months after the treatment [60].

This document was downloaded for personal use only. Unauthorized distribution is strictly prohibited.

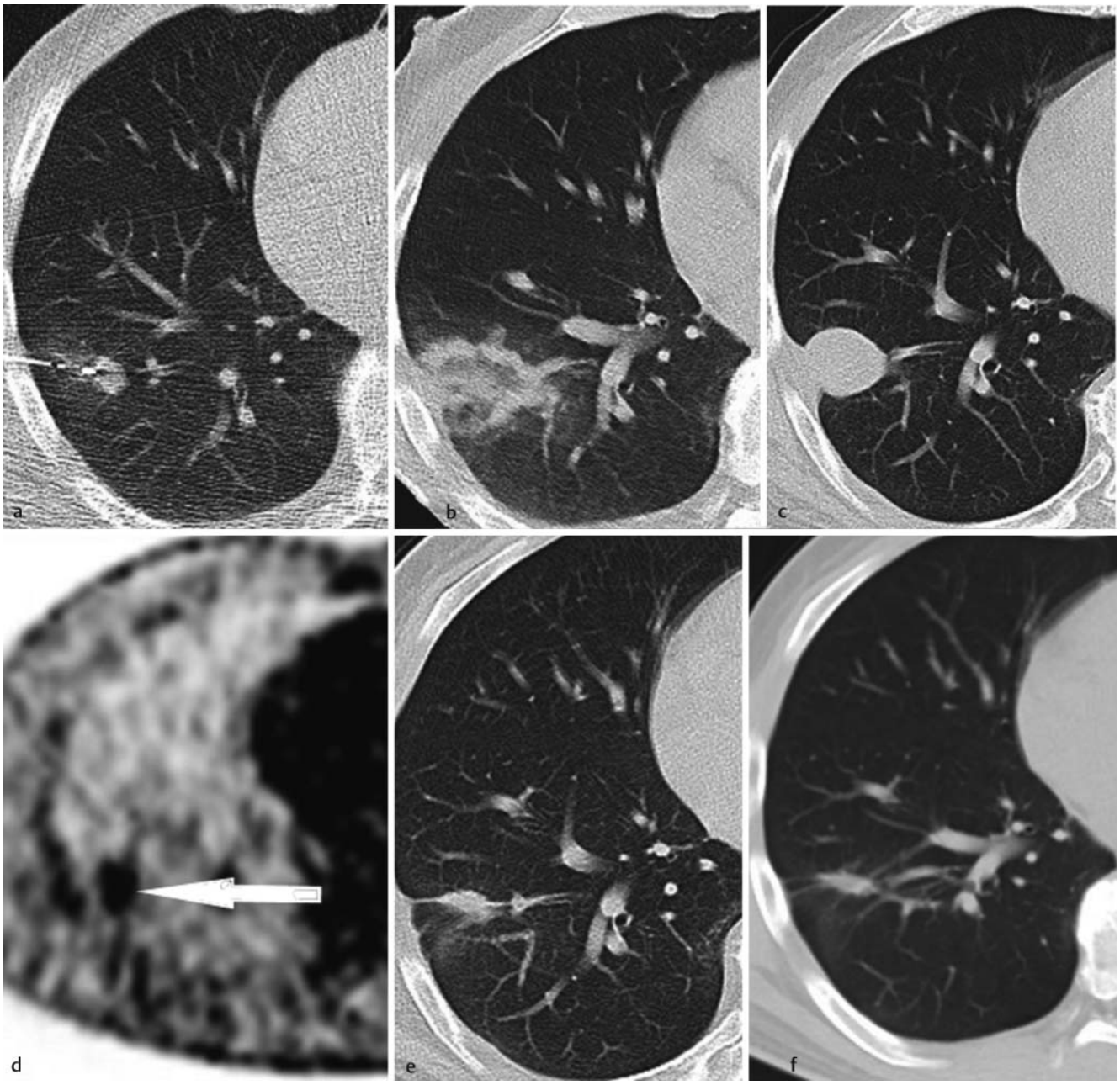

▶ **Fig. 4** High-frequency ablation of a lung metastasis originating from a colorectal carcinoma (6 minutes; 90 W). Aspect of the tumor during **a** and 24 hours after ablation **b**. **c** At 3 months, the tumor has a nodular aspect. **d** On a PET examination performed at 6 months, a hypermetabolic focus in the ablation area is visualized (arrow), but because a concomitant CT showed a decrease in size, no action was taken. The ablation zone continues to shrink until 9 months after ablation **e** and remains constant afterwards. **f** Two years after ablation, a fibrous pattern persists with no signs of local progression.

▶ **Abb. 4** Hochfrequenzablation einer kolorektalen Lungenmetastase (6 Minuten, 90 W). Aspekt des Tumors während **a** und 24 Stunden nach der Ablation **b**. **c** Nach 3 Monaten hatte der Tumor eine rundliche Erscheinung. **d** Bei einer PET-Untersuchung, die nach 6 Monaten durchgeführt wurde, wurde ein hypermetabolischer Fokus im Ablationsbereich detektiert (Pfeil), aber da eine simultane CT eine Größenregredienz zeigte, wurde keine weitere Maßnahme getroffen. Die Ablationszone blieb weiterhin bis 9 Monate nach Ablation größenregredient **e** und danach konstant. **f** Zwei Jahre nach der Ablation blieb ein fibröses Muster bestehen ohne Anzeichen lokaler Progression.

PET/CT

PET/CT is a technique with the potential for improving the early detection of local tumor progression in certain situations. The ^{18}F-FDG-pattern immediately after successful ablation consists in most cases of a high-uptake ring with central photopenia, but diffuse or heterogeneous uptake might also be encountered (▶ **Fig. 5**) [66]. Three months after treatment, 57 – 68 % of the ablation zones will show no or mild ^{18}F-FDG uptake which has a high negative predictive value [67, 68]. In the remaining cases, a

This document was downloaded for personal use only. Unauthorized distribution is strictly prohibited.

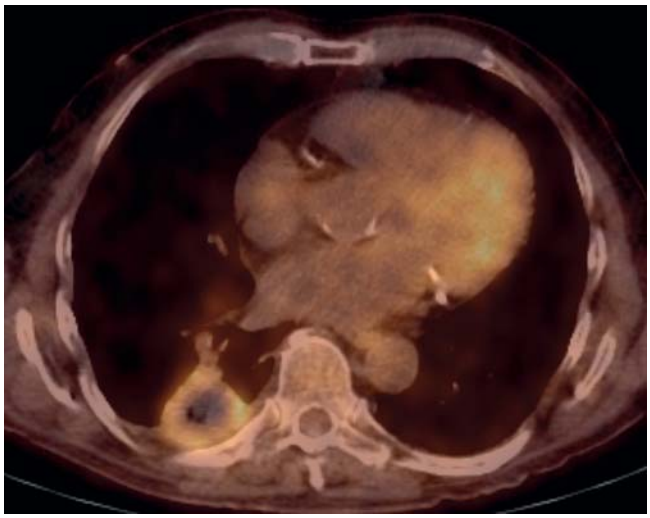

▶ **Fig. 5** PET-CT aspect of the ablation zone 3 months after the treatment with a typical high-uptake ring.

▶ **Abb. 5** T-CT der Ablationszone 3 Monate nach der Behandlung mit typischer ringförmigen Glukoseanreicherung.

moderate to high ^{18}F-FDG uptake might persist. However, this does not indicate progression on follow-up in the majority of cases [68]. As the ablation zone undergoes fibrous transformation and shrinks, the ring-like uptake pattern that can still be present at 6 months will be replaced by a nodular pattern. Therefore, 6 months after treatment, a standardized uptake value (SUV) increase in the center of the ablation zone can appear without having a pathological significance (▶ **Fig. 4**). After 12 months, the activity will usually be decreased [69]. Incomplete ablation should be suspected when a high-uptake focus persists at the location of the tumor prior to ablation [66, 70]. Local progression should be considered when a new high-uptake focus is detected within or at the periphery of the ablation zone after a period of decreased activity. An active region does not necessarily represent tumoral tissue, especially in the first three months after ablation [61, 68, 69]. Additional ablation should be considered by taking more factors into account, such as an increased size of the ablation zone, and the new occurrence of periablational nodularity or contrast enhancement patterns (▶ **Fig. 3**) [61, 69]. In the case of doubt, biopsy of the suspicious focus can be performed [61]. In addition, reactively enlarged mediastinal lymph nodes with increased ^{18}F-FDG uptake are also likely to be encountered within the first months after ablation, but should subside by 12 moths [67, 71].

MRI

The MRI appearance of the ablation zone has been described both on animal models as well as in a clinical setting in the previous decade [72 – 75]. If not affected by artifacts, MRI offers good visualization with the same concentric rings aspect as seen on CT. Okuma et al. have shown that higher apparent diffusion coefficient values of the tumor measured three days after ablation can predict complete ablation, but there are no other studies confirming these findings [75]. MRI offers no clear advantages over CT except for the lack of radiation, and because of its susceptibility to artifacts and higher costs, MRI follow-up has not become part of the clinical routine in most centers.

Follow-up protocol

To date, there is no consensus regarding the ideal follow-up protocol. Most authors employ a succession of enhanced or non-enhanced CT examinations with occasional or regular PET/CT examinations [1, 2, 55, 56, 76]. At our institution, follow-up consists mostly of unenhanced CT scans. The first CT examination is performed the day after ablation, not only to detect complications, but also to evaluate whether the ablation was complete, or an additional ablation of the same tumor may be necessary. The second CT examination is performed three months later with the main purpose of providing a baseline for the subsequent examinations which are performed in 3-month intervals within the first year and at 6-month intervals thereafter. PET/CTs are only employed to confirm unclear cases of local progression.

Safety

Pain and chest wall damage

During the ablation of subpleural tumors, the heat expands into the surrounding tissue which is the cause of chest wall burns. Pain can be encountered after 2 – 27.6 % of MWA ablations (▶ **Table 1**) [1, 3, 8, 12]. Generally, the severity is mild to moderate, and it persists for a few days to a few weeks. Pain related to ablative treatment usually responds well to analgesics, but cases of severe pain lasting up to a few months have also been reported and can be attributed to intercostal neuralgia or pathologic rib fractures [17, 43]. Paramediastinal ablation can damage the phrenic nerves resulting in diaphragmatic paralysis with potential serious impact on vital capacity [77]. The ablation of apical tumors can lead to injury of the cervical plexus resulting in sensory and motor dysfunction [78]. In addition to nerve damage, a small number of rib fractures and skin burns following MWA have also been reported [1, 2, 7, 17]. Alexander et al. have shown that RFA has a significantly higher risk of inducing rib fractures compared to MWA (15.9 % vs. 2.7 %) [7]. The induction of an artificial pneumothorax has been proposed as a safe method of preventing pain and chest wall damage [79].

Pneumothorax

The pneumothorax rates after MWA vary widely, ranging between 8.5 – 63 % and are similar to those reported after RFA, ranging between 11 % and 67 % [1 – 3, 8, 9, 11, 12, 54, 80]. The high variability of the reports is most likely a consequence of the threshold chosen by the authors. The main cause for pneumothorax seems to be associated with the insertion of the antenna and not with the thermal effect of the ablation [81]. Therefore, the ablation of more than one tumor, very large or small tumors, and tumors located deep within the lung parenchyma that require multiple pleural punctures or antenna repositioning is associated with a

This document was downloaded for personal use only. Unauthorized distribution is strictly prohibited.

▶ **Table 1** Complications after MWA.

▶ **Tab. 1** Komplikationen nach MWA.

author, year of publication	patient number (n)	procedure-related deaths (%)	pneumothorax (%)	severe pneumothorax (%)	hemorrhage(H) hemptysis (P) hemothorax (T) (%)	skin burns (B) pain (P) (%)	pneumonia (%)	pleural effusion (%)
Wolf, 2008 [1]	50	1.5	39	12	6 (P)	3 (B) 2 (P)	3	–
Vogl, 2011 [2]	80	0	8.5	0.8	6 (H) 4.6 (P)	0.8 (B) 9 (P)	–	–
Lu, 2012 [3]	69	0	18.8	7.2	7.2 (P) 2.9 (T)	2.9 (P)	–	–
Belfiore, 2013 [8]	56	0	32	14	–	17.8 (P)	–	–
Carrafiello 2013 [9]	24	0	37.5	0	3.8 (P)	–	–	3.8
Wei, 2015 [11]	39	0	30.8	7.7	15.3 (T)	–	18	18
Yang, 2014 [12]	47	0	63.8	13.5	31.9 (P)	27.6 (P)	14.9	34
Zheng, 2014 [13] (major complications)	184	0.5	–	15.7	–	–	0.5 (abscess)	2.9
Han, 2015 [15]	28	0	50	28.5	3.5 (P)	–	3.5	7.1
Ni, 2015 [16]	35	0	20.5	7.7	5.1 (H) 2.6 (P)	23.1 (P)	5.1	15.4
Splatt, 2015 [17] (major complications)	51	1.4	–	12.9	2.9 (H)	1.4 (B)	2.9	5.7
Egashira, 2016 [22]	44	0	–	13	6.9 (H)	–	–	–

H = Hemorrhage; P = Hemoptysis; T = Hemothorax; P = Pain; B = Skin Burns.

This document was downloaded for personal use only. Unauthorized distribution is strictly prohibited.

higher risk of development of a pneumothorax. Tumors located in the lower parts of the lungs (higher mobility), the traversal of lung fissures and lung emphysema, are also associated with an increased pneumothorax risk [13, 54, 81, 82]. In most cases, the pneumothorax is small and does not require additional treatment. Between 0.8 – 15 % of ablations result in a large or progressive pneumothorax that requires placement of a drain [1 – 3, 8, 11 – 13, 17, 22]. The occurrence of a pneumothorax may be particularly problematic if it appears before the definitive placement of the antenna. In this case, a new puncture can be attempted after evacuating the air. The possibility of a delayed or recurrent pneumothorax that may require additional treatment also exists. Therefore, a chest radiography or CT is recommended within 24 hours after ablation, since most pneumothoraces appear within this interval. Although rare, a significant pneumothorax can occur even later. Thus, it is crucial to inform patients and their relatives of this potential complication and the related symptomatology [2, 82, 83].

A broncho-pleural fistula is a complication caused by direct communication between a bronchus and the pleural space. It occurs as a pneumothorax persisting despite the presence of a chest drain. A fistula can become manifest during or shortly after ablation or it can appear in the weeks or months subsequent to the treatment, as the necrotic tissue of a subpleural ablation is evacuated and a new communication is formed. This complication is very rare and the treatment consists of pleurodesis, surgery, bronchoscopic management or a combination of these [13, 17, 54, 84].

Hemorrhage

A hemorrhage can occur by damaging an intrapulmonary or intercostal blood vessel. An intrapulmonary hemorrhage appears as a rapidly expanding GGO starting from the antenna and can be associated with hemoptysis. Intraparenchymal hemorrhages occur in 6 – 10 % of MWAs and lead to hemoptysis in 0 – 7 % of cases [2, 3, 16, 22]. Yang et al. reported a hemoptysis rate as high as 36 % [12]. These rates have been reported to be higher after RFA with 3 – 9 % resulting in hemoptysis and an almost double in hemorrhage [54]. Although the data are insufficient to draw a firm conclusion, the better results might be explained by the lower susceptibility of MWA for the heat sink effect and a stronger coagulative effect. Usually the hemorrhage is self-limiting and no action is needed except to carry on with the ablation which promotes coagulation. If the bleeding continues and is associated with uncontrollable cough, one should react quickly as heavy pulmonary bleeding might be lethal. The patient should be positioned on the side of the ablation and hemostatic agents should be injected. A split intubation might be needed in order to prevent asphyxia. In severe cases, only an embolization or explorative thoracotomy is able to stop the bleeding [54, 76, 85]. Damaging an intercostal vessel may result in a rapidly progressive hemothorax that usually requires endovascular or surgical treatment [54]. The best way to avoid hemorrhagic complications is to reconfirm that the patient has a safe coagulation profile and to choose a puncture pathway that avoids intersecting larger blood vessels, especially in patients with high pulmonary blood pressure [85].

Pleural effusion

Small asymptomatic pleural effusions are common after MWA and usually do not require treatment. They appear more often if the ablation is subpleural and are caused by an inflammatory reaction of the pleura [13, 86]. Large, symptomatic pleural effusions occur after 0 – 7.7 % of treatments and can be managed by insertion of a drain [12, 13, 16, 17, 22].

Infection

Postprocedural pneumonia is relatively common with rates following MWA ranging between 2 – 18 % [1, 11 – 13, 16, 17]. The risk of pneumonia seems to be increased for patients who have previously undergone radiotherapy [87]. Some authors recommend prophylactic antibiosis before and two days after ablation. In our institution, however, therapy is administered only in clinically manifest cases [13]. Lung abscess is another infectious periprocedural complication that can appear in 0.5 – 1.5 % of cases [1, 13]. Patients with cavity formation, but also with emphysema have been reported to have an increased risk for abscess [1, 13, 87]. Both pneumonia and abscess should be regarded as serious complications that can result in procedure-related death [1, 87].

Other complications, such as pulmonary artery aneurysms and systemic air embolisms, have been reported following RFA of lung tumors, but they are exceedingly rare [54].

Indications and outcome

NSCLC

Thermal ablation can be used with a curative intent only in stage I NSCLC, because it cannot address lymph nodes directly and it has a lower chance of success in complete ablation of tumors larger than 3 cm [1, 2]. Given the better local control rates, the treatment of choice for stage I NSCLC is considered to be either open or video-assisted thoracic surgery [88]. However, in the case of patients with early-stage NSCLC and severely impaired lung function, a local ablative therapy (SBRT or RFA) can be considered [89].

Randomized controlled studies comparing radiotherapy (especially SBRT) to thermal ablation therapies are currently not available and most of the data regarding these techniques consist of retrospective case series with low levels of evidence. A recent systematic review and pooled analysis by Bi et al. compared the results of RFA (328 patients) and SBRT (2767 patients) in the treatment of stage I NSCLC [90]. The authors showed that the local control rates were significantly superior for SBRT compared to RFA (1 year: 97 % vs. 77 %, 2 years: 92 % vs. 48 %, 3 years: 88 % vs. 55 %, 5 years: 86 % vs. 42 %) even after correcting for tumor size < 3 cm and age [90]. In 2015, Dupuy et al. published the results of the American College of Surgeons Oncology Group

This document was downloaded for personal use only. Unauthorized distribution is strictly prohibited.

Z4033 (Alliance) Trial which showed similar local control rates after RFA of stage IA NSCLC of 68.9 % at 1 year and 59.8 % at 2 years and overall survival (OS) rates of 86.3 % at 1 year and 69.8 % at 2 years [91]. Despite the lower local control rates for RFA compared to SBRT, there is no evidence for an increase in the OS in either group as shown by the aforementioned pooled analysis: The 1-, 2-, 3-, and 5-year OS rates for RFA were 85 %, 67 %, 53 % and 32 %, respectively, whereas the OS rates for SBRT were 85 %, 68 %, 56 % and 40 %, respectively [90]. These results can be explained by the overall poor condition of these patients and by the possibility of a second ablation in the case of local progression [91]. Likewise, based on an analysis of the Surveillance, Epidemiology, and End Results (SEER)/Medicare database (USA), Kwan et al. have shown that RFA has a lower OS compared to sublobar resection of early-stage NSCLC in elderly patients, although this difference in OS was not significant when matched for demographic and clinical characteristics [92].

The ability of MWA to create larger, more spherical ablation zones, as well as the lower susceptibility to the heat sink effect should theoretically lead to lower local progression rates (LPR). However, the patient series involving MWA treatment of stage I NSCLC show similar outcomes with RFA. Liu et al. reported an LPR of 31 % (median follow-up of 12 months) while Yang et al. reported an LPR of 27.7 % (median follow-up 30 months), local control rates at 1, 3 and 5 years of 96 %, 64 % and 48 %, respectively, and OS rates at 1, 2 and 3 years of 89 %, 63 % and 43 %, respectively [10, 12]. Similarly, Han et al. reported an LPR of 32 % (median follow-up 22 months) with local control rates at 1, 2 and 3 years of 80.5 %, 74.8 % and 22.1 %, respectively, and cancer-specific survival rates at 1, 2 and 3 years of 95 %, 74 % and 65 %, respectively, (▶ **Table 2**) [15]. The other case series involving MWA of NSCLC were either pooled together with metastases or involved locally advanced or metastatic NSCLC.

In the case of local progression after radiotherapy, reirradiation has limited effectiveness in extending survival [93]. RFA and MWA have been shown to prolong local tumor control and to alleviate symptomatology in patients with local progression within the radiation field and therefore, if available, should be recommended as a salvage therapy [21, 93, 94].

The currently accepted treatment for inoperable stage III and IV NSCLC consists of radiochemotherapy, but studies have suggested that these patients might benefit from thermal ablation techniques. A randomized prospective study by Xu et al. compared the effectiveness of MWA vs. RT of the primary tumor in patients with inoperable stage III NSCLC combined with chemotherapy and RT of the lymph nodes. They reported lower radiation pneumonitis rates (3.9 % vs. 31.9 %) and a lower incidence of progressive disease in the MWA group (0 % vs. 17 %) [20]. Wei et al. compared the effectiveness of MWA and chemotherapy to chemotherapy alone and concluded that the MWA group had a prolonged progression-free survival compared to the chemotherapy-only group (10.9 months vs. 4.8 months) [19]. Both studies showed a tendency towards an improved OS that was, however, not statistically significant.

It has been shown that tissue heating increases the penetration and retention of drugs co-administered at the time of ablation [95, 96]. The heat also has an immunomodulatory effect by releasing intact antigens that can trigger an antitumor immune response [97, 98]. Therefore, the size of the ablation zone can be enhanced by the concomitant local application of cytotoxic drugs [95, 99]. In a recent randomized study, Zhao et al. compared the intratumoral administration of 131I-labeled mouse/human chimeric monoclonal antibodies against intracellular DNA combined with MWA to postoperative adjuvant chemoradiation of stage II and III NSCLC. They found that the 1- and 2-year survival rates of the MWA group were significantly better than those of the chemoradiation group [96]. The synergic effects of cytotoxic drugs seem to be a promising approach to improve the results of lung thermal ablations, but more studies are required to prove their utility in the clinical routine.

In brief, the survival rates of patients suffering from inoperable early stage NSCLC treated with RFA or MWA do not show any significant difference compared to SBRT though the local control rates seem to be inferior. Therefore, whenever available, both techniques should be discussed with the patient while highlighting their advantages and disadvantages. The thermal ablation techniques can also be effectively employed as a salvage therapy after unsuccessful RT and as a means of prolonging local tumor control in stage III and IV NSCLC. Currently there is no evidence that MWA is superior to RFA regarding local tumor control and overall survival.

Metastases

Although the treatment concept of metastatic disease is usually palliative, patients with a controlled primary tumor and a limited number of metastases can be treated with a curative intent. When the metastases are completely resected, 20 – 50 % of patients may reach long-time survival [100]. In the case of medically inoperable metastases originating from a colorectal carcinoma, either SBRT or thermal ablation is recommended by the guidelines of the European Society of Medical Oncology [101]. The largest and most recent pooled analysis by the working group Stereotactic Radiotherapy of the German Society for Radiation Oncology analyzed the outcomes of 700 patients with lung oligometastic disease treated with SBRT. They reported a 2-year local control rate of 81.2 % and an OS rate of 54.4 % (median follow-up of 14.3 months) for up to 2 metastases treated per patient [102]. Similar outcomes were observed in a systematic review analyzing 8 studies with a total of 903 patients with lung metastases of colorectal origin treated with thermal ablation. The local progression rates were between 7 % and 21 % and the 1, 3 and 5-year survival rates ranged between 84 – 95 %, 35 – 72 % and 20 – 54 %, respectively [103]. In a series of 566 patients with 1037 lung metastases treated with RFA with a median follow-up of 35.5 months, De Baere et al. obtained 1-, 3-, and 5-year OS rates of 92 %, 67 % and 51.5 %, respectively, with an LTP rate per patient of 18.1 %. They ablated up to 4 metastases/patient with an average of 1.83 treatments/patient [80]. As prior research has suggested, thermal ablation techniques have very similar results with SBRT and there is no definitive proof for the superiority of one technique over the other. Accordingly, the latest ESMO colorectal carcinoma guideline recommends that the treatment of oligometastatic disease should be chosen from a "toolbox" of procedures including ther-

This document was downloaded for personal use only. Unauthorized distribution is strictly prohibited.

▶ **Table 2** Currently available studies investigating MWA of lung tumors with a curative intent.

▶ **Tab. 2** Derzeit verfügbare Studien bezüglich MWA von Lungentumoren mit kurativer Indikationsstellung.

author, year of publication	patient number (n)	pathology (number of ablated lesions)	follow-up (months)	LTP (%)	overall survival (OS) (%) cancer-specific survival (CSS) (%)				
					1 year	2 years	3 years	4 years	5 years
Wolf, 2008 [1]	50	NSCLC: 27 SCLC: 3 Met: 20	Mean: 10	26	OS: 65 CSS: 83	55 73	45 61		
Vogl, 2011 [2]	80	Met: 130	Mean: 9	27	OS: 91	75			
Lu, 2012 [3]	69	NSCLC (I-IV): 56 Met: 37	Median: 18	16	OS NSCLC: 75 OS Met: 47	54 24	29 14		
Belfiore, 2013 [8]	56	NSCLC: 44 Met: 25	N/A	0	CSS: 69	54	49		
Carrafiello 2014 [9]	24	NSCLC (I-IV): 14 Met: 11 Microcytoma: 1	Mean: 9.9	23	OS: 75	55			
Liu, 2013 [10]	15	NSCLC (I): 15	Median: 12	31					
Yang, 2014 [12]	47	NSCLC (I): 47	Median: 30	27	OS: 89	63	43		16
Han, 2015 [15]	28	NSCLC (I+ IIA): 28	Median: 22	32	OS: 80.5 CSS: 95	74 74	22 65	22 65	
Sun, 2015 [18]	29	NSCLC (I-IV): 15 Met: 14	Median: 25	34	OS: 91	86			
Egashira, 2016 [22]	44	Met: 87	Median: 15	2					

LTP = Local Tumor Progression; OS = Overall Survival; CSS = Cancer-Specific Survival; NSCLC = Non-Small Cell Lung Cancer; Met = Metastases.

This document was downloaded for personal use only. Unauthorized distribution is strictly prohibited.

mal ablation therapies, SBRT and to a lesser extent chemoembolization, while taking the patients preference, the size and location of the metastases, technique invasiveness, local experience and other patient-related factors into account [101].

Thermal ablation has been shown not to affect respiratory function in any way which might be an advantage over SBRT in patients with severely limited lung function, especially when the treatment of multiple lung metastases is planned [51, 91]. As an example, Crombe et al. reported a patient who underwent RFA of 23 lung metastases over a period of 10 years without loss of respiratory function [104].

Reports concerning MWA of lung metastases are still scarce and some are combined with series of NSCLC. Vogl et al. reported a local progression rate of 26.9 % (mean follow-up of 10 months) in a series of 130 ablated lung metastases. The 1- and 2-year OS rates were 91.3 % and 75 %, respectively [2]. Lu et al. reported much worse 1-, 2-, and 3-year OS rates after the ablation of 37 lung metastases: 47.6 %, 23.8 %, and 14.3 %, respectively [3]. Finally, Egashira et al. reported an LTP of only 2.3 % after the ablation of 87 lung metastases with a median follow-up of 15 months [22]. The small number of studies concerning lung metastases as well as the high variability of the reported results and methods do not allow a satisfactory comparison of MWA to the previously discussed techniques (▶ **Table 2**).

Conclusion

MWA is a relatively new thermal ablation technique with increasing use in the treatment of inoperable lung tumors. MWA has similar complication rates with RFA and, therefore, can be regarded as a safe technique. Initial experimental animal models have shown clear advantages of MWA over RFA. MWA creates larger, more spherical and less time-consuming ablation zones and is less susceptible to the heat sink effect. However, the relatively few and heterogeneous studies concerning MWA do not provide sufficient evidence to indicate any advantage in local control or overall survival compared to RFA. A larger body of evidence including randomized controlled trials is necessary to prove if the technical advantages of MWA translate into improved clinical outcomes compared to RFA.

CLINICAL RELEVANCE OF THE STUDY

- Thermal ablation and SBRT are currently the main curative treatment options for medically inoperable lung tumors.
- Despite a slightly lower local control rate for thermal ablation, there is no evidence for a difference in survival rates between thermal ablation and SBRT.
- MWA has some theoretical advantages over RFA, but the complications and clinical outcomes are similar.

Conflict of Interest

The authors declare that they have no conflict of interest.

References

[1] Wolf FJ, Grand DJ, Machan JT et al. Microwave Ablation of Lung Malignancies: Effectiveness, CT Findings, and Safety in 50 Patients. Radiology 2008; 247: 871 – 879

[2] Vogl TJ, Naguib NN, Gruber-Rouh T et al. Microwave ablation therapy: clinical utility in treatment of pulmonary metastases. Radiology 2011; 261: 643 – 651

[3] Lu Q, Cao W, Huang L et al. CT-guided percutaneous microwave ablation of pulmonary malignancies: Results in 69 cases. World journal of surgical oncology 2012; 10: 80

[4] Carrafiello G, Mangini M, Fontana F et al. Complications of microwave and radiofrequency lung ablation: personal experience and review of the literature. La Radiologia medica 2012; 117: 201 – 213

[5] Wolf FJ, Aswad B, Ng T et al. Intraoperative microwave ablation of pulmonary malignancies with tumor permittivity feedback control: ablation and resection study in 10 consecutive patients. Radiology 2012; 262: 353 – 360

[6] Vogl TJ, Worst TS, Naguib NN et al. Factors influencing local tumor control in patients with neoplastic pulmonary nodules treated with microwave ablation: a risk-factor analysis. American journal of roentgenology 2013; 200: 665 – 672

[7] Alexander ES, Hankins CA, Machan JT et al. Rib fractures after percutaneous radiofrequency and microwave ablation of lung tumors: incidence and relevance. Radiology 2013; 266: 971 – 978

[8] Belfiore G, Ronza F, Belfiore MP et al. Patients' survival in lung malignancies treated by microwave ablation: our experience on 56 patients. European journal of radiology 2013; 82: 177 – 181

[9] Carrafiello G, Mangini M, Fontana F et al. Microwave ablation of lung tumours: single-centre preliminary experience. La Radiologia medica 2014; 119: 75 – 82

[10] Liu H, Steinke K. High-powered percutaneous microwave ablation of stage I medically inoperable non-small cell lung cancer: a preliminary study. Journal of medical imaging and radiation oncology 2013; 57: 466 – 474

[11] Wei Z, Ye X, Yang X et al. Microwave ablation in combination with chemotherapy for the treatment of advanced non-small cell lung cancer. Cardiovascular and interventional radiology 2015; 38: 135 – 142

[12] Yang X, Ye X, Zheng A et al. Percutaneous microwave ablation of stage I medically inoperable non-small cell lung cancer: clinical evaluation of 47 cases. Journal of surgical oncology 2014; 110: 758 – 763

[13] Zheng A, Wang X, Yang X et al. Major complications after lung microwave ablation: a single-center experience on 204 sessions. The Annals of thoracic surgery 2014; 98: 243 – 248

[14] Acksteiner C, Steinke K. Percutaneous microwave ablation for early-stage non-small cell lung cancer (NSCLC) in the elderly: a promising outlook. Journal of medical imaging and radiation oncology 2015; 59: 82 – 90

[15] Han X, Yang X, Ye X et al. Computed tomography-guided percutaneous microwave ablation of patients 75 years of age and older with early-stage nonsmall cell lung cancer. Indian journal of cancer 2015; 52 (Suppl. 2): e56 – e60

[16] Ni X, Han JQ, Ye X et al. Percutaneous CT-guided microwave ablation as maintenance after first-line treatment for patients with advanced NSCLC. OncoTargets and therapy 2015; 8: 3227 – 3235

[17] Splatt AM, Steinke K. Major complications of high-energy microwave ablation for percutaneous CT-guided treatment of lung malignancies: Single-centre experience after 4 years. Journal of medical imaging and radiation oncology 2015; 59: 609 – 616

[18] Sun YH, Song PY, Guo Y et al. Computed tomography-guided percutaneous microwave ablation therapy for lung cancer. Genetics and molecular research: GMR 2015; 14: 4858 – 4864

This document was downloaded for personal use only. Unauthorized distribution is strictly prohibited.

[19] Wei Z, Ye X, Yang X et al. Microwave ablation plus chemotherapy improved progression-free survival of advanced non-small cell lung cancer compared to chemotherapy alone. Medical oncology (Northwood, London, England) 2015; 32: 464

[20] Xu X, Ye X, Liu G et al. Targeted percutaneous microwave ablation at the pulmonary lesion combined with mediastinal radiotherapy with or without concurrent chemotherapy in locally advanced non-small cell lung cancer evaluation in a randomized comparison study. Medical oncology (Northwood, London, England) 2015; 32: 227

[21] Cheng M, Fay M, Steinke K. Percutaneous CT-guided thermal ablation as salvage therapy for recurrent non-small cell lung cancer after external beam radiotherapy: A retrospective study. International journal of hyperthermia: the official journal of European Society for Hyperthermic Oncology, North American Hyperthermia Group 2016; 32: 316 – 323

[22] Egashira Y, Singh S, Bandula S et al. Percutaneous High-Energy Microwave Ablation for the Treatment of Pulmonary Tumors: A Retrospective Single-Center Experience. Journal of vascular and interventional radiology: JVIR 2016; 27: 474 – 479

[23] Lubner MG, Brace CL, Hinshaw JL et al. Microwave tumor ablation: mechanism of action, clinical results, and devices. Journal of vascular and interventional radiology: JVIR 2010; 21: S192 – S203

[24] Ward RC, Healey TT, Dupuy DE. Microwave ablation devices for interventional oncology. Expert review of medical devices 2013; 10: 225 – 238

[25] Simo KA, Tsirline VB, Sindram D et al. Microwave ablation using 915-MHz and 2.45-GHz systems: what are the differences? HPB: the official journal of the International Hepato Pancreato Biliary Association 2013; 15: 991 – 996

[26] Goldberg SN. Radiofrequency tumor ablation: principles and techniques. European journal of ultrasound: official journal of the European Federation of Societies for Ultrasound in Medicine and Biology 2001; 13: 129 – 147

[27] Vogl TJ, Naguib NN, Lehnert T et al. Radiofrequency, microwave and laser ablation of pulmonary neoplasms: clinical studies and technical considerations–review article. European journal of radiology 2011; 77: 346 – 357

[28] Hinshaw JL, Lubner MG, Ziemlewicz TJ et al. Percutaneous tumor ablation tools: microwave, radiofrequency, or cryoablation–what should you use and why? Radiographics: a review publication of the Radiological Society of North America, Inc 2014; 34: 1344 – 1362

[29] Koizumi T, Tsushima K, Tanabe T et al. Bronchoscopy-Guided Cooled Radiofrequency Ablation as a Novel Intervention Therapy for Peripheral Lung Cancer. Respiration; international review of thoracic diseases 2015; 90: 47 – 55

[30] Alexander ES, Dupuy DE. Lung cancer ablation: technologies and techniques. Seminars in interventional radiology 2013; 30: 141 – 150

[31] McDevitt JL, Mouli SK, Nemcek AA et al. Percutaneous Cryoablation for the Treatment of Primary and Metastatic Lung Tumors: Identification of Risk Factors for Recurrence and Major Complications. Journal of vascular and interventional radiology: JVIR 2016; 27: 1371 – 1379

[32] Savic LJ, Chapiro J, Hamm B et al. Irreversible Electroporation in Interventional Oncology: Where We Stand and Where We Go. RoFo: Fortschritte auf dem Gebiete der Rontgenstrahlen und der Nuklearmedizin 2016; 188: 735 – 745

[33] Brace CL, Hinshaw JL, Laeseke PF et al. Pulmonary thermal ablation: comparison of radiofrequency and microwave devices by using gross pathologic and CT findings in a swine model. Radiology 2009; 251: 705 – 711

[34] Andreano A, Huang Y, Meloni MF et al. Microwaves create larger ablations than radiofrequency when controlled for power in ex vivo tissue. Medical physics 2010; 37: 2967 – 2973

[35] Steinke K, Haghighi KS, Wulf S et al. Effect of vessel diameter on the creation of ovine lung radiofrequency lesions in vivo: preliminary results. The Journal of surgical research 2005; 124: 85 – 91

[36] Gillams AR, Lees WR. Radiofrequency ablation of lung metastases: factors influencing success. European radiology 2008; 18: 672 – 677

[37] Planche O, Teriitehau C, Boudabous S et al. In vivo evaluation of lung microwave ablation in a porcine tumor mimic model. Cardiovascular and interventional radiology 2013; 36: 221 – 228

[38] Crocetti L, Bozzi E, Faviana P et al. Thermal ablation of lung tissue: in vivo experimental comparison of microwave and radiofrequency. Cardiovascular and interventional radiology 2010; 33: 818 – 827

[39] Alonzo M, Bos A, Bennett S et al. The Emprint Ablation System with Thermosphere Technology: One of the Newer Next-Generation Microwave Ablation Technologies. Seminars in interventional radiology 2015; 32: 335 – 338

[40] Hoffmann R, Rempp H, Erhard L et al. Comparison of four microwave ablation devices: an experimental study in ex vivo bovine liver. Radiology 2013; 268: 89 – 97

[41] Patel IJ, Davidson JC, Nikolic B et al. Consensus guidelines for periprocedural management of coagulation status and hemostasis risk in percutaneous image-guided interventions. Journal of vascular and interventional radiology: JVIR 2012; 23: 727 – 736

[42] Hoffmann RT, Jakobs TF, Lubienski A et al. Percutaneous radiofrequency ablation of pulmonary tumors–is there a difference between treatment under general anaesthesia and under conscious sedation? European journal of radiology 2006; 59: 168 – 174

[43] Smith SL, Jennings PE. Lung radiofrequency and microwave ablation: a review of indications, techniques and post-procedural imaging appearances. Br J Radiol 2015; 88: DOI: 20140598

[44] Lal H, Neyaz Z, Nath A et al. CT-Guided Percutaneous Biopsy of Intrathoracic Lesions. Korean Journal of Radiology 2012; 13: 210 – 226

[45] Swischuk JL, Castaneda F, Patel JC et al. Percutaneous transthoracic needle biopsy of the lung: review of 612 lesions. Journal of vascular and interventional radiology: JVIR 1998; 9: 347 – 352

[46] Charig MJ, Phillips AJ. CT-guided cutting needle biopsy of lung lesions–safety and efficacy of an out-patient service. Clinical radiology 2000; 55: 964 – 969

[47] Kazerooni EA, Lim FT, Mikhail A et al. Risk of pneumothorax in CT-guided transthoracic needle aspiration biopsy of the lung. Radiology 1996; 198: 371 – 375

[48] Kim Y-s, Lee WJ, Rhim H et al. The Minimal Ablative Margin of Radiofrequency Ablation of Hepatocellular Carcinoma (> 2 and < 5 cm) Needed to Prevent Local Tumor Progression: 3D Quantitative Assessment Using CT Image Fusion. American Journal of Roentgenology 2010; 195: 758 – 765

[49] Wang X, Sofocleous CT, Erinjeri JP et al. Margin size is an independent predictor of local tumor progression after ablation of colon cancer liver metastases. Cardiovascular and interventional radiology 2013; 36: 166 – 175

[50] Anderson EM, Lees WR, Gillams AR. Early indicators of treatment success after percutaneous radiofrequency of pulmonary tumors. Cardiovascular and interventional radiology 2009; 32: 478 – 483

[51] de Baere T, Palussiere J, Auperin A et al. Midterm local efficacy and survival after radiofrequency ablation of lung tumors with minimum follow-up of 1 year: prospective evaluation. Radiology 2006; 240: 587 – 596

[52] Giraud P, Antoine M, Larrouy A et al. Evaluation of microscopic tumor extension in non-small-cell lung cancer for three-dimensional conformal radiotherapy planning. International journal of radiation oncology, biology, physics 2000; 48: 1015 – 1024

[53] Hiraki T, Mimura H, Gobara H et al. Two cases of needle-tract seeding after percutaneous radiofrequency ablation for lung cancer. Journal of vascular and interventional radiology: JVIR 2009; 20: 415 – 418

This document was downloaded for personal use only. Unauthorized distribution is strictly prohibited.

[54] Hiraki T, Gobara H, Fujiwara H et al. Lung cancer ablation: complications. Seminars in interventional radiology 2013; 30: 169 – 175

[55] Abtin FG, Eradat J, Gutierrez AJ et al. Radiofrequency ablation of lung tumors: imaging features of the postablation zone. Radiographics 2012; 32: 947 – 969

[56] Chheang S, Abtin F, Guteirrez A et al. Imaging Features following Thermal Ablation of Lung Malignancies. Seminars in interventional radiology 2013; 30: 157 – 168

[57] Palussiere J, Marcet B, Descat E et al. Lung tumors treated with percutaneous radiofrequency ablation: computed tomography imaging follow-up. Cardiovasc Intervent Radiol 2011; 34: 989 – 997

[58] Yamamoto A, Nakamura K, Matsuoka T et al. Radiofrequency ablation in a porcine lung model: correlation between CT and histopathologic findings. American journal of roentgenology 2005; 185: 1299 – 1306

[59] Miao Y, Ni Y, Bosmans H et al. Radiofrequency ablation for eradication of pulmonary tumor in rabbits. The Journal of surgical research 2001; 99: 265 – 271

[60] Goldberg SN, Grassi CJ, Cardella JF et al. Image-guided tumor ablation: standardization of terminology and reporting criteria. Journal of vascular and interventional radiology: JVIR 2009; 20: S377 – S390

[61] Zaheer SN, Whitley JM, Thomas PA et al. Would you bet on PET? Evaluation of the significance of positive PET scan results post-microwave ablation for non-small cell lung cancer. Journal of medical imaging and radiation oncology 2015; 59: 702 – 712

[62] Steinke K, Glenn D, King J et al. Percutaneous imaging-guided radiofrequency ablation in patients with colorectal pulmonary metastases: 1-year follow-up. Annals of surgical oncology 2004; 11: 207 – 212

[63] Bojarski JD, Dupuy DE, Mayo-Smith WW. CT imaging findings of pulmonary neoplasms after treatment with radiofrequency ablation: results in 32 tumors. American journal of roentgenology 2005; 185: 466 – 471

[64] Nour-Eldin NE, Naguib NN, Tawfik AM et al. CT volumetric assessment of pulmonary neoplasms after radiofrequency ablation: when to consider a second intervention? Journal of vascular and interventional radiology: JVIR 2014; 25: 347 – 354

[65] Suh RD, Wallace AB, Sheehan RE et al. Unresectable pulmonary malignancies: CT-guided percutaneous radiofrequency ablation–preliminary results. Radiology 2003; 229: 821 – 829

[66] Singnurkar A, Solomon SB, Gonen M et al. 18F-FDG PET/CT for the prediction and detection of local recurrence after radiofrequency ablation of malignant lung lesions. Journal of nuclear medicine: official publication, Society of Nuclear Medicine 2010; 51: 1833 – 1840

[67] Deandreis D, Leboulleux S, Dromain C et al. Role of FDG PET/CT and chest CT in the follow-up of lung lesions treated with radiofrequency ablation. Radiology 2011; 258: 270 – 276

[68] Bonichon F, Palussiere J, Godbert Y et al. Diagnostic accuracy of 18F-FDG PET/CT for assessing response to radiofrequency ablation treatment in lung metastases: a multicentre prospective study. European journal of nuclear medicine and molecular imaging 2013; 40: 1817 – 1827

[69] Sharma A, Lanuti M, He W et al. Increase in fluorodeoxyglucose positron emission tomography activity following complete radiofrequency ablation of lung tumors. Journal of computer assisted tomography 2013; 37: 9 – 14

[70] Suzawa N, Yamakado K, Takao M et al. Detection of local tumor progression by (18)F-FDG PET/CT following lung radiofrequency ablation: PET versus CT. Clinical nuclear medicine 2013; 38: e166 – e170

[71] Sharma A, Digumarthy SR, Kalra MK et al. Reversible locoregional lymph node enlargement after radiofrequency ablation of lung tumors. American journal of roentgenology 2010; 194: 1250 – 1256

[72] Tsuda M, Rikimaru H, Majima K et al. Time-related changes of radiofrequency ablation lesion in the normal rabbit liver: findings of magnetic resonance imaging and histopathology. Investigative radiology 2003; 38: 525 – 531

[73] Oyama Y, Nakamura K, Matsuoka T et al. Radiofrequency ablated lesion in the normal porcine lung: long-term follow-up with MRI and pathology. Cardiovascular and interventional radiology 2005; 28: 346 – 353

[74] Gadaleta C, Mattioli V, Colucci G et al. Radiofrequency ablation of 40 lung neoplasms: preliminary results. American journal of roentgenology 2004; 183: 361 – 368

[75] Okuma T, Matsuoka T, Yamamoto A et al. Assessment of early treatment response after CT-guided radiofrequency ablation of unresectable lung tumours by diffusion-weighted MRI: a pilot study. The British journal of radiology 2009; 82: 989 – 994

[76] Liu BD, Zhi XY. Expert consensus on image-guided radiofrequency ablation of pulmonary tumors-2015 edition. Translational lung cancer research 2015; 4: 310 – 321

[77] Matsui Y, Hiraki T, Gobara H et al. Phrenic nerve injury after radiofrequency ablation of lung tumors: retrospective evaluation of the incidence and risk factors. Journal of vascular and interventional radiology: JVIR 2012; 23: 780 – 785

[78] Hiraki T, Gobara H, Mimura H et al. Brachial nerve injury caused by percutaneous radiofrequency ablation of apical lung cancer: a report of four cases. Journal of vascular and interventional radiology: JVIR 2010; 21: 1129 – 1133

[79] Yang X, Zhang K, Ye X et al. Artificial pneumothorax for pain relief during microwave ablation of subpleural lung tumors. Indian journal of cancer 2015; 52 (Suppl. 2): e80 – e83

[80] de Baere T, Auperin A, Deschamps F et al. Radiofrequency ablation is a valid treatment option for lung metastases: experience in 566 patients with 1037 metastases. Annals of oncology: official journal of the European Society for Medical Oncology / ESMO 2015; 26: 987 – 991

[81] Hiraki T, Tajiri N, Mimura H et al. Pneumothorax, pleural effusion, and chest tube placement after radiofrequency ablation of lung tumors: incidence and risk factors. Radiology 2006; 241: 275 – 283

[82] Nour-Eldin NE, Naguib NN, Saeed AS et al. Risk factors involved in the development of pneumothorax during radiofrequency ablation of lung neoplasms. American journal of roentgenology 2009; 193: W43 – W48

[83] Yoshimatsu R, Yamagami T, Terayama K et al. Delayed and recurrent pneumothorax after radiofrequency ablation of lung tumors. Chest 2009; 135: 1002 – 1009

[84] Zheng A, Yang X, Ye X et al. Bronchopleural fistula after lung ablation: Experience in two cases and literature review. Indian journal of cancer 2015; 52 (Suppl. 2): e41 – e46

[85] Nour-Eldin NE, Naguib NN, Mack M et al. Pulmonary hemorrhage complicating radiofrequency ablation, from mild hemoptysis to life-threatening pattern. European radiology 2011; 21: 197 – 204

[86] Tajiri N, Hiraki T, Mimura H et al. Measurement of pleural temperature during radiofrequency ablation of lung tumors to investigate its relationship to occurrence of pneumothorax or pleural effusion. Cardiovascular and interventional radiology 2008; 31: 581 – 586

[87] Kashima M, Yamakado K, Takaki H et al. Complications after 1000 lung radiofrequency ablation sessions in 420 patients: a single center's experiences. American journal of roentgenology 2011; 197: W576 – W580

[88] Vansteenkiste J, De Ruysscher D, Eberhardt WE et al. Early and locally advanced non-small-cell lung cancer (NSCLC): ESMO Clinical Practice Guidelines for diagnosis, treatment and follow-up. Annals of oncology: official journal of the European Society for Medical Oncology / ESMO 2013; 24 (Suppl. 6): vi89 – vi98

[89] Vansteenkiste J, Crino L, Dooms C et al. 2nd ESMO Consensus Conference on Lung Cancer: early-stage non-small-cell lung cancer consensus on diagnosis, treatment and follow-up. Annals of oncology: official journal of the European Society for Medical Oncology / ESMO 2014; 25: 1462 – 1474

[90] Bi N, Shedden K, Zheng X et al. Comparison of the Effectiveness of Radiofrequency Ablation With Stereotactic Body Radiation Therapy in

This document was downloaded for personal use only. Unauthorized distribution is strictly prohibited.

Inoperable Stage I Non-Small Cell Lung Cancer: A Systemic Review and Pooled Analysis. International journal of radiation oncology, biology, physics 2016; 95: 1378 – 1390

[91] Dupuy DE, Fernando HC, Hillman S et al. Radiofrequency ablation of stage IA non-small cell lung cancer in medically inoperable patients: Results from the American College of Surgeons Oncology Group Z4033 (Alliance) trial. Cancer 2015; 121: 3491 – 3498

[92] Kwan SW, Mortell KE, Talenfeld AD et al. Thermal ablation matches sublobar resection outcomes in older patients with early-stage non-small cell lung cancer. Journal of vascular and interventional radiology: JVIR 2014; 25: 1 – 9.e1

[93] Leung VA, DiPetrillo TA, Dupuy DE. Image-guided tumor ablation for the treatment of recurrent non-small cell lung cancer within the radiation field. European journal of radiology 2011; 80: e491 – e499

[94] Schoellnast H, Deodhar A, Hsu M et al. Recurrent non-small cell lung cancer: evaluation of CT-guided radiofrequency ablation as salvage therapy. Acta radiologica (Stockholm, Sweden: 1987) 2012; 53: 893 – 899

[95] Ahmed M, Moussa M, Goldberg SN. Synergy in cancer treatment between liposomal chemotherapeutics and thermal ablation. Chemistry and physics of lipids 2012; 165: 424 – 437

[96] Zhao Z, Su Z, Zhang W et al. A randomized study comparing the effectiveness of microwave ablation radioimmunotherapy and postoperative adjuvant chemoradiation in the treatment of non-small cell lung cancer. Journal of BUON: official journal of the Balkan Union of Oncology 2016; 21: 326 – 332

[97] Bastianpillai C, Petrides N, Shah T et al. Harnessing the immunomodulatory effect of thermal and non-thermal ablative therapies for cancer treatment. Tumour biology: the journal of the International Society for Oncodevelopmental Biology and Medicine 2015; 36: 9137 – 9146

[98] Adkins I, Fucikova J, Garg AD et al. Physical modalities inducing immunogenic tumor cell death for cancer immunotherapy. Oncoimmunology 2014; 3: DOI: e968434

[99] Chen DS, Mellman I. Oncology meets immunology: the cancer-immunity cycle. Immunity 2013; 39: 1 – 10

[100] Weiser MR, Jarnagin WR, Saltz LB. Colorectal cancer patients with oligometastatic liver disease: what is the optimal approach? Oncology (Williston Park, NY) 2013; 27: 1074 – 1078

[101] Van Cutsem E, Cervantes A, Adam R et al. ESMO consensus guidelines for the management of patients with metastatic colorectal cancer. Annals of oncology: official journal of the European Society for Medical Oncology / ESMO 2016; 27: 1386 – 1422

[102] Rieber J, Streblow J, Uhlmann L et al. Stereotactic body radiotherapy (SBRT) for medically inoperable lung metastases-A pooled analysis of the German working group "stereotactic radiotherapy". Lung cancer (Amsterdam, Netherlands) 2016; 97: 51 – 58

[103] Lyons NJ, Pathak S, Daniels IR et al. Percutaneous management of pulmonary metastases arising from colorectal cancer; a systematic review. European journal of surgical oncology: the journal of the European Society of Surgical Oncology and the British Association of Surgical Oncology 2015; 41: 1447 – 1455

[104] Crombe A, Buy X, Godbert Y et al. 23 Lung Metastases Treated by Radiofrequency Ablation Over 10 Years in a Single Patient: Successful Oncological Outcome of a Metastatic Cancer Without Altered Respiratory Function. Cardiovascular and interventional radiology 2016. DOI: 10.1007/s0027001614458

This document was downloaded for personal use only. Unauthorized distribution is strictly prohibited.