

Correction of Pelvic Tilt and Pelvic Rotation in Cup Measurement after THA – An Experimental Study

Korrektur der Beckenverkipfung und der Beckenverdrehung bei der Pfannenmessung nach Hüft-TEP-Versorgungen – Eine experimentelle Studie

Authors

Timo Julian Schwarz¹, Markus Weber¹, Christian Dornia², Michael Worlicek¹, Tobias Renkawitz¹, Joachim Grifka¹, Benjamin Craiovan¹

Affiliation

- 1 Department of Orthopedic Surgery, University Medical Center Regensburg, Bad Abbach, Germany
- 2 Department of Radiology, University Medical Center, Regensburg

Key words

THA, pelvic tilt, pelvic rotation, anteversion, cup position, inclination

received 11.11.2016

accepted 08.04.2017

Bibliography

DOI <https://doi.org/10.1055/s-0043-110012>

Published online: 11.7.2017 | Fortschr Röntgenstr 2017; 189: 864–873 © Georg Thieme Verlag KG, Stuttgart · New York, ISSN 1438-9029

Correspondence

Dr. Timo Julian Schwarz

Department of Orthopedic Surgery, University Medical Center Regensburg, Kaiser-Karl-V.-Allee 3, 93077 Bad Abbach, Germany

Tel.: ++49/94 05/1 80

Fax: ++49/94 05/1 82 90

Timo_Schwarz@hotmail.com

ZUSAMMENFASSUNG

Ziel Nach Hüft-TEP-Versorgungen ist die korrekte Vermessung der Pfannenstellung in postoperativen Röntgenaufnahmen wichtig für die Qualitätskontrolle. In dieser Studie stellen wir eine neue Methode vor, mit der wir Messungenauigkeiten, die sich durch die Beckenverkipfung und -verdrehung ergeben, korrigieren können.

Methode In einem experimentellen Ansatz implantierten wir eine Prothesenpfanne in ein Kunststoffbecken und bestimmten die tatsächliche Pfannenstellung in einer CT. Um die Auswirkung der Beckenverkipfung und -verdrehung auf die Pfannenstellung in AP Röntgenbildern darzustellen, wurde das Becken auf einer Halterung fixiert, mit der eine graduelle Vor- und Rückwärts-Kippung ($\pm 15^\circ$) sowie eine Beckenver-

drehung (0° bis 20° zur Gegenseite) umgesetzt werden konnte. Zur Korrektur von Messfehlern, die sich aus der Beckenverkipfung und -rotation ergeben, entwickelten wir gemäß der Definitionen der Anteversion und Inklination nach Murray ein neues Korrekturverfahren, mit dem die Pfannenstellung in einem Becken bezogenen Koordinatensystem (Anterior Pelvic Plane) vermessen werden kann.

Ergebnisse Die im CT gemessene Anteversion betrug $23,3^\circ$; in den AP Röntgenaufnahmen ergaben sich jedoch durch die Beckenverkipfung ($\pm 15^\circ$) Anteversionswinkel zwischen $11,0^\circ$ und $36,2^\circ$ (durchschnittlicher Fehler $8,3^\circ \pm 3,9^\circ$). Die Pfanneninklination betrug im CT $34,1^\circ$ und variierte zwischen $31,0^\circ$ und $38,7^\circ$ (d. Fehler $2,3^\circ \pm 1,5^\circ$) in AP Röntgenaufnahmen. Auch die Beckenverdrehung zwischen 0° und 20° zeigte eine hohe Variation der im Röntgen gemessenen Anteversion ($21,2^\circ$ – $31,2^\circ$, d. Fehler $6,0^\circ \pm 3,1$) und Inklination ($34,1^\circ$ – $27,2^\circ$, d. Fehler $3,4^\circ \pm 2,5^\circ$). Unser neuer Korrekturalgorithmus für die Beckenverkipfung reduzierte den Fehler bei der Anteversionsvermessung auf $0,6^\circ \pm 0,2^\circ$ und bei der Inklinationsmessung auf $0,7^\circ \pm 0,2$. Ebenfalls wurde der durchschnittliche Fehler aufgrund der Beckenrotation bei der Anteversion auf $0,4^\circ \pm 0,4^\circ$ und bei der Inklination auf $1,3 \pm 0,8$ reduziert.

Zusammenfassung Beckenverkipfung und Beckenverdrehung können zu Fehleinschätzungen der Pfannenstellung in postoperativen Röntgenaufnahmen führen. Mathematische Korrekturverfahren, die direkt in zukünftige radiologische Softwareprogrammen implementiert werden können, haben das Potential diese Fehler signifikant zu reduzieren.

Kernaussagen

- Die Beckenverkipfung und -verdrehung beeinflussen die Pfannenstellung bei Hüft TEPs
- Die Anteversion und Inklination der Prothesenpfanne sollte auf das Becken bezogen werden
- Radiografische Messfehler der Pfannenposition können durch mathematische Korrekturverfahren korrigiert werden.

ABSTRACT

Purpose Accurate assessment of cup orientation on postoperative pelvic radiographs is essential for evaluating outcome after THA. Here, we present a novel method for correcting measurement inaccuracies due to pelvic tilt and rotation.

Method In an experimental setting, a cup was implanted into a dummy pelvis, and its final position was verified via CT. To show the effect of pelvic tilt and rotation on cup position, the dummy was fixed to a rack to achieve a tilt between +15° anterior and -15° posterior and 0° to 20° rotation to the contralateral side. According to Murray's definitions of anteversion and inclination, we created a novel corrective procedure to measure cup position in the pelvic reference frame (anterior pelvic plane) to compensate measurement errors due to pelvic tilt and rotation.

Results The cup anteversion measured on CT was 23.3°; on AP pelvic radiographs, however, variations in pelvic tilt ($\pm 15^\circ$) resulted in anteversion angles between 11.0° and 36.2° (mean error $8.3^\circ \pm 3.9^\circ$). The cup inclination was 34.1° on CT and ranged between 31.0° and 38.7° (m. e. $2.3^\circ \pm 1.5^\circ$) on radiographs. Pelvic rotation between 0° and 20° showed high variation in radiographic anteversion (21.2°–31.2°, m. e. $6.0^\circ \pm 3.1^\circ$) and inclination (34.1°–27.2°, m. e. $3.4^\circ \pm 2.5^\circ$). Our

novel correction algorithm for pelvic tilt reduced the mean error in anteversion measurements to $0.6^\circ \pm 0.2^\circ$ and in inclination measurements to 0.7° ($SD \pm 0.2$). Similarly, the mean error due to pelvic rotation was reduced to $0.4^\circ \pm 0.4^\circ$ for anteversion and to $1.3^\circ \pm 0.8$ for inclination.

Conclusion Pelvic tilt and pelvic rotation may lead to misinterpretation of cup position on anteroposterior pelvic radiographs. Mathematical correction concepts have the potential to significantly reduce these errors, and could be implemented in future radiological software tools.

Key Points

- Pelvic tilt and rotation influence cup orientation after THA
- Cup anteversion and inclination should be referenced to the pelvis
- Radiological measurement errors of cup position may be reduced by mathematical concepts

Citation Format

- Schwarz TJ, Weber M, Dornia C et al. Correction of Pelvic Tilt and Pelvic Rotation in Cup Measurement after THA – An Experimental Study. *Fortschr Röntgenstr* 2017; 189: 864–873

Introduction

After total hip arthroplasty (THA), accurate assessment of component orientation is crucial for both analyzing hip pain and postoperative quality control. Inaccurate placement of femoral and acetabular components is associated with dislocation [1], a decreased range of motion [2, 3], periprosthetic impingement [2], and component wear [4]. For orientation of the femoral component, stem torsion can be assessed by means of the neck-shaft angle (NSA) [5]. The orientation of the acetabular cup is described by the angle of inclination and anteversion [6]. Inclination is uniformly measured by means of plain radiographs, but various methods have been described for assessing anteversion [1, 7–12]. Several studies have investigated the accuracy of radiographic anteversion measurements by comparing radiographic measurements with measurements by means of postoperative computed tomography (CT) [13–18]. However, some of these studies have reported errors of more than 20° due to inconsistent measurement methods and reference planes [13, 14, 17–19]. Cup orientation may be referenced to the functional coronal plane (FCP) in standing position or to the bony landmarks of the anterior pelvic plane (APP) defined by the 2 anterior superior iliac spines and the pubic tubercles [1]. In an experimental study, we recently showed the isolated effect of X-ray central beam offset to be a potential source of error during cup measurement by means of anteroposterior (AP) radiographs. In the case of multidirectional central beam offsets of ± 5 cm, the mean error in cup anteversion was 4.0° and could be reduced to 0.6° by a novel calculation for central beam offsets [20].

Besides inconsistent use of measurement methods and central beam offset, pelvic tilt and pelvic rotation are two major sources of potential misinterpretation of acetabular cup position using AP pelvic radiographs in THA. 1° of pelvic tilt may change anteversion by 0.8° [21]. Several methods using normograms [22] or mathematical equations [23–25] have been developed for compensating errors due to pelvic tilt. To the best of our knowledge, no corrective calculation can yet compensate errors due to central beam offset, pelvic tilt, and pelvic rotation in one procedure.

Thus, the aim of this feasibility study was to answer the following two questions by means of a dummy pelvis simulating pelvic rotation and pelvic tilt: What are the potential measurement errors on AP pelvic radiographs due to pelvic tilt and pelvic rotation? May our novel correction algorithm that had already been used for reducing errors due to central beam offset in cup measurements also reduce errors due to pelvic tilt and rotation, thus making radiographic measurements comparable to CT measurements?

Methods

Test dummy

We implanted a press fit cup with a diameter of 52 mm (Pinnacle, Depuy, Warsaw, IN, USA) into a pelvic saw bone model. Exact values of cup orientation in the APP were obtained by means of a CT scan of the dummy pelvis. Radiographic anteversion and inclination were measured with the image processing software of MEVIS (Mevis Fraunhofer Institute, Bremen, Germany). We then constructed a rack and a rotatory platform (► **Fig. 1**) with a double



► **Fig. 1** Rotatory platform (left) and rack for a test pelvis (right) to simulate pelvic tilt and rotation.

► **Abb. 1** Rotatorische Plattform (links) und Gestell für das Testbecken (rechts) mit denen die Beckenkipfung und Beckenrotation simuliert wurden.

bottom for the test pelvis to simulate pelvic tilt and pelvic rotation on AP radiographs.

Computed tomography

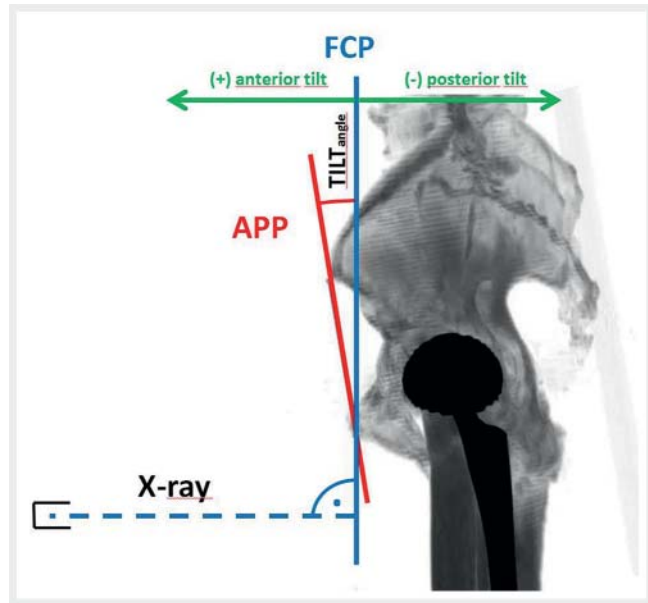
CT images were acquired with a 16-slice multidetector CT scanner (Somatom Emotion, Siemens Healthcare, Erlangen, Germany). The following scan parameters were used: collimation 16×0.6 mm, rotation time 1.0 sec, pitch 1.5, tube voltage 130 kV, tube current dose modulated 22–28 mAs.

Radiographic imaging

All radiographs were acquired in an upright position with a digital flat panel detector system (Siemens Multix, Siemens Healthcare, Erlangen, Germany). The following scan parameters were used: tube voltage 77 kV, tube current dose modulated, focus-detector distance 110 cm, focus-object distance 85 cm.

Experiment for pelvic tilt

Initially, the dummy pelvis was set onto the rack and positioned in the beam path of an X-ray apparatus for standing positions. Similar to the definition of Babisch [22], pelvic tilt was defined as the angle between the vertical functional coronary plane (FCP) and the anterior pelvis plane (APP) (► **Fig. 2**). Neutral position of pelvic tilt was set and checked with a lateral radiograph that showed a vertical line between the anterior superior iliac spine and the pelvic symphysis (► **Fig. 3**). In this position, the functional coronal plane corresponds to the APP. In AP low-centered pelvic radiographs (focus-object: 85 cm and focus-detector distance: 110 cm), we created an anterior tilt of 15° and a posterior tilt of



► **Fig. 2** In standing AP radiographs of the pelvis, the functional coronal plane (FCP) is perpendicular to the X-ray central beam. The anterior pelvis plane (APP) is defined by both superior iliac spines and the symphysis. Pelvic tilt describes the angle between the APP and FCP with a positive sign during anterior tilt.

► **Abb. 2** Bei Beckenübersichtsaufnahmen im Stand steht die funktionelle Coronarebene (FCP) senkrecht zum Röntgen-Zentralstrahl. Die vordere Beckenebene (APP) wird durch die Spina iliaca anterior superior bds. und die Symphyse definiert. Die Beckenkipfung (TILT-angle) beschreibt den Winkel zwischen der APP und FCP mit einem positiven Vorzeichen bei Vorwärtskipfung.

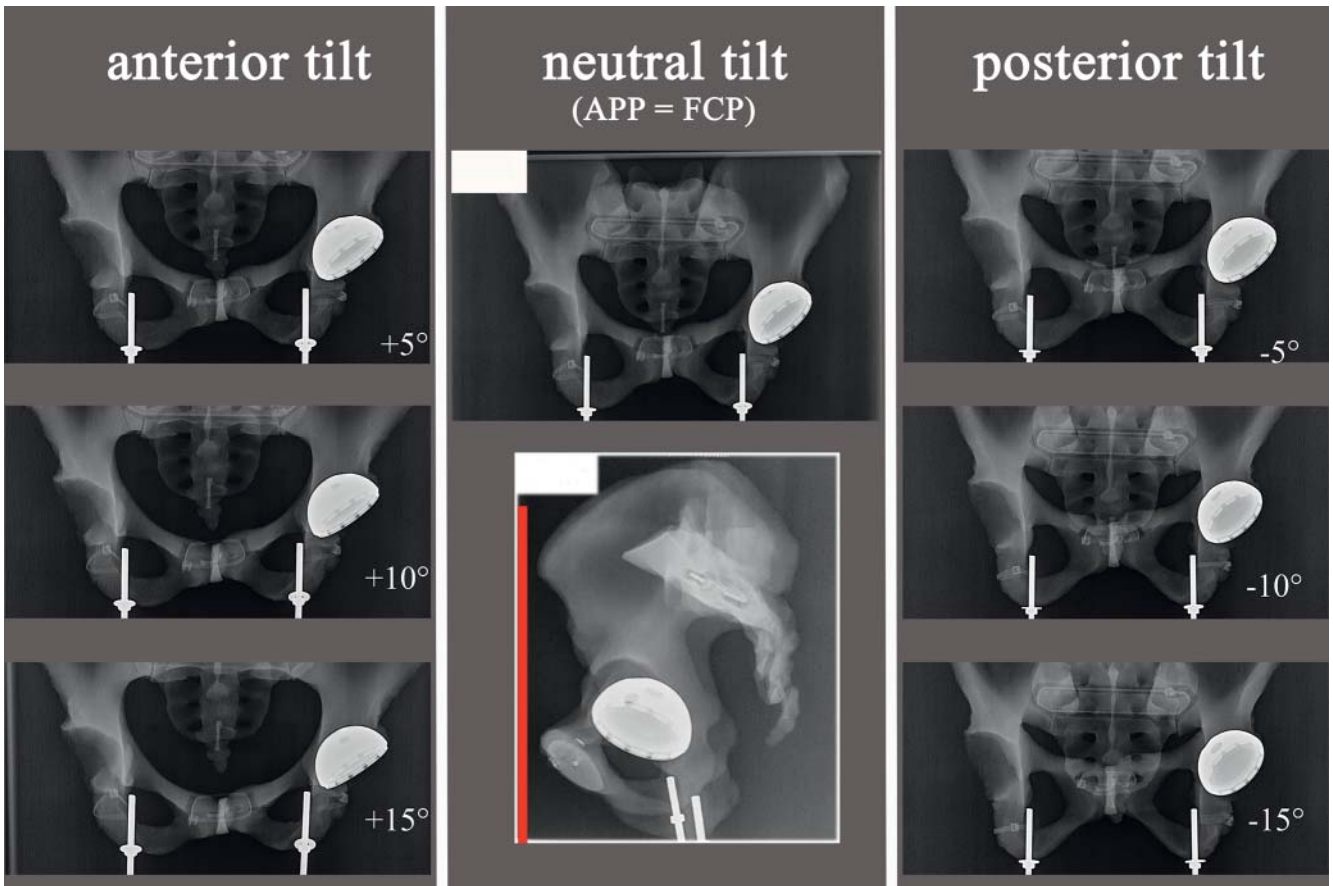
-15° using 5° steps. By positioning a smartphone on the mobile bottom of the rack, we were able to adjust the exact angles with an accelerometer (► **Fig. 1**). Thus, the pelvic tilt (TILT_{angle}) was measured in comparison to the APP (positive for anterior tilt and negative for posterior tilt).

Experiment for pelvic rotation

To show the influence of pelvic rotation in front of the X-ray detector, we positioned the rack of the test pelvis on the rotatory platform (► **Fig. 1**). The pelvis was rotated to the contralateral side from 0° to 20° in increments of 2.5° . These rotation angles were recorded as faux profile angles (FP_{angle}) with a positive sign for ipsilateral rotation and a negative sign for contralateral rotation. The faux profile angle is measured between the back of the patient and the X-ray film, which – according to Lequesne – is 65° on true faux profile radiographs [26, 27]. During this rotatory series, the pelvic tilt was disregarded. Therefore, unlike in our CT measurement, cup position could not be referenced to the APP.

Measurement of cup orientation

The radiographic anteversion and inclination of the acetabular cup were measured with the cup position tool TraumaCad 2.0 (BrainLAB Feldkirchen, Germany). After image calibration via the cup size, we measured the vertical and horizontal central beam



► **Fig. 3** Anterior and posterior tilt of the dummy pelvis. In the case of neutral pelvic tilt, the anterior pelvic plane (line between the anterior superior iliac spine and the symphysis) is vertical, and the functional coronal plane (FCP) correlates with the anterior pelvic plane (APP).

► **Abb. 3** Vorwärts- und Rückwärtskipfung des Testbeckens. Bei ausbleibender Beckenkipfung (neutral tilt) ist die vordere Beckenebene (Linie zwischen Spina iliaca anterior superior und der Symphyse) vertikal und die funktionelle Coronarebene (FCP) entspricht der vorderen Beckenebene (APP).

offset. Knowing the focus-object distance (85 cm), the error due to central beam offset was compensated for each measurement as described previously [20]. We designed a Microsoft Excel sheet (see ► **Online Excel Table 1**) for correcting the central beam offset and pelvic tilt and rotation, as shown below and in the appendix. To enable others to reproduce our technique without TraumaCad's cup position tool (software to detect radiographic anteversion), we added Lewinnek's formula for radiographic anteversion to the Excel sheet [1]. Thus, uncorrected radiographic anteversion (RA) can be assessed from the small (s) and long (l) cup diameter by the following trigonometric relation: $RA = \arcsin(s/l)$.

A detailed explanation of how to measure Lewinnek's parameters manually (small and long diameter) is given in our previous study [20]. An example is also included in the supplementary material (► **Supplementary Fig. 1**).

Corrective procedure

For erroneous measurements due to central beam offset from the cup, we developed a corrective 2-step procedure [20]. In an analogous manner, errors due to pelvic tilt and rotation are compen-

sated in the same procedure by grouping the errors into horizontal and vertical errors.

Horizontal errors stem from the X-ray source located too far to the medial or lateral side of the cup opening. Such dislocations may occur in the case of horizontal central beam offset when the central beam is directed at the symphysis (medial X-ray offset) or in the case of pelvic rotation due to body distortion in front of the X-ray detector. In both cases, the angle of incidence of the X-ray at the acetabular cup differs horizontally. Vertical errors occur as a result of the X-ray source being too far underneath or above the cup opening. Such dislocation may occur in the case of a vertical central beam offset when the central beam is directed beneath the level of the cup, for instance in low centered X-rays of the pelvis, or in the case of pelvic tilt when the view into the acetabular cup is too high or too low because of the anterior or posterior tilt of the pelvis.

As previously described, we conducted a 2-step corrective calculation for horizontal and vertical errors by means of Murray's formulas and definitions of cup position. Thus, horizontal errors were corrected in the anatomical definition of anteversion and

vertical errors in the operative definition of anteversion as described below and shown in the appendix.

In a first step, we translated the radiographic values (measured with TraumaCad 2.0) into the anatomic definition according to Murray's formulas. Horizontal errors can be compensated by adding the angle of pelvic rotation (faux profile angle) and the angle of the horizontal central beam offset from the cup to the anatomic anteversion. This step (horizontal correction) is similar to correcting radiographic oblique projection as described by Liaw [28].

In a second step, the new anatomic anteversion was translated into the operative anteversion according to Murray's formulas. The vertical errors (pelvic tilt and angle of the vertical central beam offset from the cup) were compensated by subtracting the vertical X-ray offset angle and by adding the angle of the pelvic tilt. This way, horizontal and vertical errors were compensated, and the new operative anteversion could be retransformed into the radiographic definition according to Murray. This step (vertical correction) corresponded with Tannast's calculation for tilt-corrected cup version [24]. The same procedure was carried out for inclination (see appendix).

Data analysis

To graphically show the effect of pelvic tilt and rotation, we summarized the radiographs from the tilt and rotation series in two figures (see below) and in two movies (► **Movie 1, 2**). Using Microsoft Excel sheets in all experiments, we calculated corrected (correction of the central beam, pelvic tilt, or pelvic rotation) and uncorrected (correction of the central beam only) cup position and reported minimal to maximal values of the range of anteversion and inclination. To express the error during measurements, we calculated the mean absolute difference (\pm SD) between CT measurement and measurements (corrected and uncorrected) in the six radiographs with anterior and posterior tilt. During the rotatory series, we disregarded the pelvic tilt; hence unlike on the CT scan, acetabular version cannot be referred to the APP. The mean absolute difference (\pm SD) of cup position was calculated between the first AP radiograph (0° faux profile angle) and the following eight radiographs showing pelvic rotation.

Results

Experiment of pelvic tilt

As shown in ► **Fig. 3** ► **Movie 1**, the oval shape of the cup opening becomes smaller in the case of increasing anterior tilt because of the restricted view into the acetabular cup. The oval shape of the cup opening is increased because of the better view into the cup opening during posterior tilt.

In our test pelvis, CT measurement of the cup orientation in the APP (MEVIS, Fraunhofer Institute, Bremen, Germany) showed radiographic anteversion of 23.3° and radiographic inclination of 34.1° . In the corresponding AP radiograph (neutral tilt and no pelvic rotation), we measured radiographic anteversion and inclination with TraumaCad 2.0 and applied our correction for central beam offset as described previously [20]. In line with

the CT measurement, the radiographic anteversion was 23.2° and the radiographic inclination was 34.8° on the AP radiograph.

For tilts ranging between -15° posterior tilt and $+15^\circ$ anterior tilt, the radiographic anteversion ranged between 36.2° and 11.0° (mean absolute difference 8.3° , $SD \pm 3.9^\circ$). After the application of vertical correction, the cup orientation was referenced to the osseous landmarks of the APP. Thus, the high range of radiographic anteversion was reduced to values between 22.6° and 24.0° (mean absolute difference 0.6° , $SD \pm 0.2^\circ$) compared to CT anteversion of 23.3° (► **Fig. 4A**).

Similarly, the influence of pelvic tilt on inclination showed radiographic inclination ranging between 38.7 and 31.0 (mean absolute difference 2.3° , $SD \pm 1.5^\circ$) without correction. With our correction for pelvic tilt, the range of radiographic inclination (► **Fig. 4B**) was reduced to values between 35.1° and 33.3° (mean absolute difference 0.7° , $SD \pm 0.2^\circ$).

Pelvic rotation

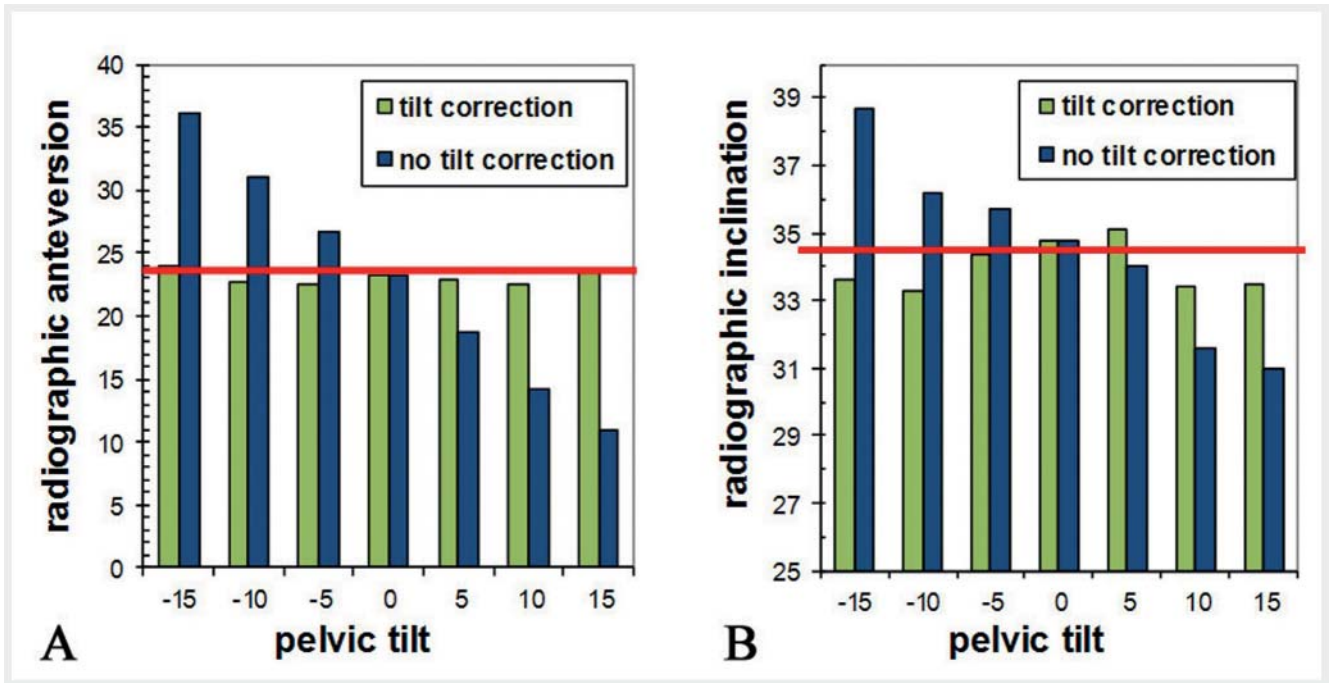
As shown in ► **Fig. 5**, ► **Movie 2**, rotation of the pelvis around the longitudinal axis to the contralateral side of the prosthetic cup allows a better view into the acetabular cup and may simulate higher anteversion.

In experiments of pelvic rotation, we disregarded the pelvic tilt. Thus, cup position was assessed in the functional coronal plane and, unlike on the CT scan, cannot be referred to APP. For the neutral pelvis position (no pelvic rotation), we measured a radiographic anteversion of 21.2° and a radiographic inclination of 34.1° . In the case of distorted pelvis positioning (rotation to the contralateral side from 0° and 20°), the radiographic anteversion ranged between 21.2° and 31.2° (mean absolute difference 6.0° , $SD \pm 3.1^\circ$) and the radiographic inclination between 34.1 and 27.2 (mean absolute difference 3.4° , $SD \pm 2.5^\circ$) (► **Fig. 6A, B**). Horizontal correction reduced the high ranges of radiographic anteversion and inclination to a range between 20.3° and 21.7° (mean absolute difference 0.4° , $SD \pm 0.4^\circ$) for anteversion and 34.1° to 36.9° (mean absolute difference 1.3° , $SD \pm 0.8$) for inclination.

Discussion

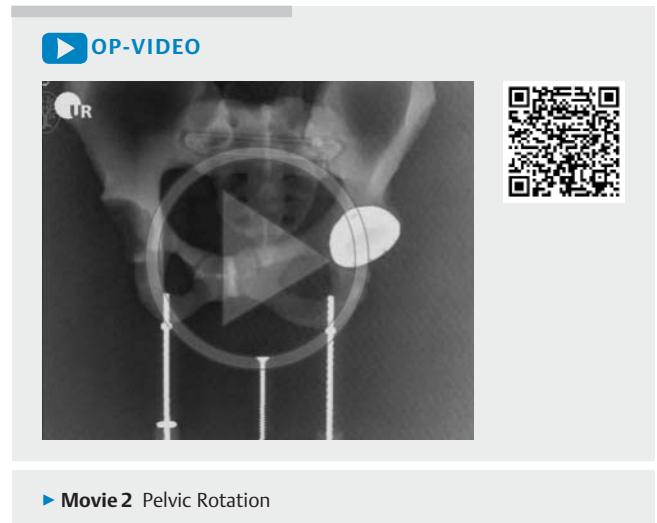
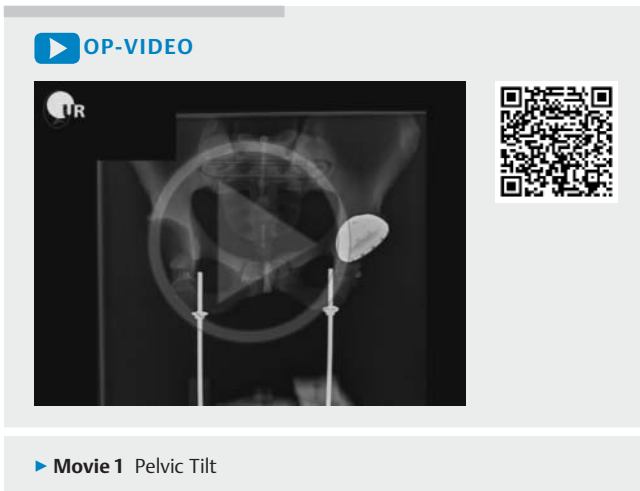Pelvic tilt and pelvic rotation are potential sources of cup misinterpretation in THA. On AP radiographs, the present study showed the large effect of pelvic tilt and rotation on measuring cup anteversion and inclination in a dummy pelvis. Our novel method for balancing these effects was successfully applied to reference measurements obtained by AP radiographs to the osseous landmarks of the APP.

This study has one major limitation, i. e., it was an experimental investigation using a dummy pelvis, in which exact angles of pelvic position were set with the aid of a rack and a rotatory platform. However, clinical settings do not provide such exact angular information. Pelvic tilt and rotation cannot yet be assessed on AP radiographs. A rough estimation of pelvic rotation on AP radiographs may be done using the Tönnis' foramen obturator index [29, 30]. By approximation, pelvic tilt may be assessed by e. g. the coccygeal-symphysis index on AP radiographs [24], but for



► **Fig. 4** The influence of pelvic tilt on **A** radiographic anteversion and **B** radiographic inclination for uncorrected orientation and pelvic tilt-corrected orientation. The red line displays radiographic anteversion and inclination according to CT-based measurement in the anterior pelvic plane.

► **Abb. 4** Auswirkung der Beckenkipfung auf die radiographische Anteversion **A** und radiographische Inklination **B** bei unkorrigierter und tilt-korrigierter Stellung. Die rote Linie beschreibt die radiografische Anteversion und Inklination, wie sie in der CT in Relation zu der vorderen Beckenebene vermessen wurde.



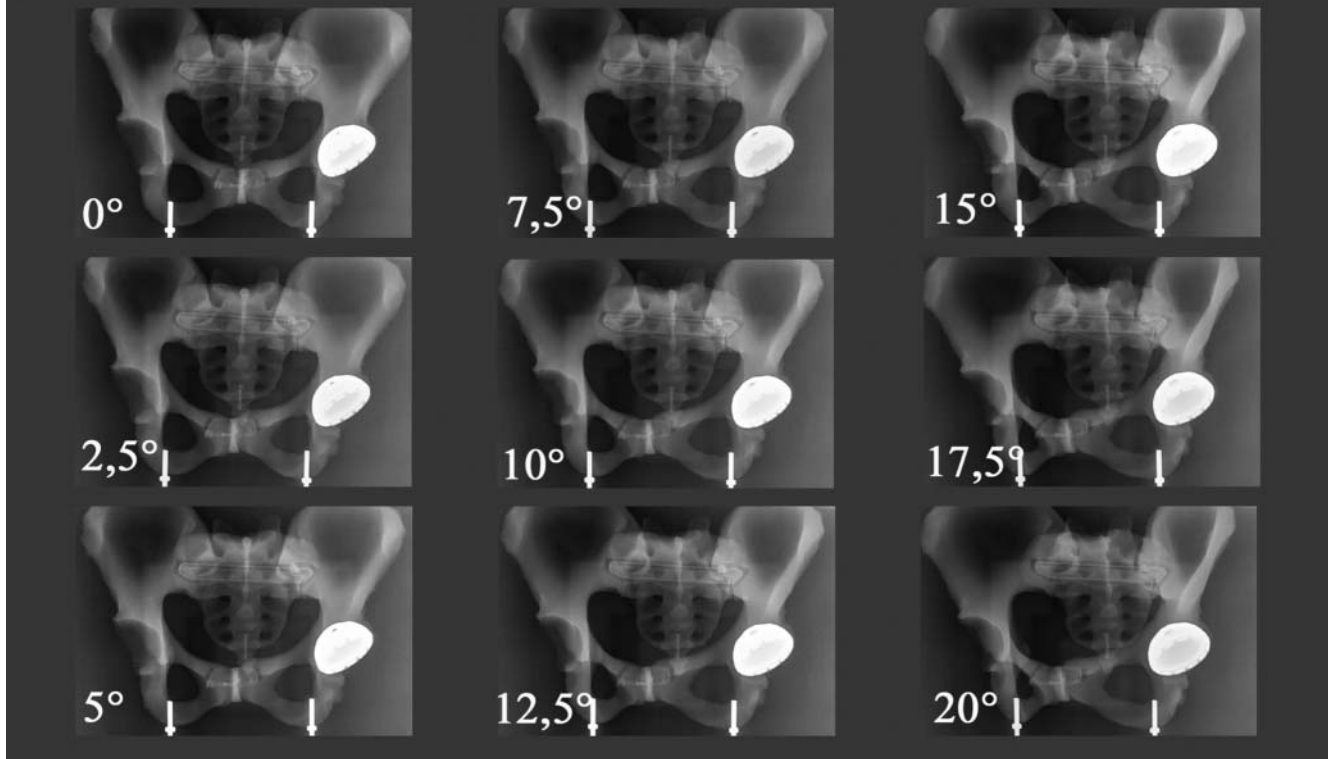
exact angular information lateral radiographs of the pelvis are necessary [22]. A second limitation is our experimental setup. We investigated the isolated effect of pelvic tilt and pelvic rotation, but did not perform experiments in combination. Thus, in this study we did not show feasibility for the correction of cup position in a mixed pelvic position. However, the high potential for combined (vertical and horizontal) errors was already shown in our previous study [20].

Although no method for assessing pelvic position on AP radiographs is yet available, our study depicts the importance of corrective calculation. A variation in the pelvic tilt of $\pm 15^\circ$ resulted

in a difference of 25.2° between the minimum and maximum angle for anteversion and in a difference of 7.7° for inclination. Consistent with the investigation by Malik, we were able to show increased inclination and anteversion during posterior tilt and decreased parameters during anterior tilt [21]. Using our corrective calculation for pelvic tilt, cup position was successfully referenced to the APP with a mean error of 0.6° for anteversion and 0.7° for inclination.

Using AP radiographs, some investigators assessed cup orientation in the APP [1, 14, 18], while others measured cup position

pelvic rotation



► **Fig. 5** Different cup positions in pelvic rotation from 0° to 20° to the contralateral side.

► **Abb. 5** Unterschiedliche Pfannenpositionen während der Beckenrotation von 0° bis 20° zur kontralateralen Seite.

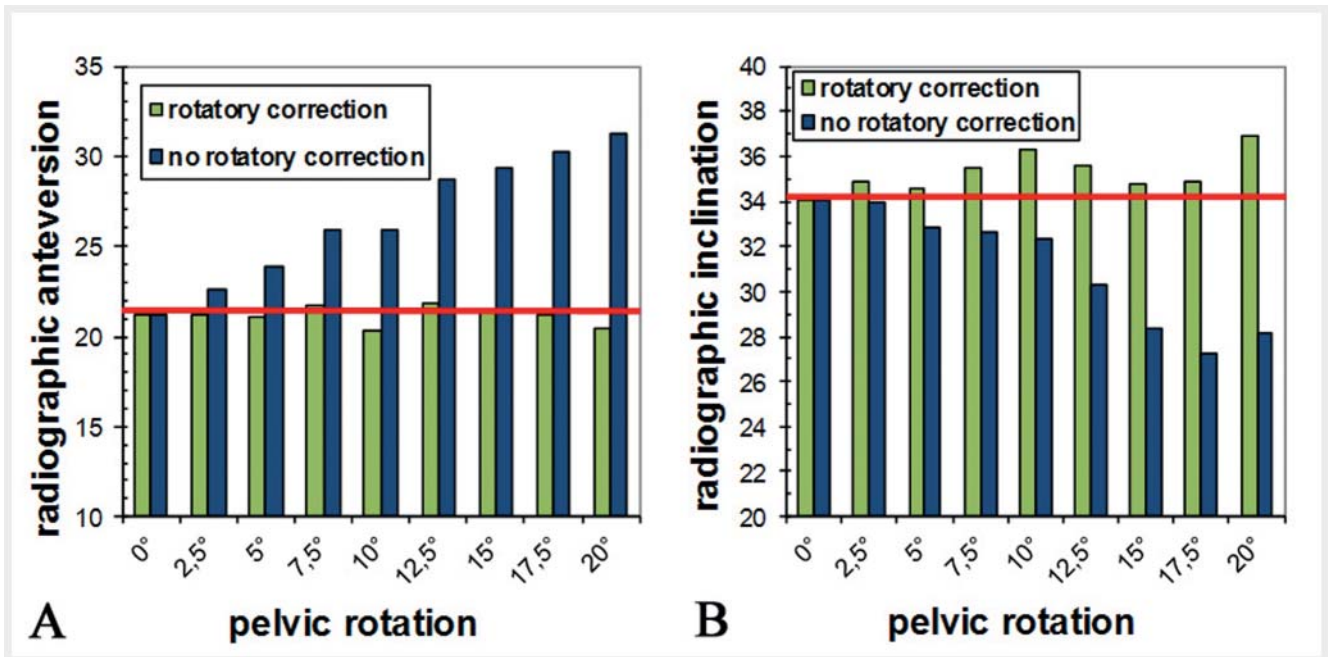
in the functional coronal plane [15–17, 31]. Assessment of cup orientation in the APP is necessary when computer navigation is used for improving the range of motion in THA [2]. Babisch used normograms to convert values of cup position from the APP to the coronal plane [22]. Similar to our correction method, Wan and Lembeck also used a mathematical solution to transfer values of cup position from one reference plane to another reference plane [23, 25]. Comparing these formulas with ours, identical values of tilt-corrected cup position were measured (data not shown). However these formulas, designed for pelvic tilt, cannot balance errors due to central beam offset and pelvic rotation.

Considering the individual pelvic tilt in standing position (in ► **Fig. 3**, $\pm 15^\circ$), prosthetic cup position (referenced in the APP) may occur in completely different orientations for anteversion and inclination on AP radiographs (referenced in the FCP). Solely performing assessment of cup position relative to the bony landmarks of the APP ignores this functional relation of the pelvis relative to the longitudinal axis of the body in standing position [21]. Thus, error analysis and postoperative quality measure also require assessment of cup orientation on the FCP on AP radiographs. Due to the reversal of the functional pelvic tilt in supine position [32], CT measurement of cup position is not suitable to assess cup position on the functional coronal plane. Assessing cup position on AP radiographs on the FCP does not necessitate

any corrective calculation for pelvic tilt. For exact angular calculation of anteversion and inclination, however, we suggest using our corrective calculation for X-ray offset and pelvic rotation.

Pelvic rotation is an obvious source of inaccurate measurements of cup anteversion on AP radiographs. Our experiment of pelvic rotation (0° to 20° to the contralateral side) showed that not only anteversion measurements but also inclination measurements require corrective calculation. Our corrective calculation reduced the mean error of anteversion to 0.4° and that of inclination to 1.3°. Analogous to pelvic tilt, radiographic anteversion showed higher variation than inclination and was better correctable compared to radiographic inclination.

Malposition of the patient bears the risk of misinterpretation of cup position in THA. The same problem is known during the measurement of parameters of the native acetabulum [33, 34]. Software tools are successfully applied to normalize parameters of the native acetabulum [35] and the cup position in THA [14]. Beside malposition of the patient, technical difficulties, such as X-ray central beam offset relative to the cup, are also a potential source of misinterpretation [10, 28, 36]. Previously, we described a novel method to compensate for the error of X-ray central beam offset using the formulas and definitions of cup position established by Murray [20]. In this experimental investigation, we were able to show that our corrective calculation may also be applied to com-



► **Fig. 6** Radiographic anteversion **A** and inclination **B** dependent on pelvic rotation from 0° to 20° to the contralateral side. Values with and without rotatory correction. The red line displays the measured radiographic anteversion and inclination in neutral position (no pelvic rotation).

► **Abb. 6** Radiografische Anteversion **A** und radiografische Inklination **B** in Abhängigkeit der Beckenrotation von 0° bis 20° zur kontralateralen Seite. Darstellung einmal mit und einmal ohne Rotationskorrektur. Die rote Linie entspricht der gemessenen radiographischen Anteversion und Inklination bei ausbleibender Rotation (0° Rotation).

compensate for the error of pelvic tilt and rotation. Regarding computer-assisted radiology, we hope future CAD software will provide our correction in order to reference cup position to the APP and FCP without errors due to central beam offset and pelvic rotation. Further investigations in a clinical setting will be necessary to prove the usefulness of this method in daily practice.

Central beam offset, pelvic tilt and rotation strongly influence cup position in THA and thus harbor the risk of potential misinterpretation of cup inclination and anteversion on AP pelvic radiographs. The current correction shows the mathematical relation of tilt and rotation to cup position measured on AP radiographs. The presented algorithm enables cup estimation corrected for central beam offset, tilt and rotation in THA.

Appendix

Vertical and horizontal correction for central beam offset, pelvic tilt and pelvic rotation

To calculate the corrected cup position and to reference cup orientation to the APP and FCP, we designed a Microsoft Excel sheet (see ► **online Excel Table 1**) for the calculations shown below. Deviations in this calculation from the previously described calculation for central beam offset correction [20] are in bold print. The following parameters are required and exemplarily measured in the ► **Supplementary Fig. 1** in the supplementary material (AP radiograph of pelvis with -10° posterior tilt and no pelvic rotation). By inserting the parameters in the yellow fields

in the Excel sheet, corrected cup position referenced to the APP and FCP is calculated automatically.

RA = radiographic anteversion = $\arcsin(s/l) = \arcsin(21\text{ mm}/45\text{ mm}) = 27.8^\circ$

RI = radiographic inclination = 39°

X = horizontal offset of X-ray (20) = 85 mm

Y = vertical offset of X-ray (20) = 8.5 mm

TILT_{angle} = pelvic tilt (negative sign for posterior tilt) = -10°

FP_{angle} = pelvic rotation (negative sign for rotation to contralateral side) = 0°

Radiographic anteversion is either calculated from the small and long diameter (s and l) of the acetabular cup according to Lewinnek or is measured with digital image processing software. Radiographic inclination (RI) is measured as the angle between the horizontal line of the pelvis and the continued line of the long diameter of the cup. The horizontal and vertical offset angles (X_{angle}, Y_{angle}) for central beam are calculated by means of the trigonometric relation between the X-ray offset (X, Y) and the distance between the focus and the object (FO = 850 mm):

X_{angle} = $\arctan(X/FO) = \arctan(85\text{ mm}/850\text{ mm}) = 5.7^\circ$

Y_{angle} = $\arctan(Y/FO) = \arctan(8.5\text{ mm}/850\text{ mm}) = 0.6^\circ$

Horizontal correction – first step:

Radiographic anteversion (RA) and inclination (RI) are transformed in the anatomic definition (AA and AI) according to Murray:

AA = $\arctan(\tan RA / \sin RI) = \arctan(\tan 27.8^\circ / \sin 39^\circ) = 40^\circ$

AI = $\arccos(\cos RI \cdot \cos RA) = \arccos(\cos 39^\circ \cdot \cos 27.8^\circ) = 46.6^\circ$

Adding the angle of the horizontal X-ray offset (X_{angle}) and the faux profile angle (FP_{angle}) to the anatomical anteversion (AA) compensates the error due to the horizontal X-ray offset and the pelvic rotation:

$$AA_{X_{\text{corr}}} = AA + X_{\text{angle}} + FP_{\text{angle}} = 40^\circ + 5.7^\circ + 0^\circ = 45.7^\circ$$

Anatomical inclination (AI) is not affected by the horizontal X-ray offset and pelvic rotation, thus no correction is necessary.

Vertical correction – second step:

The horizontal corrected anteversion ($AA_{X_{\text{corr}}}$) is transformed in the operative definition ($OA_{X_{\text{corr}}}$) according to Murray's formulas:

$$OA_{X_{\text{corr}}} = \arctan(\sin AA_{X_{\text{corr}}} \cdot \tan AI) = \arctan(\sin 45.7^\circ \cdot \tan 46.6^\circ) = 37.1^\circ$$

Subtracting the angle of the vertical X-ray offset (Y_{angle}) from operative anteversion ($OA_{X_{\text{corr}}}$) and adding the angle of pelvic tilt ($TILT_{\text{angle}}$) compensates errors due to the horizontal X-ray offset and pelvic tilt. Thus, horizontally and vertically corrected operative anteversion ($OAXY_{\text{corr}}$) is calculated:

$$OAXY_{\text{corr}} = OA_{X_{\text{corr}}} - Y_{\text{angle}} + TILT_{\text{angle}} = 37.1^\circ - 0.6^\circ - 10^\circ = 26.5^\circ$$

Operative inclination is not influenced by the vertical X-ray offset and pelvic tilt and is calculated according to Murray's formulas from horizontally corrected anteversion ($AA_{X_{\text{corr}}}$) and anatomic inclination (AI).

$$OI_{XY_{\text{corr}}} = \arcsin(\cos AA_{X_{\text{corr}}} \cdot \sin AI) = \arcsin(\cos 45.7^\circ \cdot \sin 46.6^\circ) = 30.5^\circ$$

Finally, horizontally and vertically corrected operative definitions of anteversion ($OAXY_{\text{corr}}$) and inclination ($OI_{XY_{\text{corr}}}$) are retransformed to the radiographic or anatomic definition with Murray's formulas.

Transformation into the anatomic definition:

$$AA_{XY_{\text{corr}}} = \arctan(\sin OAXY_{\text{corr}} / \tan OI_{XY_{\text{corr}}}) = 37.2^\circ$$

$$AI_{XY_{\text{corr}}} = \arctan(\tan OAXY_{\text{corr}} / \sin AA_{XY_{\text{corr}}}) = 39.6^\circ$$

Transformation into the radiographic definition:

$$RA_{XY_{\text{corr}}} = \arcsin(\sin OAXY_{\text{corr}} \cdot \cos OI_{XY_{\text{corr}}}) = 22.6^\circ$$

$$RI_{XY_{\text{corr}}} = \arctan(\tan OI_{XY_{\text{corr}}} / \cos OAXY_{\text{corr}}) = 33.3^\circ$$

In our series, we retransformed the operative definition into the radiographic definition.

Conflict of Interest

The authors declare that they have no conflict of interest.

This article does not contain any studies with human participants or animals.

This article does not contain any patient data.

Literature

- [1] Lewinnek GE, Lewis JL, Tarr R et al. Dislocations after total hip-replacement arthroplasties. *J Bone Joint Surg Am* 1978; 60: 217–220
- [2] Renkawitz T, Weber M, Springorum HR et al. Impingement-free range of movement, acetabular component cover and early clinical results comparing 'femur-first' navigation and 'conventional' minimally invasive total hip arthroplasty: a randomised controlled trial. *Bone Joint J* 2015; 97-B: 890–898
- [3] D'Lima DD, Urquhart AG, Buehler KO et al. The effect of the orientation of the acetabular and femoral components on the range of motion of the hip at different head-neck ratios. *J Bone Joint Surg Am* 2000; 82: 315–321
- [4] Patil S, Bergula A, Chen PC et al. Polyethylene wear and acetabular component orientation. *J Bone Joint Surg Am* 2003; 85-A: 56–63
- [5] Weber M, Lechler P, von Kunow F et al. The validity of a novel radiological method for measuring femoral stem version on anteroposterior radiographs of the hip after total hip arthroplasty. *Bone Joint J* 2015; 97-B: 306–311
- [6] Murray DW. The definition and measurement of acetabular orientation. *J Bone Joint Surg Br* 1993; 75: 228–232
- [7] Woo RY, Morrey BF. Dislocations after total hip arthroplasty. *J Bone Joint Surg Am* 1982; 64: 1295–1306
- [8] Ackland MK, Bourne WB, Uthoff HK. Anteversion of the acetabular cup. Measurement of angle after total hip replacement. *J Bone Joint Surg Br* 1986; 68: 409–413
- [9] Pradhan R. Planar anteversion of the acetabular cup as determined from plain anteroposterior radiographs. *J Bone Joint Surg Br* 1999; 81: 431–435
- [10] Widmer KH. A simplified method to determine acetabular cup anteversion from plain radiographs. *J Arthroplasty* 2004; 19: 387–390
- [11] Liaw CK, Hou SM, Yang RS et al. A new tool for measuring cup orientation in total hip arthroplasties from plain radiographs. *Clin Orthop Relat Res* 2006; 451: 134–139
- [12] Zheng G, von Recum J, Nolte LP et al. Validation of a statistical shape model-based 2D/3D reconstruction method for determination of cup orientation after THA. *Int J Comput Assist Radiol Surg* 2012; 7: 225–231
- [13] Kalteis T, Handel M, Herold T et al. Position of the acetabular cup – accuracy of radiographic calculation compared to CT-based measurement. *Eur J Radiol* 2006; 58: 294–300
- [14] Craiovan B, Renkawitz T, Weber M et al. Is the acetabular cup orientation after total hip arthroplasty on a two dimension or three dimension model accurate? *Int Orthop* 2014; 38: 2009–2015
- [15] Lu M, Zhou YX, Du H et al. Reliability and validity of measuring acetabular component orientation by plain anteroposterior radiographs. *Clin Orthop Relat Res* 2013; 471: 2987–2094
- [16] Shin WC, Lee SM, Lee KW et al. The reliability and accuracy of measuring anteversion of the acetabular component on plain anteroposterior and lateral radiographs after total hip arthroplasty. *Bone Joint J* 2015; 97-B: 611–616
- [17] Ghelman B, Kepler CK, Lyman S et al. CT outperforms radiography for determination of acetabular cup version after THA. *Clin Orthop Relat Res* 2009; 467: 2362–2370
- [18] Marx A, von Knoch M, Pfortner J et al. Misinterpretation of cup anteversion in total hip arthroplasty using planar radiography. *Arch Orthop Trauma Surg* 2006; 126: 487–492
- [19] Yoon YS, Hodgson AJ, Tonetti J et al. Resolving inconsistencies in defining the target orientation for the acetabular cup angles in total hip arthroplasty. *Clin Biomech (Bristol, Avon)* 2008; 23: 253–259
- [20] Schwarz T, Weber M, Wörner M et al. Central X-ray beam correction of radiographic acetabular cup measurement after THA: an experimental study. *International Journal of Computer Assisted Radiology and Surgery* 2017; 12: 829–837
- [21] Malik A, Wan Z, Jaramaz B et al. A validation model for measurement of acetabular component position. *J Arthroplasty* 2010; 25: 812–819
- [22] Babisch JW, Layher F, Amiot LP. The rationale for tilt-adjusted acetabular cup navigation. *J Bone Joint Surg Am* 2008; 90: 357–365
- [23] Lembeck B, Mueller O, Reize P et al. Pelvic tilt makes acetabular cup navigation inaccurate. *Acta Orthop* 2005; 76: 517–523
- [24] Tannast M, Murphy SB, Langlotz F et al. Estimation of pelvic tilt on anteroposterior X-rays—a comparison of six parameters. *Skeletal Radiol* 2006; 35: 149–155
- [25] Wan Z, Malik A, Jaramaz B et al. Imaging and navigation measurement of acetabular component position in THA. *Clin Orthop Relat Res* 2009; 467: 32–42

- [26] Lequesne MG, Laredo JD. The faux profil (oblique view) of the hip in the standing position. Contribution to the evaluation of osteoarthritis of the adult hip. *Ann Rheum Dis* 1998; 57: 676–681
- [27] Leunig M, Ganz R. The Bernese method of periacetabular osteotomy. *Orthopade* 1998; 27: 743–750
- [28] Liaw CK, Yang RS, Hou SM et al. Measurement of the acetabular cup anteversion on simulated radiographs. *J Arthroplasty* 2009; 24: 468–474
- [29] Tonnis D. Normal values of the hip joint for the evaluation of X-rays in children and adults. *Clin Orthop Relat Res* 1976: 39–47
- [30] Jacobsen S, Sonne-Holm S, Lund B et al. Pelvic orientation and assessment of hip dysplasia in adults. *Acta Orthop Scand* 2004; 75: 721–729
- [31] Nho JH, Lee YK, Kim HJ et al. Reliability and validity of measuring version of the acetabular component. *J Bone Joint Surg Br* 2012; 94: 32–36
- [32] Tezuka T, Inaba Y, Kobayashi N et al. Influence of Pelvic Tilt on Polyethylene Wear after Total Hip Arthroplasty. *Biomed Res Int* 2015; 2015: 327217
- [33] van der Bom MJ, Groote ME, Vincken KL et al. Pelvic rotation and tilt can cause misinterpretation of the acetabular index measured on radiographs. *Clin Orthop Relat Res* 2011; 469: 1743–1749
- [34] Tannast M, Fritsch S, Zheng G et al. Which radiographic hip parameters do not have to be corrected for pelvic rotation and tilt? *Clin Orthop Relat Res* 2015; 473: 1255–1266
- [35] Tannast M, Mistry S, Steppacher SD et al. Radiographic analysis of femoroacetabular impingement with Hip2Norm-reliable and validated. *J Orthop Res* 2008; 26: 1199–1205
- [36] Derbyshire B. Correction of acetabular cup orientation measurements for X-ray beam offset. *Med Eng Phys* 2008; 30: 1119–1126