

European Federation of Societies for Ultrasound in Medicine and Biology



EFSUMB Guidelines and Recommendations on the Clinical Use of Liver Ultrasound Elastography, update 2017 (long and short version)

Dietrich CF, Bamber J, Berzigotti A, Ferraioli G on behalf of the EFSUMB ultrasound elastography guideline group

Correspondence:

Prof. Dr. Christoph F. Dietrich
Department of Internal Medicine 2
Caritas-Hospital Bad Mergentheim
Uhlandstr. 7
D-97 980 Bad Mergentheim
Tel.: ++ 49/7931/582 201
Fax: ++ 49/7931/582 290
Christoph.dietrich@ckbm.de

Introduction

Over the last decade the European Federation of Societies for Ultrasound in Medicine and Biology (EFSUMB) has produced a series of guidelines and recommendations regarding different ultrasound applications including

- contrast enhanced ultrasound (CEUS) [1–5],
- dynamic contrast enhanced ultrasound (DCE-US) for quantification of tumour perfusion [6],
- elastography [7, 8],
- interventional ultrasound [9–19],
- student education [20, 21],
- pediatric use of CEUS [22, 23] and
- gastrointestinal ultrasound [24, 25].

EFSUMB is working to promote high quality in ultrasound education and sustain excellent professional standards in training and practice [26]. Each of these guidelines can be considered as a chapter in a growing book. These guidelines are available on the EFSUMB website and are provided to guide both novice and expert users in performing examinations with ultrasound technology [27, 28].

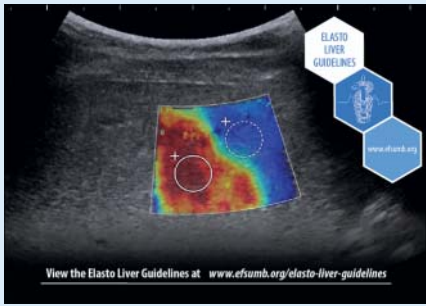
Elastography guidelines

The first elastography guidelines worldwide were introduced and published by EFSUMB in 2013 [7, 8] followed by the WFUMB guidelines [29–33]. Most recently the first update on the 2013 published EFSUMB Guidelines and Recommendations on the clinical use of elastography, focused on the assessment of diffuse liver disease, was released. The first part (long version) of these Guidelines and Recommendations deals with the basic principles of elastography and provides an update of where the technology has changed [34]. The basic principles of elastography remain unchanged since they were outlined in the first part of the original EFSUMB and WFUMB guidelines on this subject [7, 29]. This paper therefore aims to provide an update of where the technology has changed, as of 2017, in this rapidly moving field. Sufficient recapitulations are provided to allow the present paper to be understood without reference to the earlier work, although the purpose is not to reproduce the material of the 2013 paper in detail.

Content

The practical advantages and disadvantages associated with each of the techniques are described, and guidance is provided on optimization of scanning technique, image display, image interpretation, reporting of data and some of the known image artefacts. The basic principles and technology for elastography were developed by the academic research community before commercial translation, and it remains a heavily researched and rapidly developing field. EFSUMB recommends that users maintain an awareness of this field.

The second part provides clinical information about the practical use of elastography techniques and interpretation of results in the assessment of diffuse liver disease, and analyzes the main findings based on published studies, stressing the evidence from meta-analyses. The role of elastography in different etiologies of liver disease and in several clinical scenarios is also discussed. This updated document is intended to form a reference and to provide a practical guide for both beginners and advanced clinical users [34, 35]. The liver is an important target organ for the use of elastography; stiffness correlates with the degree of fibrosis and indirectly with complications including portal hypertension. Transient elastography (TE), point shear wave elastography (pSWE), two-dimensional shear wave elastography (2D-SWE), strain elastography (SE) and strain-rate imaging (SRI) are discussed according to the following chapter criteria. The following chapters were prepared to include summaries of the examination procedure, number of cases for which there is evidence, measurement technique (including fasting and resting), normal values, reproducibility, quality parameters in patients and healthy subjects, the evaluation of factors other than liver fibrosis which influence liver stiffness (confounders) and comparison of results between systems. Elastography is part of a clinical decision making process. Therefore, “clinical decision making before elastography” was a chapter of its own. The evaluation of liver diseases included the initial evaluation of chronic liver disease (as prerequisites for SWE) and the evaluation of liver diseases including the fibrosis staging of chronic hepatitis C (CHC), chronic hepatitis B (CHB), non-alcoholic fatty liver disease (NAFLD), alcoholic liver disease (ALD), cholestatic liver disease, autoimmune he-



patitis (AIH) and portal hypertension. The prognostic relevance, monitoring (evaluation) response to treatment and prediction of hepatic complications were analysed as well, according to levels of evidence (LoE), grade of recommendation (GoR) and the consensus criteria. Investigators can easily use the level of evidence to identify areas in need of additional studies. Reimbursement issues and the value of SWE in social health care systems, are also discussed.

Methodology

A steering committee was appointed, whose role was to define the general content of the guidelines, with subsequent invitation of experts from member organizations of EFSUMB, based on their publications records and expertise in the different fields, to participate in the guideline development. Section leaders were selected from the steering committee; the section leaders defined the subchapters and key topics of the new guidelines sections. Literature search was performed systematically in PubMed using predefined key words and MeSH terms and, in addition, by complimentary “hand search” using reference lists of articles retrieved by systematic search. Search in principle was defined for guidelines, meta-analyses and systematic reviews, original research articles (randomized controlled trials, prospective studies, retrospective studies, case series). Evidence tables were generated for each key topic according to EFSUMB requirements. All the recommendations were judged with regard to their evidence-based strength according to the Oxford Centre for Evidence-Based Medicine Levels of Evidence and grade of recommendations (GoR) [<http://www.cebm.net/oxford-centre-evidence-based-medicine-levels-evidence-march-2009>].

Drafts of overview, recommendations and comments were provided by the authors for each section, revised by the members of the steering committee.

The revised drafts were submitted to the whole expert group before the expert meeting, held in London, UK on 1 July 2016. Representatives of manufacturers were invited to participate in the meeting and were allowed to comment but had no influence on the writing of the guidelines. At the expert meeting the review and recommendations were presented to the entire organ group. All evidence-based recommendations were discussed, improved, and the draft document was improved according to the level of evidence. Grade of recommendation and the level of consensus was also documented. Consensus was graded using the proposed and published system: strong consensus (>95 % of experts votes), broad agreement (>75 % – 95 %) and majority consensus (>50 % – 75 %). The steering committee first, and entire group of authors thereafter, reviewed and revised the draft document in a stepwise fashion for consistency and accuracy. Following the consensus meeting, comments were adapted to the final recommendations and shortened. The LoE and GoR were checked by the authors and steering committee.

Future perspectives

Future requirements in liver elastography include the need to compare the accuracy of different technologies (TE, pSWE and 2D-SWE) in a large cohort of patients and to analyse results in terms of the aetiologies of liver diseases. Robust cut-off values must be established for each of the different systems and diseases. Combination of elastographic methods, using ultrasound with biological tests, may improve the accuracy of the evaluation of patients.

References

- [1] Albrecht T, Blomley M, Bolondi L et al. Guidelines for the use of contrast agents in ultrasound. January 2004. *Ultraschall in Med* 2004; 25: 249 – 256
- [2] Claudon M, Cosgrove D, Albrecht T et al. Guidelines and good clinical practice recommendations for contrast enhanced ultrasound (CEUS) – update 2008. *Ultraschall in Med* 2008; 29: 28 – 44
- [3] Piscaglia F, Nolsoe C, Dietrich CF et al. The EFSUMB Guidelines and Recommendations on the Clinical Practice of Contrast Enhanced Ultrasound (CEUS): update 2011 on non-hepatic applications. *Ultraschall in Med* 2012; 33: 33 – 59
- [4] Claudon M, Dietrich CF, Choi BI et al. Guidelines and good clinical practice recommendations for Contrast Enhanced Ultrasound (CEUS) in the liver – update 2012: A WFUMB-EFSUMB initiative in cooperation with representatives of AFSUMB, AIUM, ASUM, FLAUS and ICUS. *Ultrasound Med Biol* 2013; 39: 187 – 210
- [5] Claudon M, Dietrich CF, Choi BI et al. Guidelines and good clinical practice recommendations for contrast enhanced ultrasound (CEUS) in the liver – update 2012: a WFUMB-EFSUMB initiative in cooperation with representatives of AFSUMB, AIUM, ASUM, FLAUS and ICUS. *Ultraschall in Med* 2013; 34: 11 – 29
- [6] Dietrich CF, Averkiou MA, Correas JM et al. An EFSUMB introduction into Dynamic Contrast-Enhanced Ultrasound (DCE-US) for quantification of tumour perfusion. *Ultraschall in Med* 2012; 33: 344 – 351
- [7] Bamber J, Cosgrove D, Dietrich CF et al. EFSUMB guidelines and recommendations on the clinical use of ultrasound elastography. Part 1: Basic principles and technology. *Ultraschall in Med* 2013; 34: 169 – 184
- [8] Cosgrove D, Piscaglia F, Bamber J et al. EFSUMB guidelines and recommendations on the clinical use of ultrasound elastography. Part 2: Clinical applications. *Ultraschall in Med* 2013; 34: 238 – 253
- [9] Dietrich CF, Lorentzen T, Sidhu PS et al. An Introduction to the EFSUMB Guidelines on Interventional Ultrasound (INVUS). *Ultraschall in Med* 2015; 36: 460 – 463
- [10] Lorentzen T, Nolsoe CP, Ewertsen C et al. EFSUMB Guidelines on Interventional Ultrasound (INVUS), Part I. General Aspects (long Version). *Ultraschall in Med* 2015; 36: E1 – E14
- [11] Lorentzen T, Nolsoe CP, Ewertsen C et al. EFSUMB Guidelines on Interventional Ultrasound (INVUS), Part I. General Aspects (Short Version). *Ultraschall in Med* 2015; 36: 464 – 472
- [12] Sidhu PS, Brabrand K, Cantisani V et al. EFSUMB Guidelines on Interventional Ultrasound (INVUS), Part II. Diagnostic Ultrasound-Guided Interventional Procedures (Long Version). *Ultraschall in Med* 2015; 36: E15 – E35
- [13] Sidhu PS, Brabrand K, Cantisani V et al. EFSUMB Guidelines on Interventional Ultrasound (INVUS), Part II. Diagnostic Ultrasound-Guided Interventional Procedures (Short Version). *Ultraschall in Med* 2015; 36: 566 – 580

- [14] Dietrich CF, Lorentzen T, Appelbaum L et al. EFSUMB Guidelines on Interventional Ultrasound (INVUS), Part III – Abdominal Treatment Procedures (Short Version). *Ultraschall in Med* 2016; 37: 27–45
- [15] Dietrich CF, Lorentzen T, Appelbaum L et al. EFSUMB Guidelines on Interventional Ultrasound (INVUS), Part III – Abdominal Treatment Procedures (Long Version). *Ultraschall in Med* 2016; 37: E1–E32
- [16] Jenssen C, Hocke M, Fusaroli P et al. EFSUMB Guidelines on Interventional Ultrasound (INVUS), Part IV – EUS-guided interventions: General Aspects and EUS-guided Sampling (Short Version). *Ultraschall in Med* 2016; 37: 157–169
- [17] Jenssen C, Hocke M, Fusaroli P et al. EFSUMB Guidelines on Interventional Ultrasound (INVUS), Part IV – EUS-guided interventions: General aspects and EUS-guided sampling (Long Version). *Ultraschall in Med* 2016; 37: E33–E76
- [18] Fusaroli P, Jenssen C, Hocke M et al. EFSUMB Guidelines on Interventional Ultrasound (INVUS), Part V. *Ultraschall in Med* 2016; 37: 77–99
- [19] Jenssen C, Brkljacic B, Hocke M et al. EFSUMB Guidelines on Interventional Ultrasound (INVUS), Part VI – Ultrasound-Guided Vascular Interventions. *Ultraschall in Med* 2016; 37: 473–476
- [20] Cantisani V, Dietrich CF, Badea R et al. EFSUMB Statement on Medical Student Education in Ultrasound [long version]. *Ultrasound Int Open* 2016; 2: E2–E7
- [21] Cantisani V, Dietrich CF, Badea R et al. EFSUMB statement on medical student education in ultrasound [short version]. *Ultraschall in Med* 2016; 37: 100–102
- [22] Sidhu PS, Cantisani V, Deganello A et al. Role of Contrast-Enhanced Ultrasound (CEUS) in Paediatric Practice: An EFSUMB Position Statement. *Ultraschall in Med* 2017; 38: 33–43
- [23] Sidhu PS, Cantisani V, Deganello A et al. Reply: Role of Contrast-Enhanced Ultrasound (CEUS) in Paediatric Practice: An EFSUMB Position Statement. *Ultraschall in Med* 2017; (epub in advance)
- [24] Nylund K, Maconi G, Hollerweger A et al. EFSUMB Recommendations and Guidelines for Gastrointestinal Ultrasound – Part 1: Examination Techniques and Normal Findings (Long version). *Ultraschall in Med* 2016; (epub in advance)
- [25] Nylund K, Maconi G, Hollerweger A et al. EFSUMB Recommendations and Guidelines for Gastrointestinal Ultrasound – Part 1: Examination Techniques and Normal Findings (Short version). *Ultraschall in Med* 2016; (epub in advance)
- [26] EFSUMB. Education and Professional Standards Committee (EPSC). Minimum Training recommendations for the practice of medical ultrasound. *Ultraschall in Med* 2006; 27: 79–105
- [27] Dietrich CF, Rudd L. The EFSUMB website, a guide for better understanding. *Med Ultrason* 2013; 15: 215–223
- [28] Dietrich CF, Rudd L, Saftiou A et al. The EFSUMB website, a great source for ultrasound information and education. *Med Ultrason* 2017; 19: 102–110
- [29] Shiina T, Nightingale KR, Palmeri ML et al. WFUMB guidelines and recommendations for clinical use of ultrasound elastography: Part 1: basic principles and terminology. *Ultrasound Med Biol* 2015; 41: 1126–1147
- [30] Ferraioli G, Filice C, Castera L et al. WFUMB guidelines and recommendations for clinical use of ultrasound elastography: Part 3: liver. *Ultrasound Med Biol* 2015; 41: 1161–1179
- [31] Barr RG, Nakashima K, Amy D et al. WFUMB guidelines and recommendations for clinical use of ultrasound elastography: Part 2: breast. *Ultrasound Med Biol* 2015; 41: 1148–1160
- [32] Cosgrove D, Barr R, Bojunga J et al. WFUMB Guidelines and Recommendations on the Clinical Use of Ultrasound Elastography: Part 4. Thyroid. *Ultrasound Med Biol* 2017; 43: 4–26
- [33] Barr RG, Cosgrove D, Brock M et al. WFUMB Guidelines and Recommendations on the Clinical Use of Ultrasound Elastography: Part 5. Prostate. *Ultrasound Med Biol* 2017; 43: 27–48
- [34] Dietrich CF, Bamber J, Berzigotti A et al. EFSUMB Guidelines and Recommendations on the Clinical Use of Liver Ultrasound Elastography, Update 2017 (Long Version). *Ultraschall in Med* 2017; (epub in advance)
- [35] Dietrich CF, Bamber J, Berzigotti A et al. EFSUMB Guidelines and Recommendations on the Clinical Use of Liver Ultrasound Elastography, Update 2017 (Short Version). *Ultraschall in Med* 2017; (epub in advance)