

Prepectoral implant placement in plastic-reconstructive breast surgery – a contribution to the discussion

Präpektoriale Implantateinlage in der plastisch-rekonstruktiven Mammachirurgie – ein Diskussionsbeitrag



Authors

Stefan Paepke¹, Ralf Ohlinger², Evelyn Klein¹, Marc Thill³



Affiliations

- 1 Breast Centre of the Technical University of Munich, Germany
- 2 Breast Centre of the Ernst Moritz Arndt University of Greifswald, Germany
- 3 Obstetrics and Gynaecology Clinic, Breast Centre, Agaplesion Markus Hospital, Frankfurt am Main, Germany

Key words

implant-based breast reconstruction, synthetic meshes, titanised polypropylene mesh TiLoop®Bra and TiLoop®Bra-Pocket, prepectoral implant

Schlüsselwörter

implantbasierte Brustrekonstruktion, Synthetische Netze, titanisierte Polypropylen-Netze TiLoop®Bra und Tiloop®Bra-Pocket, präpektoriale Implantateinlage

Bibliography

DOI <https://doi.org/10.1055/s-0043-111747>

Senologie 2018; 15: 115–119

© Georg Thieme Verlag KG, Stuttgart · New York

ISSN 1611-6453

Correspondence

Dr. Stefan Paepke

Chief Physician: Senology

Breast Centre of the Technical University of Munich,

Ismaninger Strasse 22, 81675 Munich

stefan.paepke@rz.tu-muenchen.de

ZUSAMMENFASSUNG

Die implantatbasierten Rekonstruktionstechniken nehmen in den letzten Jahren national und international kontinuierlich zu und decken ein weites Spektrum rekonstruktiver Anforderungen ab. Die nipple-sparende subkutane Mastektomie mit subpektoraler Implantat-Sofortrekonstruktion stellt das derzeitige Standardverfahren dar. Diese Operationstechnik erfordert jedoch den Einsatz heterologener Materialien in Form von azellulären dermalen Matrices oder synthetischen Netzen, um eine optimale Implantatabdeckung, eine Stabilisierung des unteren Brustpols, die Stabilisierung des Implantats und die Fixierung des Muskels zu erreichen und somit ein opti-

males Ergebnis zu erzielen. Obwohl die subpektoriale Implantateinlage hinsichtlich der Sicherheit und der Kosmetik sehr gute Ergebnisse zeigt, erfährt die präpektoriale Implantateinlage derzeit eine Renaissance. Speziell für diese Rekonstruktionsmethode entwickelte Materialien [1] vereinfachen die Operationstechnik, und die durch die subpektoriale Implantatposition hervorgerufenen Nebenwirkungen wie das „Jumping-Breast-Phänomen“, Schmerzen, Beeinträchtigungen der Schulterfunktion und Risiken wie Blutungen können verringert werden. So ergänzen die Möglichkeiten der präpektoralen Implantateinlage das Gesamtspektrum der rekonstruktiven Operationen; eine sorgfältige Indikationsstellung und die Analyse der Operationsergebnisse sind erforderlich, um eine Gesamtbeurteilung zu ermöglichen.

ABSTRACT

Implant-based breast reconstruction has gained a high and increasing level of importance both nationally and internationally in recent years and covers a wide spectrum of reconstruction techniques. The standard procedure in nipple-sparing subcutaneous mastectomies is currently performed by placing the implant into a subpectoral pocket beneath the pectoralis muscle. The use of implant-based reconstructive techniques with the need for internal support to reconstruct the inframammary fold, to cover the implant at the lower pole and to provide a stable but flexible implant position has become relevant and led to the introduction of heterologous materials such as acellular dermal matrices and synthetic meshes. Although the safety and aesthetics of this approach have produced good results, prepectoral techniques add a whole new dimension with the development of the next generation of acellular dermal matrices and, especially, titanised implant pockets created specifically for prepectoral implant placement [1] have brought about a renaissance in muscle-sparing reconstructive techniques. These preserve the natural anatomy, thereby avoiding the adverse effects associated with submuscular reconstruction, including preservation of full shoulder function, minimising postoperative pain and the risk of bleeding and haematoma, and animation deformities such as “jumping breast phenomenon”. A new method of implant-based breast reconstruction is therefore available and must be analysed regarding indications and benefits.

Introduction

Throughout the year, many current aspects of plastic-reconstructive breast surgery have been discussed in a wide range of lectures and debates in various symposia on senology and surgery. Standards have been defined, perspectives offered, and the field has been opened up to possible further developments.

Detailed positions have been taken on:

- Indications
- Patient selection
- Anatomically correct surgical techniques with the use of intraoperative sonography to ensure surgical precision
- Complications and the possibility of avoiding or minimising them, as well as problem-solving alternatives
- Classification of surgical techniques
- National study data.

When considering the developments in implant-based reconstructive breast surgery of recent years, the following should be noted:

- Changes in basic oncological techniques, from radical to skin- and nipple-saving mastectomy techniques
- Highly-developed cooperation between professionals (senology, surgery, plastic surgery) in multi-disciplinary teams
- An increase in bilateral interventions, both primary and secondary prophylactic interventions
- An increase in reconstructive interventions in every age group, with an above-average increase in young women
- An increase in the number of implant-based, reconstructive interventions overall
- Widespread and safe use of autologous reconstruction techniques
- The introduction of newly-developed breast implants for reconstructive breast surgery
- The introduction of materials to bridge, substitute or support the tissues in reconstructive breast surgery since around 2008
- Further developments in materials to bridge, substitute or support the tissues, implemented in the German Working Group for Gynaecological Oncology's treatment recommendations since 2011
- The introduction of minimally invasive surgical techniques
- Additional tools for intraoperative safeguarding of skin perfusion

Implant-based plastic-reconstructive breast surgery

Implant-based techniques constitute approximately 40–60% of all breast reconstructions in Europe and approximately 75% in the USA [2–4]. It is therefore not surprising that implant-based breast surgery modifications of implant-based reconstructions is a subject of discussion in interdisciplinary knowledge exchange. The performance of a subcutaneous mastectomy within anatomical limits [5–7] and the optimal design of the implant bed have been specified. In this context, the surgical separation plane of

the pectoralis major muscle, which is used for the cranial covering of the implant, has also been defined [8–10].

Subpectoral implant placement was the previous standard method of implant-based reconstruction, either with

- exclusive skin coverage (mostly as an interim solution until the definitive reconstruction is specified)
- complete muscle coverage
- dual-plane method with a de-epithelised corial flap
- caudo-lateral interponation of an acellular matrix
- caudo-lateral interponation of a synthetic mesh
- combination techniques.

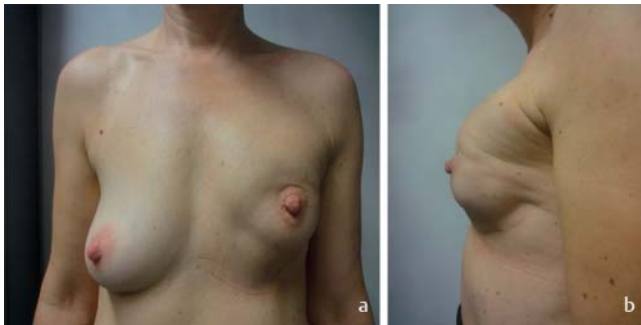Complication types and rates are described in many analyses, although these are mainly retrospective [11, 12]. The few prospective studies largely support the findings of the retrospective analyses. To summarise: it can be said that the use of both synthetic meshes and of acellular dermal and tissue matrices can be considered safe [1, 13–15]. The use of synthetic meshes seems to have few complications with regard to seroma formation and implant loss [10]. A single prospective, directly comparative study has shown that titanised polypropylene mesh (Tilloop® Bra) has an advantage over the porcine acellular dermal matrix Strattice™ regarding both the complication rate and the aesthetic result [16]. Newly-developed dermal matrices display a low rate of side effects in first application and will be analysed further in studies and registries.

Besides the question of the optimum material, the question of paramount importance regarding the implant bed is: pre- or sub-pectoral?

A large number of sometimes significant problems are caused by what is regarded as the standard placement of the subpectoral implant (► **Fig. 1**):

- unnatural breast shapes to some extent
- the “jumping breast” phenomenon
- muscle response even with less expansive movements
- muscle pain
- contraction of the upper exterior of the severed pectoralis major muscle with wrinkle formation below the muscle origin.
- fasciculations
- restricted shoulder-arm mobility.

It must be considered, however, that in the past, a prepectoral implant placement exclusively covered by remaining skin led to changes in the subpectoral implant placement due to the high rate of complications. Current data shows the limitations of prepectorally placed implants, which presuppose per se a very thick layer of subcutaneous fat that must be considered critical from the oncological perspective [17]. However, Sigalove et al. [18] report that over 207 patients have been operated on since 2008, all for prepectoral implant placements, ADM covering and lipofilling (“bio-engineered breast concept”) in 353 operations. The complication rate is remarkably low; infections occurred in 4.5% of cases, seromas in only 2% and flap necroses in 2.5%. The authors explain that the contraindications to a prepectoral implant placement arise with thin, poorly perfused or ischaemic skin, in response to previous radiotherapy in conjunction with a scar in the lower pole or in the region of the radiation boost, with a BMI



► **Fig. 1** A 34-year-old patient, 7 months post subcutaneous mastectomy (status post primary chemotherapy, status post radiotherapy). Immediate reconstruction using subpectoral implant placement with caudal mesh interposition. Currently with grade III capsular contracture, implant cranialisation and empty volume in the caudal quadrants.

of >40, in immunosuppressed patients, with HBA1c >7.5%, due to nicotine abuse or too little fat tissue for subsequent lipofilling. In the opinion of the authors, and from the oncological viewpoint, contraindications include breast carcinomas of >5 cm, advanced or deep-lying breast carcinomas, breast wall infiltration, extensive nodal involvement and a high risk of local relapse. However, the discussion also contains a critical assessment of whether the oncologically determined contraindications are based on assumptions. From our perspective, these restrictions do not exist.

Thus, in our experience, the prepectoral mesh-supported implant placement increases continuously, after initial considerations and surgery. This is partly due to a learning curve now having been completed and the related increase in the reliability of patient selection; another reason is that aesthetic deficits such as the development of volume defects and dents, and the visibility of the cranial implant edge due to the increased use of lipofilling, can now be compensated for. Thus, in our view, an important counter-argument against prepectoral implant placement no longer categorically applies. The publication of cases, case series and retrospective analyses shows that the prepectoral implant bed has also increasingly been used in German-speaking countries for several years [19, 20]. At this year's German Senology Society Conference, R. Reitsamer et al. presented in a free lecture a surgical procedure that included the formation of a complete implant sheath from an ADM, more specifically from the porcine ADM Strattice® – a procedure which is likely to be problematic from the perspective of health economics. Preference is often given to ADMs when considering prepectoral implant placements, as the benefit of tissue substitution is ascribed to them, resulting in better coverage of the cranial parts of the breast. Meanwhile, different manufacturers have responded to the special requirements of prepectoral implant placement by developing new forms using known materials. Pre-formed ADM materials such as Braxton (DecomedSrl, Italy) [21] can be used directly as implant pockets and other ADMs such as Tutomesh or Strattice and Artia can be used to shape the contours. Other ADMs, to the best of our knowledge, are not shaped but are squarer. H. Becker et al. [22] use both different synthetic meshes and ADMs to cover the implant completely in a prepectoral implant placement.

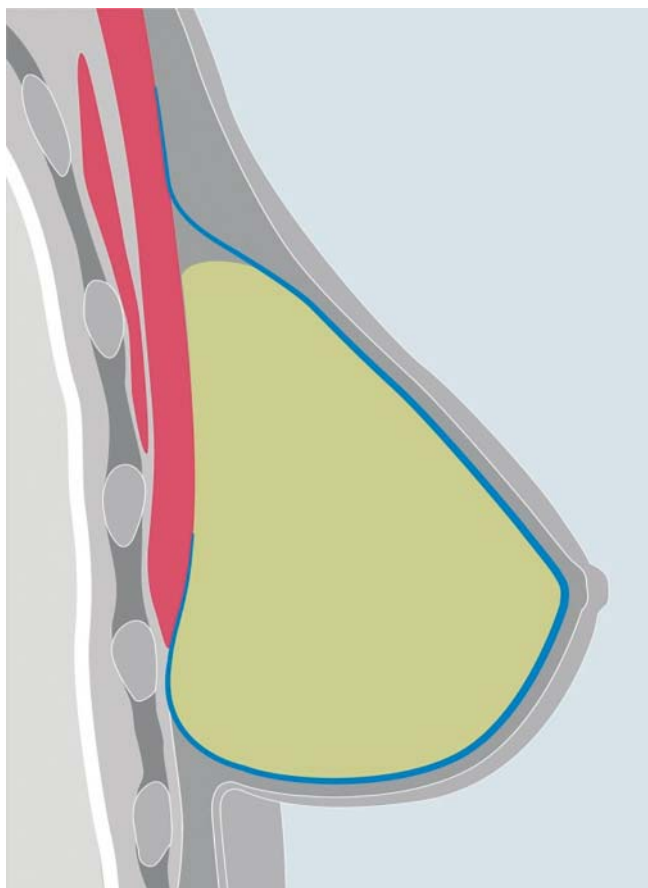


► **Fig. 2** Synthetic mesh specially designed for prepectoral implant placement (TiLoop® Bra Pocket) Source: pfm medical AG, Cologne.

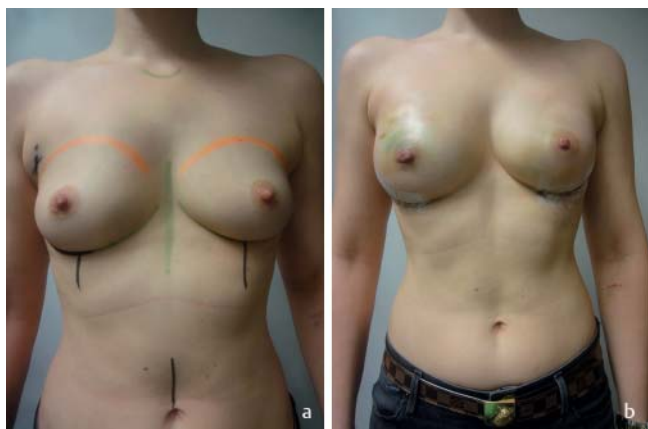
The authors of this discussion contribution also use synthetic meshes to cover prepectorally positioned implants just as frequently as ADMs and tissue matrices [23]. Similarly, some patients with epipectoral implant placement and TiLoop® Bra coverage were included and evaluated in the PRO Bra-Trial [24, 25]. Observations of possible complications and problems also arise from this experience in individual cases. New materials are also being developed in the field of synthetic meshes. Building on the experience of D. Casella et al. [26] and M. Rezaei, a titanised polypropylene implant pocket was developed, considerably simplifying prepectoral implant placement with a full covering of titanium mesh (► **Fig. 2, 3**).

Three different implant pockets are available, enabling incremental implant volumes of <270, <420 and <550 cm³ and implant widths from 11.0 to 15.0 cm with projections of <4.5 to <6.0 cm. In addition to the already frequent use of the TiLoop® Bra pocket in Italy, different breast centres across Germany have used it on approximately 60 occasions (► **Fig. 4**).

To summarise the considerations regarding the individual decision for a prepectoral implant placement from the authors' point of view, the following factors present themselves: from the patient's perspective, her own wishes are naturally paramount. More objective characteristics may be found, on the one hand, in a physically active, non-smoking patient with a BMI of <35, firm or slightly sagging skin with no striae distensae or current long-term systemic cortisone treatment, with mild or moderate ptosis and a resection weight of under 500 g. On the other hand, patients with glandular bodies in subinvolution and very flat cleavage that a submuscular implant placement would reconstruct in too accentuated a fashion may also benefit from prepectoral implant placement [27–32]. Intraoperative decision criteria would be good skin thickness with subcutaneous fat folds guaranteeing a good implant coverage in all quadrants, meaning that the risk of later dents or defects can be assumed to be low, and unrestricted skin



► **Fig. 3** A schematic drawing of the implant sheath through the synthetic mesh (blue). The mesh covers the whole of the front surface and approx. half of the rear surface of the implant. The mesh is sutured in the cranial mesh sections with soft tissue over, or to the pectoral fascia. Source: pfm medical AG, Cologne.



► **Fig. 4** A 31-year-old patient with TNBC, BRCA-1 positive, status post primary chemotherapy in complete remission according to imaging. Preoperatively, and on the 10th day postoperatively, post bilateral subcutaneous mastectomy, right SLNB with immediate reconstruction by prepectoral implant placement. The augmentative aspect was desired.

perfusion. These criteria are admittedly rather soft and do not allow any clear preference. It therefore remains a question of experience in conjunction with the individual learning curve that will guide the consultation with the patient.

Concluding remarks

When reviewing the current developments in reconstructive breast surgery, it is striking that the basic strategies have been or are covered by retrospective analyses and an increasing number of prospective studies and data from registers, and are reflected in the respective evidence level of the German Working Group for Gynaecological Oncology's treatment recommendations. This provides a high degree of user safety. Patient satisfaction regarding the cosmetic result reaches 80–90% and the complications rate is absolutely acceptable. Nevertheless, the optimisation of autologous and implant-based reconstructive surgical techniques must remain the focus. The consideration of which implant bed is to be preferred in the context of individual surgery planning will be rendered much simpler by the introduction of advanced materials. Indications and complications should be recorded in the registers.

Conflict of interest

The authors will declare any conflicts of interest (honorary activities, travel and conference support, support for scientific events).

References

- [1] Cassella D, Calabrese C, Bianchi S et al. Subcutaneous Tissue Expander Placement with Synthetic Titanium Coated Mesh in Breast Reconstruction: Long-term Results. PRSGlobalOpen 2015. doi:10.1097/GOX.0000000000000549
- [2] American Society of Plastic Surgeons. Plastic surgery statistics report. 2015 <http://www.plasticsurgery.org./news/plastic-surgery-statistics>; Accessed: Nov13; 2016
- [3] Serdetti JM, Fosnot J, Nelson JA et al. Breastreconstruction after breast-cancer. *Plast Reconstr Surg* 2011; 127: 124e–135e
- [4] Albernoz CR, Bach PB, Mehrars BJ. A paradigm shift in U.S. breast reconstruction increasing implant rates. *Plast Reconstr Surg* 2013; 131: 15–23
- [5] Drabble EH, Osborne CLE, Wu E. Skin sparing mastectomy – how thorough can breast tissue removal be? *Breast Canc Res Treatm* 2006 (Suppl. 1): 121 abstr 2121
- [6] Carlson GW, Bostwick JIII, Styblo T et al. Skin sparing mastectomy: Oncologic and reconstructive considerations. *Ann Surg* 1997; 225: 570–575
- [7] Gerber B, Krause A, Makovitzky J et al. Skin sparing mastectomy (SSM) with conservation of the nipple-areola-complex (NAC) and autologous reconstruction is an oncologically safe procedure. *Breast Canc Res Treatm* 2006 (Suppl. 1): 120 abstr 2116
- [8] Paepke S, Schmid R, Paepke D et al. Early results of nipple-areola-sparing subcutaneous mastectomy (NASSM) with complete resection of the retroareolar ductal system. *Breast Canc Res Treatm* 2005; 94 (1): 112 abstract 2081

- [9] Paepke S, Schmid R, Fleckner S et al. Subcutaneous mastectomy including conservation of the nipple areola complex: broadening the indications. *Breast Canc Res Treatm* 2006 (Suppl. 1): 122 abstr 2122
- [10] Paepke S, Schmid R, Fleckner S et al. Subcutaneous mastectomy with conservation of the nipple-areola-skin: broadening the indications. *Ann Surg* 2009; 250 (2): 288–292
- [11] Rezaei M, Strauß S, Kimmig R et al. Risk-reducing, conservative mastectomy – analysis of surgical outcome and quality of life in 272 implant-based reconstructions using Tiloop®Bra versus autologous corial flaps. *Gland Surg* 2016; 5 (1): 1–8
- [12] Dieterich M, Paepke S, Zwiefel K et al. Implant-based breast reconstruction using a titanium-coated polypropylene mesh (TiLOOP Bra): a multicenter study of 231 cases. *Plastic and Reconstructive Surgery* 2013; 132 (1): 8e–19e
- [13] Dieterich M, Stubert J, Gerber B et al. Biocompatibility, cell growth and clinical relevance of synthetic meshes and biological matrixes for internal support in implant-based breast reconstruction. *Arch Gynecol Obstet* 2015; 291: 1371–1379
- [14] Derderian CA, Karp NS, Choi M. Wise pattern breast reconstruction: Modification using AlloDerm and a vascularized dermal-subcutaneous pedicle. *Ann Plast Surg* 2009; 62: 528–532
- [15] Gamboa-Bobadilla GM. Implant breast reconstruction using acellular-dermismatrix. *Ann Plast Surg* 2006; 56: 22–25
- [16] Gschwantler-Kaulich D, Schrenk P, Bjelic-Radisic V et al. Mesh versus acellular dermal matrix in immediate implant-based breast reconstruction – A prospective randomized trial. *EJSO*. 2016
- [17] Salibian AH, Harness JK, Mowlds DS. Staged Suprapectoral Expander/Implant Reconstruction without Acellular Dermal Matrix following Nipple-Sparing Mastectomy. *Plast Reconstr Surg* 2016. doi:10.1097/PRS.0000000000002845
- [18] Sigalove S, Maxwell PG, Sigalove Noemi M et al. Prepectoral implant-based breast reconstruction: Rationale, Indications, and Preliminary Results. *Plast Reconstr Surg* 2017; Vol 139) Number 2: 287–294
- [19] Paepke S, Klein E, Krol J et al. Subpectoral implants in oncoplastic-reconstructive breast surgery – habit or necessity? First experience with epipectoral implant positioning covered by acellular dermis and meshes. *Jahrestagung der Association of British Breast Surgeons*. 2012
- [20] Reitsamer R, Peintinger F. Prepectoral implant placement and complete coverage with porcine acellular dermal matrix: a new technique for direct-to-implant breast reconstruction after nipple-sparing mastectomy. *J Plast Reconstr Aesthet Surg* 2015; 68 (2): 162–167. doi: 10.1016/j.bjps.2014.10.012. Epub 2014 Oct 16. PMID: 25455288
- [21] Vidya R, Masia J, Cawthorn S et al. Evaluation of the effectiveness of the prepectoral breast reconstruction with Braxon dermal matrix: First multicenter European report on 100 cases. *The Breast Journal* 2017. doi:10.1111/tbj.12810
- [22] Becker H, Lind JG 2nd, Hopkins EG. Immediate Implant-based Prepectoral Breast Reconstruction Using a Vertical Incision. *Plast Reconstr Surg Glob Open* 2015; 3 (6): e412. doi: 10.1097/GOX.0000000000000384. eCollection 2015 Jun. PMID: 26180713
- [23] Paepke S et al. Einsatz porciner azellulärer Dermis (Strattice™) als gewebeeretzendes und unterstützendes Interponat zur Implantatabdeckung bei problematischen Weichteilverhältnissen in der plastisch-rekonstruktiven Mammachirurgie. *Senologie – Zeitschrift für Mammadiagnostik und -therapie*. 2012
- [24] Paepke S, Riemann A, Dittmer S et al. Patient-Reported-Outcome (PRO: Vergleichsuntersuchungen bei Patientinnen mit implantatbasiereten materialunterstützten Mammaoperationen. *Jahrestagung der Deutschen Gesellschaft für Senologie*. 2016: PO73
- [25] Paepke S, Kiechle M, Ankel C et al. Patient reported outcome measures (PROMs) in implant-based mesh-supported breast reconstruction – eraly results of a multicentre prospective trial. *Deutsche Gesellschaft für Senologie*. 2015
- [26] Cassella D, Calabrese C, Bianchi S et al. Subcutaneous tissue expander placement with synthetic titanium-coated mesh in breast reconstruction: longterm results. *PRS GlobalOpen*; 2015. doi:10.1097/GOX/.0000000000000549
- [27] Casella D, Bernini M, Bencini L et al. TiLoop® Bra mesh used for immediate breast reconstruction: comparison of retropectoral and subcutaneous implant placement in a prospective single-institution series. *Eur J Plast Surg* 2014; 37 (11): 599–604 Epub 2014 Aug 3. PMID: 25339795
- [28] Sbitany H, Piper M, Lentz R. Prepectoral Breast Reconstruction: A Safe Alternative ToSubmuscularProstheticReconstruction Following Nipple Sparing Mastectomy. *Plast Reconstr Surg* 2017. doi:10.1097/PRS.0000000000003627. PMID:28574
- [29] Salibian AH, Harness JK, Mowlds DS. Staged Suprapectoral Expander/Implant Reconstruction without Acellular Dermal Matrix following Nipple-Sparing Mastectomy. *Plast Reconstr Surg* 2017; 139 (1): 30–39 10.1097/PRS.0000000000002845. PMID: 28027223
- [30] Caputo GG, Marchetti A, DallaPozza E et al. Skin-Reduction Breast Reconstructions with Prepectoral Implant. *Plast Reconstr Surg* 2016; 137 (6): 1702–1705 10.1097/PRS.0000000000002227. PMID: 27219226
- [31] Casella D, Calabrese C, Bianchi S et al. Subcutaneous Tissue Expander Placement with Synthetic Titanium-Coated Mesh in Breast Reconstruction: Long-term Results. *Plast Reconstr Surg Glob Open* 2016; 3 (12): e577. doi: 10.1097/GOX.0000000000000549. eCollection 2015 Dec. PMID: 26894002
- [32] Bernini M, Calabrese C, Cecconi L et al. Subcutaneous Direct-to-Implant Breast Reconstruction: Surgical, Functional, and Aesthetic Results after Long-Term Follow-Up. *Plast Reconstr Surg Glob Open* 2016; 3 (12): e574. doi: 10.1097/GOX.0000000000000533. eCollection 2015 Dec. PMID: 26893999