Thieme

Successful endoscopic closure of a refractory button-battery tracheoesophageal fistula in a 3-year child using endoscopic submucosal dissection of the surrounding mucosa

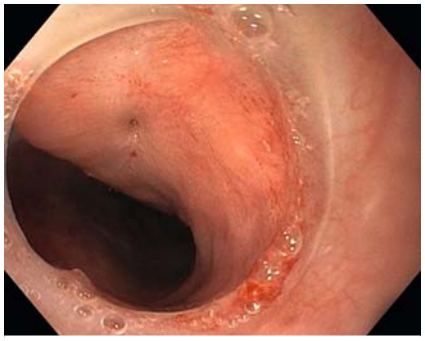

▶ **Fig. 1** Appearance of the tracheoesophageal fistula in a 3-year-old girl after ingestion of a button battery.

Most serious button-battery ingestions are not witnessed and they can cause life threatening complications.

We present here the case of a 3-year-old girl who swallowed a button battery in January 2016 with a delayed diagnosis being made after 10 days. A 5-mm tracheoesophageal fistula was endoscopically diagnosed (▶ **Fig. 1**). The first attempts at closure involved the deployment of two successive esophageal covered stents between January and May (▶ **Fig. 2**). The fistula decreased in size but persisted, so we then attempted controlled wound healing with a nasogastric tube, but the fistula still remained. Next, we tried a side fistula abrasion with argon plasma coagulation. Unfortunately, these techniques did not allow full recovery, even though the fistula reduced notably.

After 1 year, we tried endoscopic submucosal dissection (ESD) of the mucosa surrounding the fistula, resecting a 1-cm mucosal patch centered on the fistula. After injecting the submucosa and making the mucosal incision, we used a Dual-Knife (Olympus) to dissect the fibrotic area. After the dissection, the fistula was closed with three clips anchored into the submucosa of the resected area (▶ **Fig. 3**; ▶ **Video 1**). We arranged a radiologic check with contrast, which

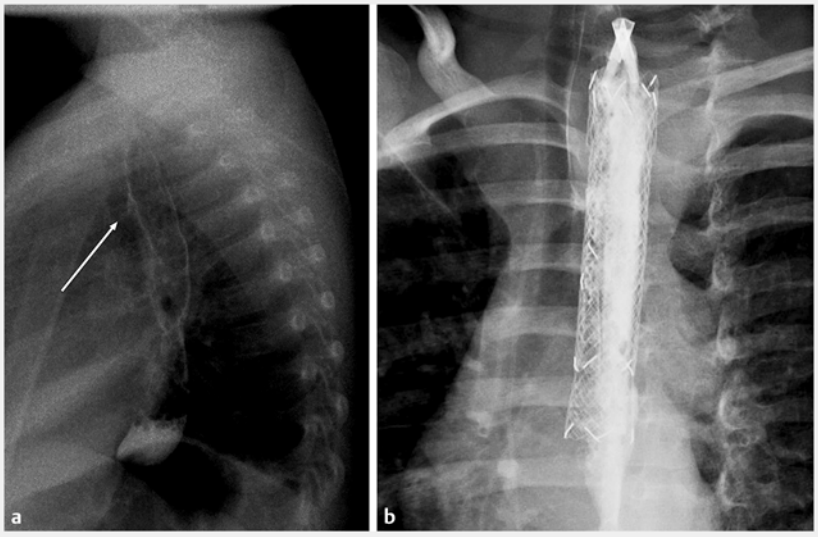

▶ **Fig. 2** Radiographic images showing: **a** the fistula on a barium swallow; **b** the first attempted closure procedure with a stent positioned in the esophagus.

▶ **Video 1** Views of the fistula and previous attempts to close it. The endoscopic submucosal dissection procedure is performed to resect the surrounding mucosa, which is subsequently clipped to close the fistula.

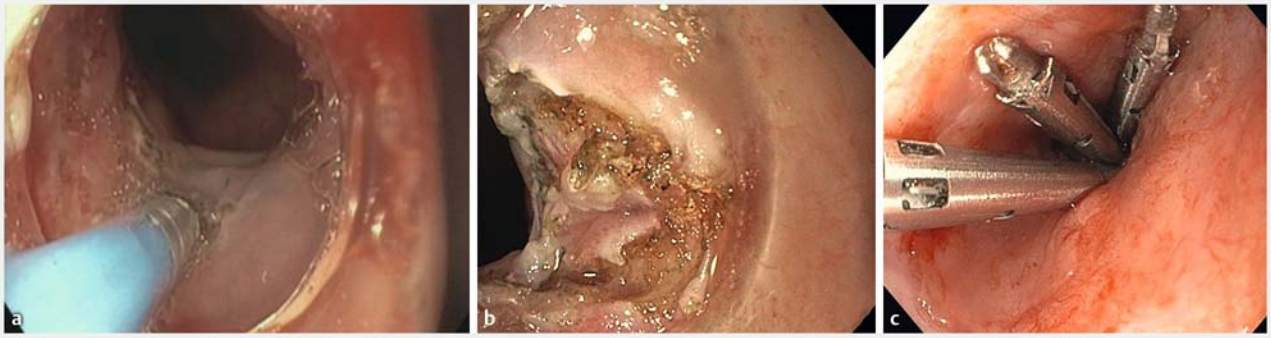

▶ **Fig. 3** Endoscopic images showing the endoscopic submucosal dissection procedure: **a** the submucosal injection being performed; **b** the incision and dissection of the fibrosis; **c** clips placed in the submucosa.

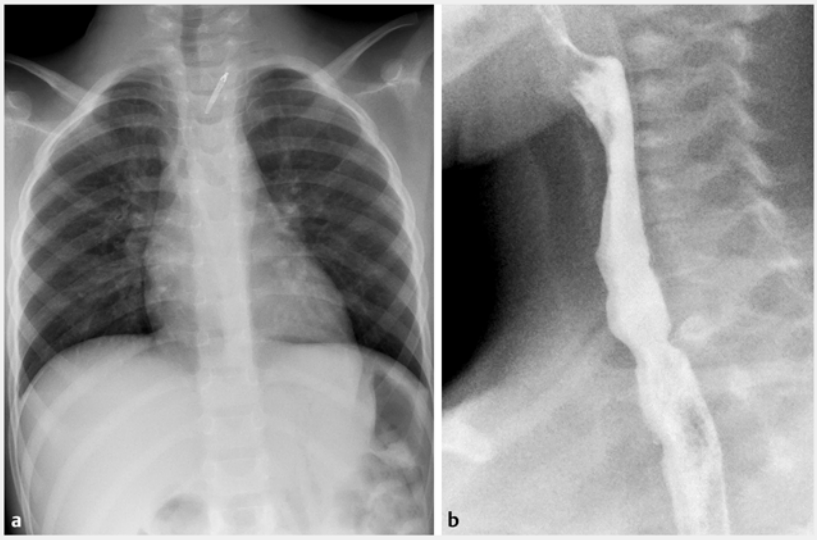

▶ **Fig. 4** Follow-up imaging. **a** Chest radiograph 2 weeks later. **b** Barium swallow 3 months later.

showed no sign of a fistula in the tracheal tract, and the girl made good and rapid progress without pain. A barium swallow 5 days later showed no signs of the fistula, and she was able to eat again. At 3 months after the procedure, a barium swallow and laryngoscopy confirmed complete healing of the fistula (▶ **Fig. 4**). The current management of tracheoesophageal fistula after button-battery ingestion is not well defined and, although some studies have demonstrated the role of conservative treatment [1], the place of endoscopy is not known. In all kind of fistulas, stent placement only permits healing in 53 % [2]. ESD can be key in non-surgical treatment to achieve complete closure of such chronic fistulas, as was previously also shown by Rodriguez-Lago et al. [3].

Endoscopy_UCTN_Code_TTT_1AO_2AI

Competing interests

None

The Authors

Melissa Gruner[1], Sophie Heissat[2], Vincent Pitiot[3], Paul Suy[4], Alain Lachaux[2], Thierry Ponchon[1,5], Mathieu Pioche[1,5]

1 Department of Endoscopy and Gastroenterology, Pavillon L, Edouard Herriot Hospital, Lyon, France
2 Department of Pediatric Endoscopy and Gastroenterology, Hôpital Femme Mère Enfant, Lyon, France
3 Department of Pediatric Digestive Surgery, Hôpital Femme Mère Enfant, Lyon, France
4 Department of Pediatric ENT, Hôpital Femme Mère Enfant, Lyon, France
5 Inserm U1032 LabTau, Lyon, France

Corresponding author

Mathieu Pioche, MD
Endoscopy unit – Digestive Disease department, Pavillon L – Edouard Herriot Hospital, 69437 Lyon, France
mathieu.pioche@chu-lyon.fr

References

[1] Grisel JJ, Richter GT, Casper KA et al. Acquired tracheoesophageal fistula following disc-battery ingestion: can we watch and wait? Int J Pediatr Otorhinolaryngol 2008; 72: 699 – 706

[2] Silon B, Siddiqui AA, Taylor LJ et al. Endoscopic management of esophagorespiratory fistulas: a multicenter retrospective study of techniques and outcomes. Dig Dis Sci 2017; 62: 424 – 431

[3] Rodríguez-Lago I, Schroeven M, Rodenstein D et al. Endoscopic closure of tracheoesophageal fistula with submucosal dissection and a biosynthetic mesh. Endoscopy 2015; 47: E312 – E313

Bibliography

DOI https://doi.org/10.1055/s-0043-113549
Published online: 29.6.2017
Endoscopy 2017; 49: E212–E214

ISSN 0013-726X