Thieme

Simultaneous duodenal stenting and endoscopic ultrasound-guided hepaticogastrostomy using a forward-oblique view echoendoscope

A 65-year old man with advanced pancreatic cancer with a combination of malignant biliary obstruction and gastric outlet obstruction was referred to our hospital. Given the presence of periampullary cancerous lesions, the endoscopic placement of a duodenal stent and endoscopic ultrasound (EUS)-guided hepaticogastrostomy (HGS) were performed simultaneously, using a single convex-array echoendoscope with a forward-oblique view (EG-580T; Fujifilm, Tokyo, Japan; ▶ **Fig. 1**). A partially covered metal duodenal stent (Niti-S COMVI; Taewoong Medical, Gimpo, Korea) was placed under fluoroscopic and endoscopic guidance (▶ **Fig. 2**, ▶ **Video 1**). This was followed, without scope exchange, by EUS-HGS: a long partially covered metal stent (modified GIOBOR, Taewoong Medical) was successfully placed [1] from the B3 intrahepatic duct to the stomach under EUS, endoscopic, and fluoroscopic guidance (▶ **Fig. 3**, ▶ **Video 2**). The total procedure time was 38 minutes.

Combined malignant biliary obstruction and gastric outlet obstruction are not rare in advanced pancreatic cancer and EUS-guided biliary drainage, especially

▶ **Fig. 1** The new forward-oblique view convex-array echoendoscope, with 40° forward viewing direction.

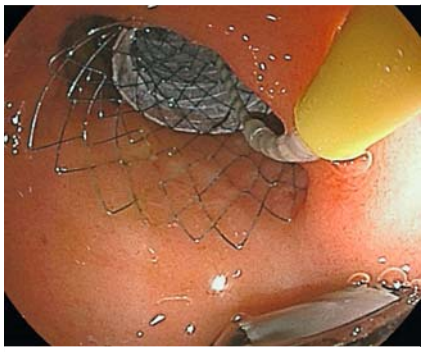

▶ **Fig. 2** Duodenal stent placement, using the new forward-oblique view echoendoscope, in a patient with advanced pancreatic cancer and a combination of malignant biliary obstruction and gastric outlet obstruction.

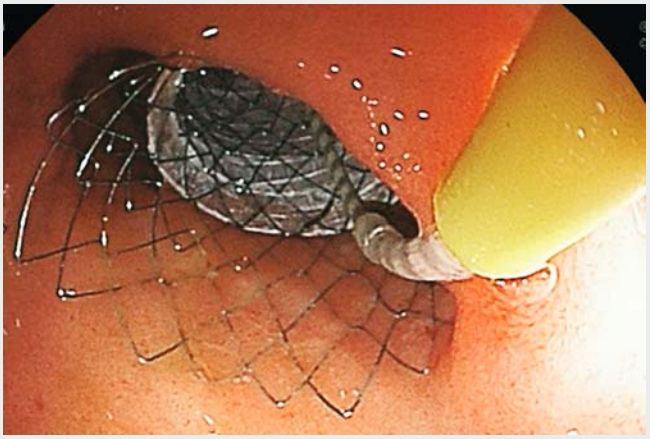

Video 1 Part 1. Simultaneous duodenal stenting and endoscopic ultrasound-guided hepaticogastrostomy (EUS-HGS) using a forward-oblique view echoendoscope. A partially covered metal duodenal stent is placed under fluoroscopic and endoscopic guidance.

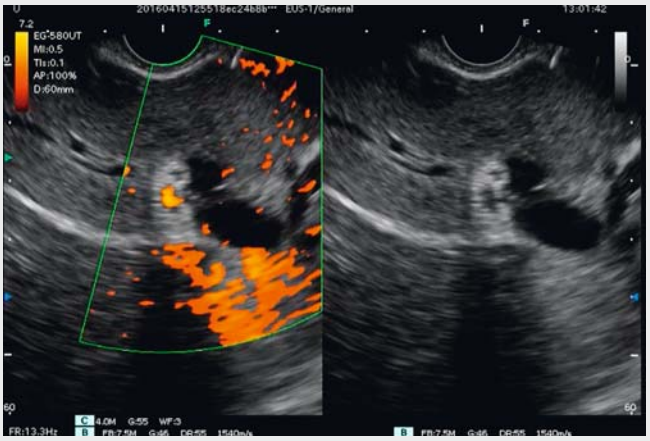

Video 2 Part 2. Simultaneous duodenal stenting and endoscopic ultrasound-guided hepaticogastrostomy (EUS-HGS). In the subsequent (EUS-HGS), done without scope exchange, a long partially covered metal stent is deployed from the B3 intrahepatic duct to the stomach under EUS, endoscopic, and fluoroscopic guidance.

This document was downloaded for personal use only. Unauthorized distribution is strictly prohibited.

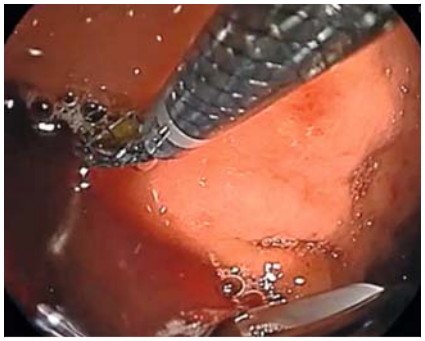

▶ **Fig. 3** Endoscopic ultrasound-guided hepaticogastrostomy (EUS-HGS) performed, without scope exchange, immediately after the duodenal stent placement shown in ▶ **Fig. 2**. The tip of the echoendoscope and the puncture site were seen endoscopically, enabling stent insertion and deployment under direct visualization.

EUS-HGS [2], is increasingly reported because of its better patency than transpapillary biliary drainage [3]. Conventionally, enteric stents are placed using a forward-viewing endoscope and EUS-guided biliary drainage by an oblique-viewing echoendoscope. A single-session dual-stent placement using two endoscopes has been described [4].

This new echoendoscope with a forward-oblique view has a 3.8-mm operating channel, and has a 40° forward viewing direction with 140° field of view compared to the 55° viewing direction and 100° field of view in the conventional oblique-viewing echoendoscope [5]. This enables the direct visualization of both the enteric stricture and the enteric stent deployment, and also helps hepaticogastrostomy with EUS-guided biliary drainage stent deployment with endoscopic guidance. Thus a single echoendoscope can be used to place a duodenal stent and an EUS-guided biliary drainage stent.

In conclusion, the simultaneous placement of a duodenal stent and EUS-HGS is feasible using the new forward-oblique view echoendoscope, facilitating shorter procedure time without the need for scope exchange.

Endoscopy_UCTN_Code_TTT_1AS_2AD

Competing interests

Hiroyuke Isayama and Yousuke Nakai have financial relationships with Fujifilm Corp. in the form of research support and/or honoraria.

The Authors

Tanyaporn Chantarojanasiri[1,2], Hiroyuki Isayama[1], Yousuke Nakai[1], Saburo Matsubara[1], Suguru Mizuno[1], Hirofumi Kogure[1], Kazuhiko Koike[1]

1 Department of Gastroenterology, the University of Tokyo, Tokyo, Japan
2 Department of Internal Medicine, Police General Hospital, Bangkok, Thailand

Corresponding author

Hiroyuki Isayama, MD, PhD
Department of Gastroenterology, Graduate School of Medicine, The University of Tokyo, 7-3-1 Hongo, Bunkyo-ku, Tokyo 113-8655, Japan
Fax: +81-3-3814-0021
isayama-tky@umin.ac.jp

References

[1] Nakai Y, Isayama H, Yamamoto N et al. Safety and effectiveness of a long, partially covered metal stent for endoscopic ultrasound-guided hepaticogastrostomy in patients with malignant biliary obstruction. Endoscopy 2016; 48: 1125 – 1128. Epub 2016 Oct 7
[2] Ogura T, Chiba Y, Masuda D et al. Comparison of the clinical impact of endoscopic ultrasound-guided choledochoduodenostomy and hepaticogastrostomy for bile duct obstruction with duodenal obstruction. Endoscopy 2016; 48: 156 – 163
[3] Hamada T, Isayama H, Nakai Y et al. Transmural biliary drainage can be an alternative to transpapillary drainage in patients with an indwelling duodenal stent. Dig Dis Sci 2014; 59: 1931 – 1938
[4] Kawakubo K, Isayama H, Nakai Y et al. Simultaneous duodenal metal stent placement and EUS-guided choledochoduodenostomy for unresectable pancreatic cancer. Gut Liver 2012; 6: 399 – 402
[5] Murad FM, Komanduri S, Abu Dayyeh BK et al. Echoendoscopes. Gastrointest Endosc 2015; 82: 189 – 202

Bibliography
DOI https://doi.org/10.1055/s-0043-116379
Published online: 5.9.2017
Endoscopy 2017; 49: 1109–1110
© Georg Thieme Verlag KG
Stuttgart · New York
ISSN 0013-726X

ENDOSCOPY E-VIDEOS
https://eref.thieme.de/e-videos

Endoscopy E-Videos is a free access online section, reporting on interesting cases and new techniques in gastroenterological endoscopy. All papers include a high quality video and all contributions are freely accessible online.

This section has its own submission website at https://mc.manuscriptcentral.com/e-videos

This document was downloaded for personal use only. Unauthorized distribution is strictly prohibited.