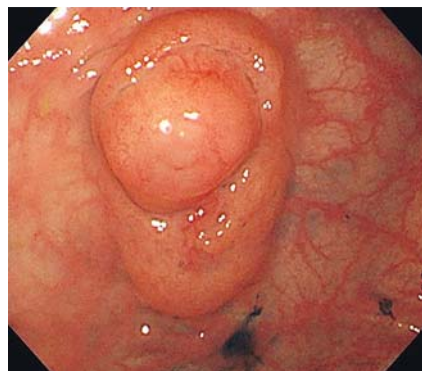
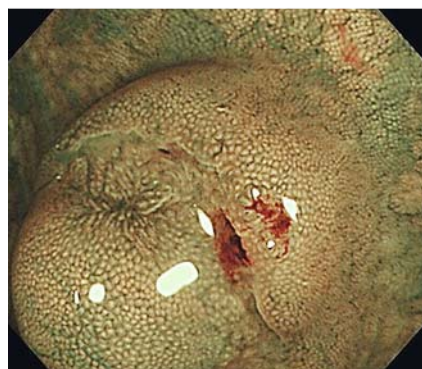

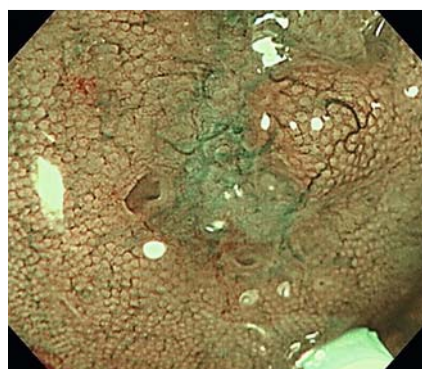
Endoscopic submucosal dissection for a heterotopic gland in the transverse colon



► **Fig. 1** Endoscopic image of a submucosal tumor in the transverse colon of a 62-year-old man. The lesion is elevated in the center and surrounded by a slit.



► **Fig. 2** Narrow band imaging shows that the margin of the lesion rises smoothly and is covered with normal mucosa.



► **Fig. 3** Magnification endoscopy with narrow-band imaging shows an open duct in part. There are thick, meandering vessels, and the mucosal structure has become unclear.

It is rare for ectopic gastric mucosa to develop in the colorectum, and there are few reported cases [1–3]. To the best of our knowledge, there are no case reports of a heterotopic gland in the colon.

A 62-year-old man experiencing weight loss had undergone total colonoscopy. A submucosal tumor (25 mm) was detected in the transverse colon. The lesion was elevated in the center and surrounded by a slit (► **Fig. 1**). Narrow band imaging showed that the margin of the lesion rose smoothly, and was covered with non-neoplastic mucosa (► **Fig. 2**). In the center of the lesion, an open crypt could be partly seen. With magnification endoscopy, thick, meandering vessels were seen and the mucosal structure became unclear. (► **Fig. 3**). Biopsy specimens of the lesion revealed non-neoplastic mucosa, and so, to allow a conclusive diagnosis, en bloc endoscopic submucosal resection was done (► **Video 1**).

Histopathologically, a heterotopic gland was detected in the specimen from the colon. An almost normal crypt or inverted mucosa was observed in the submucosal layer. The muscularis mucosae re-

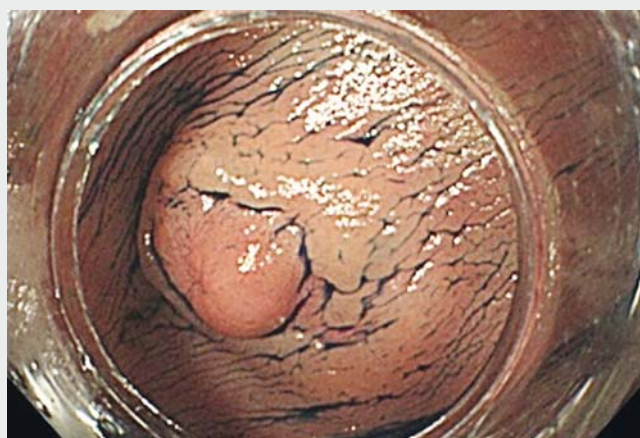mained, even though a slight gap was observed in antidesmin antibody immunohistochemical staining. In the parts lacking muscularis mucosae, the crypts of the lamina propria penetrated into the submucosal tissue (► **Fig. 4a**). A high power view of the crypt showed an almost normal feature with partial dilatation in the submucosa (► **Fig. 4b**).

The etiology of the heterotopic gland in the colon is unknown; we speculated that it was similar to the development of an ectopic gland in the stomach. In this case, the mucosal layer may have been inverted to the submucosa. Additionally, part of the superficial gland was atrophied and fibrosis was present. On the basis of these pathological findings, we speculate that this heterotopic gland may have developed in an acquired process caused by some inflammation.

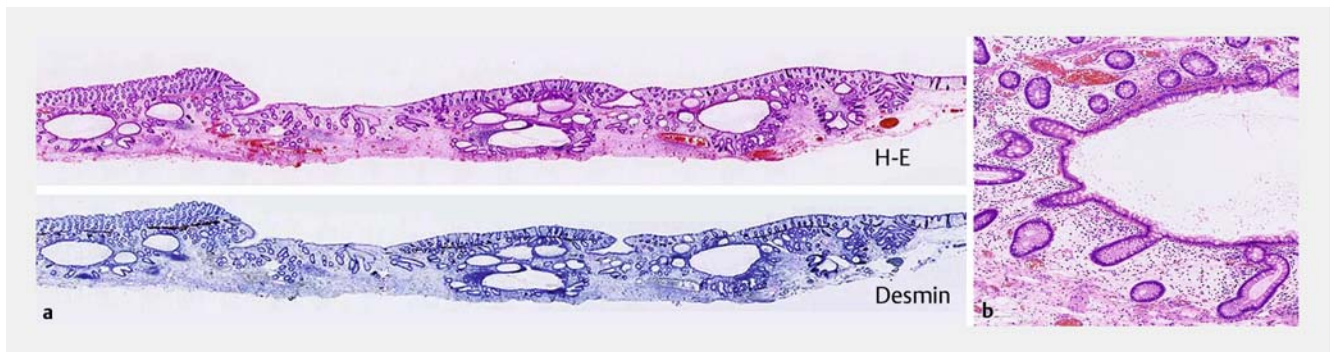
Endoscopy_UCTN_Code_CCL_1AD_2AC

Competing interests

None



► **Video 1** A heterotopic gland in the transverse colon of a 62-year-old man is completely removed by endoscopic submucosal dissection.



► **Fig. 4** **a** Histopathologic appearance of a heterotopic gland in the colon. Almost normally expanded and branched ducts are found in the submucosa. H-E, hematoxylin and eosin staining. **b** High power view of the crypt showing an almost normal feature with partial dilatation in the submucosa.

The Authors

Sayo Ito¹, Kinichi Hotta¹, Kenichiro Imai¹,
Tadakazu Shimoda², Hiroyuki Ono¹

- 1 Division of Endoscopy, Shizuoka Cancer Center, Shizuoka, Japan
- 2 Division of Pathology, Shizuoka Cancer Center, Shizuoka, Japan

Corresponding author

Sayo Ito, MD

Division of Endoscopy, Shizuoka Cancer Center, 1007 Shimonagakubo, Nagaizumi, Sunto-gun, Shizuoka 411-8777, Japan
Fax: +81-55-9895783
sa.ito@scchr.jp

Acknowledgment

The authors wish to thank Dr. Tadakazu Shimoda for advice on pathological findings.

References

- [1] Garmendia M, Aparicio JR, Martinez J et al. Heterotopic gastric mucosa in the rectum. *Gastrointest Endosc* 2007; 65: 921–922
- [2] Huelsen A, Falvey J, Whitehead M et al. Gastrointestinal: large heterotopic gastric mucosa in the rectum. *J Gastroenterol Hepatology* 2012; 27: 1641
- [3] Iacopini F, Gotoda T, Elisei W et al. Heterotopic gastric mucosa in the anus and rectum: first case report of endoscopic submucosal dissection and systematic review. *Gastroenterol Rep (Oxf)* 2016; 4: 196–205

Bibliography

DOI <https://doi.org/10.1055/s-0043-117942>
Published online: 13.9.2017
Endoscopy 2017; 49: E288–E289
© Georg Thieme Verlag KG
Stuttgart · New York
ISSN 0013-726X

ENDOSCOPY E-VIDEOS

<https://eref.thieme.de/e-videos>



Endoscopy E-Videos is a free access online section, reporting on interesting cases and new

techniques in gastroenterological endoscopy. All papers include a high quality video and all contributions are freely accessible online.

This section has its own submission website at

<https://mc.manuscriptcentral.com/e-videos>