Endoscopic sleeve gastroplasty using Apollo Overstitch as a bridging procedure for superobese and high risk patients

▶ **Fig. 1** Photograph showing the positioning of the patient, devices, and team during the performance of endoscopic sleeve gastroplasty in a superobese patient. The patient is under general anesthesia, intubated, and in a supine position.

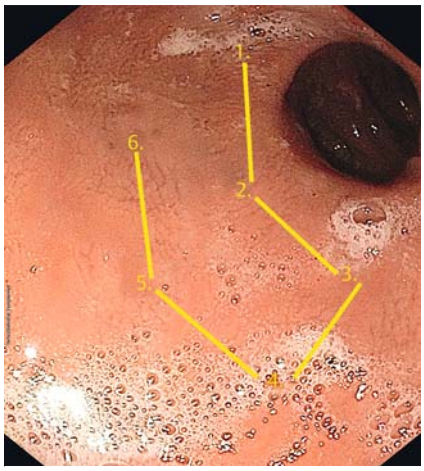

▶ **Fig. 2** The suturing pattern for the six parallel stiches used to perform endoscopic sleeve gastroplasty. A triangular pattern is obtained by positioning the sutures as following: (1) anterior wall; (2) greater curvature; (3) posterior wall; (4) posterior wall; (5) greater curvature; and (6) anterior wall.

In some cases, bariatric procedures cannot be performed via laparoscopic or open surgery because of surgical contraindications or high operative risk. Endoscopic sleeve gastroplasty (ESG) using an Overstitch (Apollo Endosurgery, Austin, Texas, USA) is a recently described procedure [1, 2] with good preliminary 1-year results in small series and low complication rates [3–5] for patients with a body mass index (BMI) ranging from 30–45 kg/m^2. However, the routine use of ESG for superobese and high risk patients has not yet been described.

The indications for ESGs performed in five superobese patients in our institution were as follows: (i) surgically impenetrable abdomen due to multiple operations or a giant incisional hernia; (ii) future liver or kidney transplant recipient; (iii) high risk patient with a contraindication to operation; (iv) a bridging procedure in a two-step concept (the first endoscopic, the second surgical 12–18 months later). Patients with BMI ranging from 51–72 kg/m^2 with numerous co-morbidities were submitted to ESG after multidisciplinary evaluation.

Video 1 Performance of an endoscopic sleeve gastroplasty in a patient with a body mass index (BMI) over 50 kg/m^2. Successive patterns of six parallel full-thickness stiches are performed from the incisura towards the gastroesophageal junction to create gastric restriction.

With the patient under general anesthesia and after installation of an overtube (Apollo Endosurgery), ESG was per-

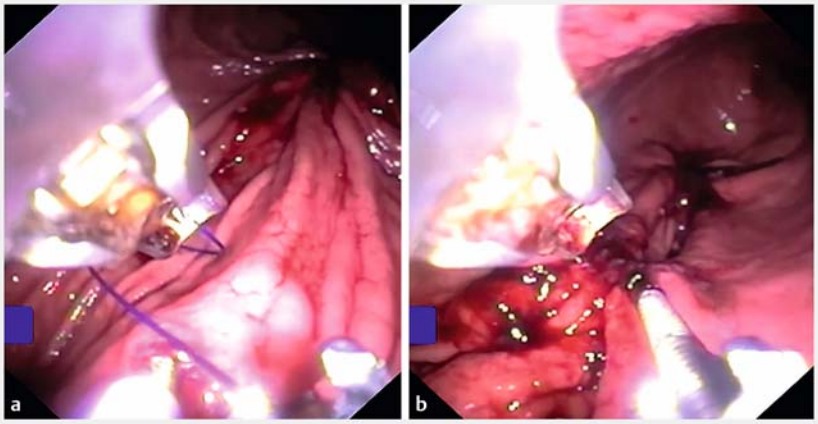

▶ **Fig. 3** Endoscopic views showing: **a** full-thickness suturing being performed across the stomach wall; **b** the tubular construction that results after completion of the endoscopic sleeve gastroplasty. In many cases, a residual pneumoperitoneum is found postoperatively.

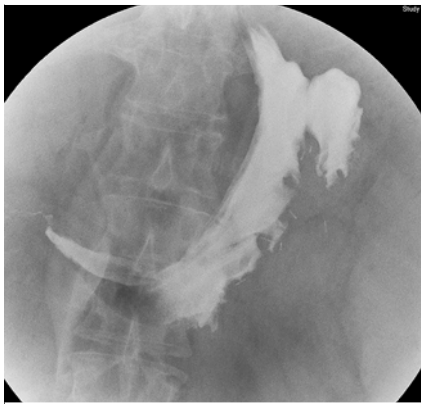

▶ **Fig. 4** Postoperative radiologic examination showing an adequate endoscopic sleeve gastroplasty with preservation of the gastric fundus, which slows the gastric emptying and improves satiation by other mechanisms, as in resectional sleeve gastrectomy.

formed using a standard two-channel endoscope (GIF-H180) with the patient intubated and in a supine position because of difficult ventilation (▶ **Fig. 1**; ▶ **Video 1**). Using CO_2 insufflation, a pattern of six stiches was performed for each suture, starting from the incisura and progressing proximally to the gastroesophageal junction (▶ **Fig. 2**). The tubular construction of the gastroplasty was obtained after five to eight sutures, while closure of the upper fundus was avoided (▶ **Fig. 3** and ▶ **Fig. 4**).

The operative time ranged from 93 to 230 minutes and there were no complications. Patients resumed a liquid diet on the same day and were discharged on postoperative day 3. At 3-month follow-up, the patients had lost 17 – 56 kg (mean 34.5 kg) resulting in a mean reduction of BMI from 58.6 to 52.5 kg/m^2.

ESG for superobese and high risk patients offers a potential alternative therapy for bridging or a primary morbid obesity therapy.

Endoscopy_UCTN_Code_CCL_1AZ_2AL

Competing interests

Ricardo Zorron is a member of the Scientific Advisory board (SAB) of Apollo.

The authors

Ricardo Zorron[1], Wilfried Veltzke-Schlieker[2], Andreas Adler[2], Christian Denecke[1], Tomasz Dziodzio[1], Johann Pratschke[1], Christian Benzing[1]

1 Center for Bariatric and Metabolic Surgery, Center for Innovative Surgery – ZIC, Department of Surgery, Charité – Universitätsmedizin Berlin, Campus Charité Mitte and Campus Virchow-Klinikum, Berlin, Germany

2 Medical Department, Division of Hepatology and Gastroenterology, Interdisciplinary 11 Endoscopy, Charité-Universitätsmedizin Berlin, Berlin, Germany

Corresponding author

Ricardo Zorron, MD
Center for Bariatric and Metabolic Surgery, Center for Innovative Surgery – ZIC, Department of Surgery, Charité – Universitätsmedizin Berlin, Campus Charité Mitte and Campus Virchow-Klinikum, Augustenburger Platz 1, Berlin, Germany
ricardo.zorron@charite.de

References

[1] Abu Dayyeh BK, Rajan E, Gostout CJ. Endoscopic sleeve gastroplasty: a potential endoscopic alternative to surgical sleeve gastrectomy for treatment of obesity. Gastrointest Endosc 2013; 78: 530 – 535

[2] Lopez-Nava G, Galvao MP, Bautista-Castaño I et al. Endoscopic Sleeve Gastroplasty for the treatment of obesity. Endoscopy 2015; 47: 449 – 452

[3] Zorron R, Galvao MP, Campos J et al. From complex evolving to simple: Current revisional and endoscopic procedures following bariatric surgery. ABCD Arch Bras Cir Dig 2016; 29: 128 – 133

[4] Sharaiha RZ, Kedia P, Kumta N et al. Initial experience with endoscopic sleeve gastroplasty: technical success and reproducibility in the bariatric population. Endoscopy 2015; 47: 164 – 166
[5] Lopez-Nava G, Galvao MP, Bautista-Castaño I et al. Endoscopic sleeve gastroplasty with 1-year follow-up: factors predictive of success. Endosc Int Open 2016; 4: E222 – E227

Bibliography
DOI https://doi.org/10.1055/s-0043-119685
Published online: 17.10.2017
Endoscopy 2018; 50: E81–E83

ISSN 0013-726X