Thieme

Endoscopic submucosal dissection to relieve a flexure of the gastric conduit after esophagectomy

OPEN ACCESS

Authors
Katsumi Yamamoto[1], Hiroshi Noro[2], Yu Sato[1], Akira Kusakabe[1], Nobuyuki Tatsumi[1], Tomoki Michida[3], Toshifumi Ito[1]

Institutions
1 Department of Gastroenterology, Japan Community Healthcare Organization, Osaka Hospital, Osaka, Japan
2 Department of Surgery, Japan Community Healthcare Organization, Osaka Hospital, Osaka, Japan
3 Third department of Internal Medicine, Teikyo University Medical Center, Chiba, Japan

submitted 9.7.2017
accepted after revision 31.8.2017

Bibliography
DOI https://doi.org/10.1055/s-0043-121883 | Endoscopy International Open 2018; 06: E350–E353
© Georg Thieme Verlag KG Stuttgart · New York
ISSN 2364-3722

Corresponding author
Katsumi Yamamoto, MD, PhD, Department of Gastroenterology, Japan Community Healthcare Organization (JCHO) Osaka Hospital, 4-2-78 Fukushima, Fukushima-ku, Osaka, 553-0003, Japan
Fax: +81-6-6445-8900
yamamoto-kts@umin.ac.jp

ABSTRACT

Background and study aims A 70-year-old-man underwent an esophagectomy and posterior mediastinal reconstruction for esophageal cancer that was curatively resected. Although the patient was allowed to eat after surgery, he repeatedly vomited after drinking water or eating meals and required continuous hospitalization. An upper gastrointestinal series and endoscopic examination revealed an obstruction due to the flexure of the gastric conduit, which was repeatedly treated with endoscopic balloon dilation. Endoscopic balloon dilation was completely ineffective, however, because the obstruction was not due to a small lumen diameter, but rather to severe flexure. We hypothesized that the power of contraction provided by ulcer scar formation after mucosal resection could straighten the flexure, and thus removed a piece of the mucosa 8 cm in diameter on the oral side of the flexure by endoscopic submucosal dissection (ESD) 4 months after the esophagectomy. Endoscopic examination on post-ESD Day 10 revealed that the gastric conduit flexure was straightened due to ulcer scarring, and obstruction at the flexure opened over time. Meals were restarted and the patient could eat without vomiting. He was discharged from the hospital 5 weeks after ESD. This is the first case report of obstruction due to flexure of the gastric conduit after esophagectomy that was successfully treated with mucosectomy using ESD. Mucosectomy using ESD may be an effective treatment option for obstruction due to flexure of the gastric conduit after esophagectomy.

Introduction

Endoscopic submucosal dissection (ESD) was developed initially for resecting superficial gastrointestinal tumors, and its application was recently expanded to other purposes; perioral endoscopic myotomy (POEM) [1], antireflux mucosectomy (ARMS) [2], and endoscopic antralplasty [3]. These reports suggest that ESD techniques may improve serious gastrointestinal disturbances by different mechanisms, but utilization of ESD is currently very limited.

Herein, we report a case with obstruction due to severe flexure of the gastric conduit after esophagectomy for esophageal cancer. The flexure was straightened and the obstruction successfully abolished by ulcer scar formation following a mucosectomy by ESD on the oral-side mucosa of the flexure. This is the first case report of the effectiveness of mucosectomy by ESD for an obstruction due to flexure of the gastric conduit after esophagectomy.

Case report

A 70-year-old-man underwent an esophagectomy and posterior mediastinal reconstruction for esophageal cancer. The esophageal cancer was curatively resected. Meals were started on postoperative day (POD) 11, but the patient repeatedly vomited after drinking water or eating meals. Changing the pa-

▶ **Fig. 1** Upper gastrointestinal study (x-ray) before and after endoscopic submucosal dissection (ESD). **a** Postoperative Day 35. Upper gastrointestinal study revealed stagnation of the contrast agent at a flexure of the gastric conduit. **b** One month after ESD, the gastric conduit flexure had straightened. Contrast agent smoothly flowed at the flexure. **c** Three months after ESD, the flexure was obscure. Red arrows point to flexure of the gastric conduit.

tient's posture had no effect. An upper gastrointestinal series revealed stagnation of the contrast agent at a flexure of the gastric conduit (▶ **Fig. 1a**). Endoscopic examination revealed an obstruction due to the flexure (▶ **Fig. 2a**). The flexure was located at about 5 cm oral side from the pylorus ring. Endoscopic balloon dilation was attempted twice (POD 60, POD 67) (▶ **Fig. 2b**), but was ineffective because the obstruction was not due to a small lumen diameter, but rather to severe flexure of the gastric conduit (▶ **Fig. 2c**). The patient could not be discharged from the hospital due to repeated vomiting even after ingesting only a small amount of fluid or food, and thus required total parental nutrition. Further surgery was considered, but was thought to be extremely risky due to difficulties in reoperating after posterior mediastinal reconstruction. We therefore attempted ESD to treat the severe flexure of the gastric conduit on POD112. A piece of the mucosa 8 cm in diameter was resected with ESD using the ITknife 2 (Olympus, Tokyo, Japan) and the clip-with-line method [4] and an artificial ulcer was created at the oral side of the flexure (▶ **Fig. 3a, b, c, d**). A delayed perforation (~5 mm in diameter) observed at the oral edge of an artificial ulcer on post-ESD Day 2 (▶ **Fig. 3e**) was conservatively treated by packing 10 15 × 7-mm polyglycolic acid sheets (Neoveil; Gunze Co., Kyoto, Japan) into the hole, applying a solution containing fibrinogen (Solution A of the Beriplast P Combi-Set; CSL Behring Pharma, Tokyo, Japan) with a spray tube, and then applying a solution containing thrombin (Solution B of the Beriplast P Combi-Set [▶ **Fig. 3f**]) with another spray tube to fix the sheets. Endoscopic examination on post-ESD Day 10 revealed that the perforation was closed, the gastric conduit flexure straightened due to ulcer scarring, and obstruction at the flexure opened over time (▶ **Fig. 1b**, ▶ **Fig. 3g**, ▶ **Fig. 4**). Meals were restarted on post-ESD Day 18 and the patient was able to eat without vomiting; the patient was discharged from the hospital on post-ESD Day 35 (POD147). Obstruction at the gastric conduit flexure was completely opened 3 months after ESD (▶ **Fig. 1c**, ▶ **Fig. 3h**) and remained open 1 year later (▶ **Fig. 3i**).

Discussion

Esophagectomy is a complex surgery with high risk of severe complications. Anastomotic stricture or gastric outlet obstruction may occur after esophagectomy [5, 6]. Treatment with repeated endoscopic balloon dilation is often required for the stricture, and even an additional surgery may be required for the obstruction. In this case, severe flexure of the gastric conduit caused an obstruction, i. e., stagnation of liquids and food, and the patient repeatedly vomited. This complication seems to be very rare, and we found no reports of a similar occurrence. The mechanism by which severe flexure occurs following esophagectomy is unknown. An upper gastrointestinal study showed that the flexure did not locate in the diaphragm. A computed tomography scan (data not shown) and upper gas-

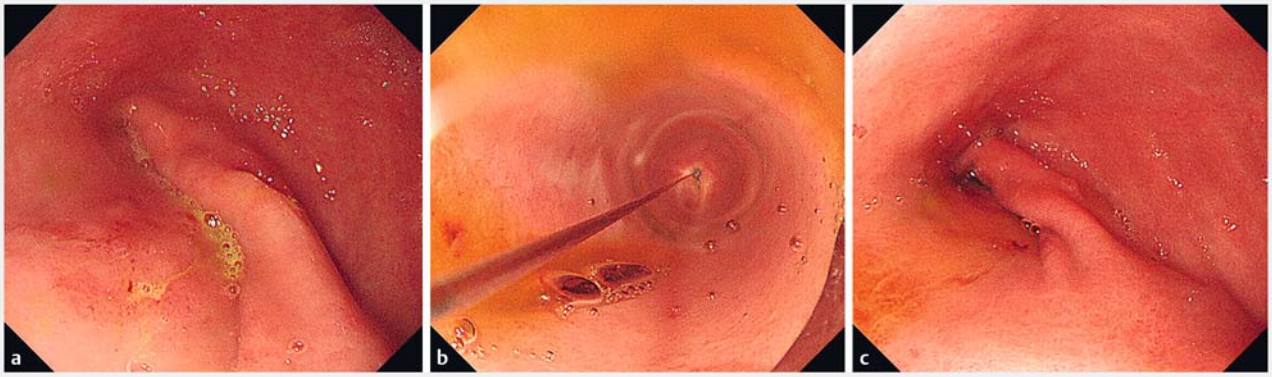

▶ **Fig. 2** Endoscopic images at the flexure of the gastric conduit before and after endoscopic balloon dilation (EBD). **a** Postoperative Day (POD) 60; before EBD. **b** EBD was repeatedly performed. **c** POD 67; after EBD. EBD was completely ineffective.

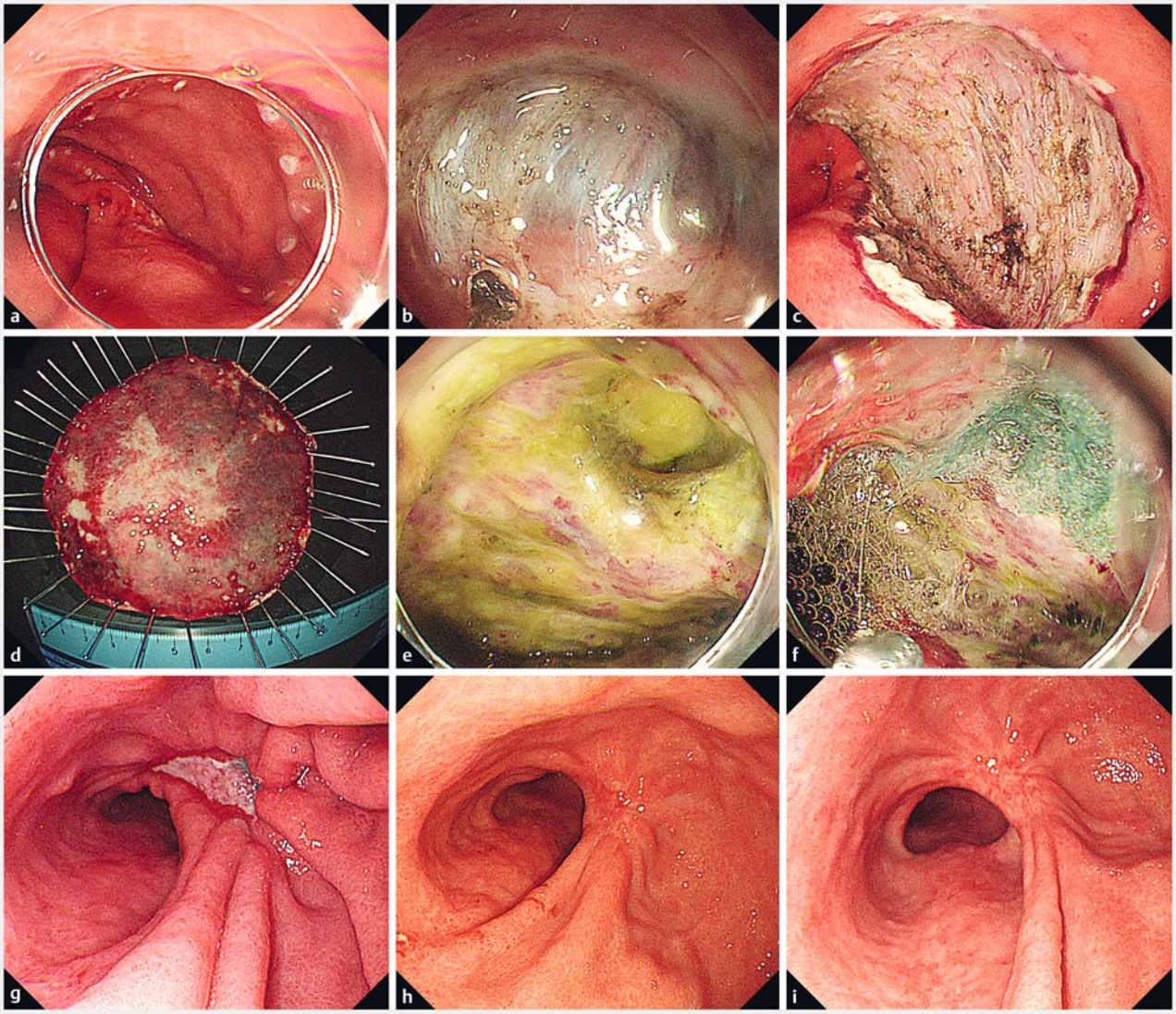

▶ **Fig. 3** Endoscopic images of the endoscopic submucosal dissection (ESD) (Postoperative Day 112) and after ESD. **a** Marking at the oral side of the flexure. **b** Following submucosal injection of glycerol and mucosal cutting, submucosal dissection was performed with the ITknife 2. **c** Artificial ulcer after ESD. **d** Resected specimen measuring 80 × 80 mm. **e** Post-ESD Day 2; delayed perforation was identified at the oral edge of an artificial ulcer. **f** The delayed perforation was treated with polyglycolic acid sheets and fibrin glue on the same day. **g** One month after ESD. **h** Three months after ESD; obstruction at the gastric conduit flexure was completely opened. **i** One year after ESD.

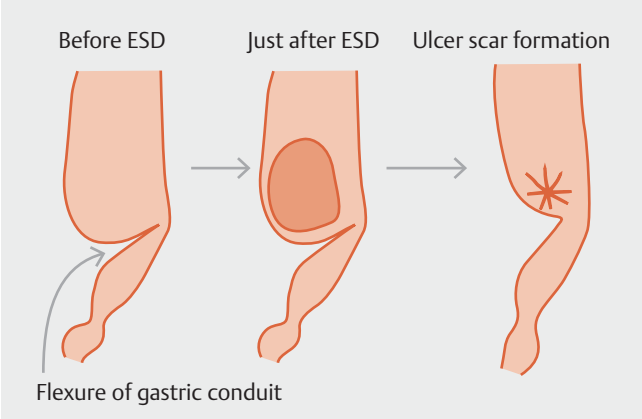

▶ **Fig. 4** Schema of the gastric conduit before and after endoscopic submucosal dissection (ESD) in this case.

trointestinal study showed no herniation of the pylorus into the thoracic cavity. Mismatching of the angle of the resection line by the linear stapler may have caused the severe flexure.

Endoscopic balloon dilation was attempted to treat the obstruction, but it was completely ineffective. Additional surgery was extremely risky due to the posterior mediastinal reconstruction, and we therefore attempted another endoscopic procedure, ESD.

Mori et al. [7] and Ohara et al. [3] reported that contralateral mucosal resection was effective for the treatment of antral deformation after ESD. Those mucosal resections utilized the power of contraction provided by ulcer scar formation to improve the antral deformation. In our case, the power of contraction by ulcer scar formation straightened the flexure of the gastric conduit, successfully opening the lumen at the flexure. The schema of the gastric conduit before and just after the ESD procedure is shown in (▶ **Fig. 4**). This treatment may be effective for other similar obstructions due to severe flexure. On the other hand, an artificial ulcer may cause subsequent stricture of the gastrointestinal lumen by ulcer scar formation, which could worsen the obstruction. The gastrointestinal lumen must have sufficient space to accommodate scarring of an artificial ulcer. We therefore resected the mucosa not on the flexure itself, but rather on the oral side of the flexure where the lumen was much broader. In this case, we planned the resection outline based on our hypothesis that the edges would be drawn to the center of an artificial ulcer by ulcer scar formation. In fact, as expected, the mucosa around the planned resection outline was drawn to the center, and it did not seem to completely join together due to mucosal regeneration. Further studies are needed to determine optimal location and size of a mucosectomy for other similar situations.

On the other hand, in this case, delayed perforation was detected 2 days after ESD. Low blood flow by cervical anastomosis via the posterior mediastinal root or bile duct reflux may be associated with delayed perforation [8], and it was conservatively treated with polyglycolic acid sheets and fibrin glue [9, 10]. Polyglycolic acid sheets and fibrin glue may also be an effective option for perforation during thoracic surgery in high risk cases.

Conclusion

This is the first case report demonstrating that mucosectomy by ESD for obstruction due to severe flexure of the gastric conduit after esophagectomy is extremely effective. This novel method may be a viable alternative therapy in cases in which surgery carries additional risks. Further studies are needed to evaluate the usefulness of this technique.

Competing interests

None

References

[1] Inoue H, Minami H, Kobayashi Y et al. Peroral endoscopic myotomy (POEM) for esophageal achalasia. Endoscopy 2010; 42: 265 – 271

[2] Inoue H, Ito H, Ikeda H et al. Anti-reflux mucosectomy for gastroesophageal reflux disease in the absence of hiatus hernia: a pilot study. Ann Gastroenterol 2014; 27: 346 – 351

[3] Ohara Y, Toyonaga T, Tanabe A et al. Endoscopic antralplasty for severe gastric stasis after wide endoscopic submucosal dissection in the antrum. Clin J Gastroenterol 2016; 9: 63 – 67

[4] Oyama T et al. Counter traction makes endoscopic submucosal dissection easier. Clin Endosc 2012; 45: 375 – 378

[5] Gallinger YuI, Chernousov AF, Andreev AL et al. Endoscopic balloon hydrodilatation and endoprosthetic treatment of esophageal and esophageal anastomotic strictures. Endoscopy 1989; 21: 11 – 14

[6] Lanuti M, de Delva PE, Wright CD et al. Post-esophagectomy gastric outlet obstruction: role of pyloromyotomy and management with endoscopic pyloric dilatation. Eur J Cardiothorac Surg 2007; 31: 149 – 153

[7] Mori H, Kobara H, Rafiq K et al. Novel method for the management of stenosis after gastric endoscopic submucosal dissection: mucosal incision with steroid injection contralateral to the severely contracted scar. Dig Endosc 2015; 27: 622 – 626

[8] Osumi W, Fujita Y, Hiramatsu M et al. Endoscopic submucosal dissection allows less-invasive curative resection for gastric tube cancer after esophagectomy – a case series. Endoscopy 2009; 41: 777 – 780

[9] Takimoto K, Hagiwara A. Filling and shielding for postoperative gastric perforations of endoscopic submucosal dissection using polyglycolic acid sheets and fibrin glue. Endosc Int Open 2016; 4: E661 – E664

[10] Tsuji Y, Ohata K, Gunji T et al. Endoscopic tissue shielding method with polyglycolic acid sheets and fibrin glue to cover wounds after colorectal endoscopic submucosal dissection (with video). Gastrointest Endosc 2014; 79: 151 – 155