

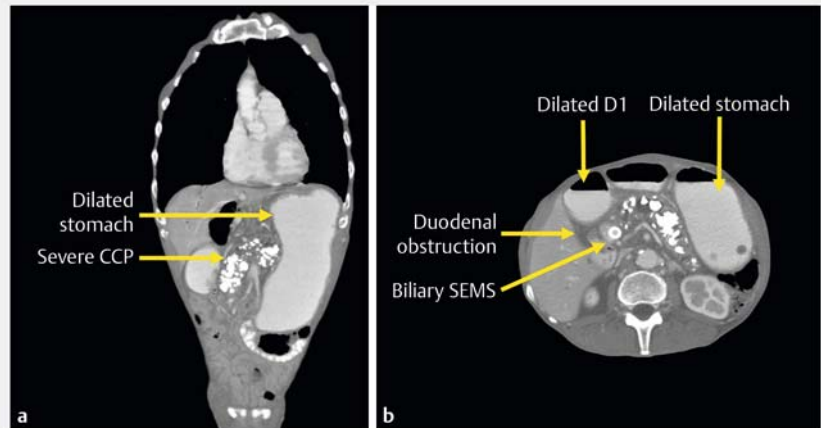
Endoscopic ultrasound-guided gastroenterostomy for the treatment of gastroduodenal obstruction in severe chronic pancreatitis

Endoscopic ultrasound (EUS)-guided gastroenterostomy is a newly described endoscopic technique that can be used to palliate the symptoms of gastroduodenal obstruction due to benign or malignant conditions. Multidisciplinary care, incorporating oncologists, surgeons, radiologists, and gastroenterologists, is strongly encouraged to ensure proper patient selection given the potential for severe adverse events, such as perforation and peritonitis.

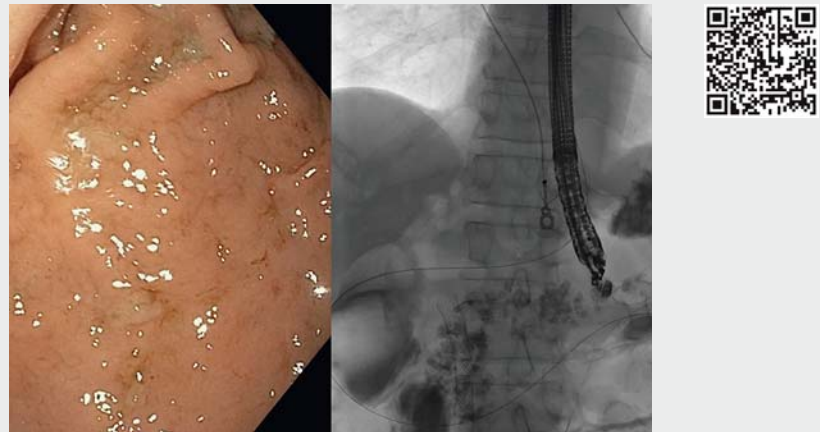
We report the case of a 63-year-old man with a history of heavy smoking, alcohol abuse, and severe chronic calcific pancreatitis who had been admitted several times over the preceding 2 years because of nausea, vomiting, abdominal pain, and weight loss. During this admission, his nasogastric tube output was more than 5L per day. Abdominal imaging showed a calcified pancreas, with marked dilatation of the stomach and the first portion of the duodenum (► **Fig. 1**). Multiple endoscopic dilations of the duodenum had been performed without clinical success in the past and he was deemed not to be a candidate for surgery. An EUS-guided gastroenterostomy was therefore performed as shown in ► **Video 1** and ► **Fig. 2** and ► **Fig. 3**.

Surgery offers better long-term outcomes; however, it is associated with higher rates of morbidity and mortality when compared to endoscopic stenting. Endoscopic stenting is safe and effective for symptom palliation and, when compared to surgery, it has lower complication rates and patients have shorter hospital stays. However, owing to the uncovered enteral stent design, it may not provide a long-term solution in benign conditions where re-intervention rates may be high because of stent occlusion [1].

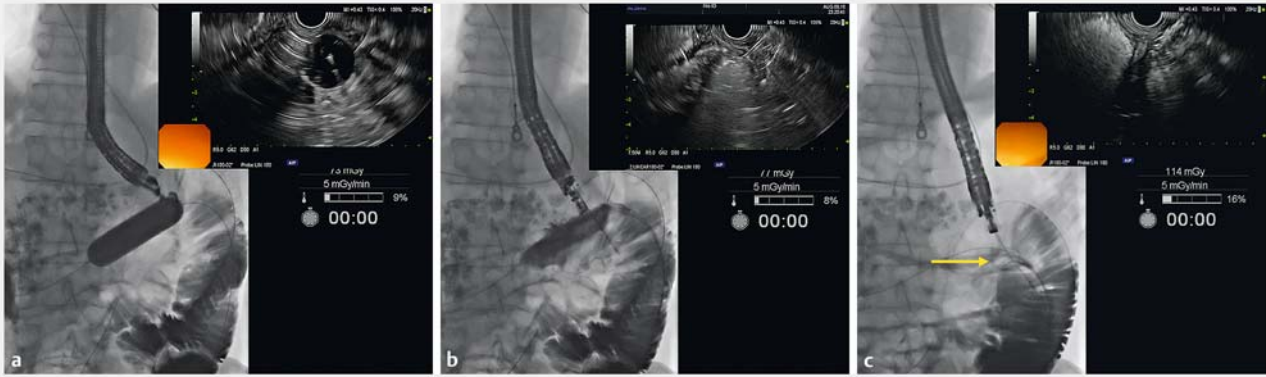
The idea of creating a luminal anastomosis between the stomach and small bowel using EUS and dedicated devices was



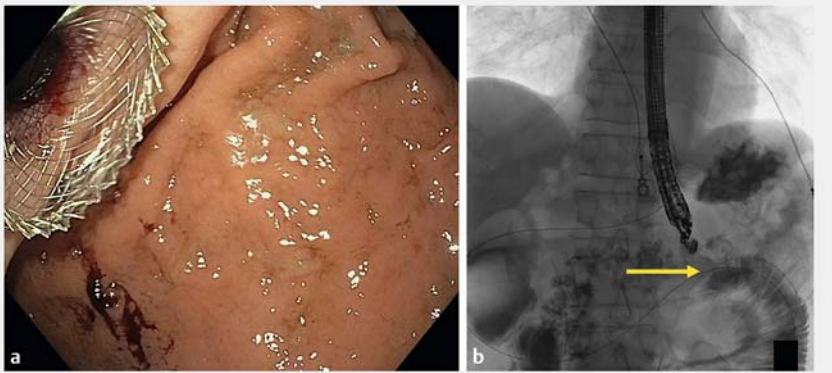
► **Fig. 1** Computed tomography (CT) images in a patient with severe gastric outlet obstruction showing a markedly dilated stomach and proximal duodenum (D1), severe chronic calcific pancreatitis (CCP), and a biliary self-expandable metal stent (SEMS) that was previously placed for benign biliary obstruction secondary to CCP: **a** coronal view; **b** axial view.



► **Video 1** Endoscopic ultrasound-guided gastroenterostomy in a patient with severe chronic pancreatitis and gastric outlet obstruction.



► **Fig. 2** Fluoroscopic and endoscopic ultrasound (EUS) views of the EUS-guided gastroenterostomy. **a** A through-the-scope dilation balloon is advanced over the wire with its location confirmed on the EUS view. **b** The balloon is punctured in the small bowel using a 19-gauge needle. **c** The distal phalange (arrow) of the cautery-enhanced lumen-apposing metal stent (CE-LAMS) is deployed in the small bowel under fluoroscopic and EUS guidance.



► **Fig. 3** End of procedure appearance of the lumen-apposing metal stent (LAMS) connecting the stomach and small bowel (arrow): **a** endoscopic view; **b** fluoroscopic view.

initially developed in animals [2,3], where it has shown successful outcomes and no adverse events. This is a novel technique with promising published data evaluating its efficacy and safety, although these are limited to a few small human studies [4–6].

Endoscopy_UCTN_Code_TTT_1AS_2AC

Competing interests

Uzma D. Siddiqui is a consultant for Boston Scientific and Olympus.

The authors

Emmanuel Coronel¹, Christopher G. Chapman¹, Jeffrey Matthews², Uzma D. Siddiqui¹

- 1 University of Chicago Medicine, Center for Endoscopic Research and Therapeutics, Chicago, Illinois, USA
- 2 University of Chicago Medicine, Department of Surgery, Chicago, Illinois, USA

Corresponding author

Uzma D. Siddiqui, MD

Center for Endoscopic Research and Therapeutics (CERT), The University of Chicago Medicine, 5700 S. Maryland Avenue MC 8043, Chicago, IL 60637, USA
 usiddiqui@bsd.uchicago.edu

References

- [1] Khashab M, Alawad AS, Shin E] et al. Enteral stenting versus gastrojejunostomy for palliation of malignant gastric outlet obstruction. *Surg Endosc* 2013; 27: 2068–2075
- [2] Binmoeller KF, Shah JN. Endoscopic ultrasound-guided gastroenterostomy using novel tools designed for transluminal therapy: a porcine study. *Endoscopy* 2012; 44: 499–503
- [3] Itoi T, Ito K, Uraoka T et al. Novel EUS-guided gastrojejunostomy technique using a new double-balloon enteric tube and lumen-apposing metal stent (with videos). *Gastrointest Endosc* 2013; 78: 934–939
- [4] Khashab MA, Kumbhari V, Grimm IS et al. EUS-guided gastroenterostomy: the first U.S. clinical experience (with video). *Gastrointest Endosc* 2015; 82: 932–938
- [5] Itoi T, Ishii K, Ikeuchi N et al. Prospective evaluation of endoscopic ultrasonography-guided double-balloon-occluded gastrojejunostomy bypass (EPASS) for malignant gastric outlet obstruction. *Gut* 2016; 65: 193–195
- [6] Tyberg A, Perez-Miranda M, Sanchez-Ocana R et al. Endoscopic ultrasound-guided gastrojejunostomy with a lumen-apposing metal stent: a multicenter, international experience. *Endosc Int Open* 2016; 4: E276–E281

Bibliography

DOI <https://doi.org/10.1055/s-0043-122597>
Published online: 15.12.2017
Endoscopy 2018; 50: 285–287
© Georg Thieme Verlag KG
Stuttgart · New York
ISSN 0013-726X

ENDOSCOPY E-VIDEOS <https://eref.thieme.de/e-videos>



Endoscopy E-Videos is a free access online section, reporting on interesting cases and new techniques in gastroenterological endoscopy. All papers include a high quality video and all contributions are freely accessible online.

This section has its own submission website at
<https://mc.manuscriptcentral.com/e-videos>