Impact of electrosurgical unit mode on post esophageal endoscopic submucosal dissection stricture in an in vivo porcine model

Authors

Yusuke Tonai[1], Ryu Ishihara[1], Yasushi Yamasaki[1], Masamichi Arao[1], Taro Iwatsubo[1], Minoru Kato[1], Syo Suzuki[1], Kenta Hamada[1], Satoki Shichijo[1], Noriko Matsuura[1], Takashi Kanesaka[1], Hiroko Nakahira[1], Sachiko Yamamoto[1], Tomofumi Akasaka[1], Noboru Hanaoka[1], Yoji Takeuchi[1], Koji Higashino[1], Noriya Uedo[1], Yasuhiko Tomita[2], Hiroyasu Iishi[1]

Institutions

1 Department of Gastrointestinal Oncology, Osaka International Cancer Institute, Osaka, Japan
2 Department of Pathology and Cytology, Osaka International Cancer Institute, Osaka, Japan

submitted 30.5.2017
accepted after revision: 25.10.2017

Bibliography
DOI https://doi.org/10.1055/s-0043-122883 |
Endoscopy International Open 2018; 65: E376–E381
© Georg Thieme Verlag KG Stuttgart · New York
ISSN 2364-3722

Corresponding author
Ryu Ishihara, MD, Department of Gastrointestinal Oncology, Osaka International Cancer Institute, 3-1-69, Otemae, Chuo-ku, Osaka-shi, Osaka, 541-8567, Japan
Fax: +81-6-69451902
isihara-ry@mc.pref.osaka.jp

ABSTRACT

Background and aim Strictures are a major complication of esophageal endoscopic submucosal dissection (ESD) for superficial esophageal carcinoma. Post ESD, stricture develops during the process of scar formation, which is related to inflammation caused by ESD. We planned a study to evaluate whether certain electrosurgical unit modes could attenuate strictures after esophageal ESD.

Methods A total of 16 ESD, three-quarters of the esophageal circumference, were performed in four live pigs. A ball-tip Flush knife was used for mucosal incision. Submucosal dissection was performed using a Hook knife in monopolar mode and a ball-tip Jet B-knife in bipolar mode. Applied electrosurgical unit modes were FORCED COAG, SWIFT COAG, SPRAY COAG, ENDO CUT in monopolar mode, and FORCED COAG in bipolar mode. One month after ESD, the pigs were killed humanely and the severity of strictures and fibrosis was assessed.

Results The resected site in the esophagus showed complete mucosal regrowth and scar formation in all pigs. The quotients of stricture following ENDO CUT, SWIFT COAG, FORCED COAG effect2, FORCED COAG effect3, FORCED COAG effect4, SPRAY COAG, and Bipolar FORCED COAG mode were 16%, 28%, 38%, 33%, 51%, 39%, and 47%, respectively. The equivalent quotients of fibrosis were 7%, 28%, 31%, 30%, 35%, 63%, and 100%, respectively. ENDO CUT mode was associated with the lowest mean quotients of stricture and fibrosis.

Conclusion ENDO CUT mode showed promising results to attenuate fibrosis and strictures after esophageal ESD.

Introduction

Esophageal cancer is the sixth most common cause of cancer-related mortality worldwide [1]. The overall survival of patients with esophageal cancer remains poor. However, a favorable prognosis can be expected if this cancer is detected at an early stage [2–4]. Endoscopic submucosal dissection (ESD) was developed in Japan and has been performed on many patients with early stage esophageal cancer because it is minimally invasive and offers excellent results [5]. Subsequently, ESD has been recognized as one of the standard treatments for superficial esophageal carcinoma.

Strictures are a major complication of esophageal ESD. The frequency of strictures for a high risk lesion, i. e. a mucosal defect covering more than three-quarters of the esophageal circumference, is 70–90% [6–8]. It substantially decreases patients' quality of life and requires multiple endoscopic balloon dilation sessions. This complication prevents the use of ESD for larger lesions. Several methods, including local steroid injection, systemic oral steroids, polyglycolic acid sheet, and tissue-engineered cell sheets, were developed to prevent strictures

▶ **Table 1** Details and peak voltage of each electrosurgical unit (ESU) mode.

ESU mode	Details of settings	Peak voltage, V
Monopolar		
▪ ENDO CUT	ENDO CUT I, Effect2 Duration2 Interval3	550
▪ SWIFT COAG	SWIFT COAG, Effect3, 40 W	990
▪ FORCED COAG E2	FORCED COAG, Effect2, 40 W	1100
▪ FORCED COAG E3	FORCED COAG, Effect3, 40 W	1430
▪ FORCED COAG E4	FORCED COAG, Effect4, 40 W	1800
▪ SPRAY COAG	SPRAY COAG, Effect1, 40 W	3520
Bipolar		
▪ FORCED COAG	Bipolar, FORCED COAG, Effect2, 50 W	1100

[9, 13 – 16]. Although they are partly effective, strictures are still a significant complication of ESD. If strictures are completely prevented, ESD will be indicated for larger lesions that were previously treated by esophagectomy.

Post ESD, a stricture develops during the process of scar formation. Scar formation is thought to be an integral part of wound healing, starting with inflammation and then proliferation, and remodeling [9]. During the remodeling process, the elasticity and compliance of the esophagus are reduced by fibrosis, which may lead to stricture formation [10 – 12]. Previous approaches to prevent strictures were targeted at the process after the occurrence of inflammation [9, 13 – 16]. For effective prevention of strictures, the process generating inflammation may also be a good target. To suppress the generation of inflammation, some modification is required to the ESD process. Electric current is a major factor contributing to the generation of inflammation during ESD and can be modified by controlling the electrosurgical unit (ESU). We therefore planned a study to investigate the impact of ESU modes on the development of strictures.

Methods

Experimental animals and methods

We performed this study in Kobe Medical Device Development Center, after approval from the animal ethics committee of the Intervention Technical Center (IVTeC) Co., Ltd. (Tokyo, Japan) which supports experiments on animals. An in vivo porcine model, four female adult Landrace-Wide Yorkshire-Duroc, was used to approximate the human situation. On the day of the procedure, they were fasted but allowed full access to water. General anesthesia was induced using ketamine hydrochloride (10 mg/kg), atropine sulfate, xylazine hydrochloride (2 mg/kg), and isoflurane. For each pig, we made virtual target lesions by marking oval-shaped dots that were about three-quarters of the circumference of the esophagus and their longitudinal diameters were about 5 mm. Virtual target lesions were made at sites 32 cm, 37 cm, 42 cm, and 47 cm from the mouth.

Endoscopic submucosal dissection

An endoscope with water-jet function (EVIS GIF-Q260 J, Olympus, Tokyo, Japan) with a distal attachment cap (D-201-11804; Olympus) was used for all procedures. All procedures were conducted by one endoscopist (R.I.) who had experienced more than 300 esophageal ESD procedures. A 0.9 % saline solution was injected into the submucosa using a 23-gauge endoscopic injection needle (01841, Top Corporation, Tokyo, Japan) to elevate the lesion. A ball-tip Flush knife (BT) (1.5 mm, DK2618JB; Fujifilm Medical, Tokyo, Japan) was used for mucosal incision and a Hook knife (KD-620LR; Olympus Medical, Tokyo, Japan), a monopolar endo-knife, was used for submucosal dissection. A ball-tip Jet B-knife (1.5 mm, BSJB15B; Zeon Medical, Tokyo, Japan), a bipolar endo-knife, was used for submucosal dissection.

A VIO electrosurgical generator (VIO 300D; ERBE, Tübingen, Germany), one of the most popular ESUs, was used for all ESD procedures [17]. ENDO CUT mode was used for marginal incision in all lesions. In the current study, we selected the ESU modes commonly used for submucosal dissection. The settings used for submucosal dissection with the monopolar endo-knife were: ENDO CUT; SWIFT COAG; FORCED COAG E2; FORCED COAG E3; FORCED COAG E4; and SPRAY COAG (▶ **Table 1**). The setting used for submucosal dissection with the bipolar endo-knife was FORCED COAG. The detailed settings and peak voltages of these modes are shown in ▶ **Table1**. The esophageal location where each ESU mode was applied is shown in ▶ **Table2**. When hemorrhage was observed, the bleeding point was coagulated with Coagrasper (FD-411QR; Olympus Medical, Tokyo, Japan), using the SOFT COAG mode (Effect 6, 80 W).

Assessment of stricture and fibrosis

One month after ESD, all pigs were examined by endoscopy to review the resection site and then humanely killed. After esophagectomy by a senior laboratory animal technician, the esophagus was opened longitudinally. The length of the normal part of the esophagus and the length of the ESD scars were both measured in the minor axis direction of the esophagus (▶ **Fig. 1**). The quotient of stricture (%) was calculated using the formula: 100 × (Maximum length of the normal part of

▶ **Table 2** Esophageal location where each electrosurgical unit (ESU) mode was applied.

Distance from the mouth	Pig 1	Pig 2	Pig 3	Pig 4
32 cm	FORCED COAG E4	SPRAY COAG	FORCED COAG E2	Bipolar, FORCED COAG
37 cm	FORCED COAG E3	FORCED COAG E2	SWIFT COAG	ENDO CUT
42 cm	FORCED COAG E2	FORCED COAG E3	ENDO CUT	SWIFT COAG
47 cm	SPRAY COAG	FORCED COAG E4	Bipolar, FORCED COAG	FORCED COAG E2

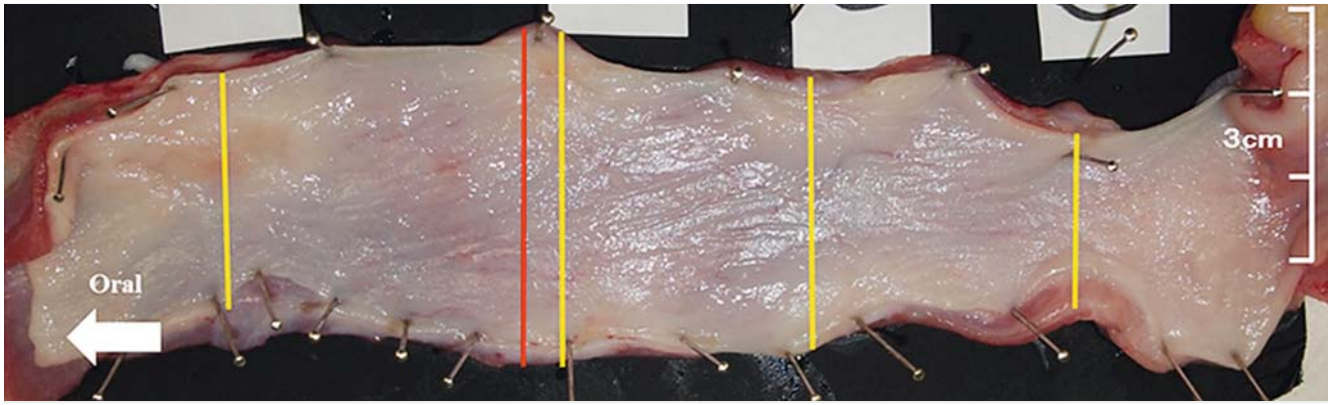

▶ **Fig. 1** Macroscopic view of the whole esophagus from Pig 3. The red line is the maximum length of the normal part of the esophagus and the yellow lines are the lengths of ESD scars, all measured in the minor axis direction of the esophagus.

each esophagus – Length of ESD scar)/Maximum length of the normal part of each esophagus. The quotient of stricture was compared among electrocautery modes.

After the assessment of stricture, the esophageal tissue was stretched, pinned onto a corkboard, and preserved in formalin. Then esophageal scars were cut up in the minor axis direction of the esophagus and stained using hematoxylin and eosin (HE) stain, desmin stain, and azan stain. Fibrosis of the muscle layer was assessed and compared among electrocautery modes. The quotient of fibrosis (%) was calculated using the formula: 100 × maximal thickness of fibrosis in the muscle layer/thickness of the muscle layer.

Data are expressed as mean (standard deviation). The association of stricture with various factors such as location, resected specimen size, frequency of hemostasis, and procedure time was tested using the Spearman correlation coefficient.

Results

Clinical course during and after ESD

The mean weight of the four pigs was 35.2 kg (32.9 – 36.2 kg). A total of 16 ESD, four ESD in each pig, was conducted without any complications (▶ **Fig. 2**). Vital status was stable during ESD in all pigs. All pigs resumed water on the day of the procedure and were placed on fluid food from postoperative day 1 and on solid food from postoperative day 3. All pigs were kept alive with an uneventful clinical course in terms of food intake, liquid intake, and physical activity. Endoscopy at 1 month, just before euthanasia, showed scar formation in all pigs (▶ **Fig. 3**). An endoscope (EVIS GIF-Q260J), 9.9 mm in diameter, could not pass the stricture on the oral side in Pigs 1, 2, and 4, and the stricture on the anal side in Pig 3.

Assessment of strictures and fibrosis

Resected esophagus showed complete mucosal regrowth and scar formation in all pigs. Mild to severe stricture was observed at the site of endoscopic resection (▶ **Fig. 1**). The quotient of stricture is summarized in ▶ **Table 3**. ENDO CUT mode showed the lowest mean quotient of stricture among all modes (16 ± 1 %). SWIFT COAG mode showed a slightly lower quotient of stricture (28 ± 28 %) than the other coagulation modes. The severity of fibrosis in the muscle layer is summarized in ▶ **Table 3**. ENDO CUT mode showed very mild fibrosis (7 ± 5 %) (▶ **Fig. 4a**). Mild to severe fibrosis was observed at all resection sites (▶ **Fig. 4b**). SWIFT COAG mode showed slightly lower fibrosis (28 ± 4 %) than the other coagulation modes. Bipolar FORCED COAG (100 ± 0 %) mode and SPRAY COAG (63 ± 53 %) mode showed severe fibrosis. The quotients of stricture for lesions located 32, 37, 42, and 47 cm from the mouth were 49.3 %, 24.4 %, 31.6 %, and 38.6 %, respectively, and the quotients of fibrosis were 67.5 %, 19.5 %, 23.8 %, and 51.3 %, respectively. Lesion location showed no significant correlation with stricture ($r = -0.14$, $P = 0.61$) or fibrosis ($r = -0.09$, $P = 0.75$), but both strictures and fibrosis were slightly less severe when the lesions were located 37 and 42 cm from the mouth. We therefore conducted subgroup analysis to reduce the impact of location. For lesions located 37 and 42 cm from the mouth, the quotients of stricture were 16 %, 28 %, 32 %, 23 %, and 51 % with ENDO CUT, SWIFT COAG, FORCED COAG E2, FORCED COAG E3, and FORCED COAG E4 modes, respectively, while the quotients of

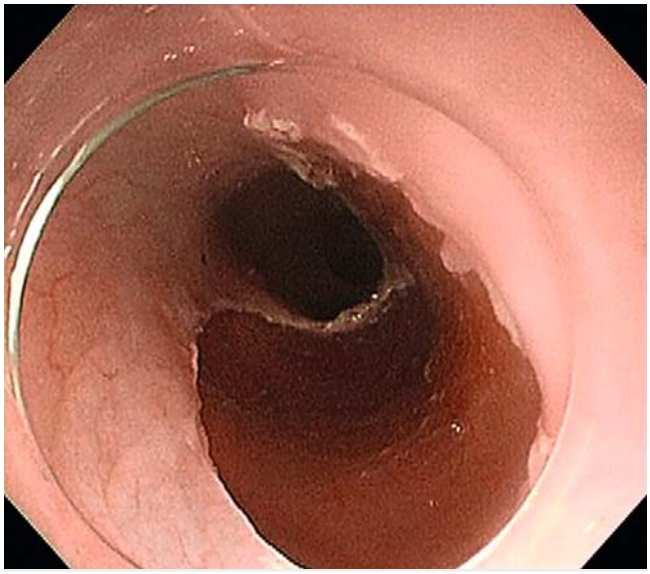

▶ **Fig. 2** Endoscopic view just after ESD shows a lesion 32 cm from the mouth of Pig 3.

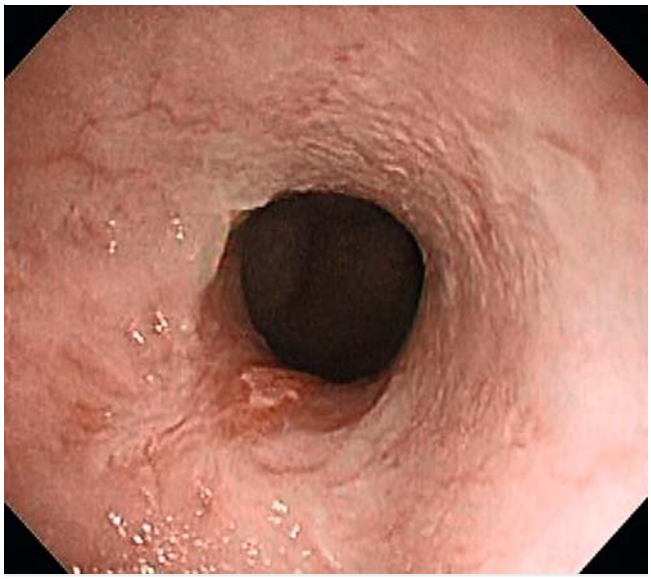

▶ **Fig. 3** Endoscopic view 4 weeks after ESD shows a scar 32 cm from the mouth of Pig 3.

fibrosis were 7 %, 28 %, 23 %, 20 %, and 40 %, respectively. For lesions located 32 and 47 cm from the mouth, the quotients of stricture were 43 %, 44 %, 50 %, 39 %, and 47 % with FORCED COAG E2, FORCED COAG E3, FORCED COAG E4, SPRAY COAG, and Bipolar FORCED COAG mode, respectively, and the quotients of fibrosis were 40 %, 40 %, 30 %, 63 %, and 100 %, respectively. ENDO CUT mode was thus associated with a lower quotient of stricture and fibrosis after adjusting for location. The mean (SD) size of the resected specimen was 20.4 (3.1) mm, and the size of the resected specimen showed no significant correlation with stricture ($r = -0.42$, $P = 0.10$) or fibrosis ($r = -0.36$, $P = 0.17$) formation. Hemostasis with forceps was only conducted twice (once during ENDO CUT and once during Bipolar FORCED COAG mode), and it was therefore not possible to investigate the relationship between hemostasis and stricture or fibrosis formation.

The mean (SD) resection time was 18.8 (4.2) minutes. Resection time was significantly correlated with stricture ($r = 0.52$, $P = 0.04$) and marginally correlated with fibrosis ($r = 0.48$, $P = 0.06$) formation. We therefore conducted subgroup analysis to account for the impact of procedure time. For lesions treated within the mean procedure time, the quotients of stricture were 16 %, 28 %, 33 %, 33 %, and 46 % using ENDO CUT, SWIFT COAG, FORCED COAG E2, FORCED COAG E3, and Bipolar FORCED COAG mode, respectively, while the quotients of fibrosis were 7 %, 28 %, 28 %, 30 %, and 100 %, respectively. The quotients of stricture for lesions treated with longer procedure times using FORCED COAG E2, FORCED COAG E4, SPRAY COAG, and Bipolar FORCED COAG were 52 %, 51 %, 39 %, and 48 %, respectively, while the quotients of fibrosis were 40 %, 35 %, 63 %, and 100 %, respectively. ENDO CUT mode was thus associated with lower quotients of stricture and fibrosis after adjusting for procedure time.

Discussion

This study compared the effect of electrocautery mode on fibrosis of the muscle layer and stricture after ESD. ENDO CUT mode showed the lowest quotient of stricture and the lowest fibrosis among all ESU modes.

ESU has two basic electrocautery patterns, one is cut current and the other is coagulation current. Cut current consists of a continuous low-voltage sinusoidal wave with no inactive period. The continuous sinusoidal wave causes very rapid heating with formation of sparks and gives sharp cutting and little coagulation. Coagulation current consists of a very short high-voltage sinusoidal wave (6 – 10 % of cycle) with long inactive periods (90 – 94 % of cycle). The long inactive period facilitates coagulation. The depth or severity of tissue injury and the coagulation effect mainly depend on electrical discharge, which is regulated by the height of the peak voltage [18]. Coagulation current, which has a higher peak voltage than cut current, theoretically has a higher coagulation effect and causes deeper and more severe damage to the surrounding tissue than cut current. Deep and severe damage probably results in extensive fibrosis and stricture. Various coagulation modes exist in the VIO 300 D ESU such as FORCED COAG, SWIFT COAG, and SPRAY COAG. FORCED COAG is frequently used for submucosal dissection; however, other modes such as SWIFT COAG, SPRAY COAG, and ENDO CUT offer alternative modes to FORCED COAG [19]. The coagulation effect increases with increasing peak voltage, in the order SWIFT COAG, FORCED COAG, and SPRAY COAG. However, the degree of fibrosis and stricture did not differ among coagulation modes. This probably means that the peak voltage of all coagulation modes is sufficiently high to cause significant damage to the muscle layer and form strictures.

ENDO CUT is a unique mode which is characterized by alternating cutting and coagulation cycles. Coagulation current employed in this mode has the lowest peak voltage (SOFT COAG)

▶ **Table 3** Mean quotient of stricture for each electrosurgical unit (ESU) mode and histopathological mean quotient of fibrosis in the muscle layer.

Modes	Quotient of stricture, %	SD	Quotient of fibrosis in the proper muscle layer, %	SD
ENDO CUT	16	1	7	5
SWIFT COAG	28	28	28	4
FORCED COAG, E2	38	20	31	10
FORCED COAG, E3	33	15	30	14
FORCED COAG, E4	51	1	35	7
SPRAY COAG	39	39	63	53
Bipolar, FORCED COAG	47	1	100	0

SD, standard deviation.

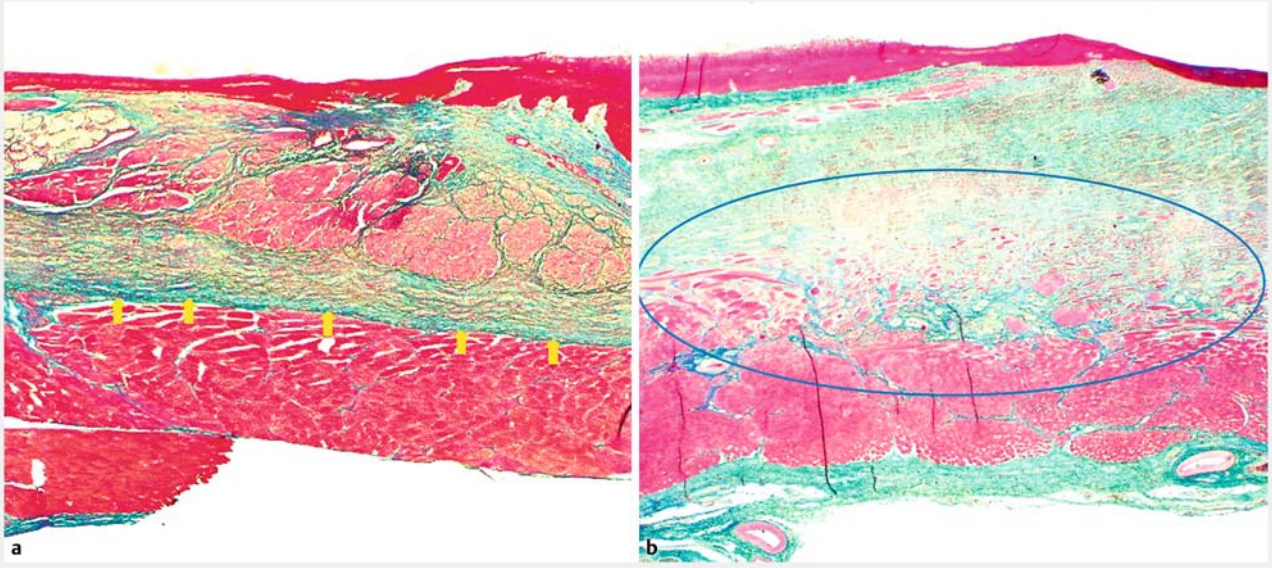

▶ **Fig. 4** Histopathologic findings in resected specimens (Azan stain). Fibrous tissue is dyed blue. **a** In ENDO CUT mode, fibrosis was observed in the submucosa (yellow arrows). No fibrosis was observed in the muscle layer. **b** In FORCED COAG E2 mode, about 40 % of the muscle layer was damaged and replaced by fibrosis (area within blue ellipse). This is a histologic view of the ESD scar 32 cm from the mouth of Pig 3.

among various coagulation currents, which may attenuate the heat damage to surrounding tissue. This mode is designed to realize submucosal dissection with lowest tissue damage by combining cutting current and lowest peak voltage coagulation current. Bahin et al. examined inflammation after endoscopic mucosal resection and showed that ENDO CUT mode resulted in less inflammation of the submucosal layer and muscle layer than COAG mode [20]. Similar to their result, in our study, lower fibrosis of the muscle layer was observed in ENDO CUT mode than in all coagulation modes. Because of its electrical characteristics, ENDO CUT mode probably causes less inflammation and fibrosis which may result in a lower degree of stricture after ESD. Considering the characteristics of ENDO CUT mode and the results of this study, ENDO CUT mode is a promising ESU mode to prevent strictures after ESD.

ESU setting is also divided into two types based on the electrodes. Monopolar electrocautery has one small active electrode and one large dispersive plate electrode. The monopolar endo-knife used in this study had a small active electrode at the tip of the knife and a large dispersive electrode placed at the back of the pig. By using a large dispersive electrode and small active electrode, electric discharge is radiated from the tip of the monopolar knife. Radiated electrical discharge of COAG modes caused severe muscle layer fibrosis and strictures in this study. Bipolar electrocautery has two small active electrodes very close to each other (active and return electrode). The bipolar endo-knife used in this study had an active electrode at the tip and return electrode at the base of the 1.5 mm knife. Localized and concentrated electrocautery flows between active and return electrode in the bipolar knife and the localized electrocautery may theoretically attenuate the damage to surrounding tissue. However, in this study, bipolar coagulation mode had similar muscle layer fibrosis and stricture formation to monopolar coagulation modes. There are two possible ex-

planations for this result. One explanation is that the dissection process of ESD is conducted just above the muscle layer. Even localized electric current may damage the muscle layer and thus cause strictures when the knife is used adjacent to the muscle layer. Another explanation is that concentrated, probably strong, electric current around the bipolar knife caused more severe damage to the surrounding tissue than expected. Considering the concept of the bipolar knife, it has the potential to reduce strictures after ESD. We have to optimize the settings and usage of this knife to reduce the damage to muscle layer and formation of strictures.

A limitation of the study is the use of a porcine model which may differ from human in certain aspects. For example, the submucosa and muscle layer are thinner in pigs than in the human esophagus [20]. Damage to the muscle layer, caused by electrocautery, may differ in the human esophagus. However, when we consider that the effects of ESU modes were compared among various modes and that a large difference was observed between ENDO CUT mode and coagulation modes, our results may be transferable to human esophageal disease. Lesion location, resected specimen size, frequency of hemostasis, and procedure time may influence stricture and fibrosis formation. In this study, procedure time was significantly associated with stricture formation. Although it was not possible to conduct multivariate analysis because of the limited sample size, subgroup analyses confirmed that ENDO CUT mode was associated with lower quotients of stricture and fibrosis than other ESU modes, after adjusting for procedure time. Another limitation of the study is the small number of pigs. More pigs would be required to detect a statistically significant difference among the various modes. There are many modes in ESU such as FORCED COAG mode, SWIFT COAG mode, SPRAY COAG mode, and ENDO CUT mode. Comparing all modes in terms of muscle layer damage and stricture may be too costly and difficult. We therefore decided to perform this study as an initial-phase test to compare various modes and identified promising modes to suppress stricture formation.

In this study, ENDO CUT mode showed promising results to attenuate fibrosis and strictures after esophageal ESD. Further study, which focuses on the effect of ENDO CUT mode, would provide more information for the prevention of strictures.

Competing interests

None

References

[1] Parkin DM, Bray F, Ferlay J et al. Global cancer statistics, 2002. CA Cancer J Clin 2005; 55: 74 – 108

[2] Yamashina T, Ishihara R, Nagai K et al. Long-term outcome and metastatic risk after endoscopic resection of superficial esophageal squamous cell carcinoma. Am J Gastroenterol 2013; 108: 544 – 551

[3] Igaki H, Kato H, Tachimori Y et al. Clinicopathologic characteristics and survival of patients with clinical stage I squamous cell carcinomas of the thoracic esophagus treated with three-field lymph node dissection. Eur J Cardiothorac Surg 2001; 20: 1089 – 1094

[4] Yamamoto S, Ishihara R, Motoori M et al. Comparison between definitive chemoradiotherapy and esophagectomy in patients with clinical stage I esophageal squamous cell carcinoma. Am J Gastroenterol 2011; 106: 1048 – 1054

[5] Oyama T, Tomori A, Hatta K et al. Endoscopic submucosal dissection of early esophageal cancer. Clin Gastroenterol Hepatol 2005; 3: 67 – 70

[6] Katada C, Muto M, Manabe T et al. Esophageal stenosis after endoscopic mucosal resection of superficial esophageal lesions. Gastrointest Endosc 2003; 57: 165 – 169

[7] Hashimoto S, Kobayashi M, Takeuchi M et al. The efficacy of endoscopic triamcinolone injection for the prevention of esophageal stricture after endoscopic submucosal dissection. Gastrointest Endosc 2011; 74: 1389 – 1393

[8] Ezoe Y, Muto M, Horimatsu T et al. Efficacy of preventive endoscopic balloon dilation for esophageal stricture after endoscopic resection. J Clin Gastroenterol 2011; 45: 222 – 227

[9] Hanaoka N, Ishihara R, Takeuchi Y et al. Intralesional steroid injection to prevent stricture after endoscopic submucosal dissection for esophageal cancer: a controlled prospective study. Endoscopy 2012; 44: 1007 – 1011

[10] Macri L, Clark RA. Tissue engineering for cutaneous wounds: selecting the proper time and space for growth factors, cells and the extracellular matrix. Skin Pharmacol Physiol 2009; 22: 83 – 93

[11] Badylak SF, Vorp DA, Spievack AR et al. Esophageal reconstruction with ECM and muscle tissue in a dog model. J Surg Res 2005; 128: 87 – 97

[12] Honda M, Nakamura T, Hori Y et al. Process of healing of mucosal defects in the esophagus after endoscopic mucosal resection: histological evaluation in a dog model. Endoscopy 2010; 42: 1092 – 1095

[13] Yamaguchi N, Isomoto H, Nakayama T et al. Usefulness of oral prednisolone in the treatment of esophageal stricture after endoscopic submucosal dissection for superficial esophageal squamous cell carcinoma. Gastrointest Endosc 2011; 73: 1115 – 1121

[14] Iizuka T, Kikuchi D, Yamada A et al. Polyglycolic acid sheet application to prevent esophageal stricture after endoscopic submucosal dissection for esophageal squamous cell carcinoma. Endoscopy 2015; 47: 341 – 344

[15] Ohki T, Yamato M, Ota M et al. Prevention of esophageal stricture after endoscopic submucosal dissection using tissue-engineered cell sheets. Gastroenterology 2012; 143: 582 – 588

[16] Nonaka K, Miyazawa M, Ban S et al. Different healing process of esophageal large mucosal defects by endoscopic mucosal dissection between with and without steroid injection in an animal model. BMC Gastroenterol 2013; 13: 72

[17] Morita Y. Electrocautery for ESD: setting of the electrical surgical unit VIO300D. Gastrointest Endoscopy Clin N Am 2014; 24: 183 – 189

[18] Munro MG. Fundamentals of electrosurgery, Part I: Principles of radiofrequency energy for surgery. In: Feldman LS, Fuchshuber PR, Jones DB , eds. The SAGES manual on the fundamental use of surgical energy (FUSE). New York: Springer; 2012: 15 – 59

[19] Matsui N, Akahoshi K, Nakamura K et al. Endoscopic submucosal dissection for removal of superficial gastrointestinal neoplasms: A technical review. World J Gastrointest Endosc 2012; 4: 123 – 136

[20] Bahin FF, Burgess NG, Kabir S et al. Comparison of the histopathological effects of two electrosurgical currents in an in vivo porcine model of esophageal endoscopic mucosal resection. Endoscopy 2016; 48: 117 – 122