

# Radiofrequency ablation (RFA) vs. argon plasma coagulation (APC) for the management of gastric antral vascular ectasia (GAVE) in patients with and without cirrhosis: results from a retrospective analysis of a large cohort of patients treated at a single center

OPEN  
ACCESS

## Authors

Paul St. Romain<sup>1</sup>, Amanda Boyd<sup>2</sup>, Jiayin Zheng<sup>3</sup>, Shein-Chung Chow<sup>3</sup>, Rebecca Burbridge<sup>1</sup>, Daniel Wild<sup>1</sup>

## Institutions

- 1 Division of Gastroenterology, Duke University Medical Center, Durham, North Carolina, United States
- 2 Division of Internal Medicine, Duke University Medical Center, Durham, North Carolina, United States
- 3 Division of Biostatistics, Duke University Medical Center, Durham, North Carolina, United States

submitted 25.8.2017

accepted after revision 8.11.2017

## Bibliography

DOI <https://doi.org/10.1055/s-0043-123187> |  
Endoscopy International Open 2018; 06: E266–E270  
© Georg Thieme Verlag KG Stuttgart · New York  
ISSN 2364-3722

## Corresponding author

Paul St. Romain, Duke University Medical Center,  
Department of Medicine, Division of Gastroenterology,  
03142 Orange Zone, Durham, NC 27710  
Fax: +1-919-684-8857  
[Paul.st.romain@duke.edu](mailto:Paul.st.romain@duke.edu)

## ABSTRACT

**Introduction and study aims** Gastric antral vascular ectasia (GAVE) is a mucosal abnormality associated with multiple conditions, most notably cirrhosis and systemic sclerosis, that causes indolent gastrointestinal bleeding. It is primarily managed with endoscopic therapy. Traditionally, GAVE is endoscopically ablated using argon plasma coagulation (APC) but radiofrequency ablation (RFA) is emerging as an alternative modality. No prior comparison of the 2 modalities has been published.

We retrospectively compared the effects of GAVE ablation with either RFA, APC or both in the largest cohort of patients thus far presented. We also attempt to discern what effect concomitant cirrhosis has on response to treatment.

**Patients and methods** After receiving IRB approval, we reviewed our electronic health records to identify all patients who underwent endoscopic evaluation for GAVE between January, 2011 and October, 2016. We compared important variables between APC and RFA, as well as between cirrhosis and non-cirrhosis, using the Chi-square test and the Wilcoxon two-sample test as appropriate.

**Results** During our study period, 81 patients were endoscopically evaluated for GAVE. 24 patients were treated with APC alone, 28 with RFA alone and 25 patients received both treatment modalities.

APC-treated patients underwent a mean of 2.4 treatment sessions with a mean of 205 days between treatments. RFA-treated patients underwent a mean of 2.3 treatment sessions with a mean of 100 days between treatments. Hemoglobin values remained stable or increased in all patients during our study period and there were no significant differences in Hgb trend between those treated with APC and those with RFA.

**Conclusions** RFA and APC were both effective in treating bleeding from GAVE. Though we found subtle differences, patients underwent a similar number of treatment sessions and had similar procedure times and a similar time between sessions no matter the treatment modality used.

## Introduction

Gastric antral vascular ectasia (GAVE) is an uncommon but significant cause of upper gastrointestinal bleeding. It can occur sporadically or in association with several conditions, principal-

ly systemic sclerosis and cirrhosis. GAVE can be difficult to manage and result in the need for chronic red blood cell transfusion despite endoscopic therapy. Traditionally, argon plasma coagulation (APC) has been employed as the primary endoscopic modality for the treatment of GAVE [1]. Data are limited

and conflicting on its efficacy with some series demonstrating significant decreases in transfusion requirements in most patients [2, 3], but other studies showing success rates as low as 25% [4, 5].

More recently, radiofrequency ablation (RFA) has gained traction as an alternative modality to APC for the endoscopic treatment of GAVE. The larger per-treatment surface area afforded by the RFA catheters, and the reproducible depth of treatment are seen as potential advantages over APC. Despite these properties, there are limited data demonstrating the comparative efficacy of either modality.

The aim of this retrospective study was to examine the comparative efficacy of RFA and APC for the treatment of GAVE in cirrhotic and non-cirrhotic patients managed at a single tertiary referral center.

## Patients and methods

### Data review

After receiving approval from our Institutional Review Board (IRB), we used key word searches in endoscopic reports and billing data to identify all patients who underwent endoscopic treatment for GAVE in the Duke Health System between 1/10/2011 and 10/19/2016.

Through chart review using our comprehensive electronic medical records, we assessed outcomes for up to 18 months after index Upper Endoscopy (EGD), recording need for repeat endoscopy and hospital readmission. Data were collected on platelet count and INR at index endoscopy, RFA and APC parameters, means of sedation and mean hemoglobin (Hgb) over the ensuing 18 months after index endoscopy.

### Statistical analysis

Descriptive statistics were calculated for the demographic and clinical characteristics. Comparisons were performed using Chi-square tests or Fisher exact tests for categorical variables and t tests, paired t tests, Wilcoxon rank-sum tests or signed rank tests for continuous variables as appropriate.

### GAVE treatment

All patients who underwent treatment were treated with either RFA or APC. APC was performed using a Filter Integrated APC probe (ERBE USA, Marietta, GA) with settings ranging from a flow of 0.8–1 L/min and power ranging from 20–30 watts. RFA was performed using the Barrx HALO-90 or HALO-60 probes (Given Medical, Minneapolis, MN) delivering 12 J/cm<sup>2</sup> per ablation.

## Results

### Cohort

81 patients underwent endoscopic evaluation for GAVE in this study period. 49 (60%) of these patients were female and the mean age at the index exam was 67 years old. 27 (33%) of these patients had a diagnosis of cirrhosis. 4 patients (5%) had end-stage renal disease, 34 (42%) had diabetes mellitus and 21 (26%) had a diagnosis of congestive heart failure. 24 patients

were treated with APC alone, 28 with RFA alone and 25 patients received both treatment modalities across multiple sessions. 4 patients were not treated endoscopically.

As expected, cirrhotic patients had a higher mean INR (INR 1.20 vs. 1.07 ( $P=0.0005$ ) and lower mean platelet count (platelet count 131.7 vs.  $244.6 \times 10^9/L$  ( $P<0.0001$ ) than patients without cirrhosis. Despite this, their coagulation parameters fell within our standard therapeutic ranges and so no cirrhotic patients required pre-treatment fresh frozen plasma or platelet transfusions. GAVE manifested earlier in cirrhotic patients (63.3 vs. 68.3 years old ( $P=0.0208$ )) than in those without cirrhosis. These and other demographics are depicted in ► **Table 1a** and ► **Table 1b**.

Of the patients on anticoagulation or anti-platelet agents, 3 were on warfarin alone, 3 were on clopidogrel alone, 3 were on novel oral anti-coagulant (NOAC) monotherapy (2 rivaroxaban, 1 apixiban), 1 was on enoxaparin and 1 patient was on dual treatment with both warfarin and apixiban. These agents were held for variable lengths of time prior to endoscopy: warfarin for a mean of 4.3 days (range 1–7 days); clopidogrel for a mean of 5.3 days (range 4–7 days); NOAC's for a mean of 2.5 days (range 1–4 days).

### APC group

Non-cirrhotic patients treated with APC alone underwent a mean of 2.4 treatment sessions with a mean of 190 days between treatments. Comparing the mean Hgb in the 18 months prior to the index exam (9.8 g/dL) and the 18 months after (10.9 g/dL), this group experienced a statistically significant increase of 1.1 g/dL after treatment ( $P=0.0150$ ).

Cirrhotic patients treated with APC alone underwent a mean of 2.7 treatment sessions with a mean of 277 days between treatments. There was no significant change in their Hgb in the 18 months prior to the index exam (10.0 g/dL) compared to the 18 months after it (10.3 g/dL) (► **Table 2**).

### RFA group

Non-cirrhotic patients treated with RFA alone underwent a mean of 2.2 treatment sessions with a mean of 120 days between sessions. Comparing their mean Hgb in the 18 months prior to (9.7 g/dL) and after the index exam (10.4 g/dL), they experienced an increase of 0.7 g/dL after treatment, though this increase was not statistically significant.

Cirrhotic patients treated with RFA alone underwent a mean of 2.4 treatment sessions with a mean of 70 days between sessions. There was no significant change in their Hgb in the 18 months prior to the index exam (9.2 g/dL) compared to the 18 months after it (9.2 g/dL) (► **Table 2**).

### RFA vs. APC and cirrhosis vs. no cirrhosis comparisons

Baseline and outcome measures were compared between patients with and without cirrhosis and between those treated with RFA or APC. Patients with cirrhosis treated with RFA had significantly shorter time between treatments than patients with cirrhosis treated with APC (70 vs. 277 days,  $P=0.0238$ ) (► **Table 2**). As expected, mean baseline INR was significantly

► **Table 1a** Study demographics.

	RFA	APC	Mixed	P value
N	28	24	25	
Age (SD)	70 (10)	64 (12)	66 (10)	NS
% female	68	56	52	NS
Hgb g/dL (SD)	9.62 (1.71)	9.67 (1.65)	9.08 (1.68)	NS
Plt 10 <sup>9</sup> /L (SD)	204 (104)	244 (112)	175 (81)	NS
INR (SD)	1.16 (0.21)	1.05 (0.2)	1.15 (0.20)	0.012
Anticoagulated	18.52%	16.67%	8.33%	NS

Hgb, hemoglobin; INR, international normalized ratio; NS, nonsignificant; Plt, platelets; SD, standard deviation

► **Table 1b** Study demographics.

	Cirrhosis	No cirrhosis	P value
N	27	54	
Age (SD)	63.3 (8.64)	68.3 (11.2)	0.0237
% female	55.56	64.15	NS
Hgb g/dL (SD)	9.52 (1.71)	9.52 (1.77)	NS
Plt 10 <sup>9</sup> /L (SD)	131.7 (76.2)	244.6 (90.8)	<0.0001
INR	1.2 (0.2)	1.07 (0.19)	0.0008
Anticoagulated	3.7%	19.61%	NS

Hgb, hemoglobin; INR, international normalized ratio; NS, nonsignificant; Plt, platelets; SD, standard deviation

► **Table 2** Radiofrequency ablation, argon plasma coagulation and hemoglobin levels

	Mean treatments	Mean time between treatments (days)	Mean Hgb, 18 months prior to first endoscopy (g/dL)	Mean Hgb, 18 months post-first endoscopy (g/dL)
Cirrhosis-APC	2.7	277	10	10.3
No cirrhosis -APC	2.4	190	<b>9.8</b>	<b>10.9</b>
Cirrhosis-RFA	2.4	70	9.2	9.2
No cirrhosis-RFA	2.2	120	9.7	10.4

APC, argon plasma coagulation; Hgb; hemoglobin; RFA, radiofrequency ablation; Bold indicates statistical significance

higher (1.25 vs. 1.09,  $P=0.0125$ ) and mean platelet counts were significantly lower (113 vs. 263,  $P=0.0005$ ) in RFA-treated cirrhotics vs. RFA-treated patients without cirrhosis.

Non-cirrhotics experienced a mean increase in Hgb in the 18 months after treatment with either modality (1.1 g/dL with APC and 0.5 g/dL with RFA) whereas cirrhotic patients' Hgb remained unchanged after treatment, however neither of these changes reached statistical significance. Comparisons in baseline Hgb, age, gender, percent on anticoagulation and number of treatment sessions were also not statistically significant.

Data on procedure times was available for 115 (48%) of the procedures that utilized APC and 126 (52%) of the procedures with RFA. The mean procedure time was 23.5 minutes (range

8.9–48.2 min) for APC procedures and 27.2 minutes (range 8.6–57.1 min) for RFA procedures. These differences were not statistically significant.

### Dual treatment group

25 patients (12 with cirrhosis) underwent treatment with both APC and RFA. Thirteen of these patients were treated first with APC and then progressed to RFA. This group underwent a mean of 2.5 APC treatments before progressing to RFA and a mean total number of endoscopic treatment sessions of 4.3. Mean time between APC sessions was 74 days and time between RFA sessions was 94 days.

4 of these patients received RFA first and then transitioned to APC for “touch-up” treatments. 8 (8) of these patients received some alternating combination of RFA and APC depending on the provider performing the procedure and the extent of the GAVE at the time of the procedure. These patients underwent a mean total of 4 endoscopic treatment sessions.

Cirrhotics treated with dual modalities had a mean Hgb of 8.6g/dL in the 18 months prior to their index treatment and 9.0g/dL in the 18 months after. The mean Hgb of Non-Cirrhotics treated with dual modalities in the 18 months before and after their index treatment was unchanged at 9.8g/dL.

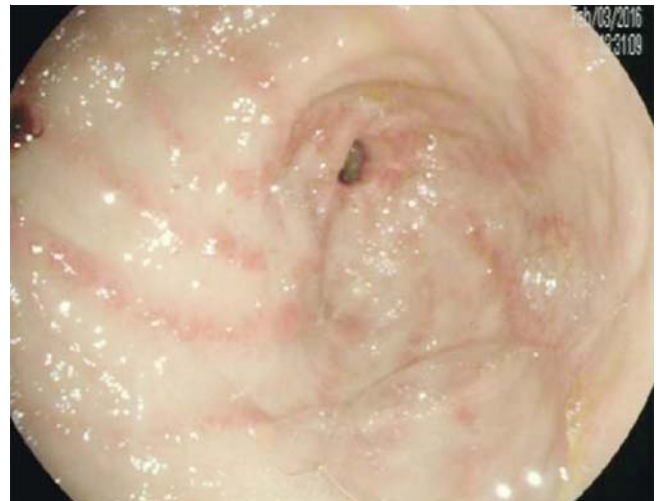
## Discussion

GAVE is a rare disorder characterized by ectatic mucosal blood vessels, most commonly in the gastric antrum, that typically manifests with indolent bleeding and iron deficiency anemia (► **Fig. 1**). Approximately 30% to 40% of patients with GAVE have cirrhosis, while approximately 2–12% of cirrhotics develop GAVE [6, 7]. Despite this association between GAVE and cirrhosis, bleeding from GAVE does not respond to therapy directed at reducing portal blood pressure, suggesting that it may be an immunologic or hormonal phenomenon [8]. GAVE is also associated with chronic kidney disease [1, 9], heart disease [1, 10] and autoimmune connective tissue diseases such as systemic sclerosis [9, 11].

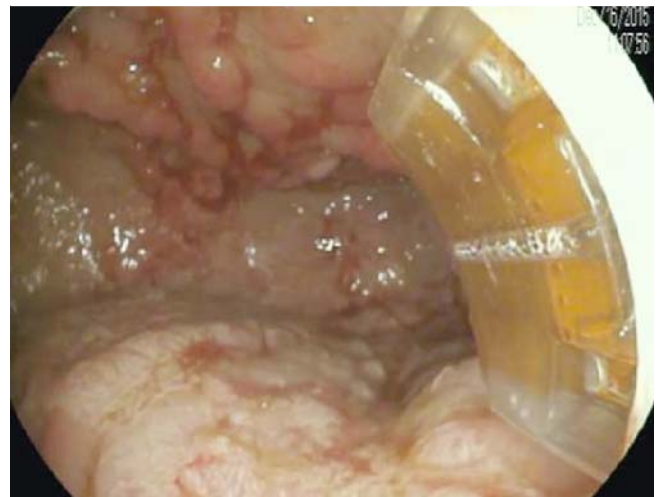Endoscopic therapy aimed at mucosal ablation remains the main therapy as data supporting the benefit of medical therapy remains limited [1]. Bleeding from GAVE can be recalcitrant despite endoscopic therapy, with studies showing 2 to 3 treatment sessions with APC are needed to achieve short term treatment success, and only a 25% treatment success rate at 5 years [2, 4, 5, 12]. RFA has emerged as a promising alternative to APC owing to the larger, per-treatment, surface area afforded by RFA catheters and its reproducible depth of treatment effect (► **Fig. 2**). Dray and colleagues showed that a mean of 1.8 RFA treatment sessions resulted in a significant decrease in transfusion requirements [13]. A slightly smaller prospective but non-randomized trial showed that RFA resulted in a mean hemoglobin increase from 7 to 10g/dL, with most patients achieving transfusion independence at 6 months [14]. These are the largest studies to date involving RFA in the treatment of GAVE, with several smaller studies also supporting RFA's benefit in decreasing need for endoscopic therapy [15], transfusions [16, 17], and mean hemoglobin [17].

In this study, the HALO-90 catheter was utilized in 93% of the exams that employed RFA. In our experience, this is the ideal catheter to use because of its large surface area and because we do not find it more difficult to pass into the esophagus than the smaller HALO-60 catheter. While there is also a Channel RFA catheter that can be passed through the device channel instead of being attached to the tip of the endoscope, this was not employed in any of the exams reviewed for this study, likely because its surface area is even smaller than that of the HALO-60.

Cost is an obvious consideration when choosing a therapeutic modality. Though a full cost analysis was beyond the scope



► **Fig. 1** Endoscopic appearance of untreated gastric antral vascular ectasia.



► **Fig. 2** Application of treatment with RFA using Halo-90. The area from 4 to 7 o'clock shows treatment effect.

of this study, we do point out that currently, RFA catheters are considerably more expensive than those used for APC. At our institution in the United States, our current costs are \$243.50 for the single-use APC catheter used in this study and \$1222 for the HALO-90 catheter.

## Conclusion

Our study describes the largest reported GAVE cohort with 81 patients treated with RFA, APC or both. It is the first study to attempt to compare RFA to APC for the management of GAVE and the first to consider the presence or absence of cirrhosis in these patients. Despite the anecdotal experience of these authors, RFA did not prove superior to APC in this retrospective analysis of a large cohort of GAVE patients. Hgb values remained stable or increased in all patients during our study period and there were no significant differences in Hgb trend between

APC and RFA. Though we found subtle differences, patients underwent a similar number of treatment sessions and had similar procedure times and a similar time between sessions no matter the treatment modality used.

There are several limitations of our study. It was retrospective and therefore patients were not randomized to the treatment modality used. Within our current method of practice, sicker patients with more severe GAVE were more likely to be treated with RFA, which is likely 1 of the reasons RFA was not found to be superior. Given the retrospective nature of this study, the time intervals between procedures sometimes reflect scheduled surveillance and sometimes reflect on-demand therapy for worsening symptoms. Another limitation is that many of these patients were seen in our capacity as a tertiary endoscopic referral center and were therefore not primarily followed at our institution and so uniform data at regular intervals were not available for our cohort. A prospective randomized controlled study comparing the efficacy of RFA compared to APC in the management of GAVE would be welcome.

### Competing interests

None

### References

- [1] Fuccio L, Mussetto A, Laterza L et al. Diagnosis and management of gastric antral vascular ectasia. *World J Gastrointestinal Endosc* 2013; 5: 6–13
- [2] Yusoff I, Brennan F, Ormonde D et al. Argon plasma coagulation for treatment of watermelon stomach. *Endoscopy* 2002; 34: 407–410
- [3] Roman S, Saurin JC, Dumortier J et al. Tolerance and efficacy of argon plasma coagulation for controlling bleeding in patients with typical and atypical manifestations of watermelon stomach. *Endoscopy* 2003; 35: 1024–1028
- [4] Boltin D, Gingold-Belfer R, Lichtenstein L et al. Long-term treatment outcome of patients with gastric vascular ectasia treated with argon plasma coagulation. *Europ J Gastroenterol Hepato* 2014; 26: 588–593
- [5] Sato T, Yamazaki K, Akaike J. Endoscopic band ligation versus argon plasma coagulation for gastric antral vascular ectasia associated with liver diseases. *Dig Endosc* 2012; 24: 237–242
- [6] Ward EM, Raimondo M, Rosser BG et al. Prevalence and natural history of gastric antral vascular ectasia in patients undergoing orthotopic liver transplantation. *J Clin Gastroenterol* 2004; 38: 898–900
- [7] Yamada M, Ichikawa M, Takahara O et al. Gastroduodenal vascular ectasia in patients with liver cirrhosis. *Dig Endosc* 1999; 11: 241–245
- [8] Spahr L, Villeneuve JP, Dufresne MP et al. Gastric antral vascular ectasia in cirrhotic patients: absence of relation with portal hypertension. *Gut* 1999; 44: 739–742
- [9] Gostout CJ, Viggiano TR, Ahlquist DA et al. The clinical and endoscopic spectrum of the watermelon stomach. *J Clin Gastroenterol* 1992; 15: 256–263
- [10] Selinger CP, Ang YS. Gastric antral vascular ectasia (GAVE): an update on clinical presentation, pathophysiology and treatment. *Digestion* 2008; 77: 131–137
- [11] El-Gendy H, Shohdy KS, Maghraby GG et al. Gastric antral vascular ectasia in systemic sclerosis: Where do we stand? *Int J Rheum Dis* 2017; doi:10.1111/1756-185X.13047
- [12] Swanson E, Mahgoub A, MacDonald R et al. Medical and endoscopic therapies for angiodysplasia and gastric antral vascular ectasia: a systematic review. *Clin Gastroenterol Hepatol* 2014; 12: 571–582
- [13] Dray X, Repici A, Gonzalez P et al. Radiofrequency ablation for the treatment of gastric antral vascular ectasia. *Endoscopy* 2014; 46: 963–969
- [14] McGorisk T, Krishnan K, Keefer L et al. Radiofrequency ablation for refractory gastric antral vascular ectasia (with video). *Gastrointest Endosc* 2013; 78: 584–588
- [15] Raza N, Diehl DL. Radiofrequency ablation of treatment-refractory gastric antral vascular ectasia (GAVE). *Surg Laparosc Endosc Percuta Tech* 2015; 25: 79–82
- [16] Jana T, Thosani N, Fallon MB et al. Radiofrequency ablation for treatment of refractory gastric antral vascular ectasia (with video). *Endoscopy Intern Open* 2015; 3: E125–E127
- [17] Gross SA, Al-Haddad M, Gill KR et al. Endoscopic mucosal ablation for the treatment of gastric antral vascular ectasia with the HALO90 system: a pilot study. *Gastrointest Endosc* 2008; 67: 324–327