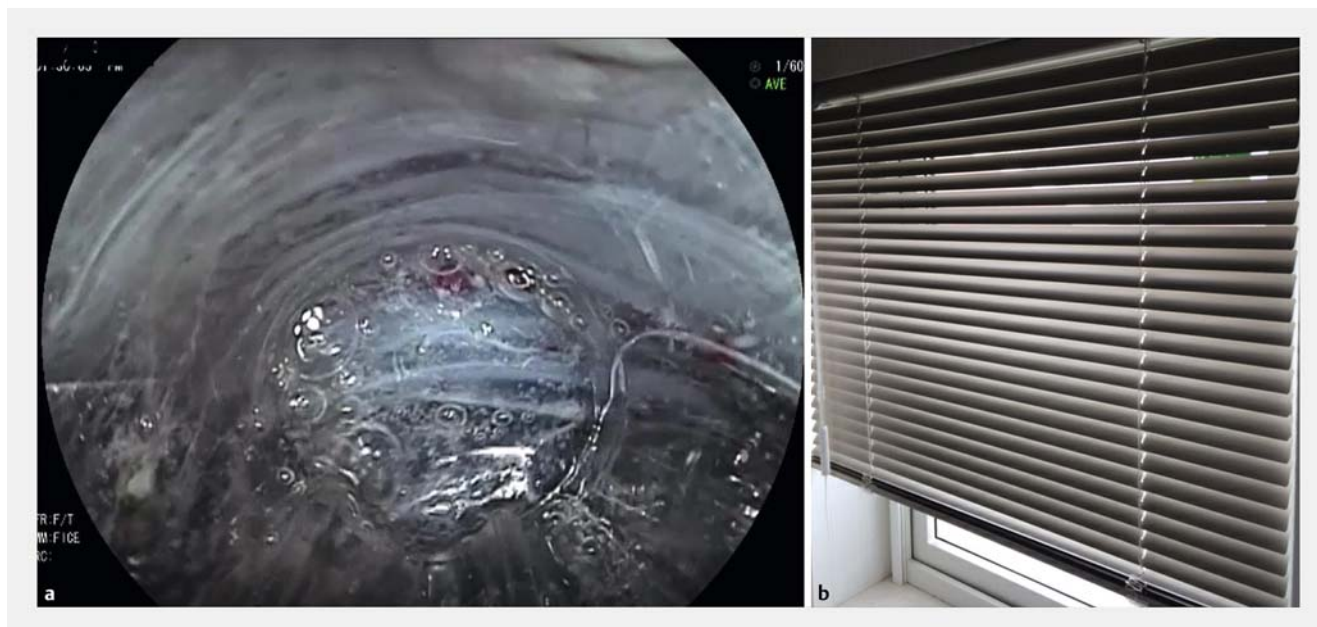

Pay attention to a “window-blind” appearance of the distal rectal muscle layer during endoscopic submucosal dissection

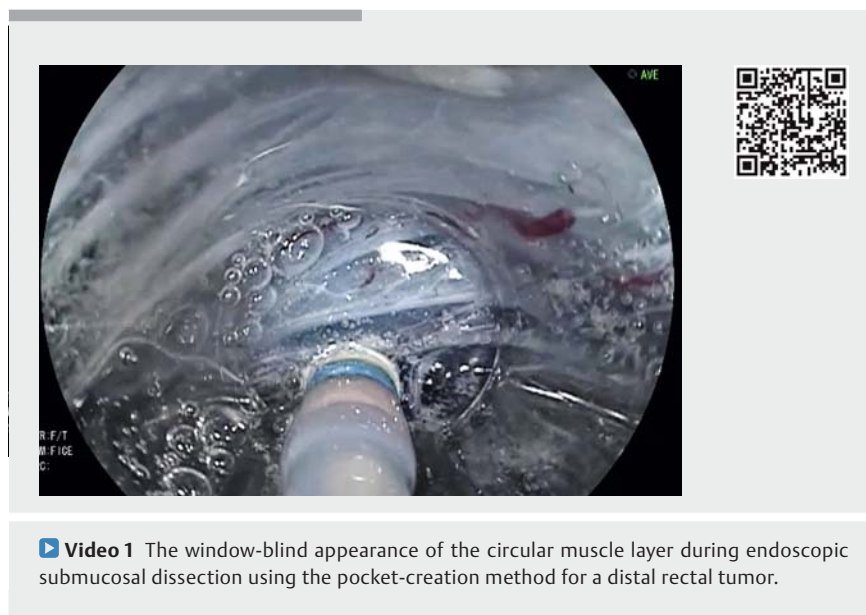


► **Fig. 1** The window-blind appearance. **a** The inner circular muscle layer in the distal rectum has many loose transverse gaps that look like; **b** a window blind.

Endoscopic submucosal dissection (ESD) is increasingly used as a minimally invasive technique for treating superficial gastrointestinal tumors. Rectal ESD using the pocket-creation method (PCM) [1] is relatively easy for endoscopists who are used to performing submucosal endoscopy (e.g. peroral endoscopic myotomy [POEM]), even if they have not performed many ESD procedures.

Initially, creating the submucosal pocket is similar to the technique for POEM. However, there is a unique pitfall when performing distal rectal ESD. The inner circular muscle layer in the distal rectum has many transverse loose gaps between the muscle fibers. Submucosally injected fluid easily disperses outward through the gaps and widens them. We refer to this as a “window-blind” appearance (► **Fig. 1**).

We must pay attention not to dissect in the clear area that looks like submucosa in those gaps. An outer longitudinal muscle layer may prevent penetration if dam-



► **Video 1** The window-blind appearance of the circular muscle layer during endoscopic submucosal dissection using the pocket-creation method for a distal rectal tumor.

age to the circular muscle layer is limited to the region of the anus. However, perforation can occur if the circular muscle layer is damaged in the more proximal

part of the distal rectum. To avoid damage to the circular muscle layer, it is important to maintain a tangential approach to the surface of the circular

muscle layer and ascertain the depth of the submucosa when performing the PCM. The PCM does not need air insufflation to maintain the endoscopic visual field because the transparent hood with small-caliber tip easily maintains the visual field. Refraining from air inflation can make the submucosa thick and the rectal wall tangential (▶ **Video 1**) [2].

The PCM therefore allows us to easily dissect the distal rectal submucosa without a reversal procedure. Although ESD in the distal rectum looks easier than in other areas, one must pay attention to the window-blind appearance to avoid damaging the muscle layer during ESD.

Endoscopy_UCTN_Code_CPL_1AJ_2AD

Competing interests

Hironori Yamamoto has patents for ESD devices produced by Fujifilm Corporation. He also has a consultant relationship with the Fujifilm Corporation and has received honoraria, grants, and royalties from the company. Yoshikazu Hayashi, Yoshimasa Miura, and Keijiro Sunada have received honoraria from Fujifilm Corporation. No other authors have personal financial relationships with a commercial entity producing healthcare-related products and/or services relevant to this article.

The authors

Yoshikazu Hayashi¹, Masahiro Okada¹, Hisashi Fukuda¹, Yoshimasa Miura¹, Keijiro Sunada¹, Alan K. Lefor², Hironori Yamamoto¹

- 1 Department of Medicine, Division of Gastroenterology, Jichi Medical University, Shimotsuke, Japan
- 2 Department of Surgery, Jichi Medical University, Shimotsuke, Japan

Corresponding author

Hironori Yamamoto, MD

Department of Medicine, Division of Gastroenterology, Jichi Medical University, 3311-1 Yakushiji, Shimotsuke, Tochigi, 329-0498, Japan
 Fax: +81-285-448297
 ireef@jichi.ac.jp

References

- [1] Hayashi Y, Miura Y, Yamamoto H. Pocket-creation method for the safe, reliable, and efficient endoscopic submucosal dissection of colorectal lateral spreading tumors. *Dig Endosc* 2015; 27: 534–535
- [2] Hayashi Y, Yamamoto H. Pocket-creation method (PCM) for rectal endoscopic submucosal dissection (ESD). *Intestine* 2017; 21: 211–218

Bibliography

DOI <https://doi.org/10.1055/s-0043-124177>
 Published online: 12.1.2018
 Endoscopy 2018; 50: E67–E68
 © Georg Thieme Verlag KG
 Stuttgart · New York
 ISSN 0013-726X

ENDOSCOPY E-VIDEOS

<https://eref.thieme.de/e-videos>



Endoscopy E-Videos is a free access online section, reporting on interesting cases and new

techniques in gastroenterological endoscopy. All papers include a high quality video and all contributions are freely accessible online.

This section has its own submission website at

<https://mc.manuscriptcentral.com/e-videos>