

Electromagnetic assisted endoscopic submucosal dissection is more efficient than water-jet assisted and conventional ESD in experimental model

OPEN
ACCESS

Authors

Joaquín Rodríguez Sánchez^{1,2}, Eduardo Rodríguez Sánchez¹, Eva de la Santa Belda¹, Pilar Palomar Olivencia¹, Rosario Salmoral Luque¹, Mónica Sánchez Alonso¹, José Olmedo Camacho¹, Francisco Javier Redondo Calvo²

Institutions

- 1 Gastrointestinal Endoscopy Unit. Hospital General Universitario de Ciudad Real, Ciudad Real (Spain)
- 2 Translational Research Unit. Hospital General Universitario de Ciudad Real, Ciudad Real (Spain)

submitted 2.11.2017

accepted after revision 18.12.2017

Bibliography

DOI <https://doi.org/10.1055/s-0043-125364> |
Endoscopy International Open 2018; 06: E498–E504
© Georg Thieme Verlag KG Stuttgart · New York
ISSN 2364-3722

Corresponding author

Joaquín Rodríguez Sánchez, MD, PhD, Gastrointestinal Endoscopy Unit, Hospital General Universitario de Ciudad Real, C/Obispo Rafael Torija s/n. 13005, Ciudad Real, Spain
Fax: +0034 926278000
joakinrodriguez@gmail.com

ABSTRACT

Background and study aims The adequate visualization of the dissection line, inside the submucosal layer, supposes the main challenging issue in ESD. For this reason, several counter traction methods have been developed focused on overcoming this handicap. One of which, Magnetic anchor

guided-ESD (MG-ESD) is an attractive alternative. However, the usefulness of this approach has been scarcely assessed and compared with other ESD strategies. Therefore, the aim of this study is to compare three different ESD alternatives in experimental faction.

Methods This was a prospective non-randomized study, in which three different ESD techniques were performed in an ex-vivo gastric porcine model by an endoscopist slight expertise in ESD: conventional ESD, waterjet assisted ESD and MG-ESD. MG-ESD was performed using two different magnets: inner Neodymium ringed shape magnet attached to the simulated lesions by an endoclip and external electromagnet connected to a Single Output Adjustable 24V/0.3A Power Supply Unit.


Results Forty-six ESD procedures were performed: 24 conventional ESD, 12 waterjet-assisted ESD and 10 MG-ESD. Average size of the simulated lesions was 33.86 mm. No differences in terms of safety and efficacy were registered between the three approaches. Nevertheless, MG-ESD proved to be faster and more efficient than conventional ESD and water-jet assisted ESD (min per cm² 10.85 vs. 7.43 vs. 3.41; $P=0.001$).

Conclusions MG-ESD could be a feasible alternative to conventional ESD even at the beginning of the learning curve. Therefore, researches focused on developing appropriate ESD magnetic devices and further comparative studies must be promoted, in order to assess the reliable usefulness of the magnet-assistance in ESD.

Introduction

Endoscopic submucosal dissection (ESD) is an advanced endoscopic procedure that has enabled en-bloc resection in lesions of any size. Moreover, ESD is a suitable technique for achieving curative resection in fibrotic and difficult polyps, with recurrence rates lower than endoscopic mucosal resection (EMR) [1]. However, in western countries, ESD is not a widely used because of the long learning curve [2], high risk of adverse events (AEs), and amount of time necessary to perform ESD (an aver-

age of 54 to 116 minutes per procedure) [3]. Avoidance of inappropriate visualization of the submucosal plane becomes crucial to perform the procedure safely because it can result in inadvertent cutting of blood vessels or the muscular layer. The reason for this drawback of the ESD procedure is that it is done entirely through a single endoscope port, unlike conventional and laparoscopic surgery. To overcome this issue, several traction techniques have been developed [4]. One of them – Magnetic anchor guided-ESD (MG-ESD) – is an attractive alternative, since it poses several advantages compared to other trac-



► **Fig. 1** Electromagnetic device. **a** External electromagnet assembled on a double-jointed mechanical arm that addresses different positions. This device is plugged into the Single Output Adjustable 24V/0.3A Power Supply Unit. **b** External electromagnet (50 mm × 50 mm) and Neodymium inner magnet (10 mm × 10 mm). **c** Inner magnet attached by 2/0 suture silk to hemoclips and assembled in the endoscope.

tion methods. First, it addresses traction independent of the endoscope movements, acting as an invisible second hand for the operator. Second, external magnets allow dynamic traction providing the possibility of changing the direction and power of the traction, depending on the operator's preferences [5]. MG-ESD has been successfully tested in animal models [6], even in small human series of cases [7]. Despite these promising preliminary results, there is only one comparative study in an ex vivo gastric model, of conventional ESD (ESD) versus MG-ESD. This study shows how MG-ESD is more efficient than ESD, and equivalent in terms of safety [8]. On the other hand, waterjet-assisted ESD consists of pressure-controlled injection of fluids through the tip of a waterjet knife. This procedure has recently been shown to be as safe as conventional ESD, but more efficient [9]. However, waterjet-assisted ESD and MG-ESD have not been compared so far. The purpose of this study was to analyze the feasibility, safety, and efficiency of MG-ESD compared with conventional and waterjet-assisted ESD in a gastric porcine ex-vivo model.

Methods

Study design

Non-randomized consecutive ESD procedures performed in ex-vivo gastric porcine models with different ESD techniques were included in the study. The aim of the study was to compare the outcomes of the different ESD techniques, especially focused on MG-ESD in terms of safety (rate of injuries in muscular layer or perforation), efficiency (time consumption per procedure) and efficacy (R0 resection rate). All data were prospectively collected in an electronic database.

Description of the electromagnetic device

The magnetic device consists of two different magnets: inner magnet and external electromagnet connected to a Single Output Adjustable 24V/0.3A Power Supply Unit. The inner one is composed of a Neodymium ringed shape magnet (10 mm × 10 mm), which is attached by 2/0 suture silk to hemostatic clips (Resolution clips, Boston Scientific, Natick, Massachusetts, USA). The external electromagnet is assembled on a double-jointed mechanical arm that allows different positions (► **Fig. 1**).

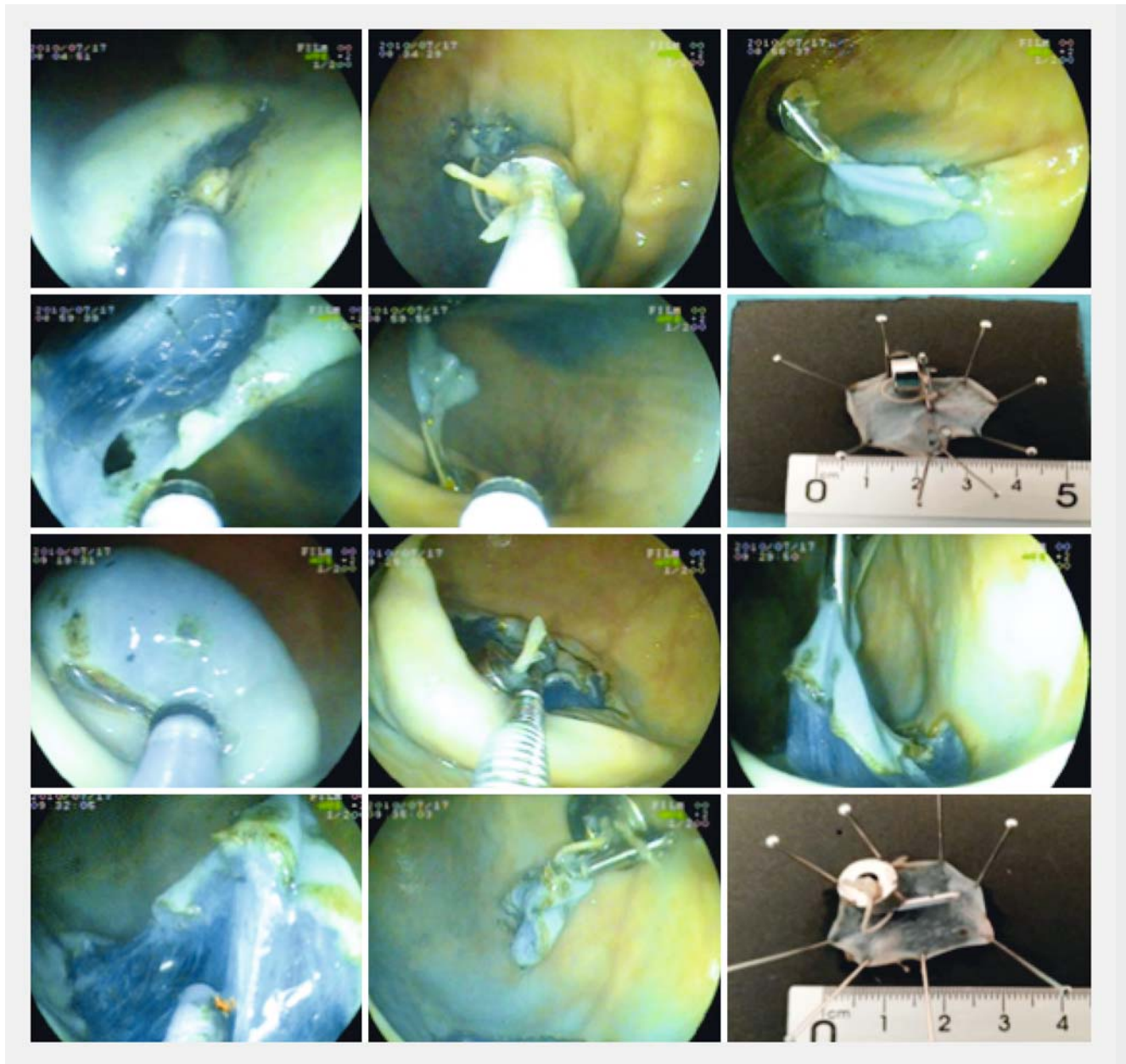
Gastric ESD model preparation

A 4-cm incision was made at the greater curvature in the upper body of the resected porcine stomachs. The stomachs were then cleaned with the mucosal surface exposed. Afterwards, the specimens were mounted in a plastic simulation box. Subsequently, the ESD model was ready to start the procedures; lesions were simulated by marking dots with forced coagulation current (6 to 8 dots spaced-out 2 mm between each other).

ESD procedure

A single endoscopist with minimal expertise in ESD (less than 50 real ESDs) (J.R.S) performed all procedures using Splash-M Knife and Mucosectom 2 Knife (Pentax Medical, Tokyo, Japan), which have shown to be suitable devices for conventional ESD. Furthermore, these knives were also used for MG-ESD [10, 11]. For waterjet-assisted ESD, Erbejet 2 Hybrid Knife (Erbe Elektromedizin GmbH, Tübingen, Germany) was used, which in animals has previously been to be as effective as traditional ESD knives [12].

In conventional ESD and MG-ESD groups, following submucosal injection of saline, a complete circumferential incision was performed in all cases. The same procedure was carried out for the waterjet-assisted ESD group avoiding the needle for submucosal injection (water-jet assistance by hybrid knife).



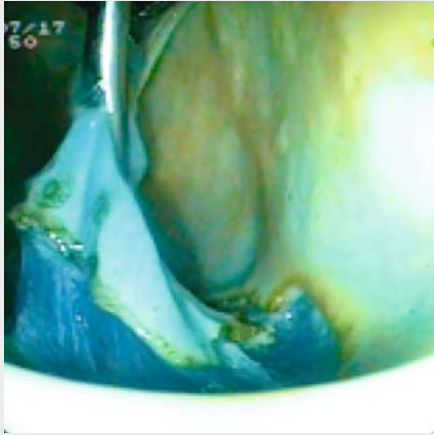► **Fig. 2** Magnetic anchor guided-ESD procedures.

Subsequently, in the conventional ESD and waterjet-assisted ESD groups, submucosal dissection was performed using the conventional technique. The endoscope tip and a flexible cap attached were used to visualize the submucosal dissection line and saline was injected into the submucosal layer to perform the procedures.

In the MG-ESD group, once the circumferential incision had been performed, the magnet was mounted outside the specimen, assembling it on a reopening capability endoclip (Resolution clip), inserted through the working channel (► **Fig. 1c**). Afterward, the endoscope was reinserted on the gastric cavity with the magnet assembled, fixing it on top of the lesion. Then, progressive and adjustable current (0–24 V) was applied using the external electromagnet power supply unit to achieve a suit-

able lift to visualize the submucosal layer by the dynamic pull of the inner magnet (► **Fig. 1a** and ► **Fig. 2**). Thereafter, the dissection was carried out (► **Fig. 2** and ► **Video 1**). Successful R0 resection was considered when all the dots were included in the resected specimen. Time consumption was recorded separately for circumferential incision and submucosal dissection, and maximum diameter of the specimen was determined following the resection.

Once the procedures were ended, endoscopic and macroscopic careful inspections of the scars were carried out in order to recognize adverse events related with the technique (muscular injuries or opened perforations).



Video 1 Magnet assisted ESD performed in ex vivo gastric fundus.

Statistics

The PASW21 statistical package (SPSS, Chicago, Illinois, United States) was used. Categorical variables were described with percentages and continuous variables were described with mean (standard deviation; SD) or median (range) as appropriate. Associations between categorical variables were tested with the χ^2 test and continuous data were assessed using the t-test and ANOVA. *P*-values lower than 0.05 were considered statistically significant.

Ethics

The current study has been approved by the animal experimentation ethics committee of our Hospital. All the procedures have been performed in the experimental endoscopy unit (translational research unit of Ciudad Real University General Hospital).

Results

Forty-six ESD procedures were performed from October 2016 to March 2017: 24 conventional ESD, 12 waterjet-assisted ESD and 10 MG-ESD. Average size of the simulated lesions was 33.86 ± 11.30 mm; no differences were found between the three groups ($P=0.23$). There were no differences in terms of location of the lesions as well (greater curvature: 66.7% ESD vs. 58.3% W-DSE vs. 40% MG-ESD; $P=0.07$).

ESD procedures

R0 resection was achieved in 32 out of 46 procedures (69.6%) with no differences between MG-ESD and others ($P=0.96$). However, time consumption per procedure was lower in MG-ESD procedures (average of 22.90 min vs. others 46.66 min; $P<0.001$). Therefore, dissection phase was faster by MG-ESD (3.41 min/cm² vs. others 9.68 min/cm²; $P<0.001$). Thereby, it is noteworthy that MG-ESD was also faster than waterjet-assisted ESD ($P=0.003$). All the data are summarised in **Table 1**.

Undesirable events rate

All adverse events were registered performing conventional ESD. These were: muscular layer injury in 6 out of 46 procedures (13%) and opened visceral perforation in 2 out of 46 procedures (4.3%) (**Table 2**).

Technical failures

In 3 out of 46 procedures, undesirable technical events were registered. However, only in 1 case, with conventional ESD, the procedure had to be reconverted into hybrid ESD because of difficulties with the endoscope manoeuvrability. Neither MG-ESD, nor the waterjet-assisted ESD was interrupted and reconverted in Hybrid ESD. Nevertheless in case of MG-ESD, 2 out of 10 cases the clips that anchored the magnets to the lesions were detached and had to be reinserted (due to the excessive magnetic counter traction) (**Table 2**).

Discussion

We present the first comparative study of magnetic counter traction ESD method and waterjet assisted ESD, in which both procedures show equivalency in terms of efficacy and safety, with efficiency in favor of MG-ESD. Likewise, these techniques have shown better results than conventional ESD, especially in terms of safety, even when performed by an endoscopist with minimal experience in ESD (less than 50 real procedures). This is noteworthy, owing to the fact that in western countries as far as it is known, expertise in ESD is hardly ever achieved at the beginning of the learning period [2, 13].

In a recent observational study [14], lack of counter traction guided by gravity has shown to be an independent predictive factor for difficult ESD, so the development of devices to help overcome this drawback is required. Kobayashi et al. [6] published the first series of cases in which endoscopic resection was assisted by an electromagnet. Despite their positive results, the procedure was complex to carry out, due to the size of the external electromagnet, difficult to suit in a conventional endoscopy room. In our study, we have tried to overcome this drawback by designing a portable device easy to adapt in any stretcher (**Fig. 1a**). There is only one study focused on comparing MG-ESD and conventional ESD, which found results similar to ours [8]. Unfortunately, the authors did not include information on any outcomes concerning adverse events. In terms of safety, our results are in agreement with those of Gotoda et al. [7] in human cases. Regarding technical features, in the comparative study performed by Aihara et al. [8], a double channel endoscope was necessary in order to anchor the magnet at two different points. However, from our point of view, the device could work just using one anchorage point, and therefore, the procedure would be easier to carry out. Regarding waterjet-assisted ESD using Hybrid Knife, our results are consistent with reports in the only comparative study between waterjet-assisted ESD and conventional ESD [9], which showed waterjet-assisted ESD was both a faster and safer approach than ESD (20% faster and less need of coagulation forceps). Furthermore, our preliminary experience with MG-ESD even improves

► **Table 1** Baseline characteristics of the simulated lesions depending on the different ESD procedures.

	All ESD procedures	Conventional ESD n = 24	Waterjet-assisted ESD n = 12	Magnetic anchor-guided ESD n = 10	P value	P value ¹ (waterjet vs. magnet-assisted ESD)
Size (mm)	30.86	33.37	26.58	30	0.23 ²	0.35 ⁴
Gastric locations						
Fundus	4/46 (8.7%)	1/24 (4.2%)	0/12 (0%)	3/10 (30%)	0.08 ³	0.07 ³
Subcardial area	9/46 (19.6%)	5/24 (20.8%)	1/12 (8.3%)	3/10 (30%)		
Lesser curvature	3/46 (6.5%)	1/24 (4.2%)	2/12 (16.7%)	0/10 (0%)		
Greater curvature	27/46 (58.7%)	16/24 (66.7%)	7/12 (58.3%)	4/10 (40%)		
Antrum	3/46 (6.5%)	1/24 (4.2%)	2/12 (16.7%)	0/10 (0%)		
R0 resection rate	32/46 (69.6%)	17/24 (70.8%)	8/12 (66.7%)	7/10 (70%)	0.96 ³	0.86 ³
Minutes per procedure mean, (SD)	42.28 (25.23)	58.16 (24.58)	26.66 (7.17)	22.90 (12.70)	<0.001 ²	0.42 ⁴
Magnetic device insertion (SD)	—	—	—	1.30 (1.21)	—	—
Timing of circumferential cutting phase, mean, (SD)	18.65 (12.24)	23.25 (15.11)	13.91 (3.62)	13.30 (5.61)	0.02 ²	0.76 ⁴
Timing of dissection phase, mean, (SD)	42.28 (25.23)	33.25 (9.06)	12.75 (4.37)	7.88 (5.64)	<0.001 ²	0.03 ⁴
Minutes per cm², mean, (SD)	8.29 (5.69)	10.85 (6.32)	7.43 (3.30)	3.41 (1.82)	0.001 ²	0.003 ⁴

¹ waterjet-assisted ESD vs. MG-ESD.

² ANOVA Test

³ Chi square test

⁴ Student's t test

upon these figures (min/cm²: 7.43 vs. 3.41; $P=0.003$). However, we must keep in mind that MG-ESD does not avoid instrument exchange. Moreover, in order to perform MG-ESD, it is necessary to insert the hemoclip in the lesion, which is also a time-consuming step compared with other ESD approaches (average 1.30 minutes per procedure). Both conditions (instrument exchange and insertion of the hemoclip) pose drawbacks compared with a waterjet-assisted procedure.

Lack of operator expertise, of necessity, influenced the timing and technical outcomes of the procedures performed in our study. However, as we see it, that cannot be considered a bias because all the resections were performed by the same endoscopist. Therefore, MG-ESD performed by an expert in ESD could achieve better results. Another remarkable handicap was that in 20% of the procedures, the clips were detached due to excessive attraction of the magnets. This fact led to delays and suggested that the technique might be troublesome to carry out. On the other hand, taking into account that waterjet-assisted ESD is considered a variant of traditional technique, a combina-

tion of this approach assisted by magnet counter traction might further improve the efficiency of this procedure.

In contrast to other counter-traction methods (clip-assisted methods), the MG-ESD procedure facilitates movement of the target tissue independently from the knife, as in surgery, and the direction and tension of traction can be controlled at will. In addition, this technique may be cheaper than other strategies such as use of an endolifter or the double-channel scope method [15].

Despite our satisfactory and preliminary results, the lack of bleeding risk in ex vivo ESD models is the main bias of this study that we acknowledge. In addition, it has been estimated that approximately 70% of procedure time during ESD is spent handling bleeding by inexperienced operators [16]. Use of porcine model is a suitable way to acquire the appropriate skills to achieve the expertise.

Apart from that, there are two relevant limitations regarding MG-ESD. First, permanent magnets, especially the Neodymium type, have low resistance to corrosion inside the human body.

► **Table 2** Undesirable events during ESD procedures.

	All ESD procedures	Conventional ESD n = 24	Waterjet-assisted ESD n = 12	Magnetic anchor-guided ESD n = 10	P value ¹
Adverse events					
Opened perforation	2/46 (4.3%)	2/24 (8.3%)	0/12 (0%)	0/10 (0%)	0.38
Muscular layer injury	6/46 (13%)	6/24 (25%)	0/12 (0%)	0/10 (0%)	0.04
Technical failures					
ESD called off (reconversion in Hybrid ESD)	1/46 (2.2%)	1/24 (4.2%)	0/12 (0%)	0/10 (0%)	0.46
Other events	2/46 (4.3%)	0/24 (0%)	0/12 (0%)	2/10 ² (20%)	0.02

¹ Chi-square test.

² inner magnet-hemoclip released and reinserted.

Thus, an inert non-ferromagnetic coating (gold or epoxy resin) must be used to prevent release of harmful substances [17]. Second, the distance between magnets is a noteworthy factor in establishment of suitable counter-traction power. Therefore, experimental models have previously shown that the maximal thickness of the abdominal wall for performing MG-ESD varies from 1.5 cm to 4 cm [18]. Hence, the procedure may not be feasible in obese patients. Unfortunately, in our study, we did not measure this meaningful issue.

Conclusion

To sum up, MG-ESD may be a feasible alternative to conventional ESD even at the beginning of the learning curve. That being said, ESD masters could easily exceed our successful preliminary results. Thus, it seems obvious to encourage research focused on developing appropriate ESD magnetic devices. Likewise, further comparative studies performed by experts are required to assess the reliable usefulness of magnet assistance in ESD.

Competing interests

None

References

- [1] Pimentel-Nunes P, Dinis-Ribeiro M, Ponchon T et al. Endoscopic submucosal dissection: European Society of Gastrointestinal Endoscopy (ESGE) Guideline. *Endoscopy* 2015; 47: 829–854
- [2] Kato M, Gromski M, Jung Y et al. The learning curve for endoscopic submucosal dissection in an established experimental setting. *Surg Endosc* 2013; 27: 154–161
- [3] Lee EJ, Lee JB, Lee SH et al. Endoscopic submucosal dissection for colorectal tumors – 1,000 colorectal ESD cases: one specialized institute's experiences. *Surg Endosc* 2013; 27: 31–39
- [4] Imaeda H, Hosoe N, Kashiwagi K et al. Advanced endoscopic submucosal dissection with traction. *World J Gastrointest Endosc* 2014; 6: 286–295
- [5] Mortagy M, Mehta N, Parsi MA et al. Magnetic anchor guidance for endoscopic submucosal dissection and other endoscopic procedures. *World J Gastroenterol* 2017; 23: 2883–2890
- [6] Kobayashi T, Gotohda T, Tamakawa K et al. Magnetic anchor for more effective endoscopic mucosal resection. *Jpn J Clin Oncol* 2004; 34: 118–123
- [7] Gotoda T, Oda I, Tamakawa K et al. Prospective clinical trial of magnetic-anchor-guided endoscopic submucosal dissection for large early gastric cancer (with videos). *Gastrointest Endosc* 2009; 69: 10–15
- [8] Aihara H, Ryou M, Kumar N et al. A novel magnetic countertraction device for endoscopic submucosal dissection significantly reduces procedure time and minimizes technical difficulty. *Endoscopy* 2014; 46: 422–425
- [9] Zhou PH, Schumacher B, Yao LQ et al. Conventional vs. waterjet-assisted endoscopic submucosal dissection in early gastric cancer: a randomized controlled trial. *Endoscopy* 2014; 46: 836–843
- [10] Fujishiro M, Sugita N. Animal feasibility study of an innovated splash-needle for endoscopic submucosal dissection in the upper gastrointestinal tract. *Dig Endosc* 2013; 25: 7–12
- [11] Kawahara Y, Hori K, Takenaka R et al. Endoscopic submucosal dissection of esophageal cancer using the Mucosectom2 device: a feasibility study. *Endoscopy* 2013; 45: 869–875
- [12] Yahagi N, Neuhaus H, Schumacher B et al. Comparison of standard endoscopic submucosal dissection (ESD) versus an optimized ESD technique for the colon: an animal study. *Endoscopy* 2009; 41: 340–345
- [13] Spsychalski M, Skulimowski A, Dziki A et al. Colorectal endoscopic submucosal dissection (ESD) in the West – when can satisfactory results be obtained? A single-operator learning curve analysis *Scand J Gastroenterol* 2017; 52: 1442–1452
- [14] Iacopini F, Saito Y, Bella A et al. Colorectal endoscopic submucosal dissection: predictors and neoplasm-related gradients of difficulty. *Endosc Int Open* 2017; 5: E839–E846

- [15] Imaeda H, Hosoe N, Kashiwagi K et al. Advanced endoscopic submucosal dissection with traction. *World J Gastrointest Endosc* 2014; 6: 286–295
- [16] Yamamoto S, Uedo N, Ishihara R et al. Endoscopic submucosal dissection for early gastric cancer performed by supervised residents: assessment of feasibility and learning curve. *Endoscopy* 2009; 41: 923–928
- [17] Kobiela J, Grymek S, Wojanowska M et al. Magnetic instrumentation and other applications of magnets in NOTES. *Wideochir Inne Tech Maloinwazyjne* 2012; 7: 67–73
- [18] Best SL, Bergs R, Gedeon M et al. Maximizing coupling strength of magnetically anchored surgical instruments: how thick can we go? *Surg Endosc* 2011; 25: 153–159