



Frontal Sinus Trauma Presenting with Frontonasal Cutaneous Fistula: A Unique Case Report

Deepak Kumar Singh¹ Diwakar Shankar¹  Kuldeep Yadav¹ Mohammad Kaif¹ Rakesh Kumar Singh¹

¹Department of Neurosurgery, Dr Ram Manohar Lohia Institute of Medical Sciences, Lucknow, Uttar Pradesh, India

Address for correspondence Diwakar Shankar, Mch Neurosurgery, Department of Neurosurgery, Dr Ram Manohar Lohia Institute of Medical Sciences, Lucknow 110001, India (e-mail: dev123diwakar@gmail.com).

Indian J Neurotrauma 2023;20:57–59.

Abstract

Frontal sinus fractures account for 5 to 15% of craniofacial trauma. Road traffic accidents account for most of the cases. Combined injury of the anterior and posterior table with nasofrontal outflow tract contributes to 67% of craniofacial trauma. We here present an interesting case of a 33-year-old male patient with a traumatic left frontal sinus fracture with a unique presentation of a cutaneous–frontonasal fistula. Treatment algorithms for the management of frontal sinus fractures have been proposed in the past but they should be tailored to the need of the individual patient. Obliteration of the frontonasal outflow tract should be advocated in these cases as they minimize complications.

Keywords

- ▶ frontal sinus fracture
- ▶ frontonasal outflow tract
- ▶ craniofacial injury
- ▶ road traffic accidents
- ▶ anterior table fracture
- ▶ frontonasal cutaneous fistula

Frontal sinus fractures account for 5 to 15% of craniofacial trauma. The thickness of the anterior table of the frontal sinus is 2 to 12 mm while that of the posterior table is 0.1 to 4 mm. Hence, the force needed for anterior table fracture is very high, around 3.6 to 7.1 kN. This is the reason that isolated anterior table fractures account for only 33% of the cases. The frontal sinus drains into the nasal cavity via the ostium present at the inferior–medial corner of the sinus floor with infundibulum of the sinus above and frontal recess below. Also, 25 to 50% of frontal sinus fractures are associated with NFOT injury. We here present an interesting case of a 35-year-old male patient with a traumatic left frontal sinus fracture with a unique presentation of a cutaneous–frontonasal fistula. The patient had a history of trauma 1 year back in a road traffic accident with an open defect on the left side of the forehead. It was observed that the contents poured in the defect emerged from the left nostril without any delay. A thin cut (1.0–1.5 mm) computerized

tomography (CT) scan was done (▶Fig. 1A, B). Injury to the nasofrontal outflow tract (NFOT) was seen (▶Fig. 2B). A necessary preoperative workup was done and the patient was shifted to the operation theater. The NFOT, as well as the frontal sinus cavity, was obliterated with a temporalis muscle patch and the periosteal flap. The bony defect was repaired using polymethyl methacrylate (PMMA) bone cement (▶Fig. 2C). The remaining periosteum was used to cover the repaired defect (▶Fig. 2D). Postoperative CT showed adequate obliteration of the frontal sinus and the NFOT (▶Fig. 1C, D). The patient was discharged on postoperative day 5. On follow-up, no sign of discharge from nostrils was seen.

Thin cuts (1.0–1.5 mm thickness) CT scan of the craniofacial region is the gold standard for diagnosis of frontal sinus injury and provides details needed to plan management. The 3D reconstruction images show the extent of contour deformity. A simple three-step treatment algorithm was proposed by

article published online
January 18, 2023

DOI <https://doi.org/10.1055/s-0043-1760743>.
ISSN 0973-0508.

© 2023. The Author(s).

This is an open access article published by Thieme under the terms of the Creative Commons Attribution License, permitting unrestricted use, distribution, and reproduction so long as the original work is properly cited. (<https://creativecommons.org/licenses/by/4.0/>)

Thieme Medical and Scientific Publishers Pvt. Ltd., A-12, 2nd Floor, Sector 2, Noida-201301 UP, India

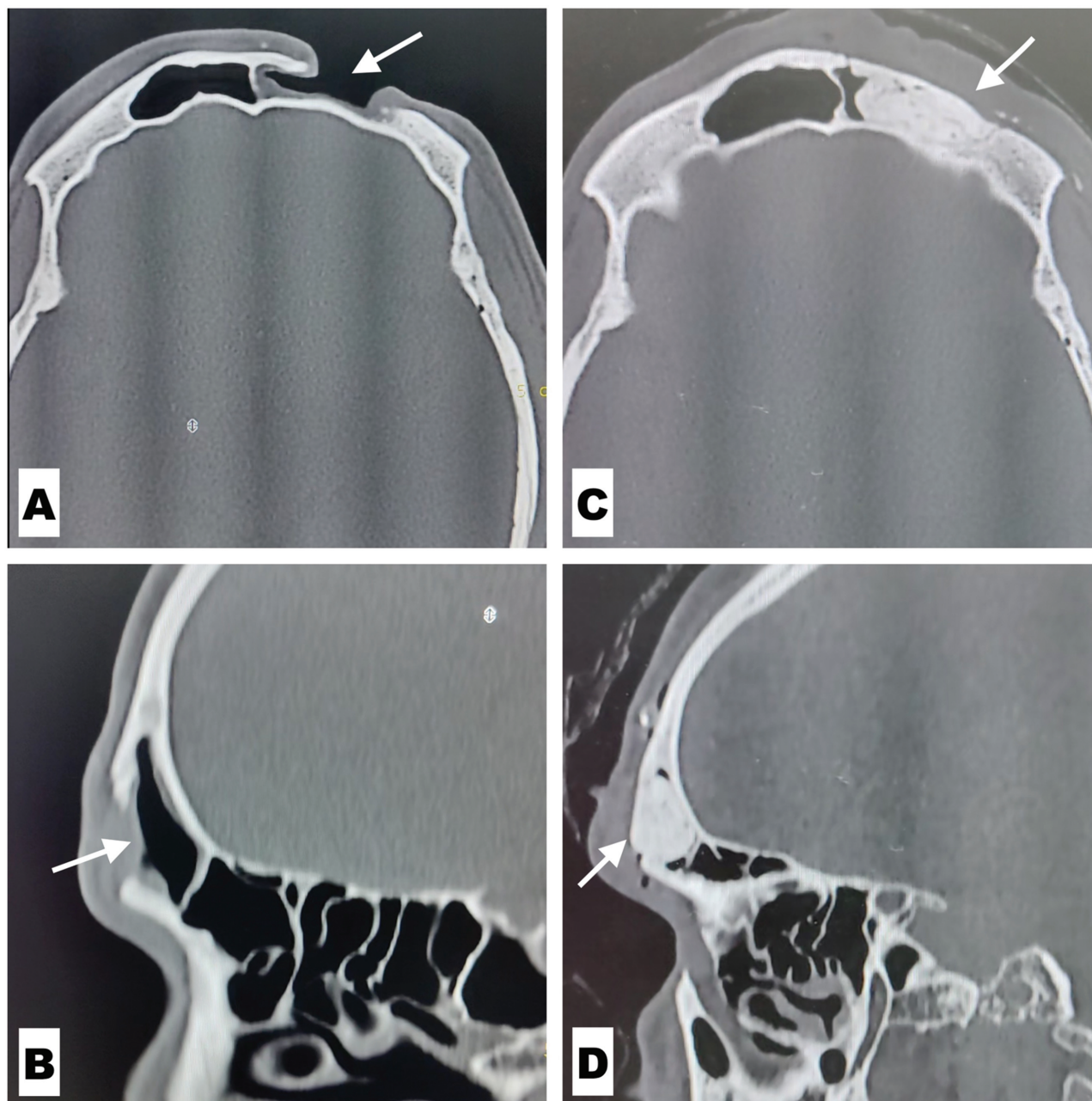


Fig. 1 A 35-year-old male patient with an open wound over the left side of the forehead shown with a black arrow (A). Sagittal CT images showing disruption of the nasofrontal outflow tract (NFOT), shown with a black arrow (B). Intraoperative image of obliteration of the frontal sinus with the reconstruction of the contour with polymethylene methacrylate (PMMA) bone cement, shown with a black arrow (C). Covering the defect and the cranium with remnant pericranium (D).

Echo et al.¹ It included assessment of the posterior table and need for cranialization, assessment of NFOT, and the need for sinus outflow obliteration, and finally reconstruction of the anterior table contour defect. Contour defects can be repaired with biocompatible materials such as titanium mesh, hydroxyapatite, polymethylene methacrylate (PMMA), polyetheretherketone (PEEK) implants.

When the likelihood of a nonfunctional NFOT following trauma is substantial, sinus obliteration is recommended. Sinus obliteration can lower the risk of complications. Some of them will close spontaneously within 7 to 10 days; however,

some will recur and require intervention.² Obliteration entails completely removing the frontal sinus mucosa, removing the inner sinus bone cortex, occluding the frontal recess, and packing the sinus chamber. Bone, temporalis muscle patch, fascia, adipose tissue, or fibrin glue can be used to pack the sinus cavity.

Treatment of frontal sinus fractures incorrectly might result in serious infections and structural complications.³ Hence, a thorough examination of the injury and its sequelae, as well as cautious surgical intervention, is essential.

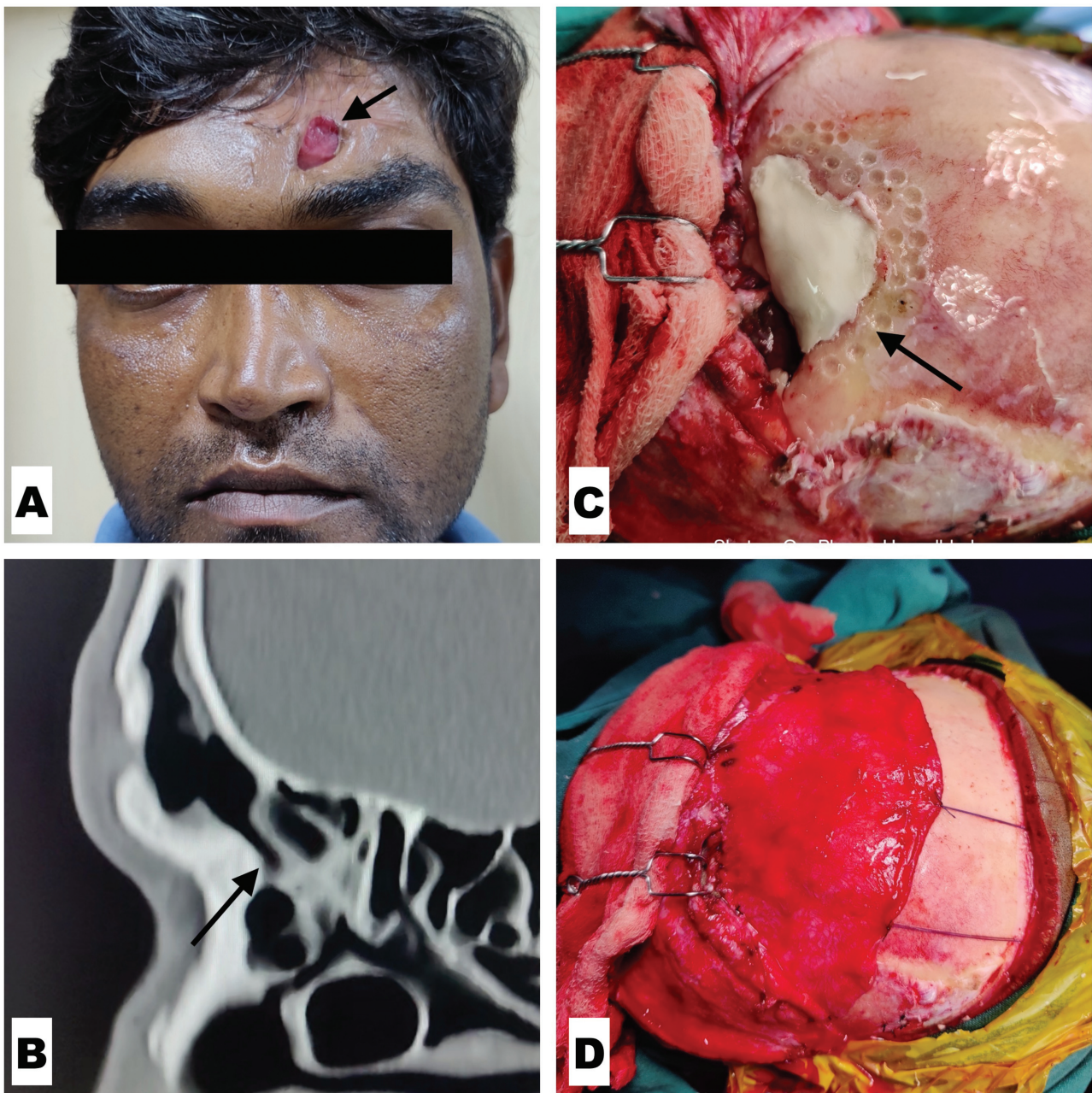


Fig. 2 Preoperative and postoperative axial CT images (A, C) respectively, and sagittal images (B, D) respectively show complete obliteration of the frontal sinus with the adequate reconstruction of the frontal bone contour.

Conflict of Interest
None declared.

Acknowledgments

I would like to thank my mentor and co-author Dr. Deepak Kumar Singh for his care and support in production of this paper.

References

- 1 Echo A, Troy JS, Hollier LH Jr. Frontal sinus fractures. *Semin Plast Surg* 2010;24(04):375–382
- 2 Schlosser RJ, Bolger WE. Nasal cerebrospinal fluid leaks: critical review and surgical considerations. *Laryngoscope* 2004;114(02):255–265
- 3 McGuire TP, Gomes PP, Clokie CM, Sándor GK. Fractures of the supraorbital rim: principles and management. *J Can Dent Assoc* 2006;72(06):537–540