



Incidence, Diagnosis and Treatment of Otorhinolaryngological, Head and Neck Tuberculosis: A Prospective Clinical Study

Biban Chhabra¹ Pratibha Vyas¹ Priyanshi Gupta¹ Prateek Sharma¹ Kanika Sharma¹

¹Department of Otorhinolaryngology and Head and Neck Surgery, Mahatma Gandhi Medical College and Hospital, Jaipur, Rajasthan, India

Int Arch Otorhinolaryngol 2023;27(4):e630–e635.

Address for correspondence Biban Chhabra, M.B.B.S., M.S. ENT, Department of Otorhinolaryngology and Head and Neck Surgery, Mahatma Gandhi Medical College and Hospital, RIICO Institutional Area, Sitapura, Tonk Road, Jaipur, Rajasthan, India 302022 (e-mail: drbibanchhabra@gmail.com).

Abstract

Introduction Tuberculosis is a disease of diversified presentation. It affects almost all organs in the body, and otorhinolaryngological, head and neck involvement is not an exception.

Objective To increase awareness about the different clinical presentations of otorhinolaryngological, head and neck tuberculosis, the techniques employed to diagnose it, and to assess the response to the treatment.

Methods We conducted a prospective study of 114 patients who presented primarily with otorhinolaryngological, head and neck tuberculosis. Routine blood investigations, chest radiographs, the tuberculin test, and sputum examination for the presence of acid-fast bacilli were performed in all cases. Site-specific investigations were performed in relevant cases only. The patients were treated according to the antitubercular treatment (ATT) regimen recommended by the Indian Ministry of Health and Family Welfare's National Tuberculosis Elimination Program (NTEP), and they were followed up clinically two and six months after starting the ATT.

Results Tubercular cervical lymphadenopathy was the most common clinical presentation (85.96%), followed by deep neck abscess (5.27%). Fine-needle aspiration cytology proved to be a reliable tool for the diagnosis of tubercular lymphadenopathy. Improvement at the end of 2 and 6 months of the ATT was observed in 90.35% and 96.50% of the cases respectively.

Conclusion The diagnosis of otorhinolaryngological, head and neck tuberculosis requires a high index of clinical suspicion, and the ATT proved to be very effective in reducing the severity of the disease.

Keywords

- ▶ tuberculosis
- ▶ Mycobacterium tuberculosis
- ▶ lymphadenopathy
- ▶ tuberculin test
- ▶ antitubercular agents

Introduction

Tuberculosis (TB) is a chronic infection with a wide spectrum of symptoms. It is one of the oldest diseases to affect mankind, and is still one of the most common long-term granulomatous

infections, especially in developing countries. It affects almost every organ in the body, including the otorhinolaryngological, head and neck (ORL, H&N) region.

Mycobacterium tuberculosis, a slow-growing strict aerobic bacillus, causes TB, and the human body is the only natural

received
January 29, 2022
accepted after revision
September 12, 2022
article published online
March 24, 2023

DOI <https://doi.org/10.1055/s-0043-1761173>.
ISSN 1809-9777.

© 2023. Fundação Otorrinolaringologia. All rights reserved.
This is an open access article published by Thieme under the terms of the Creative Commons Attribution-NonDerivative-NonCommercial-License, permitting copying and reproduction so long as the original work is given appropriate credit. Contents may not be used for commercial purposes, or adapted, remixed, transformed or built upon. (<https://creativecommons.org/licenses/by-nc-nd/4.0/>)
Thieme Revinter Publicações Ltda., Rua do Matoso 170, Rio de Janeiro, RJ, CEP 20270-135, Brazil

reservoir. It is spread through airborne particles discharged into the air by a patient with infectious TB coughing, talking, or sneezing.¹ The tubercle bacillus is an obligate aerobe which primarily affects tissues with high oxygen tension, such as the lungs. However, the bacillus can affect any body part, and extrapulmonary involvement is frequently secondary to pulmonary involvement.² Among various extrapulmonary types of TB, ORL, H&N TB contributes to ~10% to 15% of the cases. It is an engaging field of exploration because of the different presentations and sites of involvement.

The cervical lymph nodes are most commonly affected. Bacilli can be introduced into the body through the tonsils, pharynx or more commonly through lympho-hematogenous spread from a primary lung focus, causing infection. This disease tends to progress slowly, with the size of the lymph node gradually increasing. Multiple, matted lymph nodes may be observed, and there may be bilateral lymph node involvement. The posterior triangle lymph nodes are involved in most cases.³

In tubercular retropharyngeal abscess, the presenting symptoms are dysphagia to solids (progressive), neck pain, recurrent sore throat, loss of weight, and night sweats.⁴

Tubercular otitis media commonly manifests as persistent otitis media with otorrhea, unresponsive to medical treatment, which is profuse, thick and purulent, and traditionally occurs painlessly. The otoscopic examination can additionally reveal thickened bulging tympanic membrane with loss of landmarks, or multiple perforations, followed by purulent otorrhea.⁵⁻⁷

In laryngeal TB, the presenting symptoms generally encompass change in voice, difficulty in swallowing, loss of weight, and loss of appetite. Fiberoptic laryngoscopic examination shows diffuse erythema/edema of the vocal cords with surface irregularity with white tubercles occasionally.⁴

Patients with nasal TB complain of nasal obstruction and blood-stained nasal discharge. The commonest site is the antero-inferior part of the nasal septum, referred to as the Kiesselbach plexus. In anterior rhinoscopy, a pale, dull mucosa with perforation of the nasal septum can be observed.⁸

Primary tonsillar TB, in the absence of active pulmonary ailment, is rare.⁹ In the secondary form, it may be caused by contact of sputum containing bacilli from a pulmonary focus. It presents nonspecific clinical features and at times it can mimic chronic tonsillitis.¹⁰ The oral examination may additionally reveal hypertrophy of the tonsils, bulge in the oropharynx with edema and erythema, and white plaques on its surface.¹¹

A positive mycobacterial smear and culture or the histopathological presence of a caseating granuloma forms the mainstay of the diagnosis of TB.¹² In the present prospective study, we have examined various clinical presentations of tuberculosis in the ORL, H&N region, the diagnostic techniques employed, and the response of the disease to the treatment.

Materials and Methods

We conducted a prospective study from January 1st, 2020 to June 30th, 2021. All the patients who presented to the Department of Otorhinolaryngology and Head and Neck

Surgery of a tertiary care health center located in Northern India with a high index of clinical suspicion of tubercular lesion and who, on further evaluation, were diagnosed with ORL, H&N TB were included; the exclusion criteria were as follows:

- Previously-treated patients who had taken antitubercular drugs in the past (recurrent TB case or treatment after failure or treatment after loss to follow-up);
- Patients with comorbidities such as HIV or diabetes;
- Cases of multidrug-resistant (MDR) TB.

Detailed history of the patients was taken, and a complete clinical examination, which included a general physical examination, as well as local and systemic examinations, was performed. Routine blood investigations, chest radiographs, the tuberculin test, and the sputum examination for the presence of acid-fast bacilli (AFB) were performed in all the cases.

Fine-needle aspiration cytology (FNAC) of the affected site was performed on all suspected swellings which persisted for more than two weeks despite the prescription of a two-week course of broad-spectrum antibiotics. Computed tomography (CT) scans of the neck with the chest were performed in all cases of deep neck abscess and tubercular laryngitis. Flexible fiberoptic laryngoscopy was performed in cases of laryngeal TB and in cases of deep neck abscess. A mastoid radiograph (Towne's view) was performed in cases of tubercular otitis media. Culture/sensitivity of the ear discharge was sent in cases of tubercular otitis media while performing the examination under the microscope. Nasal swabs were taken in cases of nasal TB while performing the nasal endoscopy.

Few patients needed surgical management, which included an excisional biopsy of the cervical lymph nodes in cases in which the FNAC was inconclusive, incision and drainage in cases of deep neck abscess, tympanoplasty with mastoid exploration in cases of tubercular otitis media, microlaryngeal surgery in cases of laryngeal TB, nasal endoscopy with biopsy in cases of nasal TB, and tonsillectomy in case of tonsillar TB. The tissue obtained after biopsy in all of these cases was sent for a histopathological and cartridge-based nucleic acid amplification test (CBNAAT) to confirm the diagnosis.

Upon confirmation of the diagnosis, as per the guidelines of the Indian Ministry of Health and Family Welfare's National Tuberculosis Elimination Program (NTEP), all of the confirmed cases were notified on the Ni-kshay portal to keep a national record of TB patients who have started treatment and keep strict vigilance until treatment completion and cure.

All patients were treated by antitubercular treatment (ATT) for six months as per the guidelines of the government program.

The treatment was administered in two phases:

I. The intensive phase (IP) consisted of 8 weeks (56 doses) of isoniazid (H), rifampicin (R), pyrazinamide (Z) and ethambutol (E), which were administered under direct observation in daily dosages as per weight group.

Table 1 Daily dose schedule for adults (as per weight group)

Weight group	No. of tablets	No. of tablets
	Intensive phase (HRZE) (dose: 75/150/400/275)	Continuation phase (HRE) (dose: 75/150/275)
25–34 Kg	2	2
35–49 Kg	3	3
50–64 Kg	4	4
65–75 Kg	5	5
>75 Kg	6	6

Abbreviations: HRE, isoniazid, rifampicin, and ethambutol; HRZE, isoniazid, rifampicin, pyrazinamide, and ethambutol.

II. The continuation phase (CP) consisted of 16 weeks (112 doses) of H, R and E in daily dosages. Only Z was discontinued in the CP.

(The CP may be extended by 12 to 24 weeks in certain forms of TB based on clinical decision of the treating physician on case-to-case basis.)

► **Table 1** shows the daily dose schedule for adults (as per appropriate weight group)

► **Table 2** shows the Daily Dose Schedule for Children (as per appropriate weight group)

All the patients had been followed up clinically at the end of two and six months after starting the ATT. The patients were then closely monitored for treatment progress and disease response. Clinical follow-up is the most important criteria to assess the improvement in patients with ORL, H&N TB.

Results

The sample of the present study was composed of 114 subjects: 60 (52.64%) male patients and 54 (47.36%) female patients.

The youngest affected person was a 13-years-old female, and the oldest was a 75-year-old male subject. 34 patients

Table 3 Age distribution of the patients ($n = 114$)

Age in years	No. of patients ($n = 114$)	Percentage (%)
≤ 20	9	7.90%
21–30	34	29.80%
31–40	27	23.70%
41–50	23	20.17%
51–60	9	7.90%
≥ 61	12	10.53%

(29.80%) were in the third decade of life, followed by 27 patients in the fourth decade (23.70%). ► **Table 3** shows the age distribution of the sample.

A total of 98 (85.96%) patients had tubercular cervical lymphadenopathy (85.96%), 6 (5.27%) patients had tubercular deep neck abscess, 4 (3.50%) subjects had tubercular otitis media, 3 (2.64%) had laryngeal TB, 2 (1.75%) had nasal TB, and 1 (0.88%) patient had tonsillar TB. The distribution of patients according to the nature of the lesion is shown in ► **Table 4**.

Neck swelling was observed in 98 (85.96%) subjects, and 62 (63.28%) out of these 98 patients had cervical lymphadenopathy (► **Fig. 1**) at level V (that is, in the posterior triangle of the neck). In total, 6 patients (5.27%) presented with the complaint of difficulty in swallowing, 3 with voice change (2.64%), 4 with discharge in the external auditory canal with complaint of hearing loss (3.50%), 2 with the complaint of nasal bleeding (1.75%), and 1 patient had chronic throat pain (0.88%). The distribution of patients according to symptoms is shown in ► **Table 5**.

Out of the 10 (8.79%) patients (6 with difficulty in swallowing, 3 with voice change, and 1 with chronic throat pain) who presented with throat complaints, a fiberoptic laryngoscopic examination was performed, and the findings were noted. A total of 6 patients showed a bulge over the posterior oropharyngeal wall which was further diagnosed as tubercular deep neck abscess, 2 patients showed diffuse edema over the interarytenoid area, and 1 patient showed polypoidal changes over left vocal cord (► **Fig. 2**), and they were ultimately diagnosed with laryngeal TB. One patient

Table 2 Daily dose schedule for children (as per weight group)

Weight group	No. of tablets (dispersible)	No. of tablets (dispersible)	No. of tablets (dispersible)	No. of tablets (dispersible)
	Intensive phase HRZ (50/75/150)	Intensive phase E (100)	Continuation phase HR (50/75)	Continuation phase E (100)
4–7 Kg	1	1	1	1
8–11 Kg	2	2	2	2
12–15 Kg	3	3	3	3
16–24 Kg	4	4	4	4
25–29 Kg	3 + 1A [#]	3	3 + 1A [#]	3
30–39 Kg	2 + 2A [#]	2	2 + 2A [#]	2

Abbreviations: A[#], adult; E, ethambutol; HR, isoniazid, rifampicin; HRZ, isoniazid, rifampicin, and pyrazinamide.

Notes: A[#]HRZE = 75/150/400/275; HRE = 75/150/275. It is added in higher weight groups, that is, > 25 kg as these children may be able to swallow tablets.

Table 4 Distribution of patients according to nature of lesion (n = 114)

Nature of lesion	No. of cases (n = 114)	Percentage (%)
Tubercular cervical lymphadenopathy	98	85.96%
Tubercular deep neck abscess	6	5.27%
Tubercular otitis media	4	3.50%
Laryngeal tuberculosis	3	2.64%
Nasal tuberculosis	2	1.75%
Tonsillar tuberculosis	1	0.88%

Table 5 Distribution of patients according to symptoms (n = 114)

Symptoms	No. of patients (n = 114)
Neck swelling	98
Discharge in the external auditory canal with hearing loss	4
Voice change	3
Difficulty in swallowing	6
Chronic throat pain	1
Nasal bleeding	2

presenting white plaque over the tonsil was diagnosed with tonsillar TB. ► **Table 6** shows this data.

In the present study, out of the 4 (3.50%) patients that presented with ear complaints, 2 had multiple tympanic membrane perforation (► **Fig. 3**), and the other 2 had pale granulation over the tympanic membrane, and they were all diagnosed as tubercular otitis media. Out of the 2 cases that presented with nasal complaints, 1 patient had septal perforation and the other showed pale nasal mucosa on anterior rhinoscopy which were diagnosed with nasal TB.

All of the 98 (85.96%) suspected cases of tubercular cervical lymphadenopathy underwent FNAC, and 67 of those patients (68.37%) were positive for tuberculosis. The remaining 31 patients required excisional biopsy.

The 6 (5.27%) patients with deep neck abscess underwent incision and drainage; the 4 (3.50%) subjects with tubercular

Table 6 Distribution of patients based on throat findings

Findings	No. of cases (n = 10)	Percentage (%)
Bulge over the posterior oropharyngeal wall	6	60%
Diffuse edema in the interarytenoid area	2	20%
Polypoidal changes over the vocal cord	1	10%
White plaque over the tonsil	1	10%

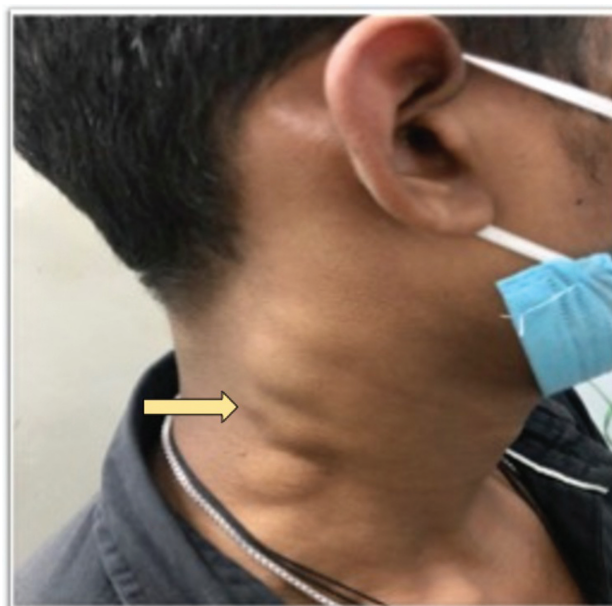


Fig. 1 Lymphadenopathy at level V of the cervical lymph node (the posterior triangle of the neck).

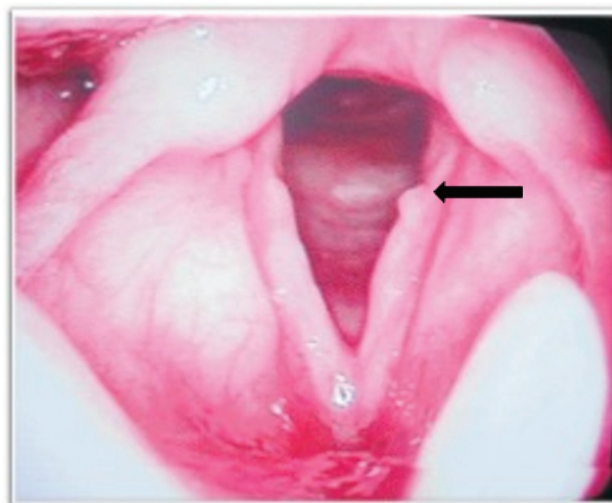


Fig. 2 Polypoidal changes over the left vocal cord.

otitis media were submitted to tympanoplasty with mastoid exploration; the 3 (2.64%) patients with laryngeal TB underwent microlaryngeal surgery; the two (1.75%) subjects with nasal TB were submitted to nasal biopsy; and the only patient (0.88%) with tonsillar TB underwent tonsillectomy. The biopsied specimens were sent for histopathology and CBNAAT, and the results were suggestive of TB, so the patients started the ATT.

The present study was concluded with a 6-month follow-up. The first follow-up visit was by the end of 2 months of the ATT, and 103 (90.35%) out of the total of 114 patients showed improvement and relief regarding the complaints they had upon presentation. However, by the end of 6 months of the ATT, 110 patients (96.50%) showed improvement. The remaining 4 (3.50%) patients continued with the ATT for another 3 months.

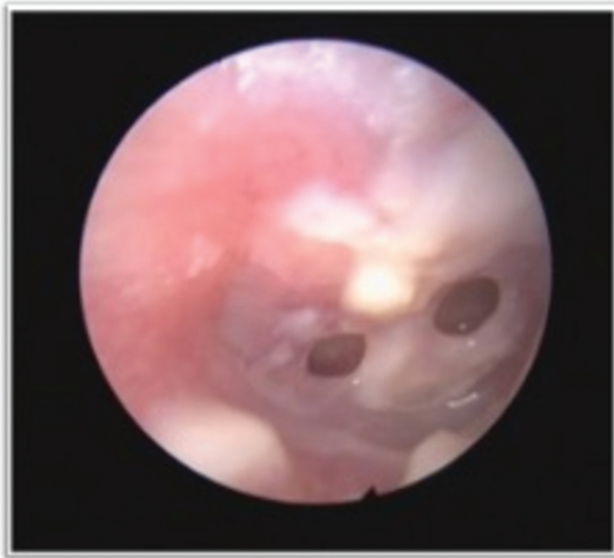


Fig. 3 Multiple perforations of the tympanic membrane.

Discussion

In the present study, out of 114 cases, 60 (52.64%) patients were male and 54 (47.36%) were female. In their studies, Sriram and Bhojwani¹³ and Bokare and Mehta¹ confirmed the same male:female ratio.

The age group of 21–40 years, that is, young adults, comprised most cases in our study. Perlman et al.¹⁴ and Arora and Gupta¹⁵ showed similar findings in their studies.

In the present study, tubercular cervical lymphadenopathy, in 98 cases, (85.96%) was the most common head and neck lesion, which is in accordance with the research performed in different parts of India by Pandurang et al.¹⁶ and Bokare and Mehta¹

Bokare and Mehta¹ mention that the posterior triangle is the most common site of involvement in tubercular cervical lymphadenitis; however, it may have an effect on other sites as well. The present study was not an exception, and we observed that the posterior triangle (Level V) was the site most commonly affected, in 62 (63.26%) out of 98 patients.

Deep neck abscess often has a rapid onset and can progress with life-threatening sequelae which include airway compromise, involvement of the carotid sheath, and septic shock. In the present study, there were 6 (5.27%) cases out of the total of 114 patients. Sriram and Bhojwani¹³ found an incidence of deep neck abscess of 3.8% in their study.

Tubercular otitis media is an unusual entity, and patients with painless discharge no longer responding to antibiotics, hearing loss, and multiple perforations of the tympanic membrane or pale granulations over the tympanic membrane arose the suspicion of it. In the present study, we found only 4 (3.50%) cases, a rate similar to those found by Das et al.¹⁷ (2%) and Akkara et al.¹⁸ (3%) in their case series.

We observed 3 (2.64%) cases of laryngeal TB, and these patients presented with voice change, which is in line with the studies by Bailey and Windle-Taylor¹⁹ and Soda et al.²⁰

The interarytenoid region was the most commonly affected, and Soni and Chatterjee²¹ and showed the similar findings.

Nasal TB is a rare entity even in nations with excessive disease load.²² We found only 2 cases (1.75%) in the present study: 1 patient presented with quadrangular septal cartilage perforation, and the other presented with pale nasal mucosa. Ricciardiello et al.²³ found an incidence of 0.5%.

Patients with tonsillar TB tend to belong to the younger age group, as in our study. We found only 1 case (0.88%), which was similar to the study by Sriram and Bhojwani¹³

Sputum examination for the presence of AFB, the tuberculin test, and chest radiographs were performed in every case. Smear microscopy for the detection of AFB is used to diagnose TB; however the extrapulmonary cases are usually paucibacillary in nature; therefore, sputum smear microscopy is mostly negative. A negative tuberculin test result does not always rule out TB, and it is not recommended for the detection of TB because of its low levels of specificity and sensitivity. Chest radiographs are a primary imaging modality for pulmonary TB, but the role of X-rays in extrapulmonary TB is not significant. The literature²⁴ shows that CT and magnetic resonance imaging (MRI) are crucial in the assessment of ORL, H&N TB, because they accurately show the sites, pattern and extent of the disease.

For the diagnosis of tubercular lymphadenitis, FNAC is an easy and cost-effective investigation;. FNAC of a tubercular lesion typically reveals epithelioid cells, the presence of eosinophilic granular material, multi-nucleated giant cells, and acute inflammatory exudates (→**Fig. 4**). It was found to be positive in 67 (68.37%) out of 98 cases of cervical lymphadenopathy in the present study. Kamal et al.²⁵ and Akkara et al.¹⁸ found the FNAC to be positive in 84% and 96% of their cases respectively. All cases that showed tubercular lymphadenitis on FNAC underwent ATT. This treatment plan is recommended by the Centers for Disease Control and Prevention (CDC) and the World Health Organization (WHO).

The present study showed that the histopathological examination and the CBNAAT had a specificity of 100%, the same rate found by Sachdeva and Shrivastava²⁶ for the CBNAAT in their study.

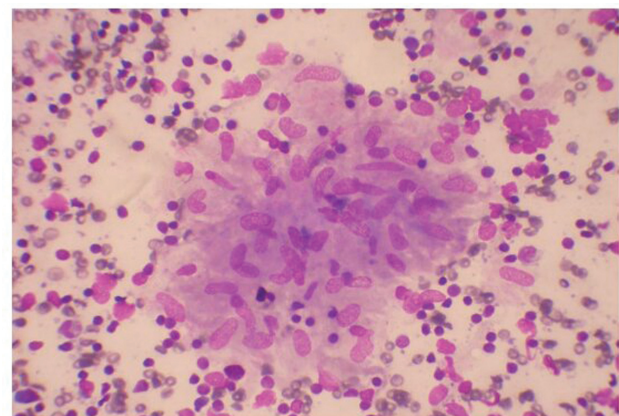


Fig. 4 Fine-needle aspiration cytology (FNAC) smear showing epithelioid granuloma.

Conclusion

Despite the efforts made at every level to control this chronic granulomatous infection, TB is still a rampant disease in India. Cases of ORL, H&N TB are not rare, and they require a high index of suspicion for diagnosis. Hence, an otorhinolaryngologist need to always keep in mind the possibility while making a differential diagnosis. To diagnose tubercular cervical lymphadenopathy, FNAC was found to be a dependable and uncomplicated procedure, and excisional biopsy was indicated when FNAC turned out to be inconclusive. However, more recent diagnostic techniques like CBNAAT increased the yield of positive cases and have been used to confirm TB. The ATT proved to be very powerful in decreasing the severity and frequency of TB manifestations in the ORL, H&N practice.

Tuberculosis is a disease caused by microscopic organisms which have a macroscopic impact in terms of healthcare resources, financial burden, and social stigma. India has been battling this war against the disease since 1962 by creating a national-level TB program, which has been revised and modified numerous times, catering to present needs; however, we still face 2.64 million cases (according to 2019 WHO data) after almost 50 years, which clearly indicates that we have a long battle ahead that needs to be fought with every possible weapon in our arsenal. The present research is our effort in this war.

Conflict of Interests

The authors have no conflict of interests to declare.

References

- Bokare B, Mehta K. Otolaryngological Manifestations of Tuberculosis: A Clinical Study. *Indian J Otolaryngol Head Neck Surg* 2020;•••:1–8
- Ryan KJ, Ray CG. *Medical microbiology*. McGraw Hill; 2004;4:370.
- Manolidis S, Frenkiel S, Yoskovitch A, Black M. Mycobacterial infections of the head and neck. *Otolaryngol Head Neck Surg* 1993;109(3 Pt 1):427–433
- Gupta A, Jamwal PS. (2019). Tubercular lesions in otorhinolaryngology. *MedPulse International Journal of ENT* 12:40–43. Doi: 10.26611/10161228
- Lucente FE, Tobias GW, Parisier SC, Som PM. Tuberculous otitis media. *Laryngoscope* 1978;88(7 Pt 1):1107–1116
- Hoshino T, Miyashita H, Asai Y. Computed tomography of the temporal bone in tuberculous otitis media. *J Laryngol Otol* 1994; 108(08):702–705
- Ng PC, Hiu J, Fok TF, Nelson EA, Cheung KL, Wong W. Isolated congenital tuberculosis otitis in a preterm infant. *Acta Paediatr* 1995;84(08):955–956
- Mota LA, Leitão PC, dos Anjos Carneiro-Leão AM. ENT Manifestations in Tuberculosis. *Tuberculosis (Edinb)* 2015
- Kant S, Verma SK, Sanjay. Isolated tonsil tuberculosis. *Lung India* 2008;25(04):163–164
- Amine C, Amal H, Nawar O, Abdelatif O, Nouredine E. La tuberculose des amygdales palatines. *Pan Afr Med J* 2010;4(01):
- Gupta KB, Tandon S, Jaswal TS, Singh S. Tuberculosis of tonsil with unusual presentation. *Indian J Tuberc* 2001;48(04):223–224
- Michael RC, Michael JS. Tuberculosis in otorhinolaryngology: clinical presentation and diagnostic challenges. *Int J Otolaryngol* 2011;2011:686894
- Sriram R, Bhojwani KM. Manifestations of tuberculosis in otorhinolaryngology practice: a retrospective study conducted in a Coastal City of South India. *Indian J Otolaryngol Head Neck Surg* 2017;69(02):210–215
- Perlman DC, D'Amico R, Salomon N. Mycobacterial infections of the head and neck. *Curr Infect Dis Rep* 2001;3(03):233–241
- Arora VK, Gupta R. Trends of Extra-pulmonary Tuberculosis under Revised National Tuberculosis Control Programme: A study from South Delhi. 2006
- Pandurang K, Shenoy VS, Bhojwani K, Alva A, Prasad V, et al. (2014) Tuberculosis in the Head and Neck in India: Down but not yet Dead. *J Mycobac Dis* 4:148
- Das S, Das D, Bhuyan UT, Saikia N. Head and neck tuberculosis: scenario in a tertiary care hospital of North Eastern India. *J Clin Diagn Res* 2016;10(01):MC04–MC07
- Akkara SA, Singhanian A, Akkara AG, Shah A, Adalja M, Chauhan N. A study of manifestations of extrapulmonary tuberculosis in the ENT region. *Indian J Otolaryngol Head Neck Surg* 2014;66(01):46–50
- Bailey CM, Windle-Taylor PC. Tuberculous laryngitis: a series of 37 patients. *Laryngoscope* 1981;91(01):93–100
- Soda A, Rubio H, Salazar M, Ganem J, Berlanga D, Sanchez A. Tuberculosis of the larynx: clinical aspects in 19 patients. *Laryngoscope* 1989;99(11):1147–1150
- Soni NK, Chatterjee P. Laryngeal tuberculosis. *Indian J Otolaryngol* 1978;30(03):115–117
- Levenson MJ, Ingerman M, Grimes C, Robbett WF. Laryngeal tuberculosis: review of twenty cases. *Laryngoscope* 1984;94(08): 1094–1097
- Ricciardiello F, Martufi S, Cardone M, Cavaliere M, D'Errico P, Iengo M. Otorhinolaryngology-related tuberculosis. *Acta Otorhinolaryngol Ital* 2006;26(01):38–42
- Moon WK, Han MH, Chang KH, et al. CT and MR imaging of head and neck tuberculosis. *Radiographics* 1997;17(02):391–402
- Kamal MS, Hoque MH, Chowdhury FR, Farzana R. Cervical tuberculous lymphadenitis: clinico-demographic profiles of patients in a secondary level hospital of Bangladesh. *Pak J Med Sci* 2016;32 (03):608–612
- Sachdeva K, Shrivastava T. CBNAAT: a boon for early diagnosis of tuberculosis-head and neck. *Indian J Otolaryngol Head Neck Surg* 2018;70(04):572–577