



Negative Pressure Pulmonary Edema after Bilateral Nasal Packing following Transsphenoidal Pituitary Surgery for Nonfunctioning Pituitary Tumor

Apoorva Singh¹ Shalvi Mahajan² Shweta Aghi² Sanjay Kumar²

¹Department of Neuroanesthesia, Postgraduate Institute of Medical Education and Research, Chandigarh, India

²Department of Anaesthesia and Intensive Care, Postgraduate Institute of Medical Education and Research, Chandigarh, India

Address for correspondence Shalvi Mahajan, MD, DM, Department of Anaesthesia and Intensive Care, Postgraduate Institute of Medical Education and Research, Chandigarh 160012, India (e-mail: drshalvimahajan@gmail.com).

J Neuroanaesthesiol Crit Care 2023;10:112–114.

Abstract

Keywords

- transnasal transsphenoidal pituitary surgery
- negative pressure pulmonary edema
- nasal packing

Negative pressure pulmonary edema (NPPE) is a well-known, albeit infrequent complication caused by upper airway obstruction. It may be seen after extubation following general anesthesia due to excessive negative intrathoracic pressure exerted against an obstructed upper airway. This leads to fluid extravasation from the pulmonary capillaries into the alveolar spaces and lung parenchyma. We report a case of NPPE after endoscopic transsphenoidal resection of the nonfunctional pituitary tumor, which occurred secondary to bilateral nasal packing. Reintubation and positive pressure ventilation were used to manage the patient, who was later extubated after the resolution of features of NPPE.

Introduction

Negative pressure pulmonary edema (NPPE) is a bilateral, noncardiogenic flash pulmonary edema manifesting as hyperacute respiratory failure. It occurs when a patient spontaneously generates strong negative intrathoracic force against an obstructed airway. The stated incidence is 0.1 to 11%, although the actual occurrence is presumed much higher.^{1,2} Underreporting is attributed to a lack of clinical awareness, delayed recognition, and masking of manifestations. However, NPPE must be addressed as a life-threatening emergency and managed expeditiously to prevent avoidable consequences. We report successful management of NPPE following endoscopic transnasal-transsphenoidal (TNTS) pituitary surgery for nonfunctional pituitary tumor (NFPT). Patient provided written consent and CARE (Case REport) guidelines were referenced in writing this case report.

Case Report

A 43-year-old, 150 cm tall, 50 kg woman with body mass index of 22.22 kg/m², without any comorbidities presented with headache and gradual visual loss. Magnetic resonance imaging of brain revealed a mass measuring 22 × 17 × 21 mm along planum sphenoidale, extending into suprasellar region. Preoperative hormonal workup and blood tests were unremarkable. The patient was scheduled for endoscopic resection of NFPT through TNTS approach.

Preoperatively, the patient was positioned supine, and standard monitors were applied. Following propofol, fentanyl, and vecuronium induced anesthesia, the patient was intubated. Intraoperatively, propofol and dexmedetomidine infusions were used to achieve target entropy values between 40 and 60. Vitals remained stable and arterial blood gas (ABG) levels were normal. Surgery lasted 2 hours. In total, 1,000 mL intravenous fluid were used,

article published online
April 24, 2023

DOI <https://doi.org/10.1055/s-0043-1763265>.
ISSN 2348-0548.

© 2023. The Author(s).

This is an open access article published by Thieme under the terms of the Creative Commons Attribution License, permitting unrestricted use, distribution, and reproduction so long as the original work is properly cited. (<https://creativecommons.org/licenses/by/4.0/>)
Thieme Medical and Scientific Publishers Pvt. Ltd., A-12, 2nd Floor, Sector 2, Noida-201301 UP, India

150 mL blood loss, and 300 mL urine output was noted. After completion, surgeon performed bilateral nasal packing using absorptive nasal packs. Propofol and dexmedetomidine infusions were stopped. Analgesics and antiemetic drugs were administered. Intravenous neostigmine 2.5 mg and glycopyrrolate 0.5 mg were given to reverse neuromuscular blockade (NMB) when train-of-four ratio (TOFR) was 0.7. A smooth extubation was performed after awakening the patient, once entropy values were >80 and TOFR was 0.9.

After extubation, the patient appeared stable and could obey commands. There were no episodes of coughing or laryngospasm or kinking of endotracheal tube. Oxygen supplementation was continued. The patient gradually exhibited labored breathing and became agitated. She was propped up and jaw-thrust was given to assist breathing. Oxygen saturation began to drop and fell to a minimum of 90%. Blood pressure and heart rate increased dramatically. On auscultation, crackles were heard in basal lung fields bilaterally. ABG revealed hypercarbia and mild hypoxemia. Due to deteriorating clinical condition, patient's trachea was reintubated. On reintubation, pinkish frothy secretions appeared in the endotracheal tube. Diagnosis of pulmonary edema was considered, and 20 mg furosemide was administered. Subsequently, patient was sedated, paralyzed, and shifted to intensive care unit. Positive pressure ventilation (PPV) with positive end-expiratory pressure of 8 cm H₂O was continued. X-ray chest revealed bilateral homogenous diffuse opacities (\rightarrow Fig. 1A). Echocardiography showed an ejection fraction of 55% with normal valvular morphology. Vital signs and ABG were normal. Diagnosis of NPPE was made considering clinical presentation, ABG analysis, chest imaging, and exclusion of other causes of pulmonary edema. PPV was continued for the next 24 hours.

Subsequent X-ray chest demonstrated reduced haziness (\rightarrow Fig. 1B). Oxygen saturation of 100% was maintained on 30% fraction of inspired oxygen. Both nasal packs were removed. Patient was gradually weaned off and extubated.

On the second postoperative day, the chest radiograph was normal; the patient was mobilized to the ward.

Discussion

NPPE is a dilemmatic diagnosis, usually by exclusion, because of its indeterminate myriad of etiologies, masked manifestations, overlapping symptoms, and lack or delay in clinical suspicion. It is more prevalent in men and healthier patients, presumably due to greater propensity to generate more negative intrathoracic pressure against a closed upper airway.^{1,2}

Pathogenically, NPPE is transudative edema caused by high negative intrathoracic pressure that translates into augmented pulmonary venous hydrostatic pressure and increased pulmonary capillary permeability leading to flooding of alveoli. Hypoxemia and respiratory acidosis further increase pulmonary vascular resistance and contribute to pulmonary capillary membrane injury, setting up a vicious cycle.

Many cases of NPPE following compact nasal packing after rhinoplasty have been reported in the literature, but its occurrence after TNTS surgery for NFPT has not been reported.^{3,4} Nishino and Kochi demonstrated that adults under the effect of sedation lose ability to shift from nasal to oral breathing due to a lack of conscious control of palatal muscles.⁵ This finding can be extrapolated to patients emerging from general anesthesia, as in our case. We believe that bilaterally packed nares acted as obstruction in indexed case. Instead of breathing through the oral cavity, the patient attempted to breathe through the nose, exerting excessive negative intrathoracic pressure, which led to the development of type-I NPPE. Type-I NPPE is caused by acute obstruction of upper airway, whereas type-II is observed following resolution of chronically obstructed upper airway.

Nasal packing helps in hemostasis, supports the reconstruction site, prevents synechiae formation, and temporarily seals off the intracranial cavity. It is also linked with

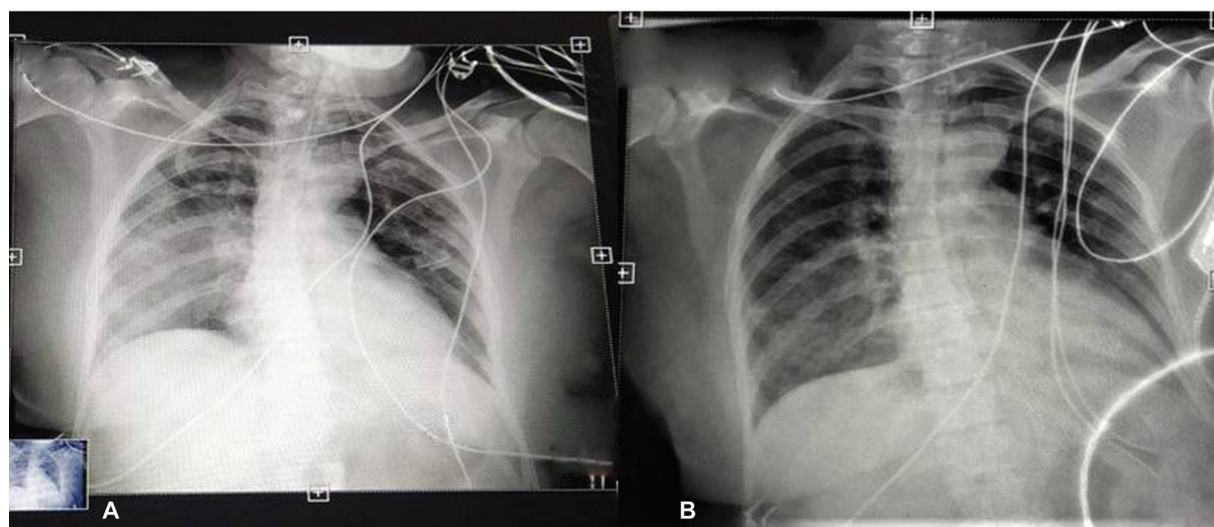


Fig. 1 (A) Chest X-ray depicts features of pulmonary edema following intubation. (B) Chest X-ray depicts resolution of pulmonary edema.

patient discomfort and theoretical risk for infection (i.e., toxic shock syndrome). Hence, foregoing nasal packing or partially packed sphenoid cavity, without packing the nasal cavity is significantly more comfortable and does not alter recovery.^{6,7}

Few reports mentioned NPPE occurrence after TNS for functional pituitary tumors.⁸ The functional tumor produces structural changes in the airway and hormonal imbalance which further causes increased pulmonary capillary permeability and aberrant fluid distribution, hence increases the likelihood of developing NPPE. Even though no hormonal abnormalities were found in our case, there might have been some underlying subclinical imbalances owing to the pituitary gland dysfunction, which was the primary site of pathology.

Other differentials for acute NPPE include aspiration pneumonia, fluid overload, sepsis, and anesthetic and non-anesthetic drugs. Neostigmine, a drug used to reverse the NMB, is occasionally implicated with NPPE by its ability to impair upper airway dilator muscle activity.⁹

NPPE responds expeditiously with appropriate therapy, such as lung protective PPV and supportive care. Diuretics are administered to reverse hydrostatic gradient across pulmonary capillary membranes and hasten recovery, although their role is debatable.¹⁰ Refractory respiratory failure is managed by paralyzing and ventilating, and prone positioning.

To conclude, a high index of suspicion of NPPE may be warranted following TNS surgery for NFPT secondary to bilateral nasal packing. Whenever possible, avoid nasal packing unless there is structural impairment or an active nasal bleed is present.

Conflict of Interest

None declared.

References

- 1 Bhattacharya M, Kallet RH, Ware LB, Matthay MA. Negative-pressure pulmonary edema. *Chest* 2016;150(04):927–933
- 2 Silva LAR, Guedes AA, Salgado Filho MF, Chaves LFM, Araújo FP. Negative pressure pulmonary edema: report of case series and review of the literature [in Portuguese]. *Braz J Anesthesiol* 2019; 69(02):222–226
- 3 Park H, Nam S, Jang YJ, Ku S, Choi SS. Negative pressure pulmonary edema in a patient undergoing open rhinoplasty: a case report. *Medicine (Baltimore)* 2021;100(01):e24240
- 4 Din-Lovinescu C, Trivedi U, Zhang K, et al. Systematic review of negative pressure pulmonary edema in otolaryngology procedures. *Ann Otol Rhinol Laryngol* 2021;130(03):245–253
- 5 Nishino T, Kochi T. Effects of sedation produced by thiopentone on responses to nasal occlusion in female adults. *Br J Anaesth* 1993; 71(03):388–392
- 6 Pan X, Ma Y, Fang M, Jiang J, Shen J, Zhan R. Improvement in the quality of early postoperative course after endoscopic transsphenoidal pituitary surgery: description of surgical technique and outcome. *Front Neurol* 2020;11:527323
- 7 Cai X, Yang J, Zhu J, et al. Reconstruction strategies for intra-operative CSF leak in endoscopic endonasal skull base surgery systematic review and meta-analysis. *Br J Neurosurg* 2022;36 (04):436–446
- 8 Xiong J, Sun Y. Negative pressure pulmonary edema: a case report. *BMC Anesthesiol* 2019;19(01):63
- 9 Nagella AB, Bijapur MB, Shreyavathi S, Rao RR. Neostigmine and pulmonary oedema. *BMJ Case Rep* 2014;8:bcr2014204992
- 10 Krodel DJ, Bittner EA, Abdunour R, Brown R, Eikermann M. Case scenario: acute postoperative negative pressure pulmonary edema. *Anesthesiology* 2010;113(01):200–207