Article published online: 2023-03-27

Morphological Factors affecting Coil-Only Embolization of Small Unruptured Aneurysms

Hiroshi Tenjin[1] Osamu Saito[2] Kuniaki Matsumoto[3] Akio Asai[1]

[1] Department of Neurosurgery, Kansai Medical University, Hirakata, Osaka, Japan
[2] Department of Neurosurgery, Shizuoka Red Cross Hospital, Japan
[3] Department of Neurosurgery, Sano Memorial Hospital, Japan

Address for correspondence Hiroshi Tenjin, MD, PhD, Department of Neurosurgery, Kansai Medical University, 2-5-1 Shinmachi, Hirakata, Osaka 573-1010, Japan (e-mail: htenjin@nn.iij4u.or.jp).

AJNS 2023;18:125–131.

Abstract

Objective When small unruptured aneurysms (SUA) are embolized by coils, manipulation of the microcatheter and coil is limited because of their small size. Previous studies suggested that the morphology of the artery and aneurysm is important. In the present study, we clarified the morphological factors affecting coil-only embolization of SUA.

Patients and Methods We retrospectively identified 17 patients who underwent embolization for unruptured aneurysm with a maximum diameter less than 5 mm. We investigated the following: (1) the relationships among dome/neck ratio (D/N), height/neck ratio (H/N), height/dome ratio (H/D), projection of aneurysm-parent artery, and adverse events, (2) immediate and late occlusion, and (3) number of coils.

Results (1) Adverse events developed in three cases in which the H/D was smaller than 1 ($p < 0.02$). There was a significant difference in the rate of adverse events by projection of the aneurysm-parent artery ($p < 0.03$), (2) Occlusion rate: Immediately after coil embolization, 71% (12/17) were neck remnant; however, 88% (15/17) of SUA became complete occlusion in the follow-up term, and (3) 1.5 ± 0.6 coils were used.

Conclusion To achieve successful coil-only embolization in SUAs, it is important to select aneurysms for which the projection of the parent artery is suitable for embolizing and the H/D ratio is larger than 1. In SUAs, occlusion develops naturally after coil embolization.

Keywords
- coil embolization
- height dome ratio
- morphology
- parent artery-aneurysm projection
- small aneurysm

Introduction

Cerebral unruptured aneurysms (UA) smaller than 5 to 7 mm are not usually indicated for surgical treatment according to the present Japanese guidelines.[1] The growth and rupture rates of small UA (SUA) are generally low.[2–6] However, knowledge of the presence of UA may lead to substantial stress and anxiety for the patient and affect their perspective regarding treatment.[7] Technical difficulties in embolization of SUA include obtaining a stable microcatheter position and selecting coils for packing.[8–10] If SUA are treated, the risk of treatment must be weighed against their benign natural course. In contrast, if coils are placed in SUA, late occlusion often develops.[11–13] Besides, after coil-only embolization for SUA, continuous antiplatelet agents are seldom required. If

article published online
March 27, 2023

DOI https://doi.org/10.1055/s-0043-1763528.
ISSN 2248-9614.

© 2023. Asian Congress of Neurological Surgeons. All rights reserved.
This is an open access article published by Thieme under the terms of the Creative Commons Attribution-NonDerivative-NonCommercial-License, permitting copying and reproduction so long as the original work is given appropriate credit. Contents may not be used for commercial purposes, or adapted, remixed, transformed or built upon. (https://creativecommons.org/licenses/by-nc-nd/4.0/)
Thieme Medical and Scientific Publishers Pvt. Ltd., A-12, 2nd Floor, Sector 2, Noida-201301 UP, India

only coil embolization can be safely performed for SUAs, it can be good therapy.

When SUA are embolized by coils, manipulation of the microcatheter and coil is limited because of their small size. Therefore, the morphology of the artery and aneurysm is important; however, a few studies have been published.[8,9,14] In the present study, we clarified the morphological factors affecting coil embolization of SUA and treatment result.

Materials and Methods

We retrospectively identified all patients who underwent embolization for UA with a maximum diameter less than 5 mm measured by digital angiography between March 2019 and November 2021. Fusiform aneurysms and pseudoaneurysms were excluded. Seventeen SUAs for which coil embolization were performed were included in this study. Indications for treatment were dome/neck ratio (D/N) and/or height/neck ratio (H/N) were more than 1, and the aneurysm was enlarged, the bleb was deformed, and the patient strongly desired treatment. Patient ages were 60.6 ± 10.8 years, the average size was 3.5 ± 0.7 mm, H/N was 1.5 ± 0.3, D/N was 1.3 ± 0.3, and height/dome ratio (H/D) was 1.2 ± 0.4. SUAs were in the posterior circulation ($n = 7$), the internal carotid artery ($n = 5$), the anterior communicating artery ($n = 3$), and the middle cerebral artery ($n = 2$). To assess the effects of aneurysm and parent artery projection, we classified SUA into three categories: type 1—same projection: aneurysm axis and parent artery axis were on the same arc both anteroposterior and lateral projections, type 2—not same projection: aneurysm axis and parent artery axis were not on the same arc either the anteroposterior or lateral projection, and type 3—not same projection in short segment: aneurysm axis and parent artery axis were not on the same arc either or both the anteroposterior or/and lateral projection in the short segment (►**Fig. 1**). These aneurysms required complex microcatheter shaping at a short distance. Type 3 projection aneurysm is difficult to insert a microcatheter into the aneurysm and decide the position to secure the microcatheter. SUA with type 3 is usually not indicated for coil embolization, except in patients that strongly request treatment. Aneurysms were type 1 ($n = 10$), type 2 ($n = 4$), and type 3 ($n = 3$) (►**Table 1**).

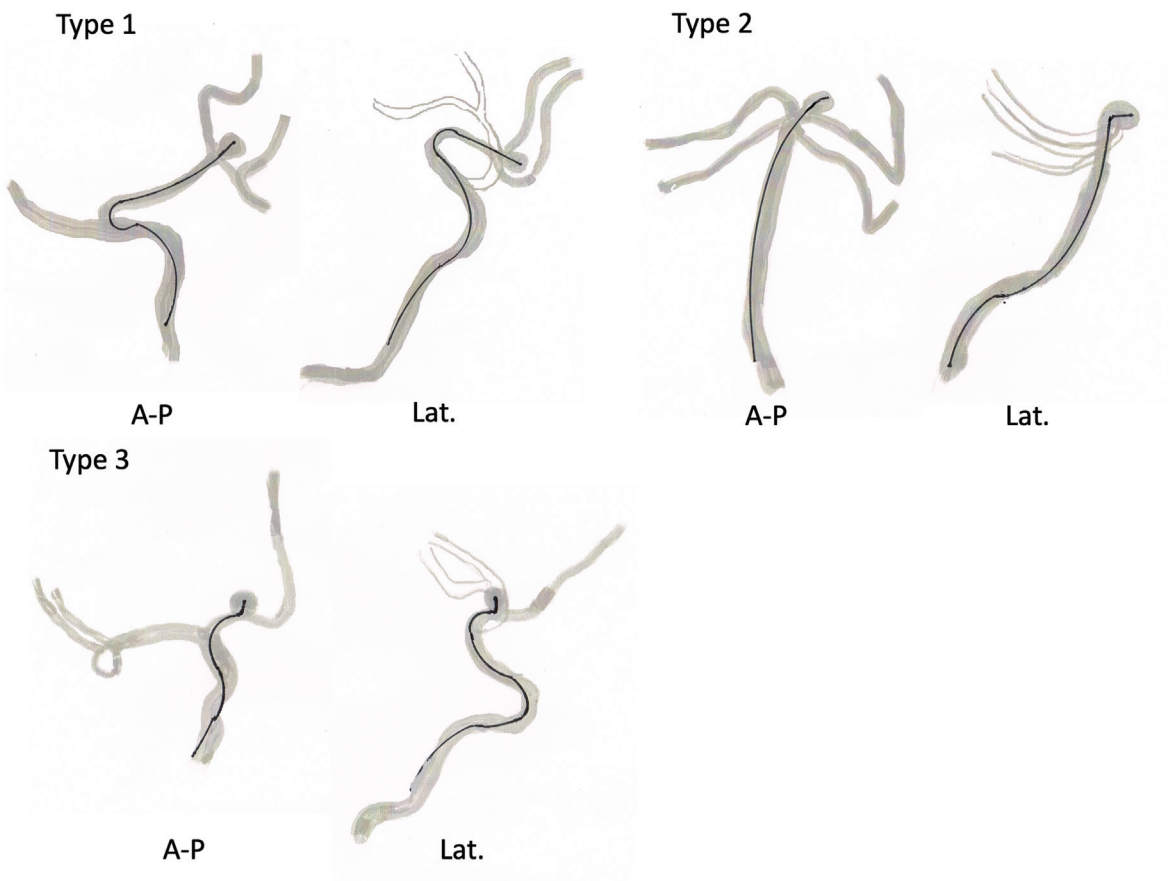

Fig. 1 Schema of aneurysm and parent artery projection type 1: same projection: aneurysm axis and parent artery axis were on the same arc both anteroposterior and lateral projections, type 2: not same projection: aneurysm axis and parent artery axis were not on the same arc either the anteroposterior or lateral projection, and type 3: not same projection in short segment: aneurysm axis and parent artery axis were not on the same arc either or both the anteroposterior or/and lateral projection in the short segment. These aneurysms required complex microcatheter shaping at a short distance. Type 3 projection aneurysm is difficult to insert a microcatheter into the aneurysm and decide position to secure the microcatheter.

 © 2023. Asian Congress of Neurological Surgeons. All rights reserved.

Table 1 Patients' characteristics

Case	Age	Sex	Location	Size	H/N	D/N	H/D	Projection	Procedure	Coils	Adverse events	Immediate MR angiography	Neurological Deficit	Short-term result		Long-term result	
														Duration (months)	MR angiography	Duration (months)	MR angiography
1	68	F	Batop	3.4	1.7	1.2	1.4	2	Simple	Target US 3 × 4, Target nano 2 × 3	n	C	None	2	C	9	C
2	46	F	L.ICPC	3.8	2.2	1.8	1.2	1	Simple	Target 360 3 × 6, Target helical 2 × 3	n	NR	None	1	NR	34	NR
3	46	F	R.ICprcl	4.9	1.6	0.9	1.8	3	Balloon	Target 360 5 × 15	n	NR	None	2		32	C
4	71	F	R.MC	3.5	1.6	1.1	1.5	1	Double	Target 360 2.5 × 4, Barricade 1 × 2	n	C	None	8	C	31	C
5	62	F	R.ICPC	3.7	1.4	1.2	1.2	1	Balloon	Target 360 3 × 6	n	NR	None	2	C	29	C
6	68	F	L.BASCA	4.5	1.7	2	0.9	2	Simple	Target 360 3.5 × 10	n	NR	None	1	C	31	C
7	62	F	R.BASCA	3.2	1.5	1	1.5	1	Simple	Target US 2.5 × 4, Target nano 1 × 2	n	C	None	1	C	31	C
8	78	M	Acom	2.6	1	1.3	0.8	1	Simple	Target nano 2 × 3	n	NR	None	1	C	2	C
9	70	M	Acom	3.4	1.4	1.4	1	2	Simple	Target 360 3 × 6, Target nano 1 × 2	n	NR	None	1	C	27	C
10	46	M	L.Icophth	3.2	0.7	1.4	0.5	3	Balloon	Target 360 3 × 6, Target nano 1.5 × 3	y	C	Quadrantanopsia	1	C	19	C
11	49	M	L.BASCA	2.7	1.6	1.8	0.9	2	Simple	Target 360 2.5 × 4, Target nano 1 × 2	y	NR	None	1	NR	25	NR
12	62	F	R.ICprcl	3.9	1.4	1.5	0.9	3	Balloon	Target 360 2 × 8	y	NR	None	1	C	15	C
13	60	M	L.MC	2.8	1.2	1.2	1	1	Simple	Target nano 1.5 × 3	n	NR	None	1	C	3	C
14	55	F	L.ICantchor	4.9	1.8	1.2	1.5	1	Simple	Target 360 2.5 × 4, Target nano 1 × 2	n	NR	None	4	C	14	C
15	66	M	Acom	4.9	1.8	1.2	1.5	1	Simple	Target US 3 × 6	n	NR	None	1	C	2	C
16	62	M	Basilar	3	2	1.2	1.7	1	Simple	Target US 2 × 3	n	C	None	1	C	5	C
17	47	F	R.BASCA	3	1.5	1.2	1.3	1	Balloon	Target US 3 × 6	n	NR	None	1	C	1	C
Average	60			3.6	1.5	1.3	1.2			Coil number 1.5				1.8		18	
Standard deviation	± 10.1			± 0.8	± 0.4	± 0.3	± 0.4			± 0.6				± 2.0		± 12	

Abbreviations: Acom, anterior communicating artery aneurysm; balloon, balloon-assisted technique; Batop, basilar apex aneurysm; BASCA, basilar artery–superior cerebellar artery aneurysm; C, complete occlusion; D/N, dome/neck ratio; H/D, height/dome ratio; H/N, height/neck ratio; ICantchor, internal carotid–anterior choroidal artery aneurysm; ICopht, internal carotid–ophthalmic artery aneurysm; ICPC, internal carotid–posterior communicating artery aneurysm; ICprcl, internal carotid artery paraclinoid portion aneurysm; L, left; R, right; MC, middle cerebral artery aneurysm; n, no adverse events; NR, neck remnant; simple, simple technique; y, adverse events.

 © 2023. Asian Congress of Neurological Surgeons. All rights reserved.

All patients were pretreated with dual antiplatelet therapy (clopidogrel and aspirin) at daily doses (clopidogrel 75 mg PO and aspirin 100 mg PO) for 1 week. All patients received general anesthesia and systemic heparin therapy with an intravenous bolus dose of 3,000 U, followed by an infusion of 1,000 U/hour and activated clotting time maintained over 250 seconds. Via transfemoral access, a guide catheter was positioned into the vessel of interest, and working views were obtained in both the anteroposterior and lateral projections. Through the guide catheter, microcatheters were navigated into the aneurysm. In three patients, a balloon was placed in front on the neck. When necessary, balloon inflation was used to stabilize the microcatheter to avoid coil protrusion and achieve hemostasis when the SUA ruptured. The size of the first coil was chosen based on the average value of the aneurysmal sac. All coils were bare coils. After coil placement, when intraaneurysmal flow clearly decreased, the procedure was finished. Antiplatelet agents were stopped after coil embolization except in one patient with moyamoya disease.

Follow-up was performed by MRI including time-of-flight,[15–17] two-way plain X-ray, and neurological examination on the next day and after 1 week, 3 months, 6 months, and every year. Aneurysm occlusion was evaluated using Raymond's 3-grade scale: complete occlusion (CO), neck remnant (NR), and dome filling (D). Statistical analysis was performed using chi-squared test. Significance was *p*-value less than 0.05. We investigated the following: (1) Relationships among D/N, H/N, H/D, projection of aneurysm-parent artery (types 1, 2, and 3), and adverse events. Adverse events include intraoperative rupture, intraoperative vascular occlusion even if these could be controlled, and temporary or permanent neurological deficit. (2) Immediate and late occlusion. (3) Mean number of coils for embolization.

The research within our submission has been approved by ethics institutional review board of Shizuoka Red Cross Hospital (authorization number 2019-36).

Results

Results are shown in ►**Tables 1–3**.

1: Adverse events developed in three cases in which the H/D was smaller than 1, which was statistically significant ($p < 0.02$). There was a significant difference in the rate of adverse events among type 1, type 2, and type 3 SUAs ($p < 0.03$). As adverse events, there were two cases of aneurysm rupture during the procedure (one [case 12] was internal carotid artery—paraclinoid aneurysm and one [case 11] was basilar artery—superior cerebellar artery aneurysm [the neck was on the superior cerebellar artery]), even though these adverse events could be controlled. One One patient [case 10] of internal carotid artery—ophthalmic artery aneurysm (the neck was on the ophthalmic artery) developed permanent quadrantanopsia (mRS1). No other patients showed permanent neurological deficits. All patients returned to their original occupations (mRS $\leq$ 1) (►**Table 3**).

Table 2 Relationship among height-dome ratio, aneurysm projection, and adverse events

	Adverse events +	Adverse events -
Height/dome < 1	3	2
Height/dome ≥ 1	0	12

$p < 0.02$ (chi-squared test).

	Adverse events +	Adverse events -
Type 1	0	10
Type 2	1	3
Type 3	2	1

$p < 0.03$ (chi-squared test).

2: Occlusion rate: Immediately after coil embolization, 71% (12/17) were NR, but 88% (15/17) of SUA became CO within 2 ± 2 months and CO continued until 18 ± 12 months. In NR cases, NR was less than 1 mm and did not recanalize. No SUA were retreated.

3: Number of coils: 1.5 ± 0.6 coils were used for embolization.

Representative Cases

Case 16: A 62-year-old male patient complained of dizziness. MRA showed basilar artery aneurysm of 3.0 mm diameter, H/N 1.5, D/N 1.2, H/D 1.3, and type 1 (aneurysm axis and parent artery axis were on the same arc). Aneurysm was embolized safely by only one coil and no neurological deficit remained. After coil embolization, aneurysm was not seen by MR angiography (►**Fig. 2**).

Case 12: A 62-year-old female patient complained of dizziness. MRA showed right internal carotid artery paraclinoid aneurysm of 3.9 mm diameter, H/N 1.4, D/N 1.5, H/D 0.9, and type 3 (aneurysm axis and parent artery axis were not on the same arc in the short segment). Aneurysm rupture was developed during the procedure although hemorrhage was stopped by placement of one coil and no permanent neurological deficit remained. After coil embolization, MR angiography revealed that the aneurysm was not seen (►**Fig. 3**).

Discussion

Cerebral UAs smaller than 5 to 7 mm are generally not indicated for surgical treatment according to the present Japanese guidelines.[1] Backes et al reported that the rate of UA growth is 12% and the rupture rate is 1%.[2] Guresir et al[3] reported an annual incidence of subarachnoid hemorrhage of 0.2% in UA smaller than 7 mm. The UCAS Japan investigators reported an annual rupture rate of 0.34% of 3 to 4 mm aneurysms.[5] Murayama et al reported that the annual rupture rate of SUA is 0.33%.[4] Thus, if SUA are treated, the risks of treatment must be weighed against the benign natural course.

 © 2023. Asian Congress of Neurological Surgeons. All rights reserved.

Table 3 Details of cases with adverse events

Case 10: 46-year-old male patient, left internal carotid artery–ophthalmic artery bifurcation aneurysm, 3.2 mm. Aneurysm was detected at brain screening. H/N: 0.7, D/N: 1.4, H/D: 0.5, type 3 parent artery, neck was on ophthalmic artery Guiding catheter: 7F Optimo, left internal carotid artery Microcatheter: Headway duo, Microguide wire: Chikai Balloon protection by Syouryu 7 × 7 mm Embolization: Target 360 3 × 6 Target nano 2 × 3, Ophthalmic artery was occluded. After coil embolization, quadrantanopia was developed Present: He works as usual and drives a car by himself, mRS 1
Case 11: 48-year-old male patient, basilar artery–superior cerebellar artery aneurysm, 2.7 mm, He examined an MRI due to headache. H/N: 1.6, D/N: 1.8, H/D: 0.9, type 2 parent artery, neck was on superior cerebellar artery Guiding catheter: 7F Fubuki, left vertebral artery Microcatheter: SL-10 straight, Microguide wire: Chikai Embolization: Galaxy: 2.5 × 3.5, rupture was developed Galaxy: 2.5 × 2, settled in subarachnoid space Target 360 2.5 × 4, Target nano: 1 × 2, aneurysm coil embolization After coil embolization, ventricular drainage was performed. Present: He works as a taxi driver, mRS 0
Case 12: 62-years-old female patient, right internal carotid artery paraclinoid aneurysm, 3.9 mm, Aneurysm was detected at brain screening. She was eager for treatment. H/N: 1.4, D/N: 1.5, H/D: 0.9. type 3 Guiding catheter: 8F Optimo, right internal carotid artery Microcatheter: SL10 straight, 3D form change, Microguide wire: Chikai Balloon protection by Syouryu 7 × 7 mm Embolization: Target 360 3 × 6 trial, rupture was developed Hemostasis was performed by balloon inflation Target 360 2 × 8, aneurysm embolization Present: She works as a pharmacist, mRS 0

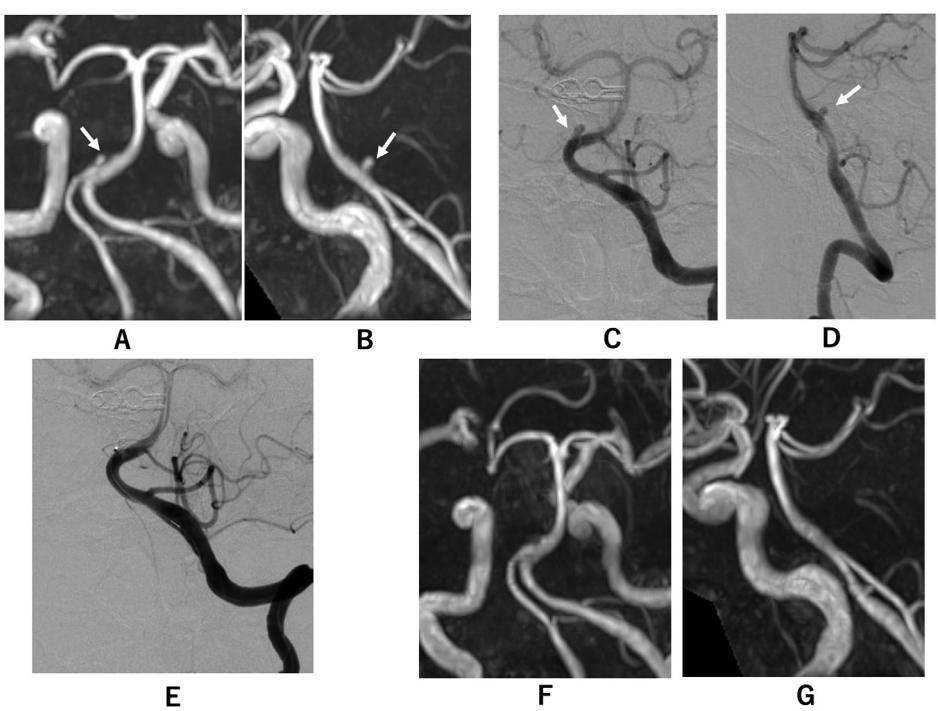

Fig. 2 Case 16, a 62-year-old male patient, 3-mm basilar aneurysm. (**A**, **B**) MR angiography, white arrow shows an aneurysm. (**C**, **D**) angiography before surgery. (**E**) angiography during surgery. (**F**, **G**) follow-up MR angiography.

 © 2023. Asian Congress of Neurological Surgeons. All rights reserved.

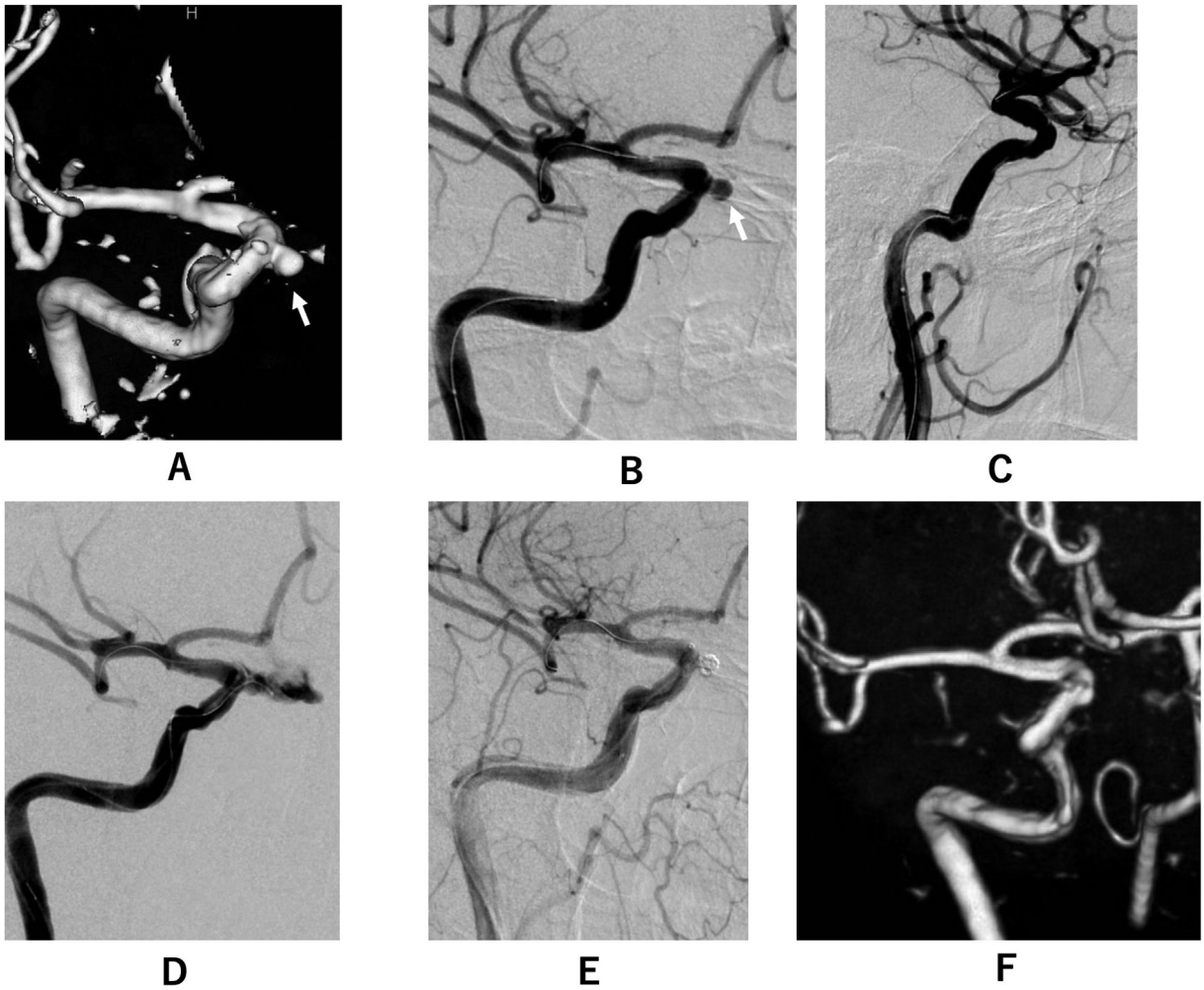

Fig. 3 Case 12, 62-year-old female patient, right internal carotid paraclinoid portion aneurysm of 3.9 mm. (**A**) MR angiography, white arrow shows an aneurysm. (**B–E**) angiography during surgery. (**F**) follow-up MR angiography.

Previous studies demonstrated that coil embolization is feasible and there are low morbidity and mortality rates for UA between 5 and 10 mm.[18] However for SUAs, small size is a factor negatively affecting coil embolization. Van Rooij et al reported that procedural rupture occurred in 15 of 196 (7.6%) ruptured or unruptured aneurysms of 3 mm or less.[19] Pop et al reported thrombotic complications were more frequent (7%) and neurological morbidity was (2.8%) after SUA treatment.[13] Kawabata et al reported that among 1,406 embolization procedures of UA, small dome size was a factor for intraoperative rupture.[10] Jindal et al reported 3% of ischemic events and 1% of hemorrhage.[20] Spinotta et al reported 8.7% of serious adverse events.[21] In this study, although all patients became under mRS 1, adverse events sometimes happened.

The projection of SUA and the parent artery are significantly associated with the embolization rate,[8,9,14,22] that means difficulty of embolization. Birkenes et al reported anterior communicating aneurysms with anterior projection, that means aneurysm axis and parent artery axis were on the same arc and had a higher embolization rate than other projections.[8] Singh et al reported that proximal vessel tortuosity was an important factor.[22] We clarified that there was a significant association among adverse events, and projection of the aneurysm and parent artery in SUAs. In type 3 SUAs, adverse events must have sometimes occurred because embolization is difficult. Another factor for adverse events of the coil embolization of SUAs is presumed to be the small H/D ratio. We had clarified that D/N and H/N ratios over 1.5 are good indicators in UA larger than 5 mm.[18] In addition, this study clarified that the H/D ratio is important for SUA. In SUA with an H/N ratio of less than 1, coils must be placed orthogonally against the axis of the parent artery. For SUAs, horizontal placement of coils is often difficult with standard three-dimensional coils.

In contrast, once coils were placed, SUA naturally occluded. Feng et al reported that among 56 SUA without complete occlusion, 43 (76.8%) had progressive occlusion.[11] Pop et al reported that only 1.5% of SUA needed retreatment.[13] In this study, long-term follow-up showed 88% complete occlusion rate. The mean number of coils was 1.5 ± 0.6. In this study, it was clarified that intra-aneurysmal thrombosis progressed spontaneously even with a small number of coils in SUAs.

 © 2023. Asian Congress of Neurological Surgeons. All rights reserved.

Because this study had a limited number of cases, we believe that it should be considered in future by increasing the number of cases.

Conclusion

To achieve successful embolization in SUAs, it is important to select aneurysms for which the projection of the parent artery and aneurysm is type 1 or type 2, and the H/D ratio is larger than 1. In SUAs, occlusion develops naturally after coil embolization.

Ethical Approval

The research within our submission has been approved by ethics institutional review board of Shizuoka Red Cross Hospital (authorization number 2019-36).

Conflict of Interest

None declared.

References

1 Committee for stroke guideline in The Japan Stroke Society Japanese guidelines for the management of stroke 2021. Kyowa Kikaku Co. Ltd. Tokyo, Japan 2021, 197–199
2 Backes D, Vergouwen MDI, Tiel Groenestege AT, et al. PHASES score for prediction of intracranial aneurysm growth. Stroke 2015;46(05):1221–1226
3 Güresir E, Vatter H, Schuss P, et al. Natural history of small unruptured anterior circulation aneurysms: a prospective cohort study. Stroke 2013;44(11):3027–3031
4 Murayama Y, Takao H, Ishibashi T, et al. Risk analysis of unruptured intracranial aneurysms: prospective 10-year cohort study. Stroke 2016;47(02):365–371
5 Morita A, Kirino T, Hashi K, et al; UCAS Japan Investigators. The natural course of unruptured cerebral aneurysms in a Japanese cohort. N Engl J Med 2012;366(26):2474–2482
6 Wiebers DO, Whisnant JP, Huston J III, et al. International study of unruptured intracranial aneurysms investigators: natural history, clinical outcome, and risks of surgical and endovascular treatment. Lancet 2003;362:103–110
7 Brown RD Jr, Broderick JP. Unruptured intracranial aneurysms: epidemiology, natural history, management options, and familial screening. Lancet Neurol 2014;13(04):393–404
8 Birknes JK, Hwang SK, Pandey AS, et al. Feasibility and limitations of endovascular coil embolization of anterior communicating artery aneurysms: morphological considerations. Neurosurgery 2006;59(01):43–52, discussion 43–52
9 Jia ZY, Song YS, Sheen JJ, Kim JG, Lee CW, Suh DC. Loop microcatheter technique for coil embolization of paraclinoid aneurysms. Acta Neurochir (Wien) 2018;160(09):1755–1760
10 Kawabata S, Imamura H, Adachi H, et al. Risk factors for and outcomes of intraprocedural rupture during endovascular treatment of unruptured intracranial aneurysms. J Neurointerv Surg 2018;10(04):362–366
11 Feng X, Wang L, Guo E, et al. Progressive occlusion and recanalization after endovascular treatment for 287 unruptured small aneurysms (<5mm): a single-center 6-year experience. World Neurosurg 2017;103:576–583
12 Goddard JK, Moran CJ, Cross DT III, Derdeyn CP. Absent relationship between the coil-embolization ratio in small aneurysms treated with a single detachable coil and outcomes. Am J Neuroradiol 2005;26(08):1916–1920
13 Pop R, Aloraini Z, Mihoc D, et al. Embolization of very small (≤3 mm) unruptured intracranial aneurysms: a large single-center experience on treatment of unruptured versus ruptured cases. World Neurosurg 2019;128:e1087–e1095
14 Kuroiwa T, Shimizu F, Yamashita T, et al. Coil embolization of cerebral tiny aneurysms. Journal of Neuroendovascular Therapy 2016;10:243–248
15 Lavoie P, Gariépy JL, Milot G, et al. Residual flow after cerebral aneurysm coil occlusion: diagnostic accuracy of MR angiography. Stroke 2012;43(03):740–746
16 Kwee TC, Kwee RM. MR angiography in the follow-up of intracranial aneurysms treated with Guglielmi detachable coils: systematic review and meta-analysis. Neuroradiology 2007;49(09):703–713
17 Pierot L, Portefaix C, Gauvrit JY, Boulin A. Follow-up of coiled intracranial aneurysms: comparison of 3D time-of-flight MR angiography at 3T and 1.5T in a large prospective series. Am J Neuroradiol 2012;33(11):2162–2166
18 Tenjin H, Yamamoto H, Goto Y, Tanigawa S, Takeuchi H, Nakahara Y. Factors for achieving safe and complete treatment for unruptured saccular aneurysm smaller than 10mm by simple clipping or simple coil embolization. World Neurosurg 2016;91:308–316
19 van Rooij WJ, Keeren GJ, Peluso JPP, Sluzewski M. Clinical and angiographic results of coiling of 196 very small (< or = 3 mm) intracranial aneurysms. Am J Neuroradiol 2009;30(04):835–839
20 Jindal G, Almardawi R, Gupta R, et al; ULTRA Study Investigators. Target ultra and nano coils in the endovascular treatment of small intracranial aneurysms (ULTRA Registry). J Neurosurg 2022;24:1–8
21 Spiotta AM, Bellon RJ, Bohnstedt BN, Park MS, Sattur MG, Woodward BK, SMART Registry Investigators. SMART registry: safety and performance of the penumbra SMART COIL system for patients with intracranial aneurysms 4mm and smaller. Neurosurgery 2022;91(04):555–561
22 Singh DK, Pathak V, Yadav K. Risk factor assessment and outcomes of intra procedural rupture of intracranial aneurysm during endovascular treatment: a race against time. Turk Neurosurg 2022;32(01):52–57

 © 2023. Asian Congress of Neurological Surgeons. All rights reserved.