Article published online: 2023-04-05

Chondromyxoid Fibroma of Clavicle Presenting as Radiological Disappearance of Bone

Sumit Arora[1] Abhishek Kashyap[1] Lalit Maini[1] Anjali Prakash[2] R. K. Saran[3]

[1] Department of Orthopaedic Surgery, Maulana Azad Medical College and Associated Lok Nayak Hospital, New Delhi, India
[2] Department of Radiodiagnosis, Maulana Azad Medical College and Associated Lok Nayak Hospital, New Delhi, India
[3] Department of Pathology, GIPMER Associated with Maulana Azad Medical College, New Delhi, India

Address for correspondence Sumit Arora, MS, DNB, MRCPS, MNAMS, C/o Mr. Raj Kumar Arora, B-253, Second Floor, Derawal Nagar, Delhi 110009, India (e-mail: mamc_309@yahoo.co.in).

Ann Natl Acad Med Sci (India) 2023;59:109–114.

Abstract

Case Presentation Chondromyxoid fibroma (CMF) is a relatively rare bone tumor of cartilaginous origin and it comprises less than 1% of all primary bony tumors. Clavicle is an unusual site of involvement for any bone tumor and may produce diagnostic dilemma. Approximately only 1% of all primary bone tumors may involve the clavicle. The literature on clinical features and outcome of CMF clavicle remains sparse.

Conclusion We present an unusual case of CMF clavicle in which the medial aspect of the clavicle gradually disappeared on radiographs. CMF should be included in the differential diagnoses of disappearing bone disease.

Keywords
- chondromyxoid fibroma
- clavicle
- disappearing bone

Introduction

Chondromyxoid fibroma (CMF) is a relatively rare bone tumor of cartilaginous origin and comprises less than 1% of all primary bony tumors.[1] Clavicle is an unusual site of involvement for any bone tumor and may produce diagnostic dilemma. Approximately 1% of all primary bone tumors may involve the clavicle.[2,3] In a review of 48 cases of clavicular tumors over a 50-year period, Smith et al did not observe even a single case of CMF in the clavicle.[3] Another review of 12 patients with primary tumor or tumorous lesions of the clavicle over 10 years did not feature CMF.[2] The present case was unusual as the lesion initially involved diaphysis of the clavicle and this part of the bone gradually disappeared on radiographs. We suggest that CMF should be included as one of the differentials of disappearing bone disease.

Written, informed consent was obtained from the parents authorizing radiological and photographic documentation and they were also informed that data concerning the case might be published in print and/or electronic form.

Case Report

A 13-year-old Indian girl presented with the complaints of pain and swelling over the left clavicle for past 8 months. Pain was insidious in onset, gradually progressive, non-radiating, and dull aching in nature. No diurnal variation was observed. It used to get relieved on rest and taking oral analgesics, and aggravated with activities of the left arm. The parents also noticed diffuse swelling/fullness in the region that was limited to middle and medial third of the clavicle. These complaints were associated with fever around 2 months before presenting to us. The episode necessitated admission in the medicine ward with the diagnosis of pneumonitis with subcutaneous emphysema. Chest radiographs at that time showed bilateral upper zone

article published online
April 5, 2023

DOI https://doi.org/10.1055/s-0043-1764435.
ISSN 0379-038X.

© 2023. National Academy of Medical Sciences (India). All rights reserved.
This is an open access article published by Thieme under the terms of the Creative Commons Attribution-NonDerivative-NonCommercial-License, permitting copying and reproduction so long as the original work is given appropriate credit. Contents may not be used for commercial purposes, or adapted, remixed, transformed or built upon. (https://creativecommons.org/licenses/by-nc-nd/4.0/)
Thieme Medical and Scientific Publishers Pvt. Ltd., A-12, 2nd Floor, Sector 2, Noida-201301 UP, India

opacities in the lungs with hilar lymphadenopathy; however, left clavicle appeared normal. High resolution computed tomography revealed bilateral multiple cavitary lesions in lungs. She was given intensive care with intravenous antibiotics through central line and was discharged after 1 month once she improved. One month later, she reported back with rapid aggravation of the pain over the left clavicular region. Fresh radiographs were obtained, but patient refused admission for further management. They came back after 3 weeks for admission. There was no history of weakness in the affected limb, discharge from the involved region, recent weight loss, anorexia, hemoptysis, pruritus, seizures, or similar swellings elsewhere in the body. It was not associated with any preceding history of trauma. Her family history was noncontributory.

On examination, the vitals were stable and there was no evidence of lymphadenopathy. Her physical status was good. Local examination revealed tenderness and diffuse swelling originating from medial two-third of left clavicle. Local temperature was normal. Overlying skin was freely mobile. There were no scars or sinuses. Bony gap with abnormal painful mobility in the middle of clavicle was also appreciable. Rest of the organ systems were normal.

Plain radiograph obtained during her stay in intensive care unit was reported as having no bony abnormality (►**Fig. 1A**). The radiograph (obtained 2 months later) revealed areas of lysis in the middle third of left clavicle (►**Fig. 1B**). The latest radiograph (obtained 2 months and 3 weeks later) revealed a pathological diaphyseal fracture with complete destruction of the middle third of clavicle with surrounding osteopenia especially in the medial aspect (►**Fig. 1C**). Though on retrospective analysis, it was noted that ill-defined lytic lesion was appreciable in the first round of radiograph, which was missed. Computed tomography revealed irregular outline of the medial two-third clavicle and lytic lesion in the mid-shaft along breach in cortical continuity (►**Fig. 2A–C**). There was no evidence of calcification. Surrounding osseous structures were unremarkable. MRI revealed markedly irregular medial two-third clavicle that displayed altered signal intensity appearing hypo- to isointense on T1-weighted imaging (T1WI) and hyperintense on T2WI and short tau inversion recovery. Postgadolinium images revealed heterogenous contrast enhancement along with ill-defined adjacent soft tissue component and surrounding edema (►**Fig. 3A, B**). There was no evidence of hemorrhage or necrosis. Laboratory examination revealed leucocyte count (13,800/cumm), polymorphs 63%, lymphocytes 33%, monocytes 2%, and eosinophils 2%. The erythrocyte sedimentation rate was 39 mm at the end of first hour and C-reactive protein level was 2.3 mg/L. Kidney and parathyroid functions were normal. Sputum examination was negative for acid fast bacilli. Enzyme-linked immunosorbent assay test for human immunodeficiency virus I and II antibody was negative. The patient's immune status was normal with no other focus of infection.

She underwent open biopsy under general anesthesia. Soft tissue component with overlying pseudocapsule was dissected and excised. It was a fibrous structure without areas of hemorrhage or necrosis. Curettage of the bone ends was performed. The entire tissue was submitted for histopathological examination and culture. The histopathological examination revealed predominantly low cellularity (►**Fig. 4A**). Bland tumor cells were observed, at the periphery occupying the intertrabecular spaces, with collagenous tissue (►**Fig. 4A, B**). The tumor was composed of areas of fibrous tissue, chondromyxoid tissue in varying proportions (►**Fig. 4C–D**). The hypocellular areas were chondromyxoid that had multiple stellate shaped cells with minimal pleomorphism (►**Fig. 4D**). However, sclerotic shell at the periphery, haemosiderin laden macrophages, hyaline cartilaginous tissue, and unlined blood filed spaces were not observed. There was no evidence of calcification, necrosis, or hemorrhage. Cultures for pyogenic organisms and microscopic examination for acid fast bacilli were negative. These findings were considered consistent with fibrous predominant CMF.

The patient underwent resection of the medial two-third of the clavicle with preservation of the lateral third clavicle along with acromioclavicular complex. No reconstruction was done. Resected specimen confirmed the biopsy diagnosis. Gradual shoulder mobilization was started at 4 weeks and she was kept under regular follow-up on outpatient basis. She was asymptomatic during latest follow-up at 22 months and had good shoulder function. The repeat radiograph did not reveal any further disappearance of bone (►**Fig. 5**). She had mild discomfort only on carrying heavy weights (like bucket full of water).

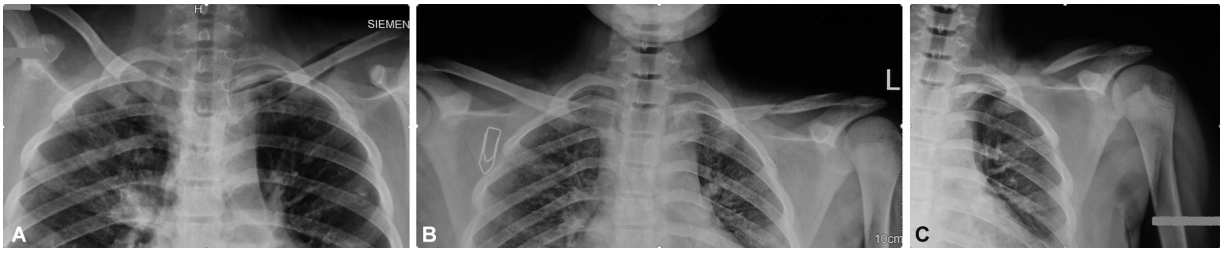

Fig. 1 (**A**) Plain radiograph taken in medical intensive care unit did not reveal obvious bony abnormality. (**B**) Plain radiograph (taken 2 months later) showing areas of lysis in the middle third of left clavicle. (**C**) The radiograph (taken 2 months and 3 weeks later) revealed a pathological diaphyseal fracture with complete destruction of the middle third of left clavicle. There was also presence of surrounding osteopenia especially in the medial third clavicle.

 © 2023. National Academy of Medical Sciences (India). All rights reserved.

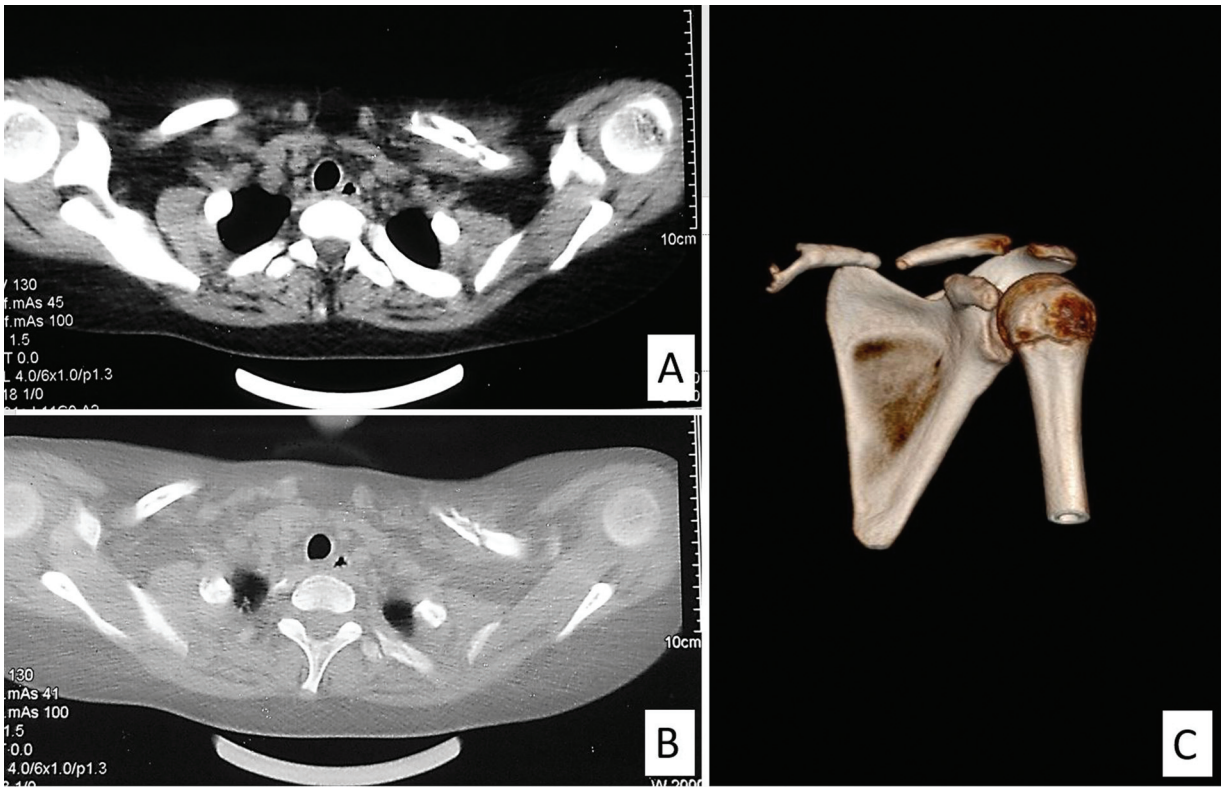

Fig. 2 Computed tomographic image: (**A**) axial section of soft tissue window; (**B**) axial section of bony window; (**C**) three-dimensional reconstruction image showing irregular outline of the clavicular diaphysis, and lytic lesion with pathological fracture and soft tissue swelling.

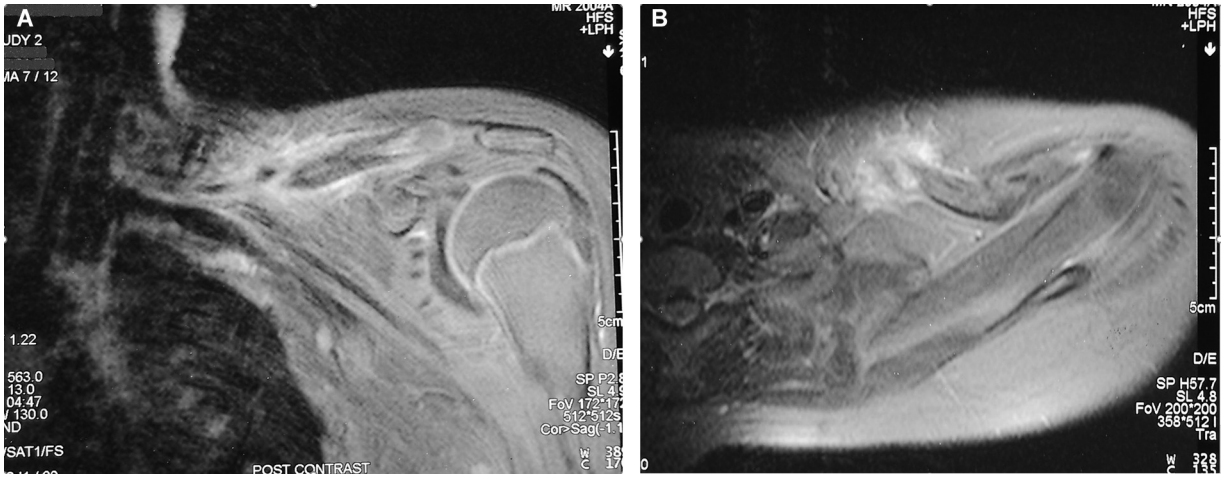

Fig. 3 (**A**) T1-weighted magnetic resonance imaging (MRI) coronal image acquired following administration of intravenous Gadolinium agent showing heterogenous contrast enhancement along with ill-defined adjacent soft tissue component; (**B**) T2-weighted MRI axial image showing hyperintense signal intensity. Soft tissue component was seen abutting the mediastinal fat in the prevascular space.

Discussion

CMF of the clavicle is exceedingly rare and only seven cases bearing this diagnosis have been reported in literature, to the best of our knowledge[4–11] (►**Table 1**). This includes a case out of total 36 cases of CMF reported by Zillmer and Dorfman over 22 years,[9] and another out of 278 cases of CMF reported by Wu et al over the period of 88 years.[8]

A careful clinical, radiological, and pathological correlation is necessary to arrive at the correct diagnosis. CMF often display local aggressiveness radiologically, such as cortical thinning, expansion, erosions, and destruction,[8–10] as was evident in our case.

The differential-diagnosis based on clinical and radiographic data included chronic osteomyelitis, tuberculous osteomyelitis, malignant neoplasm (Ewing's sarcoma), benign neoplasm (CMF/nonossifying fibroma), Synovitis, Acne, Pustulosis, Hyperostosis, Osteitis (SAPHO) syndrome, and chronic recurrent multifocal osteomyelitis. Considering the radiological disappearance of bone, we additionally considered differential diagnosis of Gorham's disease, osteolysis

 © 2023. National Academy of Medical Sciences (India). All rights reserved.

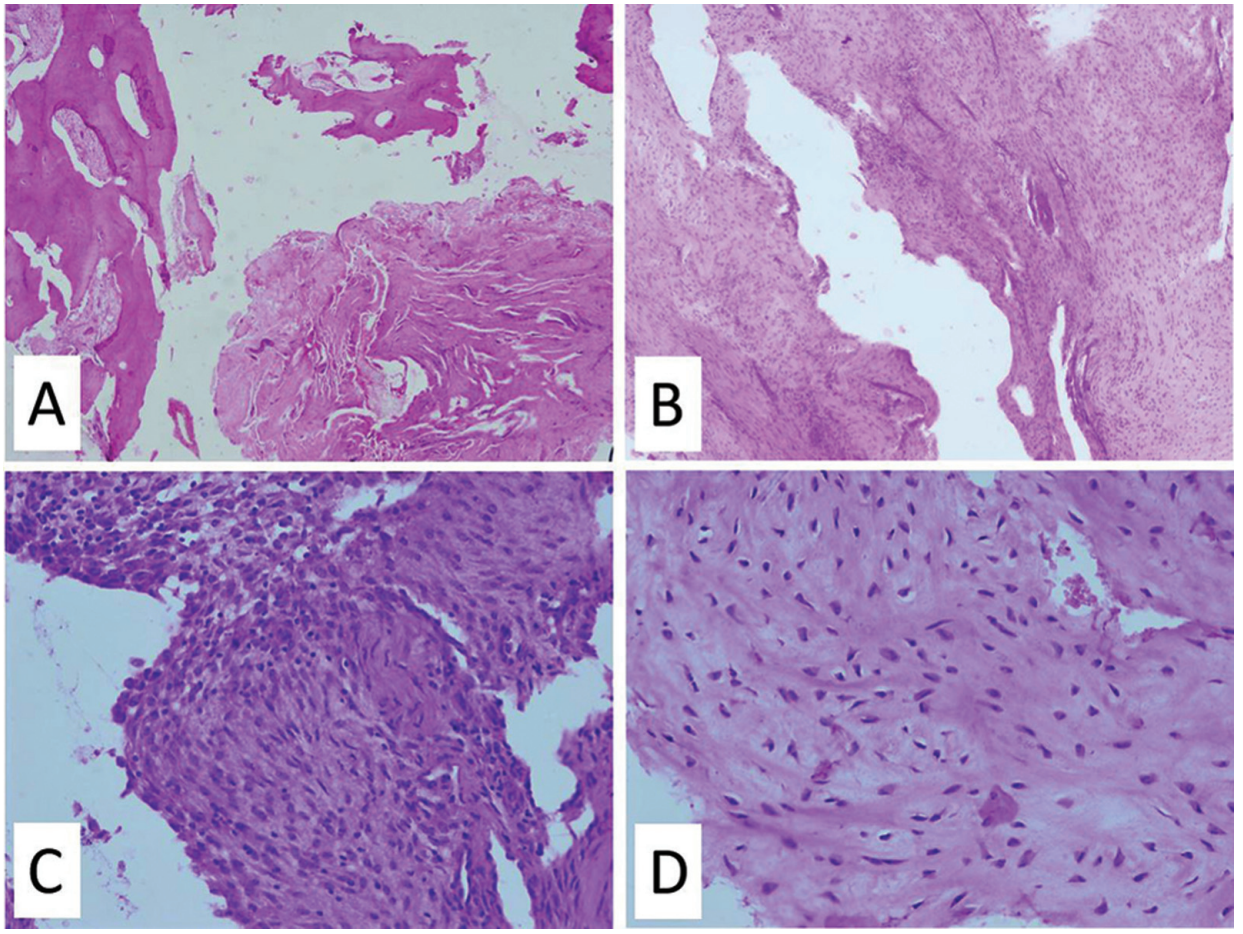

Fig. 4 (**A**) Photomicrograph (stain, hematoxylin and eosin, original magnification, ×100) showing the presence of hypocellular myxoid areas and scattered stellate cells. (**B**) Photomicrograph (stain, hematoxylin and eosin, original magnification, ×200) showing predominantly low cellularity. Bland tumor cells are seen at the periphery occupying the intertrabecular spaces, with collagenous tissue. (**C**) A high-power photomicrograph (stain, hematoxylin and eosin, original magnification, ×400) showing focal ABC like areas with increased cellularity. However, hemosiderin laden macrophages, and unlined blood-filled spaces are not present. (**D**) A high-power photomicrograph (stain, hematoxylin and eosin, original magnification, ×400) showing lobulated chondroid areas with chondroid cells displaying minimal pleomorphism.

with nephropathy, hyperparathyroidism, and eosinophilic granuloma.

Chronic infective etiology displays osteolytic lesions surrounded by sclerotic rim.[12] The absence of sequestrum, negative cultures, typical histopathological features excluded the infective etiology. Other bony neoplasms could be ruled out by the absence of typical histopathological features.[1,13] Other differentials of disappearing bone[14] could be ruled out by laboratory tests and the absence of typical histopathological features.

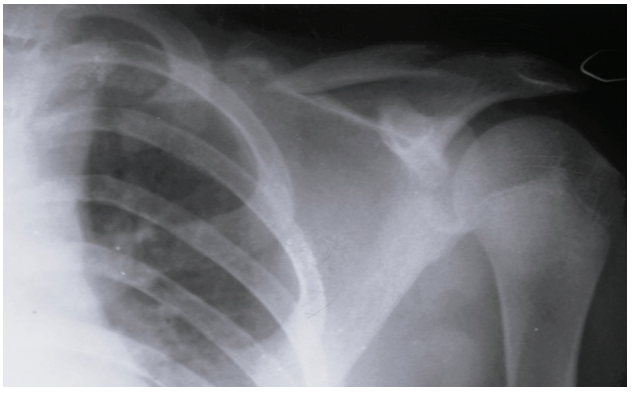

Fig. 5 Follow-up radiograph at 22 months postoperatively showing resected medial aspect of clavicle.

The prognosis of CMF of clavicle has not been established because of the paucity of literature[4–11] (►**Table 1**). It, however, appears good with early diagnosis and appropriate treatment as presented in various case reports. Conventionally, it has been treated with curettage with or without bone grafting/clavicular reconstruction. Approximately 20 to 25% cases of the CMF of the various sites may recur following curettage and the figure may be slightly higher in pediatric age-group.[1] However, such recurrences have not been observed in any of the reported cases of CMFs of clavicle that may be attributed to the facts that clavicle is a subcutaneous bone; its entire length and reconstruction may not be necessary following bone resection. Phenol has been used as an adjunct to curettage to reduce local recurrence.[7]

 © 2023. National Academy of Medical Sciences (India). All rights reserved.

Table 1 The details of reported cases of chondromyxoid fibroma of the clavicle

Authors	Age/ sex	Involved region in clavicle	Radiological features	Treatment	Follow-up
Zillmer and Dorfman[9] (1989)	One out of 36 reported cases of chondromyxoid fibroma had involvement of clavicle. However, a detailed workup of the case was not published				
Wu et al[8] (1998)	One out of 278 reported cases of chondromyxoid fibroma had involvement of clavicle. However, a detailed workup of the case was not published				
Nakazora et al[5] (2003)	34/ F	Diaphysis	Radiographs and CT: an osteolytic lesion with cortical thinning and expansion with partial destruction at the diaphysis MRI: a homogeneous iso-signal intensity mass in T1WI and a heterogeneous high-signal intensity in T2WI		
Pattamapaspong et al[6] (2006)	23/M	Distal end clavicle	Radiograph: an expanded osteolytic lesion at distal end of the clavicle with well-defined margins and internal septa NCCT: expanded osteolytic lesion at the distal end of the clavicle with endosteal scalloping, thin sclerotic rim and erosion of the inferior surface MRI: not available Tc-99m MDP bone scan: focal tracer uptake in distal end of the clavicle	Curettage with bone grafting	No recurrence at 37 months follow-up
Sakamoto et al[7] (2006)	17/M	Lateral end of clavicle	Radiograph and NCCT: osteolytic lesion with cortical thinning, expansion and destruction. High density areas of calcification were present MRI: hypointense signal intensity on T1W and hyperintense signal intensity on T2WI in intra-medullary space with soft tissue extension	Extended curettage with phenol followed by bone grafting	No recurrence at 12 months follow-up
Khan et al[4] (2008)	6/F	Medial end of clavicle	Radiograph: large osteolytic area involving whole of medial end of clavicle with resorption of superior cortical margins of medial end NCCT: extensive lytic lesion in medial end of clavicle with breach in posterior cortex and a soft tissue shadow MRI: globular soft tissue component with no involvement of the underlying neurovascular bundle	Wide excision	No recurrence at 2 years follow-up
Aggarwal et al[10] (2012)	84/M	Lateral end of clavicle	Radiograph: eccentrically placed osteolytic lesion in the lateral end of clavicle MRI: $4.3 \times 3.7 \times 3$ cm cystic solid lesion involving the lateral end of clavicle and acromion process with cortical erosions and scalloping extending to acromioclavicular joint.	En-bloc excision	No recurrence at 18 months follow-up
Hope et al[11] (2018)	7/F	Lateral end of clavicle	Radiograph: expanded, radiolucent, osteolytic lesion in the lateral end of clavicle CT: thin sclerotic rim with endosteal scalloping measuring 2.9 cm $\times$ 1.3 cm. No calcification or soft tissue mass	Curettage with phenol followed by synthetic processed bone grafting	No recurrence at 5 years follow-up
Present case	13/F	Medial two-third	Radiograph: a pathological diaphyseal fracture with complete destruction of the middle third of the clavicle CT: irregular outline of the medial two-third clavicle and lytic lesion in the mid shaft along with breach in the cortical continuity MRI: markedly irregular medial two-third clavicle which displayed altered signal intensity appearing hypo- to isointense on T1WI and hyperintense on T2WI. Heterogenous enhancement was evident on postgadolinium contrast images	Excision	No recurrence at 22 months follow-up

Abbreviations: CT, computed tomography; MDP, methylene diphosphonate; MRI, magnetic resonance imaging; NCCT, noncontrast computed tomography; T1WI, T1-weighted imaging.

 © 2023. National Academy of Medical Sciences (India). All rights reserved.

High index of suspicion may be required for early diagnosis and treatment in such patients. The diagnosis may be delayed owing to its indolent course, nonspecific symptomatology, and unfamiliarity among orthopaedic surgeons with such atypical presentation. CMF should be considered as a differential diagnosis of disappearing bone disease.

Note

Each author certifies that he has no commercial associations (e.g., consultancies, stock ownership, equity interest, patent/licensing arrangements) that might pose a conflict of interest in connection with the submitted article.

Each author certifies that his institution approved the reporting of this case report, that all investigations were conducted in conformity with ethical principles of research, and that informed consent for participation in the study was obtained.

This work was performed at The Maulana Azad Medical College, New Delhi-110002, India.

Conflict of Interest

None declared.

References

1 Unni KK. Introduction and scope of study. In: Unni KK, ed. Dahlin's Bone Tumors: General Aspects and Data on 11,087 Cases. 5th ed. Philadelphia: Lippincott Williams & Wilkins; 1996:1–9

2 Kapoor S, Tiwari A, Kapoor S. Primary tumours and tumorous lesions of clavicle. Int Orthop 2008;32(06):829–834

3 Smith J, Yuppa F, Watson RC. Primary tumors and tumor-like lesions of the clavicle. Skeletal Radiol 1988;17(04):235–246

4 Khan SA, Kumar A, Varshney MK, Rastogi S. Chondromyxoid fibroma of the clavicle in a child. Eur J Orthop Surg Traumatol 2008;18:135–137

5 Nakazora S, Kusuzaki K, Matsumine A, Seto M, Fukutome K, Uchida A. Case report: chondromyxoid fibroma arising at the clavicular diaphysis. Anticancer Res 2003;23(04):3517–3522

6 Pattamapaspong N, Peh WCG, Tan MH, Hwang JSG, Tan PH. Chondromyxoid fibroma of the distal clavicle. Pathology 2006; 38(05):464–466

7 Sakamoto A, Tanaka K, Matsuda S, et al. Chondromyxoid fibroma of the clavicle. J Orthop Sci 2006;11(05):533–536

8 Wu CT, Inwards CY, O'Laughlin S, Rock MG, Beabout JW, Unni KK. Chondromyxoid fibroma of bone: a clinicopathologic review of 278 cases. Hum Pathol 1998;29(05):438–446

9 Zillmer DA, Dorfman HD. Chondromyxoid fibroma of bone: thirty-six cases with clinicopathologic correlation. Hum Pathol 1989;20(10):952–964

10 Aggarwal A, Bachhal V, Soni A, Rangdal S. Chondromyxoid fibroma of the clavicle extending to the adjacent joint: a case report. J Orthop Surg (Hong Kong) 2012;20(03):402–405

11 Hope JMV, Sane JC, Souleymane D, et al. Chondromyxoid fibroma of the distal clavicle: report of an additional case at very unusual anatomic location. JOJ Orthoped Ortho Surg. 2018;2(02):555581

12 Aggarwal AN, Dhammi IK, Singh AP, Kumar S, Goyal MK. Tubercular osteomyelitis of the clavicle: a report of four cases. J Orthop Surg (Hong Kong) 2009;17(01):123–126

13 Rodriguez Martin J, Pretell Mazzini J, Viña Fernandez R, Marti Ciruelos R, Curto de la Mano A. Ewing sarcoma of clavicle in children: report of 5 cases. J Pediatr Hematol Oncol 2009;31(11):820–824

14 Nikolaou VS, Chytas D, Korres D, Efstathopoulos N. Vanishing bone disease (Gorham-Stout syndrome): a review of a rare entity. World J Orthop 2014;5(05):694–698

 © 2023. National Academy of Medical Sciences (India). All rights reserved.