



T-piece Traction Removal for Buried Bumper Syndrome

Vincent Zimmer^{1,2}

¹Department of Medicine, Marienhausklinik St. Josef Kohlhof, Neunkirchen, Germany

²Department of Medicine II, Saarland University Medical Center, Saarland University, Homburg, Germany

Address for correspondence Vincent Zimmer, PhD, Department of Medicine, Marienhausklinik St. Josef Kohlhof, Klinikweg 1-5, 66539 Neunkirchen, Germany (e-mail: vincent.zimmer@gmx.de).

J Digest Endosc 2023;14:106–107.

Percutaneous endoscopic gastrostomy (PEG) has become the standard nutrition access with well-established procedural and long-term safety data. Yet, buried bumper syndrome (BBS) remains a major concern and complicates up to 5% of PEGs. Albeit poorly standardized, endoscopic management is possible in most internal disc migrations with variable traction- or dissection-based techniques available. Most advanced BBS stages > *Cyrany* stage 2 call for incision of hyperplastic tissue overgrowth due to insufficient traction forces for nondissection extraction.¹

A 54-year-old institutionalized male patient suffering from cerebral palsy dependent on enteral nutrition presented with suspicion of BBS due to insufficient PEG forward mobility, with tube patency maintained. BBS was confirmed using computed tomography, in addition and compatible with laboratory signs of systemic inflammation, suggesting a small intramural abscess. After institution of broad-spectrum antibiotics, the patient underwent upper endoscopy the following day with the internal disc not visible. Instead, an elevated lesion reminiscent of a submucosal tumor with central putrid discharge emerged (► **Fig. 1A**). However, given adequate internal drainage, no specific treatment was needed beyond antibiotic treatment. After adequate washing, the abscess cavity could be entered with the scope tip with gentle pressure and the disc was visualized (► **Fig. 1B**). Next, the external tube length was reduced, and a standard biopsy forceps advanced through the tube (► **Fig. 1C**). A polypectomy snare was advanced through the endoscope, opened and grasped by the forceps (► **Fig. 1D**). An estimated 3-cm piece, the fashioned T-piece, was cut from the tube and externally grasped by the snare (compare ► **Fig. 1E**). Beforehand, a nylon thread from a commercially available PEG tube set was tied to the tube

and pulled into the stomach along with the tube system withdrawn into the stomach. Alternatively, the nylon thread might have been placed through the indwelling PEG tube beforehand. After repeat endoscopy of the intramural cavity, a new PEG was inserted in the pull technique (► **Fig. 1F**; ► **Video 1**). Concerning chances of migration of the newly placed PEG tube as it has been placed in the same area, in fact, there are no specific data available for this critical issue. However, in the author's opinion, migration and/or BBS are rather a question of proper PEG care by well-trained nurses rather than a question of endoscopy technique and/or tactics.

Video 1

Video 1 illustrates the T-piece traction removal technique for buried bumper syndrome. Online content including video sequences viewable at: <https://www.thieme-connect.com/products/ejournals/html/10.1055/s-0043-1768044>.

Endoscopy-guided traction techniques are uncommonly considered and, given typically high *Cyrany* stages, indicated. However, as an iteration of the push-pull T technique, the presented simplified technique, pioneered but, as yet, only published as abstract by the Southampton group, provides a rapid and uncomplicated procedure for borderline BBS cases. Overall, it may emerge as a welcome and valuable gap technique in BBS *Cyrany* stages 2–3, obviating the need for dissection techniques associated with much higher bleeding risks.^{2,3} Of note, the options of endoscopic PEG placement in BBS can be performed under both endoscopic and fluoroscopic control.

article published online
April 20, 2023

DOI <https://doi.org/10.1055/s-0043-1768044>.
ISSN 0976-5042.

© 2023. The Author(s).

This is an open access article published by Thieme under the terms of the Creative Commons Attribution License, permitting unrestricted use, distribution, and reproduction so long as the original work is properly cited. (<https://creativecommons.org/licenses/by/4.0/>)

Thieme Medical and Scientific Publishers Pvt. Ltd., A-12, 2nd Floor, Sector 2, Noida-201301 UP, India

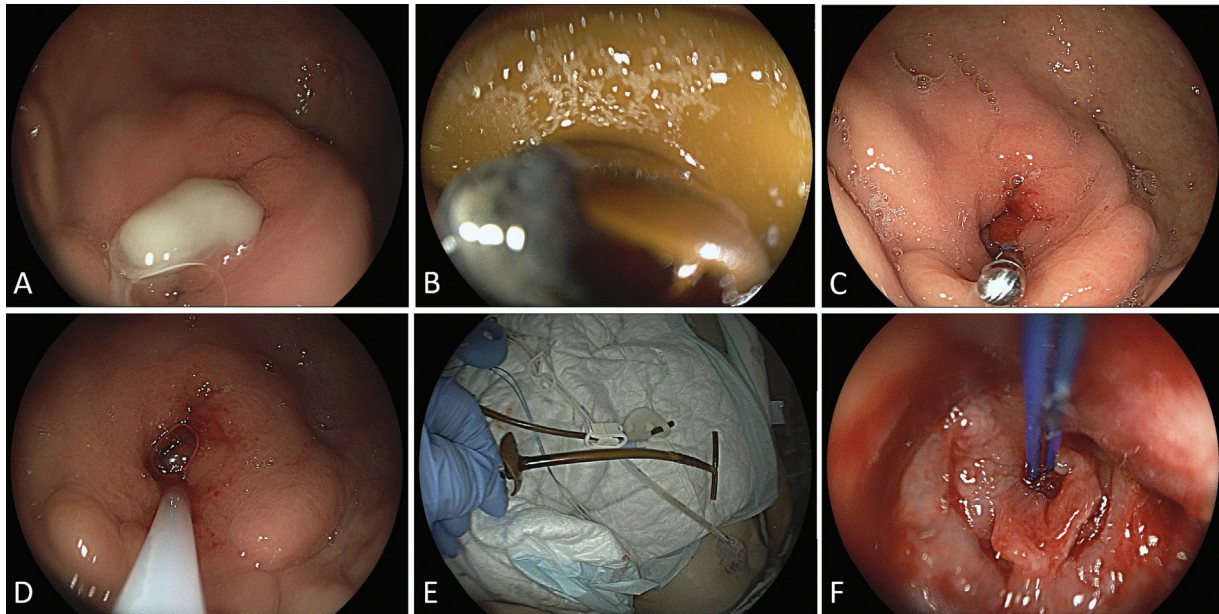


Fig. 1 (A) Putrid discharge from the central portion of the buried bumper consistent with *Cyraný* 2–3 stage. (B) After adequate washing, an intramural cavity with the migrated internal disc visible could be entered with gentle pressure. (C) Insertion of a biopsy forceps through the tube. (D) A polypectomy snare advanced through the gastroscop grasped and externalized by the forceps. (E) Ex vivo illustration of the T-piece configuration with an estimated 3-cm piece, the fashioned T-piece, cut from the tube and grasped by the snare (post hoc after extraction; please note the completeness of all parts of the disc-shaped, pull-type PEG tube). (F) Final situs with the nylon thread to insert a new PEG system visible as well as the intramural cavity. (Please compare ►**Video 1**).

Conflict of Interest

None declared.

References

- 1 Cyraný J, Rejchrt S, Kopacova M, Bures J. Buried bumper syndrome: a complication of percutaneous endoscopic gastrostomy. *World J Gastroenterol* 2016;22(02):618–627
- 2 Furlano RI, Sidler M, Haack H. The push-pull T technique: an easy and safe procedure in children with the buried bumper syndrome. *Nutr Clin Pract* 2008;23(06):655–657
- 3 Hollingwoth T, Boger P, Clarke E, et al. The T-piece pull technique removal of PEG buried bumpers - a quick novel endoscopic technique. *Gut* 2019;68(Suppl 2):A176