



Possible Triggers of Supraventricular Tachycardia in a Toddler Rescued from a Garage Fire: A Case Report

Susanna Shaw¹ Karim Rafaat¹ Brian Frugoni¹

¹Department of Anesthesiology, University of California, San Diego, California, United States

Address for correspondence Susanna Shaw, MD, Department of Anesthesiology, University of California, 200 W. Arbor Dr. San Diego, CA 92103, United States (e-mail: s1shaw@ucsd.health.edu).

J Child Sci 2023;13:e51–e53.

Abstract

We describe the case of a previously healthy toddler with the finding of supraventricular tachycardia after being rescued from a garage fire. The patient's initial presentation was concerning for inhalational injury and a 2% total body surface area burn to the forehead. Additionally, the patient was noted to be extremely agitated in the trauma bay. Given the patient's agitation and the mysterious circumstances surrounding the fire, a urine toxicology was performed shortly after admission and was positive for cocaine. Passive cocaine inhalation, possibly during the fire, is a likely explanation for the child's arrhythmia.

Keywords

- ▶ pediatric
- ▶ supraventricular tachycardia
- ▶ burns
- ▶ inhalational injury
- ▶ cocaine
- ▶ unintentional drug exposure

Introduction

Twenty to thirty percent of all severe burns suffered in a fire are associated with inhalational injury, the presence of which increases the risk of mortality threefold.^{1,2} Inhalational injury, however, is not always immediately obvious in the pediatric patient who may be awake and alert, but too young to effectively communicate. Therefore, certain criteria should increase suspicion for injury. Any patient who has been trapped in a fire in an enclosed structure is at risk. Patients may present with facial burns, singed nasal hairs, and soot on the nose and face. There may also be signs of respiratory distress such as stridor, drooling, hoarseness, or wheezing. In pediatric patients, the agitation and confusion often associated with toxic inhalation may be mistaken for expected behavior in a toddler who is afraid and/or injured.³ Perhaps the most challenging aspect is the unknown nature of what substance may have been inhaled. Any number of toxins are released in the combustion process initiated by a structure fire. This potential for an unknown toxin allows for a wide variety of neurologic and cardiovascular derangements to

potentially be part of the presentation of pediatric inhalational injury. The following case report describes a toddler whose final diagnoses included cocaine intoxication. It is possible that the cocaine was inhaled while trapped in a high heat, fast burning garage fire.

Case Report

A 3-year-old girl was brought to the trauma bay after being extracted from a home garage fire. According to the paramedic report, the patient was initially hypoxic with percent oxygen saturations in the 70s, which improved with supplemental oxygen. On arrival, the patient's oxygen saturation was greater than 92% with a simple face mask at 6L per minute. The remainder of the child's vital signs included a blood pressure of 107/82 mm Hg, a heart rate of 160 beats per minute, and a temperature of 38.4°F.

Additional examination was notable for an extremely agitated, well-nourished, well-developed child with 2% total body surface area partial thickness burn to the forehead. The patient was crying and restless, but the exam was otherwise

received

August 12, 2022

accepted after revision

March 20, 2023

DOI <https://doi.org/>

10.1055/s-0043-1768566.

ISSN 2474-5871.

© 2023. The Author(s).

This is an open access article published by Thieme under the terms of the Creative Commons Attribution License, permitting unrestricted use, distribution, and reproduction so long as the original work is properly cited. (<https://creativecommons.org/licenses/by/4.0/>)

Georg Thieme Verlag KG, Rüdigerstraße 14, 70469 Stuttgart, Germany

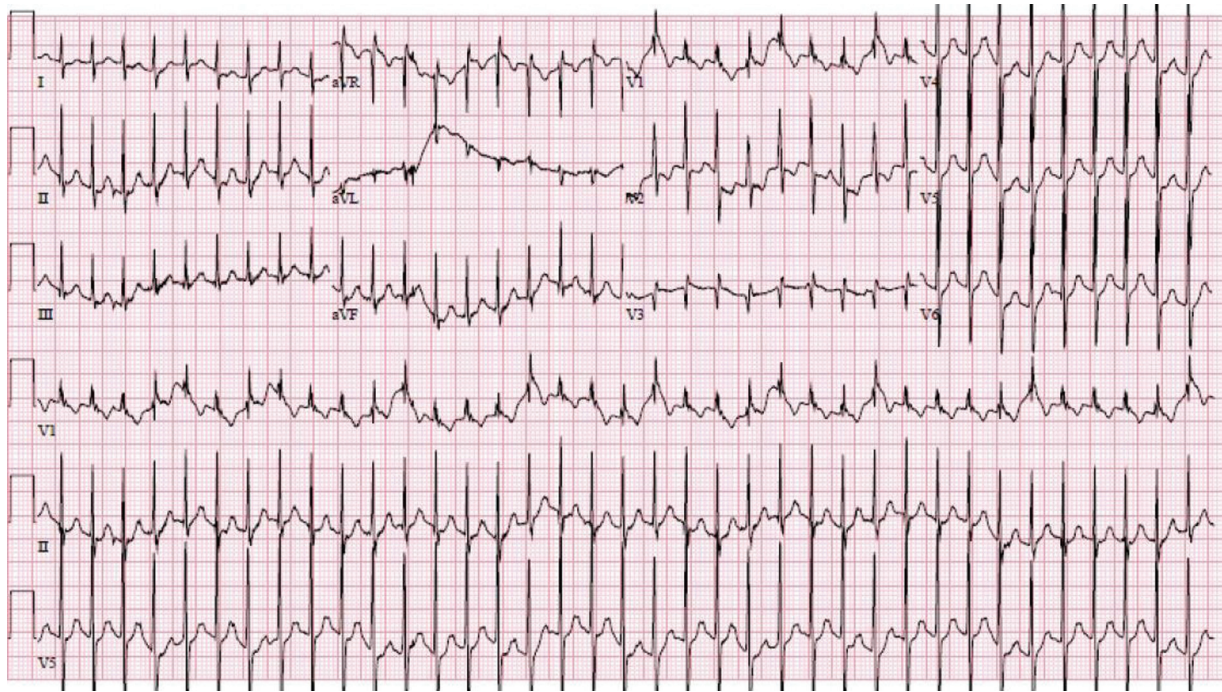


Fig. 1 Electrocardiogram (EKG) obtained during patient's episode of tachycardia. The EKG demonstrates regular, narrow complex tachycardia with absent P waves typical of atrioventricular node reentrant tachycardia.

normal. In the trauma bay, the patient was given 2 mg of intravenous midazolam with only mild improvement in her agitation. Of note, this was the only medication administered to the child during transport and while in the emergency department. Additional past medical history was not immediately available as no caregivers were present at the bedside in the trauma bay.

Initial laboratories were notable for a carboxyhemoglobin of 21% (poisoning is considered to have occurred at carboxyhemoglobin levels of over 10%, and severe poisoning is associated with levels over 20–25%). The patient was admitted to the burn-intensive care unit for further monitoring secondary to concern for possible inhalational injury. Shortly after arrival to the intensive care unit, the patient developed sudden onset of supraventricular tachycardia (SVT) with a heart rate of 250 beats per minute (► Fig. 1).

During the episode, blood pressure by noninvasive cuff was 80/40 mm Hg; the patient was alert, but continued to be inconsolable. Adenosine 0.05 mg/kg was administered via rapid intravenous bolus without response. A second dose of adenosine 0.1 mg/kg of was given with immediate resolution of the SVT. Her heart rate returned to 150 beats per minute and blood pressure increased to 100/62 mm Hg. After this intervention, the patient was noted to have a markedly increased work of breathing in addition to a continued level of agitation that was out of proportion to the size and location of the burn. The decision was made to intubate the patient out of concern for evolving inhalational injury. Following intubation, it was challenging to adequately sedate the child despite concurrent drips of fentanyl, versed and dexmedetomidine. A low-dose infusion of cis-atracurium was necessary to safely reduce the remaining excessive

movements the patient continued to exhibit. The patient had a 5-year-old sister that was rescued from the same fire and admitted for treatment of her burns as well. The sibling was also tachycardic and agitated to a degree inconsistent with presenting visible injuries, although not quite as severely. Per hospital policy, child protective services were contacted due to the unclear circumstances surrounding the fire and because the siblings appeared to be unattended in the structure. A urine toxicology screen was requested for both children, both of which came back positive for cocaine.

Following 4 hours of oxygen therapy, the patient's carboxyhemoglobin decreased to 4%. Bronchoscopy revealed only mild inhalational injury and the patient was successfully extubated on hospital day 2. There were no further episodes of SVT, and the patient received no additional cardiac workup. She was discharged after a thorough investigation by social work and child protection services.

Discussion

This case highlights the importance of a comprehensive differential when treating small children in the acute trauma setting. Although inhalational injury can cause broad and severe physiologic changes, the presence of SVT in the child was an unexpected finding that called for additional workup. Suspicion for another etiology was also heightened by the patient's extreme agitation and a sibling that shared several elements of this peculiar presentation. In addition to physical exam, a detailed history can also be key to expanding the differential. In our patient's case, we did not have the past medical history of the child at initial presentation and even after interviewing the patient's caregiver the circumstances surrounding the fire remained unclear.

Our patient's presenting symptoms of hypoxia, elevated carboxyhemoglobin level, and agitation, as well as facial burns (although minor) appeared consistent with inhalational injury. Both cyanide toxicity and CO poisoning can be associated with agitation and confusion and cyanide toxicity may be associated with cardiac arrhythmias (including SVT). In adults with cyanide poisoning who experience cardiac complications, approximately 30% may be diagnosed with SVT.³

Since the laboratory tests revealed that cyanide was not to blame for this patient's range of symptoms, the cocaine-positive urine screen provides a likely explanation for the patient's SVT. Cocaine has a biological half-life of 45 to 90 minutes and is rapidly metabolized by plasma and liver esterases. The cocaine urine toxicology test evaluates for the presence of benzoylecgonine, an inactive metabolite that can be detected for up to a week after cocaine exposure.⁴ The tachyarrhythmia, agitation, and elevated temperature on presentation are symptoms consistent with cocaine intoxication. These effects are the result of sympathomimetic stimulation by dopamine and norepinephrine and central dopamine and serotonin reuptake inhibition. There is little data on frequency and type of arrhythmia associated with cocaine toxicity, but in research animals, virtually every type of rhythm disturbance can be induced.⁵ These disturbances can be due to the ion-channel effects of cocaine, the increase in sympathetic nervous system stimulation, and/or myocardial ischemia.⁶ In pediatric patients who are unintentionally exposed to cocaine, tachycardia, seizures, and agitation are the most common presenting symptoms.⁷ Case reports from the late 1980s and early 1990s also suggest that small children and infants can have detectable cocaine levels secondary to passive inhalation.^{8,9} Eventually we were able to obtain further history from the caregiver suggesting that an acquaintance with a history of drug abuse had been spending time in the garage. Although the

timeline of events leading up to the patient presenting to the trauma bay remains unclear, it is possible that the positive urine screen for cocaine was secondary to unintentional inhalation of or exposure to the drug. The exposure could have been secondary to proximity to the drug user while they were inhaling cocaine, or the presence of some amount of drug stored in the garage that burned in the fire.

Conflict of Interest

None declared.

References

- 1 Palmieri TL, Warner P, Mlcak RP, et al. Inhalation injury in children: a 10 year experience at Shriners Hospitals for Children. *J Burn Care Res* 2009;30(01):206–208
- 2 Kraft R, Herndon DN, Al-Mousawi AM, Williams FN, Finnerty CC, Jeschke MG. Burn size and survival probability in paediatric patients in modern burn care: a prospective observational cohort study. *Lancet* 2012;379(9820):1013–1021
- 3 Sen S. Pediatric inhalation injury. *Burns Trauma* 2017;5:31. Doi: 10.1186/s41038-017-0097-5
- 4 Fortin JL, Desmettre T, Manzon C, et al. Cyanide poisoning and cardiac disorders: 161 cases. *J Emerg Med* 2010;38(04):467–476
- 5 Moon TS, Pak TJ, Kim A, et al. A positive cocaine urine toxicology test and the effect on intraoperative hemodynamics under general anesthesia. *Anesth Analg* 2021;132(02):308–316
- 6 Mehta A, Jain AC, Mehta MC. Electrocardiographic effects of intravenous cocaine: an experimental study in a canine model. *J Cardiovasc Pharmacol* 2003;41(01):25–30
- 7 Wood DM, Dargan PI, Hoffman RS. Management of cocaine-induced cardiac arrhythmias due to cardiac ion channel dysfunction. *Clin Toxicol (Phila)* 2009;47(01):14–23
- 8 Armenian P, Fleurat M, Mittendorf G, Olson KR. Unintentional pediatric cocaine exposures result in worse outcomes than other unintentional pediatric poisonings. *J Emerg Med* 2017;52(06):825–832
- 9 Bateman DA, Heagarty MC. Passive freebase cocaine ('crack') inhalation by infants and toddlers. *Am J Dis Child* 1989;143(01):25–27