Article published online: 2023-05-01

THIEME OPEN ACCESS

Case Report

Sialolith with Sialadenitis: A Case Study and a Proposal of a Diagnostic Algorithm

Vinisha S. Pousya[1] Urvashi Shetty[1] Pushparaja Shetty[1]

[1] Department of Oral & Maxillofacial Pathology and Oral Microbiology, A B Shetty Memorial Institute of Dental Sciences (ABSMIDS), Nitte Deemed to be University, Mangalore, Karnataka, India

J Health Allied Sci[NU]

Address for correspondence Urvashi Shetty, MDS, Reader, Nitte (Deemed to be University), Department of Oral and Maxillofacial Pathology and Oral Microbiology, AB Shetty Memorial Institute of Dental Sciences (ABSMIDS), Mangalore, Karnataka, India (e-mail: Urvashishetty10@gmail.com; drurvashishetty@nitte.edu.in).

Abstract

Sialolithiasis along with sialadenitis is one of the commonly occurring salivary gland disorders. Sialadenitis is an inflammatory disease of the salivary glands. It usually occurs insidiously causing pain to the patient and may lead to development of fibrous mass of the salivary gland. The cause of sialadenitis is most commonly due to the salivary duct caliculi which is termed as sialolith or salivary stones which causes statis of saliva in the ducts. This condition is usually accompanied by pain and tenderness of the involved site. Therefore, we report a case of a male patient aged 60 years with pain in the floor of the mouth in the submandibular region which was diagnosed as submandibular sialolithiasis along with sialadenitis and propose a diagnostic algorithm.

Keywords

- salivary calculi
- sialadenitis
- salivary stones
- salivary stasis and salivary gland pathology

Introduction

Sialolithiasis occurs in approximately 1% of the general population. About 80 to 90% of salivary stones occur in submandibular gland.[1] The composition of sialolith can vary depending upon the concentrations of organic or inorganic components and the gland in which it has occurred. Submandibular gland sialoliths (SMGS) are usually composed of inorganic materials such as hydroxyapatite, brushite, and octacalcium phosphate.[2] The formation of SMGS is not a single process, it is influenced by various factors such as stasis of saliva, changes occurring in the salivary biochemistry, and accumulation of calcium phosphate.[2] The inflammation of the salivary gland is termed sialadenitis and it is an insidious disease usually affecting the major salivary glands and characterized by intermittent swelling, accompanied by pain and tenderness.[3] The microbiology of sialadenitis is not much reported in submandibular and sublingual glands. Bacterial colonies such as staphylococcus, streptococcus, and Gram-negative bacteria are the most common etiologic factors to cause this inflammatory condition.[4]

Since the exact etiology is still unclear there are few theories considered for the formation of sialoliths: (1) sialomicroliths agglomerating together, (2) mucus plug getting calcified, and (3) alteration of the saliva's biochemical composition. The composition of the sialoliths can be assessed through various methods such as wet chemical techniques, X-ray powder diffraction, and/or Fourier-transform infrared spectroscopy (FTIR). The FTIR is the most commonly accepted method since it is rapid and easily reproducible. The concept of FTIR is that the IR spectrum initially begins from the vibration of molecules. These motions of molecules due to vibration produces frequencies which are unique to individual compounds similar to that of fingerprints. This can be utilized for the classification of organic and inorganic compounds present. Similarly, in wet chemical analysis the quantification of ions and organic components can be calculated.[5] The most commonly accepted method for assessing the composition of lithiasis is wet chemical analysis method proposed by Larsson et al,[6] he had initially performed in urinary caliculi. The wet chemical method includes various steps such as:

(1) Drying and dissolution: Initially, the calculus must be weighed and needs to be pulverized in a mortar and to

DOI https://doi.org/10.1055/s-0043-1768590.
ISSN 2582-4287.

© 2023. The Author(s).
This is an open access article published by Thieme under the terms of the Creative Commons Attribution License, permitting unrestricted use, distribution, and reproduction so long as the original work is properly cited. (https://creativecommons.org/licenses/by/4.0/)

Thieme Medical and Scientific Publishers Pvt. Ltd., A-12, 2nd Floor, Sector 2, Noida-201301 UP, India

be dried over silica gel to completely desiccate at room temperature for 2 days.

(2) Later, 1 mL of concentrated nitric acid to be added to the powder, effervescence shows the presence of carbon.

(3) Next, the calculus needs to be completely dissolved and kept in magnetic stirring for 3 hours at room temperature for creating the sample solution to find the presence of particular component such as calcium, magnesium, ammonium, phosphate, oxalate, and urate. The sample solution shouldn't be diluted for the analysis of cysteine and protein but for rest it needs to be diluted.

(4) Result calculation: The molar concentrations and volume of sample solution can be used to evaluate the amount of analyte in µmol. The composition of calculus can be computed.[6]

The diagnosis of this disease is usually made clinically with conventional radiography such as orthopantomogram (OPG) or occlusal radiographs followed by surgical removal of the salivary stone and the gland involved.[5]

Case Report

Clinical Examination

A 60-year-old male patient presented with pain and swelling in the lower right side of the floor of the mouth for the past week. The history of pain was sudden in onset with moderate intensity and was continuous in nature. The patient did not state any aggravating or relieving factors. The patient also gave no relevant history about the change in the size of the mass. On extraoral examination, mild facial asymmetry was noted on the right side. On palpation of the right submandibular region, there was a diffused enlargement noted of approximately 2 cm × 2 cm in size roughly along with tender and palpable lymph nodes. There was no difficulty in mouth opening and closing along with normal jaw moments.

Radiographic Examination

An OPG was taken (►**Fig. 1**). The OPG revealed a well-defined radiopaque mass seen superimposed in the right lower body of the mandible near the angle of the mandible of size approximately 3.5 mm × 1.7 mm in size and a provisional diagnosis of sialolith was considered. The patient was referred to the department of oral surgery for further management.

Surgical Intervention

The surgeons evaluated the patient and prepared for the removal of the sialolith along with the involved salivary gland. An excisional biopsy was performed and given for histological evaluation (►**Fig. 2**).

Histopathological Examination

The gross specimen was received for histopathological evaluation (►**Fig. 3**). A radiograph of the gross specimen was also taken to check for any other calcifications present within the gland (►**Fig. 4**). On gross examination of the sialolith it roughly measured around 1.3 cm × 0.9 cm in size (►**Fig. 5**).

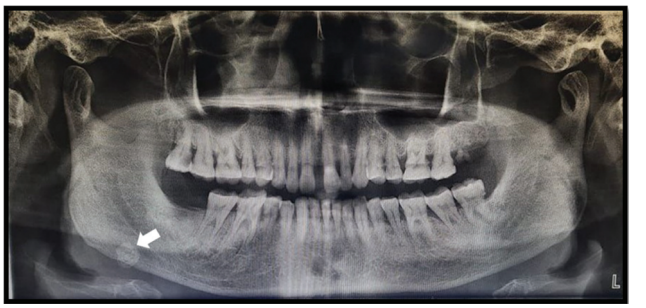

Fig. 1 X-ray showing sialolith on right submandibular region (white arrow).

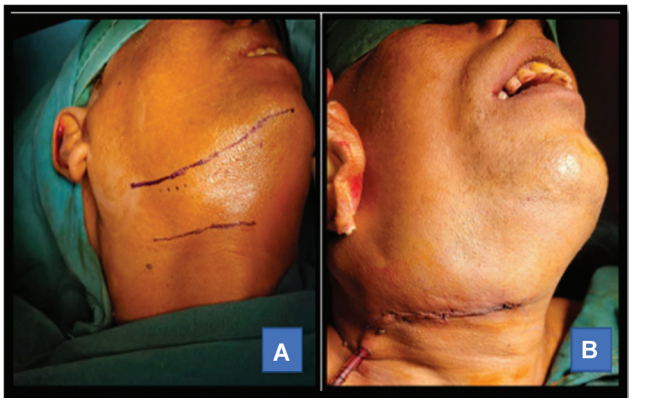

Fig. 2 (**A**) Preop picture of the patient with marking prior to removal of the sialolith and the involved submandibular gland. (**B**) Postop picture of the patient after the removal of sialolith along with submandibular gland.

The hematoxylin and eosin-stained section showed encapsulated lobules of the salivary gland which were seen separated by thin fibrous septa. Numerous seromucous acini were seen. One part of the section showed loss of architecture of the acini and a focal area of diffused infiltration of inflammatory cells into the gland along with numerous ducts. Periductal inflammation was also noted along with blood vessels and extravasated red blood cells (►**Fig. 6**).

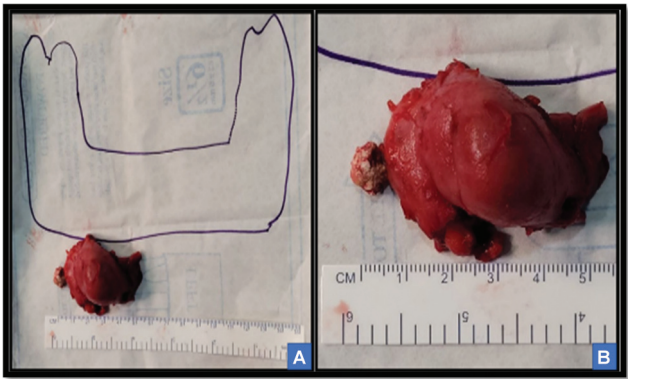

Fig. 3 (**A**) the gross specimen. (**B**) Sialolith along with submandibular gland approximately measuring 5.5 cm × 4.5 cm.

 © 2023. The Author(s).

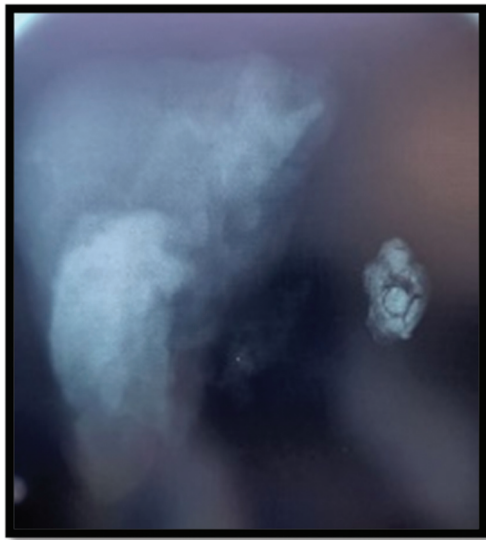

Fig. 4 X-ray of the excisional biopsy of sialolith along with submandibular gland.



Fig. 5 Macroscopic view of sialolith roughly measuring 1.3 cm × 0.9 cm in size.

Discussion

Sialolithiasis

Sialolithiasis is formation of salivary stones in the ducts of the major salivary glands: the parotid, submandibular, and sublingual glands with a reported prevalence of 1 in 10,000 to 1 in 30,000, and it is the most common cause of salivary gland enlargement.[7] Sialoliths can occasionally restrict the salivary ducts, causing inflammation and root a secondary bacterial infection, or in extremely rare circumstances form an abscess. There are many presenting signs, but the two most prevalent signs are reduced salivary flow and cyclical

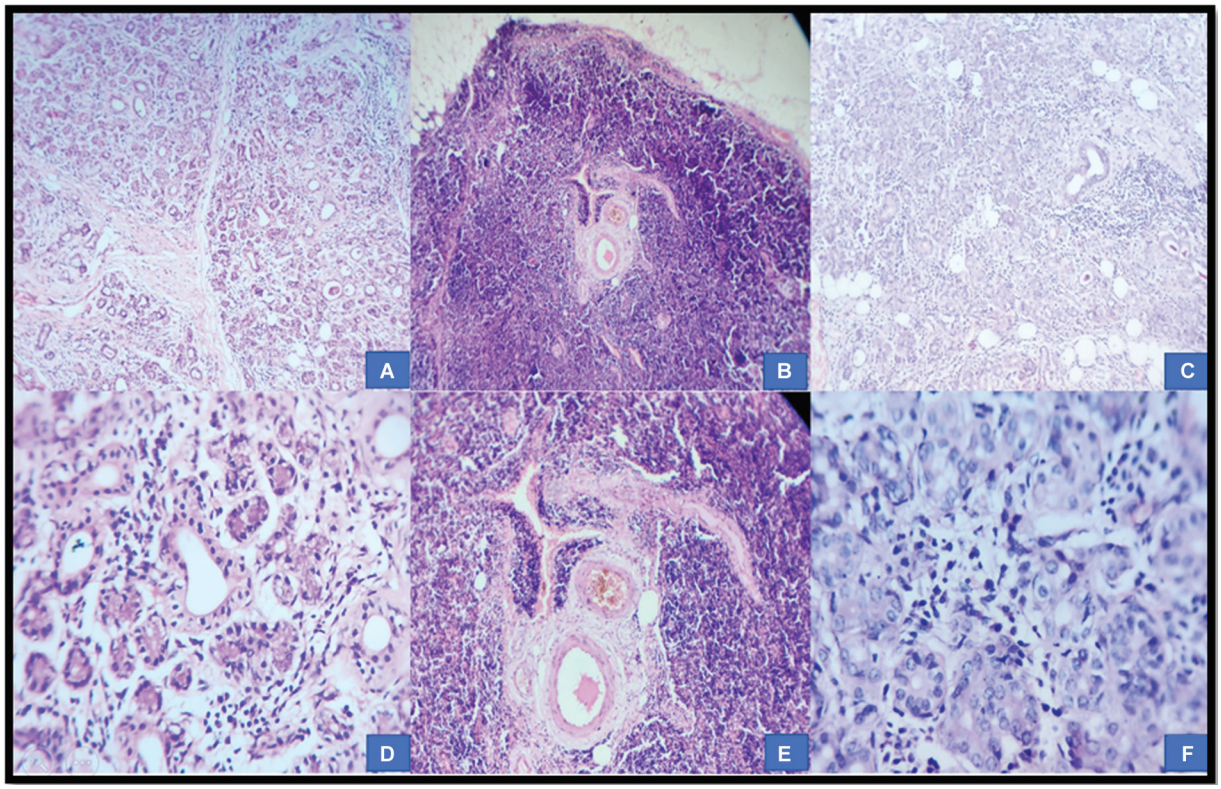

Fig. 6 Photomicrograph of submandibular sialadenitis showing: (**A**) Lobules of gland with mixed seromucinous acini in lower power magnification. (**B**) Periductal inflammation with dense inflammatory infiltrate. (**C**) Infiltration of inflammatory cells into the gland. (**D** and **F**) Higher power image showing infiltration of inflammatory cells in between acini and ducts. (**E**) Destruction of the ducts by the inflammatory cells.

 © 2023. The Author(s).

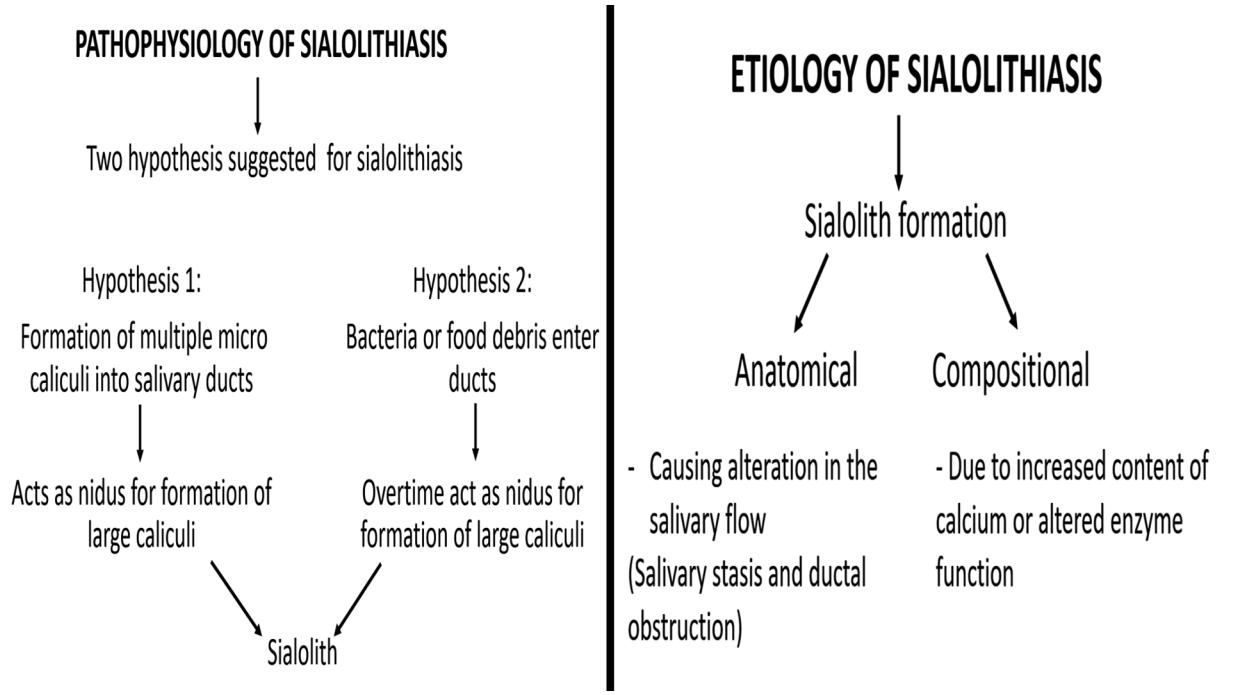

Fig. 7 Flowcharts showing the pathophysiology and etiology of sialolithiasis.

postprandial enlargement of the afflicted gland.[8] The etiology and pathophysiology are presented as a flowchart (►**Fig. 7**).[9,10]

Sialadenitis

Sialadenitis is the inflammatory condition of salivary glands. It most commonly occurs in major salivary glands. Submandibular sialadenitis is usually caused due to stasis of saliva which in turn leads to retrograde seeding of bacteria from the oral cavity. Submandibular glands are present bilaterally in the submandibular triangle covered by the investing layer of deep cervical fascia and it drains into the oral cavity through the Wharton's duct in the floor of the mouth. The submandibular gland saliva is rich in potassium and low in sodium. There are two forms of submandibular gland sialadenitis: acute and chronic form. The acute form is characterized by insidiously occurring and the chronic form is characterized by long-standing infection due to obstruction. The usual clinical presentation will be swelling of the gland without erythema accompanied by pain. The common causes and pathophysiology are listed in ►**Fig. 8**.[11–14]

Since there are numerous causative factors, all differential diagnosis must be excluded by the clinician based on the clinical criteria to arrive at a diagnosis. The clinical, radiographical, laboratory, and histological tests need to be done for confirmatory diagnosis. To assist the diagnostician in

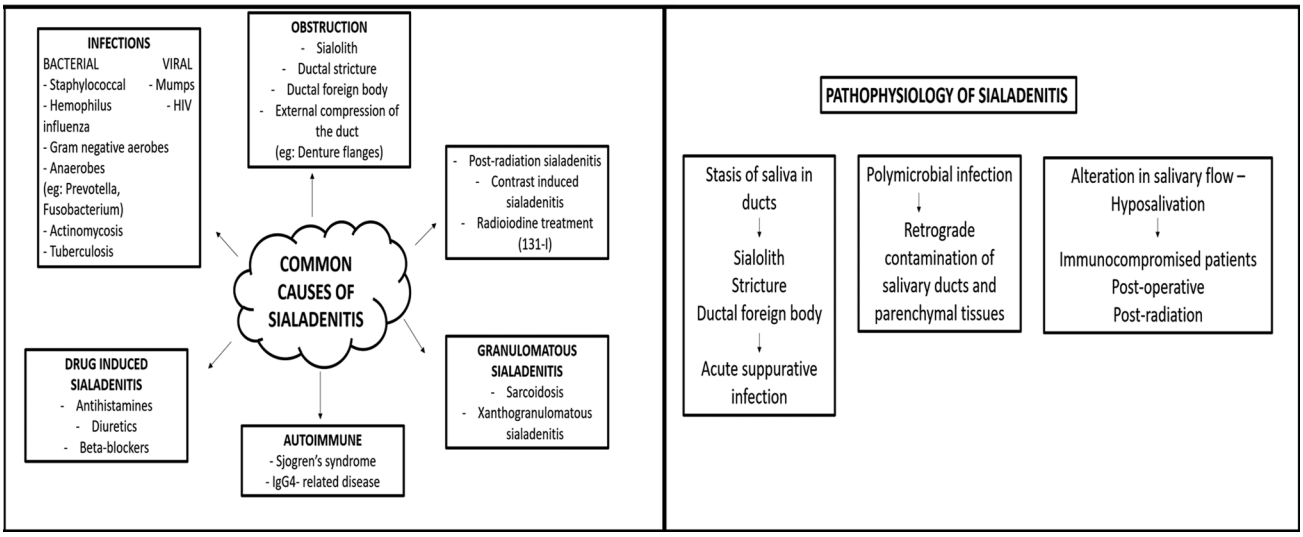

Fig. 8 Common causes and pathophysiology of sialadenitis.

 © 2023. The Author(s).



Fig. 9 Diagnostic algorithm for sialadenitis and sialolithiasis.

reaching a diagnosis and course of treatment, we suggest a straightforward but practical diagnostic algorithm. This algorithm takes into consideration the palpable salivary stones as well[15–18] (►**Fig. 9**).

The most common cause of sialadenitis is sialolithiasis, which occurs in the submandibular region and accounts for approximately 80% of cases.[19] There are various theories put forth on the formation of salivary stones, but they are most likely to occur in the submandibular gland because of salivary stagnation, increased alkalinity of saliva, physical trauma, being more susceptible to infection and inflammation, and the production of saliva against gravity.[20] Also, the contents of submandibular saliva contribute due to their increased levels of mucin, protein, calcium, and phosphate

Table 1 Differential diagnosis that can be considered for swelling in submandibular region and radiopacities seen in radiographs[25,26]

Differential diagnosis considered for submandibular gland swelling	
Acute symptoms	**Chronic symptoms**
- Viral infections - Bacterial infections	- Obstruction of the duct due to caliculi - Low-grade non0pyogenic bacterial infection - Lymphoepithelial disease such as sicca syndrome - Granulomatous conditions such as tuberculosis, fungal infections - Sarcoidosis - Salivary gland neoplasm
Lesions with similar clinical presentations in the submandibular region are: - Space infections - Dental abscess - Thyroglossal cyst	
- Non-neoplastic, noninflammatory swelling of the salivary gland can occur due to various reasons such as metabolic and nutritional imbalances which also includes liver cirrhosis due to alcoholism, pellagra, and uremia	
Differential diagnosis to be considered for radiopacities in submandibular region	
- Sialoliths (salivary stone or caliculi) - Calcified lymph nodes - Phleboliths - Tuberculosis - Atherosclerotic plaques - Metastasis from calcified carcinoma	

 © 2023. The Author(s).

Table 2 Cases of sialoliths occurring in submandibular gland reviewed in literature from the year 2010 to 2023 among the Indian population

Author name	Year of publication	Age and gender of the patient	Feature and site of occurrence
Chandra Mouli et al[27]	2011	44/M	Pain on lower left side below the tongue
Shetty and Sharma[28]	2010	50/M	Left submandibular region, swelling
Lokesh Babu and Jain[29]	2011	50/M	Left side on the floor of the mouth, pain with swelling
Parkar et al[30]	2012	84/F	Left floor of the mouth, swelling
Iqbal et al[31]	2012	55/M	Left submandibular duct region
Arunkumar et al[32]	2015	55/M	Left border of the mandible, swelling
Marwaha and Nanda[33]	2012	10/F	Left submandibular gland region, intermittent pain
Saluja et al[34]	2012	65/M	Right side floor of the mouth, pain and swelling
Kuruvila et al[35] (6 cases)	2013	1- 55/F 2- 25/F 3,4,5- F (age not mentioned) 6- 8/F	Right mandibular region Lower left back tooth region Swelling in the floor of the mouth Swelling below the tongue
Dalal et al[36]	2013	40/F	Left floor of the mouth, intermittent pain
Singh and Singh[37]	2013	55/M	Floor of the mouth, asymptomatic
Dewan et al[38] (multiple sialoliths)	2013	26/M	Pus discharge from the opening of the duct
Kiran et al[39] (2 cases)	2013	26/M 44/M	Right submandibular region, swelling and pain Left submandibular region, swelling
Divya and Sathasivasubramanian[40] (2 cases)	2013	22/M 69/F	An insidious swelling appears during meals and disappears Pain below the tongue
Trivedi[41]	2014	9/F	Right submandibular region
Sinha et al[42]	2014	55/M	Right lower side of the face, swelling with intermittent pain
Mathew Cherian et al[43]	2014	36/M	Floor of the mouth, pain and swelling
Shruthi Hegde et al[44]	2014	55/M	Left submandibular region, swelling
Baliah et al[45] (2 cases)	2014	10/M 55/M	Right submandibular region, swelling Lower border of mandible, swelling
Krishnan et al[46]	2014	43/M	Left side on the floor of the mouth, swelling
Mohapatra et al.[47]	2015	18/F	Right submandibular region, swelling
Kiran et al[48]	2015	65/M	Floor of the mouth, swelling
Gopinath[49]	2015	35/M	Intraoral swelling with chronic pain
Thopte et al[50]	2016	23/M	Lower right back tooth region, pain
Singh et al[51]	2016	35/M	Floor of the mouth, pain and swelling
Sabu et al[52]	2017	55/M	Bilateral swelling noted on the lower jaw
Rana and Arya[53] (3 cases)	2017	22/M 35/M 48/F	Right side of the face, pain and swelling Left side of the face, pain and mild swelling Right submandibular region
Sakthivel et al[54]	2017	42/M	Right submandibular region, swelling
Monika et al[55]	2017	52/F	Floor of the mouth, swelling
Ujjwal et al[56] (2 cases)	2018	58/F Young female (age not mentioned)	Left submandibular region, swelling Right submandibular region, intermittent pain and swelling
Sengupta and Bose[57]	2018	35/M	Pain on mastication
Neeraj et al[58]	2018	37/M	Left submandibular region, pain

 © 2023. The Author(s).

Table 2 (*Continued*)

Author name	Year of publication	Age and gender of the patient	Feature and site of occurrence
Wadhawan et al[59]	2019	19/M	Right back jaw region, swelling
Kumar et al[60]	2021	29/M	Left angle of mandible
Nirola et al[61] (2 cases)	2020	37/M 35/F	Right side floor of the mouth Left side floor of the mouth, swelling
Khorate and Vaidya[62]	2020	39/M	Left submandibular region, swelling
Chandak and Chandu[63]	2020	23/M	Left submandibular region, pain and swelling
Anand et al[64]	2020	69/M	Floor of the mouth, pain
Mathew et al[65]	2022	50/M	Right submandibular region, swelling
Present case	2023	60/M	Right lower side in floor of the mouth, pain and swelling

Abbreviations: F, female; M, male.

compared to that of other major salivary glands.[19] In fact, tobacco can also contribute to the formation of sialoliths because it greatly influences the rate of salivary flow and can also cause inflammation of the gland.[20] About 85% of the sialoliths occur in Wharton's duct because of its complex morphology, while the rest, 15%, occur in the gland parenchyma.[20,21] The obstruction of the gland can cause swelling with a subsequent risk of superinfection. Sialolith usually occurs predominantly in adult male population. In the current case report a 60-year-old male was affected which is in accordance to the literature.[21] The signs and symptoms include cyclical episodes of pain accompanied by inflammation and swelling, the inflammation and swelling occur due to the obstruction of the flow of saliva, resulting in increased intraglandular pressure. In partial or incomplete ductal obstruction, the saliva can escape around the sialolith. In these types of cases, the patients will be asymptomatic and can only be diagnosed as an incidental finding in routine dental radiography.[22] The imaging of the salivary gland is crucial because it aids in determining the location, kind, and extent of the lesion, assessing the ductal morphology, choosing the site of the biopsy, and formulating a treatment strategy.[23] Conventional radiography, digital subtraction sialography, sonography, computed tomography, and magnetic resonance (MR) imaging sialography are imaging methods that can be used to investigate salivary calculi. Just 20% of calculi are radiopaque, and conventional radiography depends on the nature of the stone. Digital subtraction sialography has a sensitivity range of 96 to 100% and a specificity range of 88 to 91%. Because of the possibility for an infection's symptoms to worsen, it is contraindicated in the acute context. According to reports, sonography has a sensitivity range of 59.1 to 93.7% and a specificity range of 86.7 to 100%.[22,23] According to reports, MR imaging sialography has a 91% sensitivity rate and a 94 to 97% specificity rate.[24]

The choice of imaging modality should be made based on the disease and the characteristics of the patient. There are numerous therapy options that principally rely on the sialolith's size and location. Frequently performed is bimanual palpation for tiny stones which pass through the duct and are "milked out." Surgical shock wave lithotripsy is advised for salivary stones up to 10 mm which have been found in the proximal part of the duct and it is an extremely minimal invasive procedure for removing substantial salivary stones. Sialoliths greater than 10 mm and which are not palpable are removed surgically along with the gland involved.[15–18]

The differentials that can be considered in case of swelling in the submandibular region and radiopacities seen in radiographs are listed out in ►**Table 1**.

The uniqueness of this case study is that it provides a detailed insight on sialolith in the submandibular gland; its etiology, pathogenesis, analysis and composition of salivary caliculi, and a diagnostic algorithm is proposed which can help the surgeons to manage sialoliths with sialadenitis more efficiently and contribute to the literature on the subject. The terms "sialolithiasis" and "submandibular gland sialolithiasis" were used in searches on PubMed and Google Scholar. Pertinent published articles in dentistry journals were reviewed and included in the current case report. Only English-language studies published after the year 2010 reporting cases of sialoliths with sialadenitis occurring in the submandibular gland among Indian population were chosen for the review and tabulated (►**Table 2**).

Conclusion

Sialoliths need to be assessed and managed properly prior to the involvement of the gland because sialadenitis can cause detrimental effects. A meticulous history collection and appropriate imaging techniques would preserve time. This case report adds to the literature, it illustrates a case of sialolithiasis occurring along with sialadenitis that was diagnosed clinically and interpreted using a simple radiograph and treated with no complications. A diagnostic algorithm has been proposed to arrive at a quick diagnosis and initiate a prompt treatment.

 © 2023. The Author(s).

Conflict of Interest
None declared.

Acknowledgment
None.

References

1 Williams MF. Sialolithiasis. Otolaryngol Clin North Am 1999;32 (05):819–834
2 Kraaij S, Karagozoglu KH, Forouzanfar T, Veerman ECI, Brand HS. Salivary stones: symptoms, aetiology, biochemical composition and treatment. Br Dent J 2014;217(11):E23
3 Jambhulkar M, Palve D, Mohite D, Udapure S, Bodele V, Borkar V. Sialadenitis associated with sialolith- a case report. Arch Dent Res 2021;11(02):130–132
4 McQuone SJ. Acute viral and bacterial infections of the salivary glands. Otolaryngol Clin North Am 1999;32(05):793–811
5 Kraaij S, Brand HS, van der Meij EH, de Visscher JG. Biochemical composition of salivary stones in relation to stone- and patient-related factors. Med Oral Patol Oral Cir Bucal 2018;23(05): e540–e544
6 Larsson L, Sörbo B, Tiselius HG, Ohman S. A method for quantitative wet chemical analysis of urinary calculi. Clin Chim Acta 1984; 140(01):9–20
7 Bijai LK, Jayaraman V, Austin RD. Chronic bacterial sialadenitis—a case report. Oral Surg Oral Med Oral Radiol 2013;1(01):1–3
8 Huoh KC, Eisele DW. Etiologic factors in sialolithiasis. Otolaryngol Head Neck Surg 2011;145(06):935–939
9 Rzymska-Grala I, Stopa Z, Grala B, et al. Salivary gland calculi - contemporary methods of imaging. Pol J Radiol 2010;75(03): 25–37
10 Sherman JA, McGurk M. Lack of correlation between water hardness and salivary calculi in England. Br J Oral Maxillofac Surg 2000;38(01):50–53
11 Marchal F, Kurt AM, Dulguerov P, Lehmann W. Retrograde theory in sialolithiasis formation. Arch Otolaryngol Head Neck Surg 2001;127(01):66–68
12 Silvers AR, Som PM. Salivary glands. Radiol Clin North Am 1998; 36(05):941–966, vi vi
13 Virmani N, Dabholkar J. Primary tubercular sialadenitis - a diagnostic dilemma. Iran J Otorhinolaryngol 2019;31(102):45–50
14 Lucarelli A, Perandini S, Borsato A, Strazimiri E, Montemezzi S. Iodinated contrast-induced sialadenitis: a review of the literature and sonographic findings in a clinical case. J Ultrason 2018;18 (75):359–364
15 Gurwale SG, Gore CR, Gulati I, Dey I. Immunoglobulin G4-related chronic sclerosing sialadenitis: an emerging entity. J Oral Maxillofac Pathol 2020;24(Suppl 1):S135–S138
16 Koch M, Zenk J, Iro H. Algorithms for treatment of salivary gland obstructions. Otolaryngol Clin North Am 2009;42(06): 1173–1192
17 Capaccio P, Torretta S, Pignataro L. The role of adenectomy for salivary gland obstructions in the era of sialendoscopy and lithotripsy. Otolaryngol Clin North Am 2009;42(06):1161–1171
18 Abdel Razek AAK, Mukherji S. Imaging of sialadenitis. Neuroradiol J 2017;30(03):205–215
19 Zhang YY, Hong X, Wang Z, et al. Diagnostic utility of submandibular and labial salivary gland biopsy in IgG4-related sialadenitis. Clin Rheumatol 2020;39(12):3715–3721
20 Lustmann J, Regev E, Melamed Y. Sialolithiasis. A survey on 245 patients and a review of the literature. Int J Oral Maxillofac Surg 1990;19(03):135–138
21 Yiu AJ, Kalejaiye A, Amdur RL, Todd Hesham HN, Bandyopadhyay BC. Association of serum electrolytes and smoking with salivary gland stone formation. Int J Oral Maxillofac Implants 2016;45 (06):764–768
22 Rauch S, Gorlin RJ. Disease of the salivary glands. In: Gorlin RJ, Goldmann HM, eds. Thomas' Oral Pathology. St Louis, MO: Mosby-Year Book Inc.; 1970:997–1003
23 Pace C, Ward S. Incidental finding of sialolithiasis in the sublingual gland: a diagnostic dilemma. Dent Update 2011;38(10):704–705
24 Joshi B. Imaging the major salivary glands: a review. Adv Dent & Oral Health 2018;8(04):555745
25 Purcell YM, Kavanagh RG, Cahalane AM, Carroll AG, Khoo SG, Killeen RP. The diagnostic accuracy of contrast-enhanced CT of the neck for the investigation of sialolithiasis. AJNR Am J Neuroradiol 2017;38(11):2161–2166
26 Blitzer A. Inflammatory and obstructive disorders of salivary glands. J Dent Res 1987;66(Spec No):675–679
27 Chandra Mouli PE, Kumar SM, Kailasam S, Shanmugam S, Satish S. Sialolith: a case report with review of literature. Indian J Multidiscip Dent 2011;2:377–379
28 Shetty BN, Sharma P. Unusual case of a projecting intraoral giant sialolith. Indian J Surg 2010;72(02):155–157
29 Lokesh Babu K, Jain MK. Giant submandibular sialolith: a case report and review of literature. Int J Head Neck Surg 2011;2(03): 154–157
30 Parkar MI, Vora MM, Bhanushali DH. A large sialolith perforating the Wharton's duct: review of literature and a case report. J Maxillofac Oral Surg 2012;11(04):477–482
31 Iqbal A, Gupta AK, Natu SS, Gupta AK. Unusually large sialolith of Wharton's duct. Ann Maxillofac Surg 2012;2(01):70–73
32 Arunkumar KV, Garg N, Kumar V. Oversized submandibular gland sialolith: a report of two cases. J Maxillofac Oral Surg 2015;14 (Suppl 1):116–119
33 Marwaha M, Nanda KD. Sialolithiasis in a 10 year old child. Indian J Dent Res 2012;23(04):546–549
34 Saluja H, Kasat VO, Mahindra U. Giant Sialolith in the Wharton's duct causing sialo-oral fistula: a case report and review of literature. J Orofac Sci 2012;4:137–142
35 Kuruvila VE, Bilahari N, Kumari B, James B. Submandibular sialolithiasis: report of six cases. J Pharm Bioallied Sci 2013;5 (03):240–242
36 Dalal S, Jain S, Agarwal S, Vyas N. Surgical management of an unusually large sialolith of the Wharton's duct: a case report. King Saud Univ J Dental Sci 2013;4(01):33–35
37 Singh S, Singh S. Submandibular gland megalith eroding the floor of the mouth: a case report. Ear Nose Throat J 2013;92(12): e17–e19
38 Dewan H, Dewan SK, Patel H, Pandya H, Bhavasar B, Shah U. Multiple sialoliths in Wharton's duct: a case report. BUJOD 2013; 3(02):99–101
39 Kiran JS, Sachin S, Amit KS. Unusaual presentation of submandibular duct and gland calcui: case report. Online J Otolaryngol 2013; 3(01):56
40 Divya VC, Sathasivasubramanian S. Submandibular sialolithiasis-a report of two cases. Biomed 2013;5:240–242
41 Trivedi BD. Surgical removal of submandibular gland sialolithiasis in a 9-year-old girl: A case report. Pediatr Dent J 2014;24(02): 111–114
42 Sinha P, Nagaraj T, Mahalakshmi IP, Suchetha DN. Submandibular gland sialolithiasis with chronic sialadenitis: a case report. Intl J Med Dental Case Rep 2014;1(01):1–4
43 Mathew Cherian N, Vichattu SV, Thomas N, Varghese A. Wharton's duct sialolith of unusual size: a case report with a review of the literature. Case Reports Dentist 2014;2014;
44 Shruthi Hegde DP, Shetty SR, Ajila V. Sialadenitis of left submandibular salivary gland associated with giant sialolith-a case report. Ind J of Med Res and Pharm Sci 2014;1(1)
45 Baliah J, Kayalvizhi EB, Rangdhol V, Lakshman VL. Giant sialolithiasis-a case report and review. J Sci Dentist 2014;4(02):30–33
46 Krishnan AR, Raj SV, Sooraj S, Rahul R, Kamal SS, Deepa MS. Giant submandibular sialolith. Kerala Dent J 2014;37:37–39

 © 2023. The Author(s).

47 Mohapatra S, Verma A, Sharma A, Choudhary A, Narain P. Giant sialolith in Wharton's duct with perforation in oral cavity: case report. Indian J Contemp Dentist 2015;3(02):44
48 DN Kiran, Garg A, Garg B, Kumar S, S Chawla JP. A megalith (giant sialolith) in Wharton's duct: a case report and review of the literature. Egyptian J Oral Maxillofacial Surg 2015;6(03):102–106
49 Gopinath G. A rare case report of large submandibular duct calculus. Intl J Curr Innovat Res 2015;1:225–227
50 Thopte S, Nisa SU, Jadhav A, Chaudhari R. Sialolithiasis of submandibular gland with acute suppurative sialadenitis: A Case Report. World J Pharm Pharm Sci 2016;5(4):1677–1682
51 Singh P, Singh S, Vermani M, Garg S, Gupta A. Giant sialolith of Wharton's duct treated economically in a poor patient. J Clin Diagn Res 2016;10(06):ZJ03–ZJ04
52 Sabu AM, Gandhi S, Solanki M, Sakharia AR. Submandibular sialolithiasis with sialadenitis presenting as Ludwigs angina-a case report. J Adv Med Dental Sci Res 2017;5(06):10–12
53 Rana SS, Arya S. Sialolithiasis of the Wharton's duct-report of 3 cases. J Adv Med Dental Sci Res 2017;5(11):108–111
54 Sakthivel P, Yogal R, Singh S, Sharma P, Singh CA. Giant sialolith of submandibular duct. JNMA J Nepal Med Assoc 2017;56(206): 262–264
55 Monika M, Vijay L, Amita S, Payal L, Sonal DP, Praveen R. Submandibular sialolith of an unusual size: a clinical review. Ann Dental Special 2017;5(04):198
56 Ujjwal G, Rajesh K, Gurkeerat S, Mehvash G. Submandibular sialolithiasis: a brief overview and report of two cases. Mod Res Dent 2018;1(05):1–7
57 Sengupta S, Bose S. Sialolithiasis of right submandibular duct of unusual size. Indian J Surg 2018;80(02):190–191
58 Neeraj NJ, Beniwal BL, Maliwad V, Berwal V. Sialolithiasis of the submandibular salivary duct-a case report. J Oral Med Oral Surg Oral Pathol Oral Radiol 2018;4(01):58–60
59 Wadhawan R, Mohan V, Gupta S, Lau H. Sialolithiasis in a 19 year old male: a case report. J Dent Spec 2019;7:118–121
60 Kumar ND, Sherubin JE, Bagavathy K. Sialolithiasis: an unusually large salivary stone. J Maxillofac Oral Surg 2021;20(02):227–229
61 Nirola A, Grover S, Batra P. Submandibular duct sialoliths of unusual sizes-two case reports. J Dent Health Oral Disord Ther 2020;11(01):33–35
62 Khorate MM, Vaidya A. Submandibular sialolithiasis case report with 10 years follow up. Intl J Appl Dental Sci 2020;6:446–449
63 Chandak SR, Chandu R. Submandibular gland Wharton's duct phlegomous calculus sialoadenitis: A rare case report. J Datta Meghe Inst Med Sci Univ 2020;15(02):292–294
64 Anand J, Suresh A, Desai AK. A giant submandibular sialolith-How to manage? S Afr Dent J 2020;75(07):387–390
65 Mathew J, Pothanikat JJK, Vinod Kumar RB, Padikadan NO, Arakkal NJ. Extremely large submandibular sialolith removal - a case report. Ann Maxillofac Surg 2022;12(02):237–239

 © 2023. The Author(s).