



Supratentorial Intracerebral Hematoma as a Rare Complication of Posterior Fossa Surgery in Prone Position: A Case Report with Review of Literature

Hanuman Prasad Prajapati¹ Raj Kumar²

¹ Department of Neurosurgery, Uttar Pradesh University of Medical Sciences, Saifai, Etawah, Uttar Pradesh, India

² Department of Neurosurgery, SGPGI, Lucknow, Uttar Pradesh, India

Address for correspondence Hanuman Prasad Prajapati, MCh, Department of Neurosurgery, Uttar Pradesh University of Medical Sciences (UPUMS) Saifai, Etawah, UP - 206130, India (e-mail: pushpa84.dhp@gmail.com).

AJNS 2023;18:387–390.

Abstract

Supratentorial intracerebral hematoma is a rare complication after posterior fossa tumor surgery in prone positioning. Although rare, its occurrence may cause significant impact on survival of the patient. We had described this rare complication and their possible pathophysiology in this report. A 52-year-old male with fourth ventricle epidermoid tumor with noncommunicative hydrocephalus was presented to us in drowsy condition in emergency department. Right-sided medium pressure ventriculo-peritoneal surgery was performed in emergency. After shunt surgery patient become conscious and oriented. Total excision of tumor was done via suboccipital craniotomy in prone positioning after preanesthesia fitness. Patient extubated from anesthesia and was conscious but after 2 hours patient condition deteriorated. Patient was intubated again and taken on ventilatory support. Postoperative plain computed tomography brain showed total excision of tumor with left temporal lobe hematoma. Patient was managed conservatively and his condition improved in 3 weeks' periods. Supratentorial intracerebral hematoma after posterior fossa surgery in prone positioning is a rare complication. Despite the rarity of this complication, it is still challenging as it may lead to significant morbidity and mortality.

Keywords

- ▶ supratentorial
- ▶ intracerebral hematoma
- ▶ posterior fossa
- ▶ complication
- ▶ prone position

Introduction

Supratentorial intracerebral hematoma remote from the operative site after posterior fossa tumor surgery in prone positioning is a rare complication. Its occurrence may cause significant morbidity and mortality.^{1–3} Incidence of supratentorial hemorrhage after posterior fossa surgery is 0.4 to 1.6%.⁴

A few cases have been reported in the literature; however, the exact cause could not be located.^{3,5,6} In this article, we report a case of supratentorial hematoma developed after posterior fossa tumor removal in prone positioning. We have made an attempt to find out the pathophysiology and the possible ways to prevent this complication. The work has been reported according to SCARE 2020 criteria. Written consent was taken from the

article published online
June 7, 2023

DOI <https://doi.org/10.1055/s-0043-1768602>.
ISSN 2248-9614.

© 2023. Asian Congress of Neurological Surgeons. All rights reserved.

This is an open access article published by Thieme under the terms of the Creative Commons Attribution-NonDerivative-NonCommercial-License, permitting copying and reproduction so long as the original work is given appropriate credit. Contents may not be used for commercial purposes, or adapted, remixed, transformed or built upon. (<https://creativecommons.org/licenses/by-nc-nd/4.0/>)

Thieme Medical and Scientific Publishers Pvt. Ltd., A-12, 2nd Floor, Sector 2, Noida-201301 UP, India

patient's attendant for publication of this case report and accompanying images.

Case Report

A 52-year-old male presented to us with history of progressive headache from 1 year. Patient also having recurrent vomiting from last 7 days. On admission patient was drowsy. Plain computed tomography (CT) brain done on emergency basis showed a large hypodense mass of size 5.89×4.3 cm in fourth ventricle. It was associated with noncommunicating hydrocephalus with periventricular lucency. Right-sided medium pressure ventriculoperitoneal shunt surgery was done in emergency. After shunt surgery, patient become conscious and oriented to time, place, and person.

On neurological examination, his higher mental function, cranial nerve, motor and sensory system examination were normal. There was slight gait ataxia on cerebellar examination. Contrast magnetic resonance imaging findings were suggestive of large epidermoid tumor in fourth ventricle (→Fig. 1). Patient was prepared for surgery and suboccipital craniotomy in prone position with total excision of tumor was done. Intraoperative period was uneventful. Immediately after surgery, patient was extubated and conscious and oriented. After 2 hours of surgery, patient condition deteriorated

and patient reintubated and took on ventilatory support. Postoperative plain CT brain was done and it showed left temporal intracerebral hematoma with total excision of tumor (→Fig. 2). Tracheostomy was done on postoperative day 3.⁷ Gradually patient neurological condition improved and he became conscious and weaned from ventilatory support on postoperative day 6. Patient developed chest infection that was managed conservatively with intravenous antibiotics. Tracheostomy tube was removed on postoperative day 22 and patient was discharge from the hospital.

Discussion

Operative site hematoma may occur after surgery but remote hemorrhage mostly of intracerebral is rare. Only few cases were reported in the literature and the cause of this particular complication was not clear in majority of cases.⁵ We have summarized these cases in →Table 1. The following pathophysiologies have been proposed.

In the previous reported cases, most were operated in sitting position, hematoma developed within hours of surgery, and majority of the cases either died or had severe disability (→Table 1). The sitting position can reduce the arterial blood flow, causing ischemia and after the return to the supine position, the hypertension can lead to

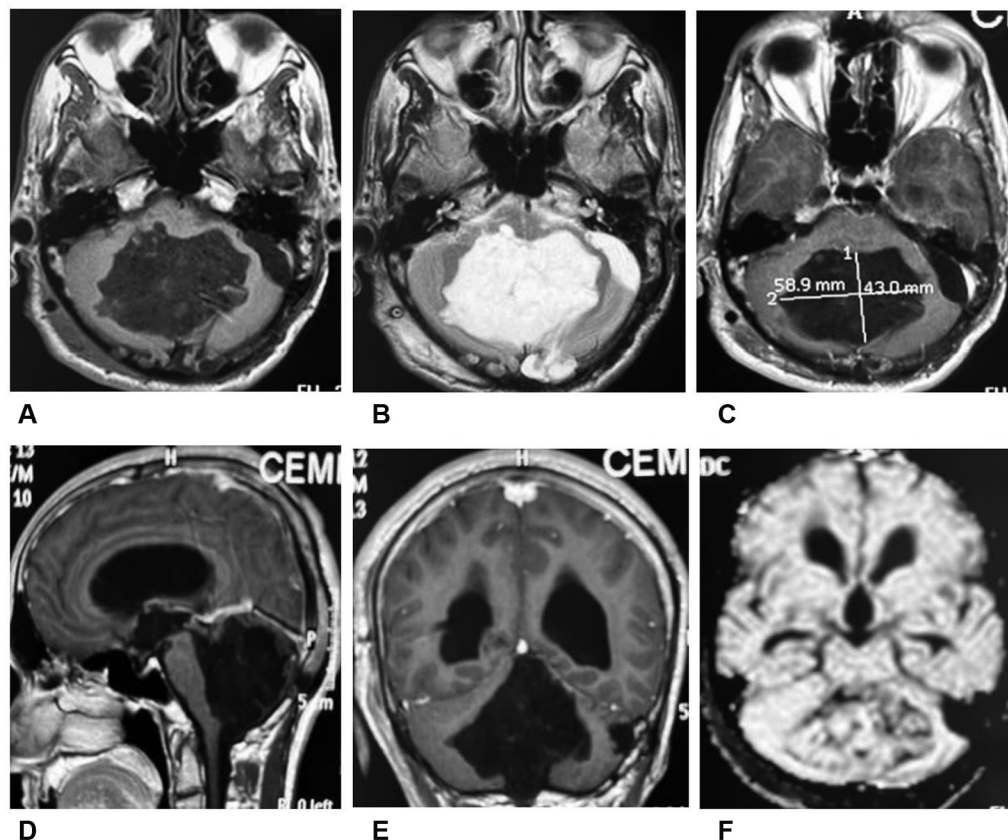


Fig. 1 (A) Magnetic resonance imaging (MRI) brain T1-weighted (T1W) axial image showing large hypointense mass lesion filling whole of fourth ventricle. (B) MRI brain T2W axial image showing large hyperintense mass. (C) MRI brain T1 contrast axial image showing no enhancement. (D) MRI brain T1 contrast sagittal image showing tumor filling whole of the fourth ventricle. (E) MRI brain T1 contrast coronal image showing tumor filling whole of the fourth ventricle and insinuating bilaterally into foramen of Luschka. (F) MRI brain with diffusion weighted imaging showing minimal diffusion restriction.

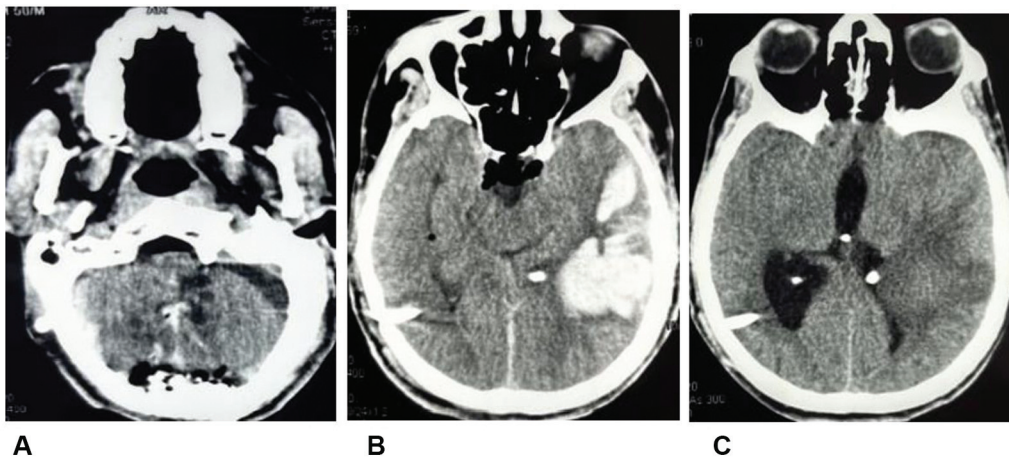


Fig. 2 Postoperative plain computed tomography brain axial image (A) showing total excision of tumor, (B) left temporal intracerebral hematoma with right-sided shunt tube in situ, and (C) resolving hematoma in left temporal region.

Table 1 Previous reported cases of supratentorial hematoma after posterior fossa surgery

Authors	Year	Age/sex	Primary pathology	Position	Approach	Site of hematoma	Hematoma diagnosis	Outcome
Haines et al ²	1978	65/F 55/F 41/F 64/F	TGN GPN Atypical TGN Anesthesia dolorosa	Sitting	RM craniectomy	(R) O (R) BG (R) FP (L) F	Within hours	Mod D Death Mod D Mild D
Cartier-Giroux et al ⁹	1980	55/F	Metastatic breast cancer	Sitting	SO craniectomy	(R) BG	Day 3	Death
Standefer et al ¹²	1984	55/NA 59/NA	Parotid cancer metastasis Meningioma	Sitting	SO craniectomy	T BG	NA Day 7	Death Death
Harder et al ⁶	1985	44/F 51/F 58/M	Meningioma Acoustic neuroma Meningioma	Sitting	SO craniectomy	(L) FP B/L FT (L) P	NA	Severe D Death Mod D
Seiler and Zurbrugg ¹⁰	1986	66/F 64/F 59/F	Acoustic neuroma Meningioma Acoustic neuroma	Lateral Sitting Sitting	SO craniectomy	(R) P (L) P (R) PO	Within hours	Severe D Death Severe D
Bucciero et al ⁵	1991	46/M	Hemangioblastoma	Sitting	So craniectomy	TP (L)	Within hours	NA
Kalkan and Eser ⁸	2006	63/F	Meningioma	Sitting	SO craniectomy	FP (R)	Within hours	NA
Tondon and Mahapatra ³	2004	34/F 50/F	Acoustic tumor Pons tumor	NA	RM craniectomy SO craniectomy	O BG		
Vrettou et al ¹⁰	2010	60/F	Hemangioblastoma	Prone	SO craniectomy	F with IVH	Within hours	Severe D
Agrawal et al ¹	2010	47/F	NA	NA	NA	T (R)	3 hours	NA
de Albuquerque et al ⁴	2015	23/F	Ependymoma	Lateral	SO craniectomy	F & P (L)	Within hours	Death
Salunke et al ¹³	2016	35/M 7/M	Acoustic neuroma Posterior fossa tumor	Lateral Prone	RM craniectomy SO craniectomy	F (L) P	12 hours Day 2	Severe D Death

Abbreviations: BG, basal ganglia; D, disability; F, frontal; GPN, glossopharyngeal neuralgia; IVH, intraventricular hemorrhage; L, left; NA, not available; O, occipital; P, parietal; R, right; RM, retromastoid; SO, suboccipital; T, temporal; TGN, trigeminal neuralgia.

hemorrhage in the cerebral parenchyma previously affected by ischemia.^{3,8} CSF drainage during posterior fossa surgery in sitting position may cause decrease in intracranial pressure and rupture of ventricular ependymal wall and intraventricular hemorrhage.⁹ Tondon and Mahapatra³ and Vrettou et al¹⁰

reported that coagulation disorder can be the cause of intracerebral hematoma at a distance from operative site. Seiler and Zurbrugg¹¹ and Standefer et al¹² had reported hypertension as a cause of supratentorial intracerebral hemorrhage following suboccipital craniectomy.

In most of the previous reports, posterior fossa surgery was performed in sitting position that is why we are doing posterior fossa surgery in prone positioning to decrease the probability of this complication. Salunke et al¹³ also suggested to perform posterior fossa surgery in prone position to decrease this type of rare complication.

Our case was operated in prone positioning, the possible mechanism for this rare complication may be the occlusion of carotid artery in the neck by improper positioning of the head, which leads to intraoperative infarction and hemorrhage in the infarcted brain after repositioning the patient. Previous cases reported by Harders et al,⁶ Vrettou et al,¹⁰ and Pandey et al¹⁴ had described this possible mechanism for this rare complication in his case operated in prone position for posterior fossa tumor. Our case is unique, as our case had neither hypertension nor coagulation disorder and the operative positioning was prone. Most of the previous studies (►Table 1) had reported this complication in sitting position and in this case it occurred in prone positioning.

On reviewing the literature, we found that the type of tumor (epidermoid cyst) and approach had no relation with this complication. Despite the rarity of this complication, it is still challenging as it may lead to significant morbidity and mortality.

Conclusion

Supratentorial intracerebral hematoma after posterior fossa surgery in prone position is a rare complication. Despite the rarity of this complication, it is still challenging as it may lead to significant morbidity and mortality. The possible mechanism for this rare complication in prone positioning may be the occlusion of carotid artery in the neck by improper positioning of the head that leads to intraoperative infarction and hemorrhage in the infarcted brain after repositioning the patient. The type of tumor and approach had no relation with this complication.

Conflict of Interest
None declared.

References

- 1 Agrawal A, Kakani A, Ray K. Extensive supratentorial hemorrhages following posterior fossa meningioma surgery. *J Surg Tech Case Rep* 2010;2(02):87–89
- 2 Haines SJ, Maroon JC, Jannetta PJ. Supratentorial intracerebral hemorrhage following posterior fossa surgery. *J Neurosurg* 1978; 49(06):881–886
- 3 Tondon A, Mahapatra AK. Supratentorial intracerebral hemorrhage following infratentorial surgery. *J Clin Neurosci* 2004;11 (07):762–765
- 4 de Albuquerque LAF, Dourado JC, Almeida JP, Costa BS. Multiple supratentorial intraparenchymal hemorrhage after posterior fossa surgery. *Surg Neurol Int* 2015;6(Suppl 2):S104–S109
- 5 Bucciero A, Quaglietta P, Vizioli L. Supratentorial intracerebral hemorrhage after posterior fossa surgery. Case report. *J Neurosurg Sci* 1991;35(04):221–224
- 6 Harders A, Gilsbach J, Weigel K. Supratentorial space occupying lesions following infratentorial surgery early diagnosis and treatment. *Acta Neurochir (Wien)* 1985;74(1-2):57–60
- 7 Hawryluk GWJ, Rubiano AM, Totten AM, et al. Guidelines for the management of severe traumatic brain injury: 2020 update of the decompressive craniectomy recommendations. *Neurosurgery* 2020;87(03):427–434
- 8 Kalkan E, Eser O. Supratentorial intracerebral haemorrhage following posterior fossa operation. *Neurol India* 2006;54(02): 220–221
- 9 Cartier-Giroux J, Mohr G, Sautreaux JL. [Supratentorial hemorrhage of hypertensive origin during operation: an unusual complication of surgery on the posterior fossa in the sitting position (author's transl)]. *Neurochirurgie* 1980;26(04):291–294
- 10 Vrettou CS, Stavrinou LC, Halikias S, et al. Factor XIII deficiency as a potential cause of supratentorial haemorrhage after posterior fossa surgery. *Acta Neurochir (Wien)* 2010;152(03):529–532
- 11 Seiler RW, Zurbrugg HR. Supratentorial intracerebral hemorrhage after posterior fossa operation. *Neurosurgery* 1986;18(04): 472–474
- 12 Standefer M, Bay JW, Trusso R. The sitting position in neurosurgery: a retrospective analysis of 488 cases. *Neurosurgery* 1984;14 (06):649–658
- 13 Salunke P, Malik V, Kovai P, Aggarwal A, Khandelwal NK. Delayed supratentorial intracerebral hemorrhage following posterior fossa surgery. *Asian J Neurosurg* 2016;11(03):315
- 14 Pandey P, Madhugiri VS, Sattur MG, Devi B I. Remote supratentorial extradural hematoma following posterior fossa surgery. *Childs Nerv Syst* 2008;24(07):851–854