



Peroral Endoscopic Myotomy (POEM) in a 19-Month-Old Girl with Primary Achalasia

Serkan Duman¹ Alper Yurci² Joo Young Cho³

¹Department of Gastroenterology, Ankara University Faculty of Medicine, Ankara, Turkey

²Department of Gastroenterology, Erciyes University Faculty of Medicine, Kayseri, Turkey

³Department of Gastroenterology, Cha University School of Medicine, Seoul, South Korea

Address for correspondence Serkan Duman, MD, Department of Gastroenterology, Ankara University Faculty of Medicine, Ankara, Turkey (e-mail: nakresnamud@hotmail.com).

J Digest Endosc 2023;14:112–114.

Abstract

Introduction Primary achalasia is an idiopathic motility disorder of the esophagus characterized by esophageal aperistalsis and incomplete relaxation of the lower esophageal sphincter (LES) in response to swallowing. The gold standard diagnostic method in adults is high-resolution manometry (HRM). Diagnostic criteria in adults are also used in children, but some HRM normal values may change depending on age.

Case Report A 15-month-old girl was admitted to the hospital for evaluation due to persistent vomiting since birth. Vomiting included what she ate regardless of the amount of food she consumed. Barium esophagography revealed barium retention, esophageal dilatation, and a “bird’s beak appearance” in the distal esophagus. Esophagogastroduodenoscopy revealed stenosis in the lower esophagus and bubbles at the esophagogastric junction.

In HRM, the resting LES pressure was 43.4 mm Hg, there was pan-esophageal pressurization with 60% of swallows and no normal peristalsis. The patient was diagnosed with type II achalasia based on the Chicago 3.0 classification.

First, the tube was inserted to ensure adequate nutrition of the patient, and approximately 4 months later, when the patient was 10 kg, the peroral endoscopic myotomy (POEM) procedure was performed.

No complications developed during and after the procedure. At the 6th month after treatment, the patient was completely asymptomatic and her weight was within normal limits for her age.

Conclusion POEM is an effective and safe method in the treatment of pediatric patients with idiopathic achalasia.

Keywords

- ▶ achalasia
- ▶ child
- ▶ pediatrics
- ▶ POEM

Introduction

Primary achalasia is an idiopathic motility disorder of the esophagus characterized by esophageal aperistalsis and incomplete relaxation of the lower esophageal sphincter (LES) with swallowing.¹ The mean incidence in adults is 0.3 to

1.63/100,000 per year, and it is rarer in children, with an annual incidence of 0.18/100,000.² The most common symptoms in children are vomiting, dysphagia, growth retardation, and weight loss.³ Diagnosis requires examinations including esophagogastroduodenoscopy (EGD), barium

article published online
June 22, 2023

DOI <https://doi.org/10.1055/s-0043-1769926>.
ISSN 0976-5042.

© 2023. The Author(s).

This is an open access article published by Thieme under the terms of the Creative Commons Attribution License, permitting unrestricted use, distribution, and reproduction so long as the original work is properly cited. (<https://creativecommons.org/licenses/by/4.0/>)

Thieme Medical and Scientific Publishers Pvt. Ltd., A-12, 2nd Floor, Sector 2, Noida-201301 UP, India

esophagram, and esophageal manometry.⁴ High-resolution manometry (HRM) is the gold standard diagnostic method in adults.⁵ Diagnostic criteria in adults are also used in children, but some normal HRM values may change depending on age.⁴ The youngest peroral endoscopic myotomy (POEM) procedure was performed on an 11-month-old boy in 2015.⁶ Our case is one of the patients who underwent POEM at the youngest age reported in the literature.

Case Presentation

A 15-month-old girl was admitted to the hospital for evaluation due to persistent vomiting since birth. The patient was formula-fed and ingested approximately 750 mL of food per day. Vomiting included what she ate regardless of the amount of food she consumed. Barium esophagography revealed barium retention, esophageal dilatation, and a “bird’s beak appearance” in the distal esophagus (►Fig. 1). EGD revealed stenosis in the lower esophagus and bubbles at the esophagogastric junction (EGJ) (►Fig. 2).

In HRM, the resting LES pressure was 43.4 mm Hg; there was pan-esophageal pressurization with 60% of swallows and no normal peristalsis. The patient was diagnosed with type II achalasia based on the Chicago 3.0 classification.

First, a 12-Fr percutan gastrostomy tube was inserted to ensure adequate nutrition of the patient, and approximately 4 months later, when the patient was 10 kg, the POEM procedure was performed.

The procedure was performed under general anesthesia and with endotracheal intubation in the operating room. For the procedure VIO-300 S electro generator (ERBE; Tübingen, Germany), CO₂ insufflator (UCR; Olympus), a standard single-channel endoscope (GIF-Q260; Olympus, Tokyo, Japan) with a transparent distal cap attachment (D-201-10704; Olympus), and coagulating forceps (Coagrasper, FD-411QR; Olympus) were used. The distance between the upper incisors and the EGJ was 27 cm. After submucosal lifting with 0.9% saline injection, the mucosal incision was made in the endocut Q

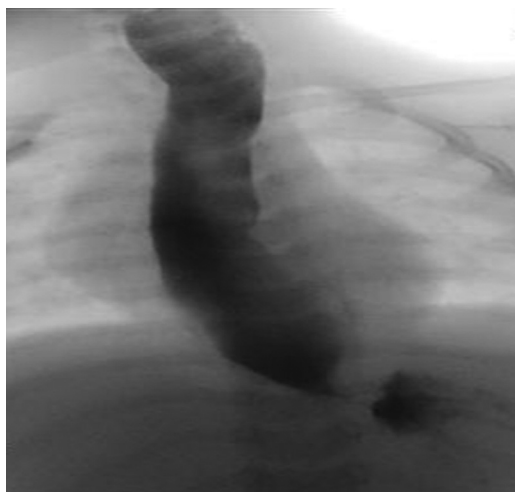


Fig. 1 Before peroral endoscopic myotomy (POEM) barium swallow test. Bird beak appearance in distal esophagus and esophageal dilatation.

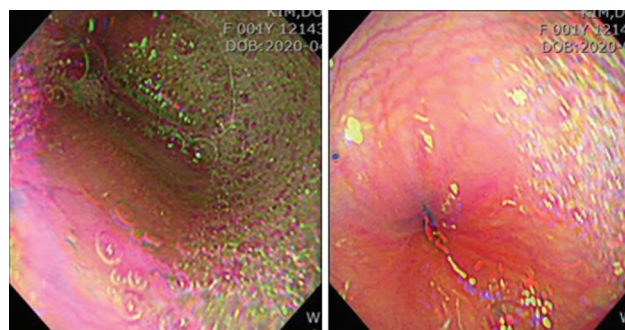


Fig. 2 Pre-peroral endoscopic myotomy (POEM) esophagogastroduodenoscopy (EGD). Pinpoint narrowing of lower esophageal sphincter (LES) with no patency difficulties and bubble was noted in esophagus.

mode (effect 3; cut duration 2; cut interval 1) with a dual knife (KD-650L; Olympus) in the 5 o'clock direction posterior to the esophagus. The submucosal tunnel was created to extend below the EGJ (30 cm below the dental line) with a dual knife in the spray coagulation mode (50 W; effect 2). Just 2 cm below the incision line, with a hook knife (KD-620LR; Olympus) up to the EGJ, a 5-cm long selective circular myotomy was performed in endocut Q mode (effect 3; cut duration 2; cut interval 1), and it was advanced 2 cm distal from the EGJ. The total myotomy length was 7 cm. We often use a triangle knife in POEM cases though we may sometimes use a hook or a dual knife due to the larger size of the tip of the triangle knife in narrow submucosal spaces, especially at the EGJ. In this case, we used a combination of a hook and a dual knife instead of a triangle knife, since the submucosal space was narrow and the esophageal muscle was thin and fragile.

Hemostatic clips (HX-610-90S; Olympus) were used for the final closure of the mucosal incision. The total procedure time was 54 minutes, and no significant complications developed during and after the procedure (►Fig. 3).

At the 6th month after treatment, the patient was completely asymptomatic and her weight was within normal limits for her age (►Fig. 4).

Discussion

All treatments for achalasia are aimed at relieving symptoms by reducing LES pressure. The best treatment option in children is unclear due to insufficient evidence. There are options such as medical treatment, pneumatic dilation, and surgery. The long-term effects of treatments such as medical, botulinum toxin injections, and endoscopic balloon dilation are limited. There has been a trend toward laparoscopic Heller myotomy (LHM) as a treatment method in the last decade.^{7,8} A newer method, POEM, has been shown to be at least as effective and reliable as LHM in adults. Although there are promising results in children, experience is limited.⁹

POEM is an endoscopic method that allows myotomy to be performed. POEM seems to be a candidate for standard treatment in achalasia because of its low complication rate and recovery time, being less invasive, and a cheaper method than LHM.^{10–14}

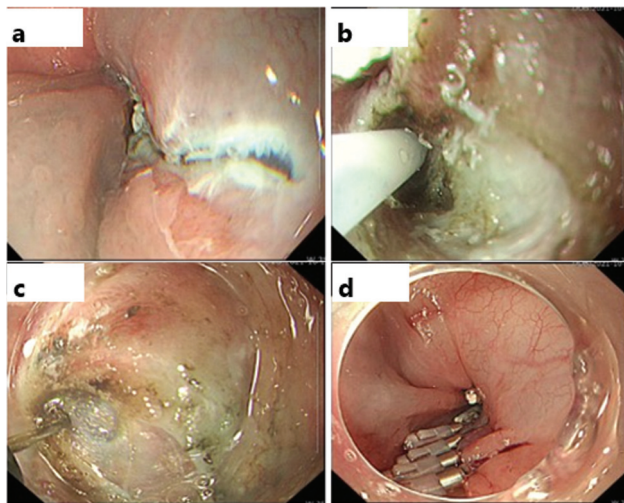


Fig. 3 Main steps of peroral endoscopic myotomy (POEM). (a) Mucosal incision at five o'clock in the middle esophagus. (b) Opening of the submucosal tunnel beyond the gastroesophageal junction. (c) Cutting only the circular muscles by performing selective myotomy. (d) Complete closure of mucosal incision.

In addition, treatment success in POEM continues for many years. In another study evaluating the retrospective results of 69 pediatric patients for at least 4 years, 95% clinical treatment success was reported.¹⁵

In our case, a child with idiopathic achalasia had been successfully treated with POEM and 6 months after the patient was at a normal weight for her age and her vomiting completely resolved.

Funding

No specific funding has been received.

Conflict of Interest

None declared.

References

- Patel DA, Kim HP, Zifodya JS, Vaezi MF. Idiopathic (primary) achalasia: a review. *Orphanet J Rare Dis* 2015;10:89
- Boeckstaens GE, Zaninotto G, Richter JE. Achalasia. *Lancet* 2014; 383(9911):83–93
- Lee CW, Kays DW, Chen MK, Islam S. Outcomes of treatment of childhood achalasia. *J Pediatr Surg* 2010;45(06):1173–1177
- van Lennep M, van Wijk MP, Omari TIM, Benninga MA, Singendonk MMJ. Clinical management of pediatric achalasia. *Expert Rev Gastroenterol Hepatol* 2018;12(04):391–404
- Vaezi MF, Pandolfino JE, Vela MF. ACG clinical guideline: diagnosis and management of achalasia. *Am J Gastroenterol* 2013;108(08): 1238–1249, quiz 1250
- Zhang XC, Li QL, Huang Y, Miao SJ, Zhou PH. Peroral endoscopic myotomy using the posterior approach in an 11-month-old girl

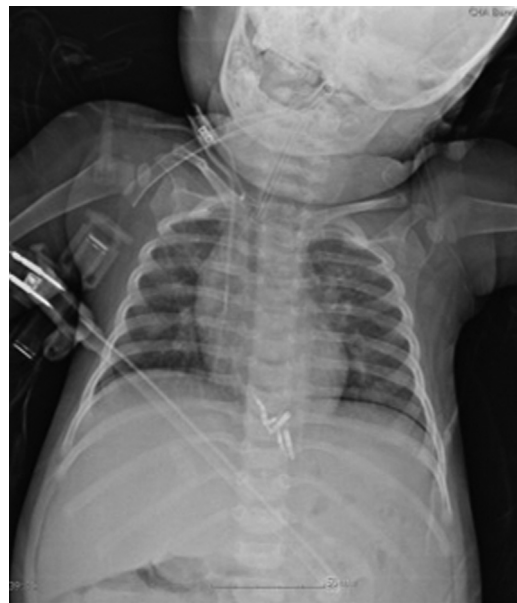

Fig. 4 X-ray imaging shows hemoclips in middle esophagus at day 0 post-peroral endoscopic myotomy (POEM).

with achalasia, severe malnutrition, and recurrent pneumonia. *Endoscopy* 2015;47(Suppl 1 UCTN):E480–E482

- Saez J, Mejia R, Pattillo JC, et al. Per oral endoscopic myotomy (POEM) in pediatric patients with esophageal achalasia: first Latin-American experience. *J Pediatr Surg* 2021;56(04):706–710
- Di Nardo G, Rossi P, Oliva S, et al. Pneumatic balloon dilation in pediatric achalasia: efficacy and factors predicting outcome at a single tertiary pediatric gastroenterology center. *Gastrointest Endosc* 2012;76(05):927–932
- Tashiro J, Petrosyan M, Kane TD. Current management of pediatric achalasia. *Transl Gastroenterol Hepatol* 2021;6:33
- Inoue H, Minami H, Kobayashi Y, et al. Peroral endoscopic myotomy (POEM) for esophageal achalasia. *Endoscopy* 2010;42 (04):265–271
- Caldaro T, Familiari P, Romeo EF, et al. Treatment of esophageal achalasia in children: today and tomorrow. *J Pediatr Surg* 2015;50 (05):726–730
- Inoue H, Kudo S-E. Per-oral endoscopic myotomy (POEM) for 43 consecutive cases of esophageal achalasia [in Japanese]. *Jpn J Clin Med* 2010;68(09):1749–1752
- Talukdar R, Inoue H, Nageshwar Reddy D. Efficacy of peroral endoscopic myotomy (POEM) in the treatment of achalasia: a systematic review and meta-analysis. *Surg Endosc* 2015;29(11): 3030–3046
- Li QL, Wu QN, Zhang XC, et al. Outcomes of per-oral endoscopic myotomy for treatment of esophageal achalasia with a median follow-up of 49 months. *Gastrointest Endosc* 2018;87(06): 1405–1412.e3
- Nabi Z, Ramchandani M, Basha J, Goud R, Darisetty S, Reddy DN. POEM is a durable treatment in children and adolescents with achalasia cardia. *Front Pediatr* 2022;10:812201