Article published online: 2023-06-26

Imaging the Ear Anatomy and Function Using Optical Coherence Tomography Vibrometry

Wei Dong, Ph.D.[1,2] and Sebastiaan W.F. Meenderink, Ph.D.[1]

ABSTRACT

Optical coherence tomography (OCT) is a novel technology for performing real-time high-speed and high-resolution cross-sectional imaging on the micro-scale in situ. It is analogous to ultrasound imaging, except that it uses light instead of sound. OCT has recently been introduced in auditory research to visualize the various structures of the ear with a minimally invasive operation. In addition, OCT can be used as a vibrometry system that is capable to detect sound-induced sub-nanometer vibrations of the middle and inner ear. OCT-vibrometry measures depth-resolved vibrations into the specimen, which overcomes several limitations of classical vibrometry techniques (e.g., single surface point measurements using laser interferometry). In this article, we illustrate how to visualize the anatomy and function of the middle and inner ear (the cochlea) in a gerbil model using recently developed spectral-domain OCT. Our results demonstrate that the largest clinical impact of OCT for otology is to visualize various pathologies and quantify sound conduction and processing in the individual peripheral human ear.

KEYWORDS: cochlea or inner ear, laser interferometer, low-frequency hearing, middle ear, optical coherence tomography

[1]VA Loma Linda Healthcare System, Loma Linda, California; [2]Department of Otolaryngology – Head and Neck Surgery, Loma Linda University Health, Loma Linda, California.

Address for correspondence: Wei Dong, Ph.D., VA Loma Linda Healthcare System, Research Service 151, 11201 Benton Street, Loma Linda, CA 92374 (e-mail: wei.dong@va.gov).

VA Rehabilitation Research for Hearing and Balance Disorders; Guest Editors, Dawn Konrad-Martin, Ph.D. and Michelle E. Hungerford, Au.D.

Semin Hear 2024;45:101–109.

Thieme Medical Publishers, Inc., 333 Seventh Avenue, 18th Floor, New York, NY 10001, USA
DOI: https://doi.org/10.1055/s-0043-1770154.
ISSN 0734-0451.

The auditory system of mammals is a marvelous achievement of biological evolution, capable of detecting and analyzing sounds over wide ranges of frequencies and intensities. Humans can hear sounds with frequencies over the range of 20 Hz to 20 kHz, and some mammals can perceive frequencies beyond 100 kHz. Mammalian auditory systems also respond to sounds over an intensity range spanning 12 orders of magnitude or 120 dB (dB). Moreover, the ear possesses great sensitivity while maintaining the ability to discriminate tonal frequencies and intensities that differ by only 0.2% and 1 dB, respectively. Such striking performance is largely determined by the peripheral hearing organ because of efficient sound transmission through the middle ear and mechanical and biophysical processing of sounds within the inner ear (i.e., the cochlea).

On the other hand, the ear is vulnerable to noise/blast overexposure. Military personnel who exhibit hearing loss and/or tinnitus suffer primarily from damage to the middle ear, inner ear, or auditory neural components (Gallun et al. 2012; Garth 1994; Spoendlin & Brun 1973), which results in either a conductive hearing loss (injuries to middle ear components) or sensorineural hearing loss (injuries to the cochlea and/or auditory neural components), respectively. Hearing impairment leads to auditory dysfunction, which reduces situational awareness by degrading sound detection threshold, localization accuracy, and speech intelligibility. This can compromise mission success, survival, and quality of life. Although middle ear damage is clinically treatable, there are still no approved treatments to cure sensorineural hearing loss. To improve therapeutics that restore our hearing, it is necessary to identify what part of the auditory pathway (middle ear, sensory, neural, synaptic, or central processing) is compromised so that appropriate treatment/intervention can be implemented.

Localizing the anatomical and functional damage along the auditory pathway is challenging. Visualizing or accessing the middle and inner ear is difficult because they are deeply embedded in the skull and are only accessible via invasive surgeries. There are imaging techniques with widespread application in medicine (i.e., ultrasound, high-resolution computed tomography (CT), and magnetic resonance imaging (MRI)). These have specific applications due to their physical properties, resolution (150 micrometer to 1 mm), and penetration range, but none of them work well to image the peripheral ear. Specifically, they cannot spatially resolve the sensory organ within the cochlea. Functional evaluation is clinically performed via noninvasive approaches (e.g., middle ear reflectance, otoacoustic emissions, audiograms). These measure a summed response along the auditory pathway, often preventing an accurate differential diagnosis of the pathology underlying hearing loss. Therefore, there is an urgent need to develop precise diagnostic tools for both structural and functional evaluation of the human ear in a clinical setting.

THE CLASSICAL APPROACH TO EAR FUNCTION: LASER INTERFEROMETRY

To explore how the peripheral ear converts sound into an informative ensemble of neural signals and understand the underlying mechanisms in normal and pathological ears, a straightforward approach is through direct measurements of sound-induced motions from these hearing components. To date, direct observations of the middle- and inner-ear mechanical responses to sound have provided the most detailed information that is available on the sound encoding of time, frequency, and intensity in the peripheral auditory system.

Various techniques have been used to explore the middle ear function and cochlear mechanics in the past (e.g., the Mössbauer technique, capacitive probes, optical levers, and video-enhanced microscopy. For an early review, see Yates & Johnstone 1979). The most popular classical technique, however, is laser interferometry. Laser interferometers are the most sensitive, linear, and reliable technique that have been applied to the auditory system since the late 1960s (Khanna 1986; Khanna Tonndorf & Wolcott 1968). There are many different forms of interferometers in present-day use, and they are commercially available (e.g., Polytec Inc.; see Cooper 1999a; de La Rochefoucauld Khanna & Olson 2005; Ren & Nuttall 2001). The laser technique, in its

simplest forms, relies on the optical interference that occurs when two beams of light (object and reference) that are of slightly different frequencies are allowed to mix on a suitable detector to produce a time-varying signal due to the Doppler effect. The fact that the object's displacement (and/or velocity) can be encoded without relying on the amplitude of the optical signal is hugely advantageous for studies of biological tissues, the reflectance of which is low (reflectivity between ~0.002 and 0.09% for the sensory epithelium within the cochlea [Khanna Willemin & Ulfendahl 1989]) and may vary with time, physiological condition, and/or position. To detect motion from a structure with such low reflectivity (i.e., the gel-like tectorial membrane, which is 97% water, has a reflectivity of 0.0001%), artificial reflectors are needed to enhance the signals (Cooper 1999b; Khanna Ulfendahl & Steele 1998). In addition, the interferometer uses a high-coherence helium-neon laser, whose red light is not optimal for penetrating the structure and records motion only from the surface under focus. Thus, this technique provides limited information on the complex three-dimensional (3D) motion of the hearing components.

Efforts have been made to introduce the laser interferometer into a clinical diagnostic tool, for example, to measure sound-induced vibration of the eardrum so to evaluate the mobility and integrity of the ossicular chain (Huber et al. 2001). Fig. 1A demonstrates how to use a laser interferometer to directly measure sound-induced vibrations of the umbo, the tip of the manubrium attaching to the eardrum (Stomackin et al. 2019). The umbo is the only location of the entire middle ear/ossicular chain that can be accessed noninvasively from the ear canal without opening the middle ear cavity. Considering the invasive surgery required to access other ossicles, the limited viewing angle of the laser interferometer, the relatively large instrumental setup, and the big inter-ear variability of middle ear function, the technique has not (yet) become established in clinical routine.

After transmission through the middle ear, sounds are further processed by the sensory hair cells within the cochlea. This is an elongated and spiraled conical structure that is part of the bony labyrinth, located in the skull's temporal bone that serves as an amplifier, a frequency analyzer, and a signal transducer. The cochlea is divided along its length by the so-called cochlear

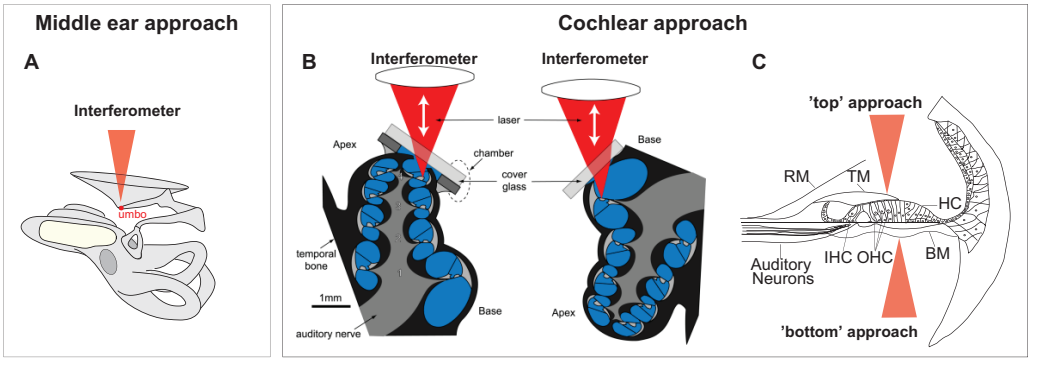

Figure 1 A schematic approach using a laser interferometer to directly measure sound-induced vibrations from ear components. (**A**) Recording of middle ear umbo motion via ear canal opening. To access other ossicles (i.e., the incus or the stapes) requires a wide opening of the middle ear cavity. Modified from Figure 1 in Stomackin et al. (2019). (**B, C**) Intracochlear motion measurements. The various structures of the cochlear partition had to be exposed after shaving a small hole into either the scala tympani (ST) of the basal turn (bottom approach) or the scala vestibuli (SV) of the apical turn of the cochlea (top approach). Some measurements were also made after tearing a small hole in the cochlea's round window membrane, without the need to remove any bone. In each case, a small glass coverslip was used to stabilize the resulting interface between the air and the cochlear fluids, hence ensuring the validity of the subsequent interferometric measurements (e.g., Cooper & Rhode 1992). The holes in the cochlea were not sealed from a hydromechanical point of view, however, and in some cases (particularly in the apical turn experiments) this may lead to experimental artifacts (e.g., Dong & Cooper 2006). BM, basilar membrane; HC, Hensen's cells; IHC, inner hair cell; OHC, outer hair cell; RM, Reissner's membrane; TM, tectorial membrane.

partition, a structure that contains the sensory epithelium with its hair cells sandwiched between the basilar (BM) and tectorial membrane. Sound enters near the cochlea's base via the stapes, and evokes a traveling wave that propagates in the longitudinal direction along the cochlear partition toward the apex. Systematic gradients of anatomical and biophysical properties along the cochlear length affect the local amplitude and propagation speed of the traveling wave and its dependence on frequency (von Békésy 1960). This creates a place-based spectral decomposition of sound, or tonotopic organization, in which high frequencies maximally excite the cochlear base and low frequencies the apex. During traveling wave propagation, the active outer hair cell (OHC) responses play a preeminent role in maintaining the cochlear high-frequency selectivity and sensitivity (Dong & Olson 2013).

To explore sound processing within the cochlea using a laser interferometer, observations have been limited to only a few locations within the cochlea, that is, at the very apical or basal sites where the cochlear partition is accessible via a small opening of the otic capsule (Fig. 1B, C; Cooper 2003; Robles & Ruggero 2001). However, these major surgeries often lead to trauma and pathological conditions (Dong & Cooper 2006; Overstreet Temchin & Ruggero 2002). As mentioned, most measurements require reflective beads to be placed onto the top surface of the cochlear partition to enhance reflectivity (Cooper 1999b). This not only makes these experiments even more challenging and prone to an artifact but also limits data collection to responses from the partition's surface. Because of these difficulties, the cochlear mechanics at the low-frequency apical region of the cochlea (Cooper & Dong 2003; Dong & Cooper 2006), essential to human speech perception, are still poorly understood. Motion has been characterized at basal sites of the cochleae of gerbils, guinea pigs, chinchillas, squirrel monkeys, and cats, but only for vibrations from the BM, which is visible through the cochlea's round window. They have provided intracochlear data on the frequency selectivity and sensitivity of high-frequency sounds (reviewed in Robles & Ruggero 2001), but how different structures of the cochlear partition work together to achieve the remarkable frequency selectivity and sensitivity is still an active field of hearing research.

To summarize, the laser interferometer has been used to study sound transmission through the middle ear components as well as responses inside the cochlea under normal and pathological conditions. These observations have yielded many significant insights on hearing, but the technique fails to probe responses from any (non-surface) structures that cannot be directly visualized. Moreover, this classical approach requires invasive surgery, which is impossible for humans. To understand the active, nonlinear mechanical processing leading to hair cell stimulation and develop better rehabilitation strategies, it is essential to provide a detailed characterization of the individual structure and its interplay with others in real time, from the same preparation and under natural conditions.

OPTICAL COHERENCE TOMOGRAPHY AND ITS APPLICATION TO HEARING RESEARCH

Optical coherence tomography (OCT) is a technique for performing real-time high-resolution cross-sectional imaging on the micron scale in situ that measures the reflectivity profile (magnitude and phase) of a light field reflected from a tissue sample as a function of depth into the specimen (Izatt & Choma 2008). Depending on the tissue properties and used wavelengths, the OCT imaging depth is a few mm, with axial and lateral resolutions that are typically in the range of 1 to 15 m and 10 to 30 m, respectively. The reflectivity profile is decomposed into its depth-resolved magnitude and phase. The magnitudes create tomographic images, where contrast is provided by small changes in the tissue's refractive index, while the phase is used for vibrometry. Following the terminology used for ultrasounds, a depth-resolved magnitude profile of the tissue sample at a fixed position of the scanning mechanism is known as an A-scan. A two-dimensional (2D) cross-section image of the tissue sample, termed a B-scan is then obtained by combining multiple A-scans while scanning the OCT optical beam across the tissue sample. Similarly, combining B-scans yields a 3D OCT volume scan of

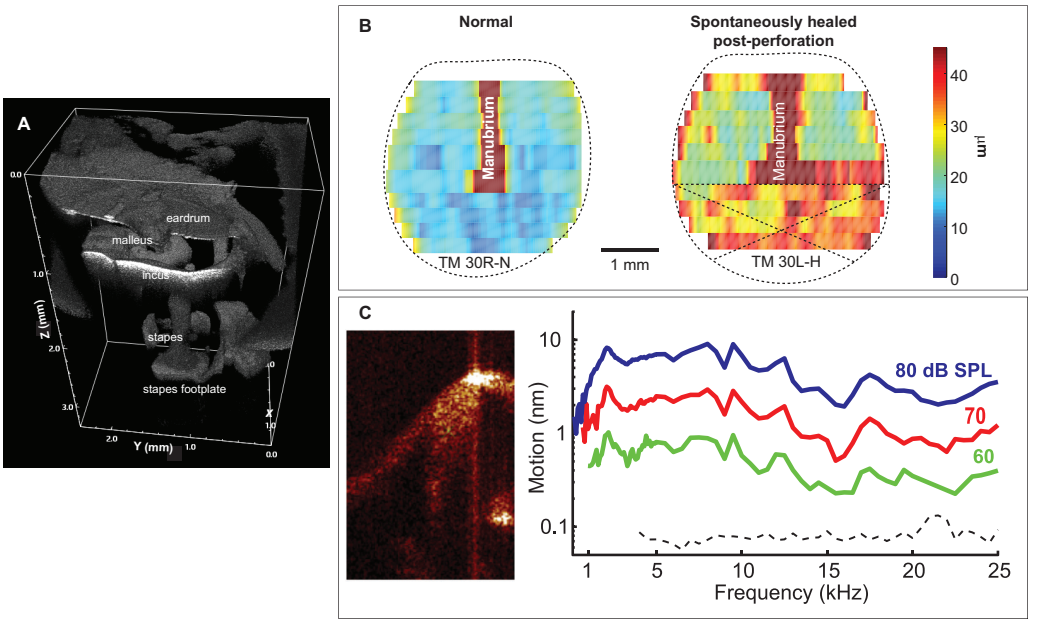

Figure 2 Viewing middle ear structure and function using optical coherence tomography (OCT). (**A**) OCT 3D volume scan of gerbil middle ear; (**B**) OCT image of the thickness of gerbil eardrums: (left) normal and (right) spontaneously healed post 4 weeks of 50% perforation of pars tensa (cross-area). (Modified from Figures 2 and 3 in Cai et al. (2019). (**C**) OCT image of the umbo (left); and sound-induced vibrations of umbo (right). Sound pressure levels were 60, 70, and 80 dB SPL. OCT image resolutions are 4.7, 4.5, and 2.4 micrometer in the X-, Y-, and Z-direction, respectively.

the sample (Fig. 2A). These scans provide excellent images in which different structures (e.g., ossicles, cochlear partition) can readily be identified.

For vibrometry, a series of OCT recordings from a single, fixed position are acquired over time. Within this time series, changes in the phase of the light field may be interpreted (assumed that the refractive index at each depth does not change) as small relative changes in position. That is, the extracted depth-resolved phase data of the light field describe motions on a sub-nanometer scale for the various structures of biological tissue. This functional imaging (vibrometry) is sometimes referred to as an M (otion)-scan.

In hearing research, the implementation of OCT uses spectral-domain interferometry (Gao et al. 2013; Gao et al. 2011; Lin Hendon & Olson 2017), in which the depth of the tissue's "reflectors" is encoded in the wavenumber (spatial frequency) of the reflected light. Here, different wavenumbers are presented either simultaneously (broadband light source) or sequentially (swept narrow wavelength band light source), which are referred to as Fourier-domain OCT and swept-source OCT, respectively. Similar to laser interferometry, OCT relies on the optical interference that occurs when an object and reference beam of light are allowed to mix. This mixed signal is recorded to create the so-called spectral interferogram (reflected light intensity vs. wavenumber). Now, a Fourier transform of this interferogram yields the aforementioned reflectivity profile that contains depth-resolved information needed for imaging and vibrometry.

Visualization of Middle Ear Structure and Function Noninvasively

Imaging of the middle ear using OCT was first proposed by Pitris et al. in 2001. Fig. 2 illustrates the application of our commercially available OCT system (Thorlabs, Telesto) that was adapted to provide an anatomical and functional evaluation of the gerbil middle ear. Unlike otoscopy or microscopy, the OCT system

generates 3D scans of the eardrum and ossicular chain quickly (<30 seconds) through the ear canal (Fig. 2A). Thus, the OCT allows us to visualize the ossicles behind the eardrum with precise anatomical information (i.e., the size, location, and condition of the ossicles) without a need for surgery or opening of the middle ear cavity. A specific application in otology is demonstrated in Fig. 2B where the OCT volume scans provide a direct readout of the thickness of the eardrum under normal and pathological conditions (Cai et al. 2019). This benefits directly the diagnosis of abnormal eardrums.

In addition, OCT-vibrometry allows us to measure sound-induced motions from the eardrum or the ossicles behind it (applicable to living humans) to evaluate how (efficient) sounds are transmitted to the cochlea. Figs. 2C shows the sound-evoked umbo vibrations. This shows that sound transmission from the eardrum to the ossicular chain is similar at all test frequencies (all-pass filter) and that it grows linearly with the intensity of the sound. The detection of the motion using OCT is down to sub-nanometers, with a noise floor in this example is around 100 pm. This illustrates the super-resolution of OCT-vibrometry in the functional evaluation of the ear. Combined structural and functional OCT measures will pinpoint the exact cause for conductive hearing loss, aiding diagnosis, recovery, and treatment options.

Visualization of Structure and Function from the Intact Cochlea In Vivo

Fig. 3 illustrates the application of OCT to the cochlea, where the remarkable frequency selectivity, sensitivity, and compression of the huge dynamic range of hearing are accomplished. Imaged through the cochlear bony wall, the inside of the gerbil cochlea is visible from the high-resolution 2D OCT images (human cochlear partition can be visualized through the round window rather than the thick cochlear bony wall using commercially available models). Not only are the different cochlear turns with the three fluid chambers (scala tympani, scala vestibuli, and scala media) discernable, the cochlear partition and the Reissner membrane are also visible (Fig. 3). We can, for the first time, also identify key structural components within the cochlear partition (outlined in Fig. 4A) under natural conditions, even though the individual cells could not be differentiated. The anatomical dimensions that we observe in vivo are consistent with studies of apical cochlear regions using fresh postmortem preparations but differed from those using classical fixed tissue represented by the histology image (Edge et al. 1998). The identification of key structures of the cochlear partition facilitates the interpretation of the mechanical function measurements.

We observed a complex pattern of vibrations that only emerged in the active cochleae of living animals (Fig. 4B), which disappeared

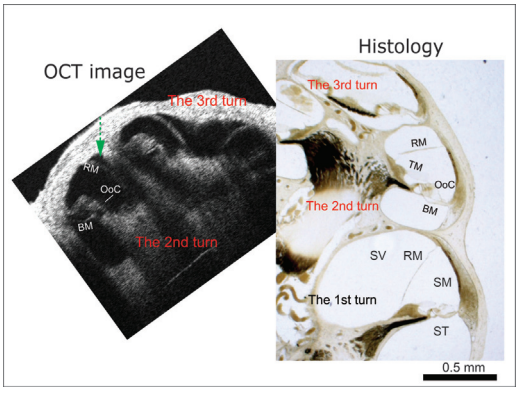

Figure 3 Two-dimensional optical coherence tomography (2D OCT) image of a cochlear cross-section through the bony wall in a living gerbil. The OCT image (left) showed different cochlear turns with three fluid chambers of scala tympani (ST), scala vestibuli (SV), and scala media (SM) separated by the cochlear partition and the Reissner membrane (RM). For comparison, an image of a histological preparation of the gerbil cochlea is shown on the right.

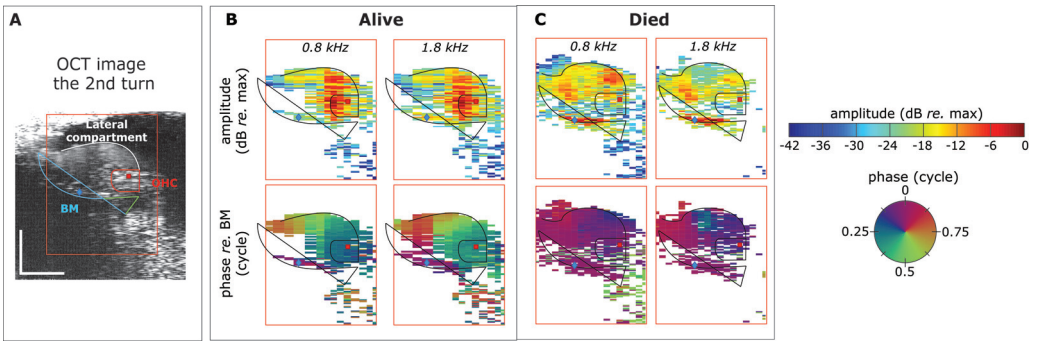

Figure 4 Two-dimensional vibration maps of the cochlear partition. (**A**) In vivo optical coherence tomography images of the cochlear partition in the second turn of the gerbil cochlea. Scale bars, 0.1 mm. The identified key structural framework of the cochlear partition is superimposed as visual guidance. BM = blue; tunnel of Corti (ToC) = green; outer hair cell (OHC) region = red; lateral compartment = white. Vibratory response maps for two stimulus frequencies were obtained at (**B** and **C**) at 50 (alive) and 80 (died) dB SPL/frequency component, respectively. In these panels, the red outline gives the region-of-interest in which the vibrations for each pixel were analyzed. Responses are shown only for pixels with a significant response. Amplitudes are normalized re. max response (from left to right: 58, 48, 78, and 26 nm) and phase is relative to BM phase (blue diamond). In living animals, the OHC region always shows the maximum vibration, and other regions moved much less. The phase transition occurred relatively abruptly and close to the BM: positions that were only 10 micrometer transversely into the organ of Corti (re. the BM) already showed this full change in phase. Specifically, the tectal cells (TC), extension connecting the reticular lamina of the top surface of the OHC, vibrated in phase with the adjacent OHC, while the vibrations of the Claudius/Hensen cells (near the BM) lagged these TCs by ~180 degrees (0.5 cycles). After the animal died, the vibration pattern was simple that all structures moved in phase and followed the motion of the BM.

after the animal died (Fig. 4C). Evoked by 50-dB SPL tones, the largest in vivo vibrations tended to occur within a "hotspot" centered at the OHC and Deiters cell region, similar to the observation from the high-frequency basal region (Cooper et al. 2018). Unique to the low-frequency region, the "hotspot" extended to the adjoining tectal cells within the lateral compartment. The other structures, including the BM, moved 10 to 20 dB less than the hotspot region in vivo. These observations strongly suggest that it was the motile OHCs that actively drove the surrounding structures to enhance the frequency selectivity and sensitivity of the traveling wave.

The underlying mechanism of how OHC motion affects the surrounding structures would be in their phase responses presented in the corresponding vibratory phase maps (bottom row in Fig. 4B, C). In living animals, different elements of the cochlear partition moved at different phases, indicating that they did not move together as a unit. Taking the BM responses as an "anchor" (i.e., setting phase BM = 0), we observed that the "hotspot" region lagged the BM response by ~0.25 cycles. After this initial transition, the phase of the responses remained almost constant within the hotspot region. The phases of vibrations in the lateral compartment of supporting cells showed systematic variation with position within the cochlear partition. The phase pattern of different key structures appeared to be invariant with frequency, intensity, which was unique to the apical low-frequency regions (Meenderink et al. 2022). The detailed documentation of the complex motion of the cochlear partition, especially from the apical cochlear regions where low-frequency sounds are decoded, directly addresses the mechanisms of human speech and sound perception in normal ears and informs the anatomy-related dysfunctions, the sensory loss, in impaired ears.

OCT APPLICATION IN OTOLOGY

OCT is a real-time imaging system that was initially applied in the clinic to the visualization of the eye (Huang et al. 1991), and to date, OCT has had the largest clinical impact in ophthalmology. The current diagnosis of many hearing problems that result in conductive or

sensorineural hearing loss, especially those requiring surgical intervention, is lengthy and costly. They require MRI or CT scans, with little to no precise functional evaluation of sound transmission. As demonstrated in Figs. 2 to 4, with extensive and specialized programming of the system, OCT can be adapted into an OCT-vibrometry that allows minimal to noninvasive approaches to the middle and inner ear to provide insights on how ear components move with sounds. It thus can be used to identify what part/degree of the peripheral auditory pathway (conductive, sensory) is compromised, evaluate surgery outcomes for repair and reconstruction promptly (even during the operations), and develop appropriate treatments/interventions. We can foresee many audiologic implications with the application of OCT in otology. For example, OCT can pinpoint middle ear disorders noninvasively through the eardrum by measuring sound-induced vibrations from individual ossicles, which helps the positioning of middle ear prosthesis to achieve better hearing restoration. The OCT can also visualize the cochlea through the bony wall to provide both structural and function evaluation that identify intracochlear disorders (e.g., endolymphatic hydrops; Badash et al. 2021). During surgery, the real-time imaging capability can be helpful in the placement/advancement of the electrode array during cochlear implantation. In addition, OCT applications are not limited to the peripheral auditory system but can be extended to other levels for auditory physiology and otology (i.e., the vascular) as well as the auditory neural system. Currently, several efforts are underway to progress OCT from a pure research technique to a routinely used clinical diagnostic tool (Matthews & Adamson 2020). Its important features in cost, ease of use, safety, and precision for both patients and clinicians will be directly beneficial to the individual objective diagnosis of hearing problems in veterans as well as civilians.

FUNDING/ACKNOWLEDGMENTS

We thank Drs. Hyle Park and Xiaohui Lin. This work was supported by VA Rehabilitation Research and Development Service Merit Award 101RX002296 and NIDCD 1R21DC019998 to W.D. These contents do not represent the views of the U.S. Department of Veterans Affairs or the U.S. government.

CONFLICT OF INTEREST

None declared.

REFERENCES

Badash I, Quiñones PM, Oghalai KJ, et al. Endolymphatic hydrops is a marker of synaptopathy following traumatic noise exposure. Front Cell Dev Biol 2021; 9:747870

Cai L, Stomackin G, Perez NM, Lin X, Jung TT, Dong W. Recovery from tympanic membrane perforation: effects on membrane thickness, auditory thresholds, and middle ear transmission. Hear Res 2019; 384:107813

Cooper NP. An improved heterodyne laser interferometer for use in studies of cochlear mechanics. J Neurosci Methods 1999a;88(01):93–102

Cooper NP. Vibration of beads placed on the basilar membrane in the basal turn of the cochlea. J Acoust Soc Am 1999b;106(06):L59–L64

Cooper NP. (2003). Compression in the peripheral auditory system. In: S.P. Bacon, R.R. Fay, & A.N. Popper (eds.), Compression from Cochlear to Cochlear Implants (Vol. 17, pp. 18–61). New York: Springer

Cooper NP, Dong W. (2003). Baseline position shifts and mechanical compression in the apical turns of the cochlea. Paper presented at the Biophysics of the cochlea from molecules to models. Titisee, Germany

Cooper NP, Vavakou A, van der Heijden M. Vibration hotspots reveal longitudinal funneling of sound-evoked motion in the mammalian cochlea. Nat Commun 2018;9:3054

de La Rochefoucauld O, Khanna SM, Olson ES. Recording depth and signal competition in heterodyne interferometry. J Acoust Soc Am 2005;117(3, Pt 1):1267–1284

Dong W, Cooper NP. An experimental study into the acousto-mechanical effects of invading the cochlea. J R Soc Interface 2006;3(09):561–571

Dong W, Olson ES. Detection of cochlear amplification and its activation. Biophys J 2013;105(04): 1067–1078

Edge RM, Evans BN, Pearce M, Richter CP, Hu X, Dallos P. Morphology of the unfixed cochlea. Hear Res 1998;124(1-2):1–16

Gallun FJ, Lewis MS, Folmer RL, et al. Implications of blast exposure for central auditory function: a review. J Rehabil Res Dev 2012;49(07):1059–1074

Gao SS, Raphael PD, Wang R, et al. In vivo vibrometry inside the apex of the mouse cochlea using spectral

domain optical coherence tomography. Biomed Opt Express 2013;4(02):230–240

Gao SS, Xia A, Yuan T, et al. Quantitative imaging of cochlear soft tissues in wild-type and hearing-impaired transgenic mice by spectral domain optical coherence tomography. Opt Express 2011;19(16): 15415–15428

Garth RJ. Blast injury of the auditory system: a review of the mechanisms and pathology. J Laryngol Otol 1994;108(11):925–929

Huang D, Swanson EA, Lin CP, et al. Optical coherence tomography. Science 1991;254(5035):1178–1181

Huber AM, Schwab C, Linder T, et al. Evaluation of eardrum laser Doppler interferometry as a diagnostic tool. Laryngoscope 2001;111(03):501–507

Izatt JA, Choma MA. (2008). Theory of Optical Coherence Tomography. Berlin, Heidelberg: Springer

Khanna SM. Homodyne interferometer for basilar membrane measurements. Hear Res 1986;23(01):9–26

Khanna SM, Tonndorf J, Wolcott WW. Laser interferometer for the measurement of sub-microscopic displacement amplitudes and their phases in small biological structures. J Acoust Soc Am 1968;44:1555–1565

Khanna SM, Ulfendahl M, Steele CR. Vibration of reflective beads placed on the basilar membrane. Hear Res 1998;116(1-2):71–85

Khanna SM, Willemin JF, Ulfendahl M. Measurement of optical reflectivity in cells of the inner ear. Acta Otolaryngol Suppl 1989;467:69–75

Lin NC, Hendon CP, Olson ES. Signal competition in optical coherence tomography and its relevance for cochlear vibrometry. J Acoust Soc Am 2017;141(01): 395

Matthews TJ, Adamson R. Optical coherence tomography: current and future clinical applications in otology. Curr Opin Otolaryngol Head Neck Surg 2020;28(05):296–301

Meenderink SWF, Lin X, Park BH, Dong W. Sound induced vibrations deform the organ of Corti complex in the low-frequency apical region of the gerbil cochlea for normal hearing : sound induced vibrations deform the organ of Corti complex. J Assoc Res Otolaryngol 2022;23(05):579–591

Overstreet EH III, Temchin AN, Ruggero MA. Basilar membrane vibrations near the round window of the gerbil cochlea. J Assoc Res Otolaryngol 2002;3(03): 351–361

Pitris C, Saunders KT, Fujimoto JG, Brezinski ME. High-resolution imaging of the middle ear with optical coherence tomography: a feasibility study. Arch Otolaryngol Head Neck Surg 2001;127(06): 637–642

Ren T, Nuttall AL. Recording depth of the heterodyne laser interferometer for cochlear vibration measurement. J Acoust Soc Am 2001;109(02):826–829

Robles L, Ruggero MA. Mechanics of the mammalian cochlea. Physiol Rev 2001;81(03):1305–1352

Spoendlin H, Brun JP. Relation of structural damage to exposure time and intensity in acoustic trauma. Acta Otolaryngol 1973;75(02):220–226

Stomackin G, Kidd S, Jung TT, Martin GK, Dong W. Effects of tympanic membrane perforation on middle ear transmission in gerbil. Hear Res 2019; 373:48–58

von Békésy G. (1960). Experiments in Hearing. New York: McGraw-Hill Book Company

Yates GK, Johnstone BM. (1979). Measurement of basilar membrane movement. In: H.A. Beagley (ed.),Auditory Investigation: The Scientific and Technological Basis. (pp. 418–430). Clarendon: Oxford