



Prevention of Fetal Anemia with Plasma Exchange and Intravenous Immunoglobulin in a Pregnancy with a Complex Anti-K and Anti-C Alloimmunization

Paola Galoppi¹ Ursula La Rocca^{2,3} Gianluca Giovannetti² Giuseppina Perrone¹ Maria Gozzer² Mahnaz Shafii Bafti² Giovanna Biondino⁴ Francesco Equitani⁵ Alessia Neri² Giovanna Savastano¹ Damiana Pompeo¹ Benedetta Lobo¹ Isabella Santilio² Federica Falco^{2,3} Adele Delli Paoli^{2,3} Roberto Brunelli¹ Serelina Coluzzi²

¹ Department of Maternal and Child Health and Urological Sciences, Sapienza University of Rome, Italy

² Department of Immunohematology and Transfusion Medicine, Sapienza University, Rome, Italy

³ Division of Haematology, Department of Translational and Precision Medicine, Sapienza University, Rome, Italy

⁴ Department of Transfusion Medicine, POS Formia, AUSL Latina, Latina, Italy

Address for correspondence: Giovanna Savastano, MD, Department of Maternal and Child Health and Urological Sciences, Sapienza University of Rome, Policlinico Umberto I Hospital, Viale del Policlinico, 155 - 00161 Rome, Italy (e-mail: giovanna.savastano@uniroma1.it).

⁵ Department of Transfusion Medicine, Santa Maria Goretti Hospital, AUSL Latina, Latina, Italy

J Fetal Med 2023;10:65–68.

Abstract

Keywords

- ▶ alloimmunization
- ▶ fetal anemia
- ▶ hemolytic disease of the fetus and newborn
- ▶ fetal therapy
- ▶ intravenous immunoglobulin
- ▶ plasma exchange

Hemolytic disease of the fetus and newborn (HDFN) remains the main cause of fetal anemia primarily due to RH-D maternal incompatibility but also to other rarer antigens. Anti-Kell mediated immunization is a rare disease involving about 0.1% of pregnant women causing a more severe HDFN compared to RH-D both for its anemia mechanism and because of lack of preventive immunoglobulin therapy. Although the standard treatment of fetal anemia is intrauterine transfusion (IUT), at early gestational age with high antibody titer and absence of ultrasound anemia signs, noninvasive strategies can be offered. We present a case of severe anti-Kell and anti-C Rh positive immunized pregnancy with high Kell titer at 14 weeks of gestation that successfully treated with plasma exchange and intravenous immunoglobulin to prevent the onset of fetal anemia and to avoid the need for IUT.

Introduction

Red cell immunization represents the most important cause of hemolytic disease of the fetus and newborn (HDFN), affecting 1/300 to 1/600 live births.¹ Rh (Rhesus) D incompatibility remains the most common cause of HDFN. The use of Rh to immunoprophylaxis, in many countries, has reduced

the incidence of HDFN under 0.1%, while alloimmunizations due to other rarer antibodies are increasing.² Anti-K HDFN occurs in about 0.1% of pregnant women with approximately 40% of mild to severe disease in live newborn.^{3,4} The anti-K immunization itself places the pregnancy at high risk despite the low antibody titer and HDFN occurs early (<20 weeks)

DOI <https://doi.org/10.1055/s-0043-1770735>.
ISSN 2348-1153.

© 2023. Society of Fetal Medicine. All rights reserved.
This is an open access article published by Thieme under the terms of the Creative Commons Attribution-NonDerivative-NonCommercial-License, permitting copying and reproduction so long as the original work is given appropriate credit. Contents may not be used for commercial purposes, or adapted, remixed, transformed or built upon. (<https://creativecommons.org/licenses/by-nc-nd/4.0/>)
Thieme Medical and Scientific Publishers Pvt. Ltd., A-12, 2nd Floor, Sector 2, Noida-201301 UP, India

with severe manifestation at onset, including hydrops. Regarding anti-C immunization, the perinatal mortality is much lower as compared to anti-D; however, severe HDFN could result from the combination of alloantibodies.⁵

High-risk pregnancies require close monitoring from the 16th week of gestation by ultrasound assessment to detect possible fetal anemia and to determine the need for intra-uterine fetal transfusion (IUT).⁶ Alternative noninvasive options have been proposed to postpone IUT, due to the related risks.

Some clinical protocols involve the use of plasma exchange (PE) and/or intravenous immunoglobulins (IVIGs).² The success of these therapies in cases of non-Rh-D is less known because of the different mechanisms of fetal damage and the lack of sufficient studies.

In this report, we discuss a case of complex anti-K and anti-C alloimmunization in a Rh positive pregnant woman successfully treated with PE and IVIG to avoid the onset of fetal anemia and the need for IUT and postnatal transfusion support.

Case Report

A 25-year-old Caucasian woman, G2, P1, without previous history of hemolytic disease, was referred to our department at 14 weeks of gestation because of suspected rare alloimmunization (blood type: A Rh positive, indirect antiglobulin test: positive). The immunohematologic evaluation included red blood cell (RBC) typing for ABO, Rh, and Kell antigens, by microplates in automated instruments (Neo-Immucor). Direct antiglobulin test (DAT) was performed with a broad spectrum antiserum by the column agglutination test (Biorad). Indirect antiglobulin test (IAT) was performed with untreated and treated (ficin/papain) autologous and homologous RBC (Ortho Clinical Diagnostics-OCD- and Biorad). The antibodies specificity was identified using O RBC extended panels (Ortho Clinical Diagnostics and Grifols). Antibodies titration, recorded as the reciprocal of the dilution, was performed by column agglutination test using O Kk CC and with O kk Cc RBC (for anti-K and anti-C titers, respectively). The desensitization strategy was based on four PE procedures for each one 1.5 volumes processed (substitution fluid: albumin), using COBE SPECTRA, to remove preformed antibodies, scheduled from 19 to 21 weeks, and weekly IVIG infusion (1 g/kg), to limit antibodies rebound, starting from week 20th of pregnancy.

Fetal ultrasound monitoring was performed from 16 weeks without detecting fetal anemia which results in middle cerebral artery (MCA) peak systolic velocity (PSV) >1.5 multiples of the median (MoM) for gestational age expressed in cm/s according to the Mari curve; the PSV of the MCA, with a starting value of 1.06 MoM at 19 weeks, was monitored every 2 weeks until 32 weeks of gestation, then weekly.

Because of the high risk of HDFN, the therapeutic first-line strategy of therapeutic plasma exchange and IVIG was shared with the patient and an informed consent was obtained.

The patient was A Rh positive, CCDee, kk; her husband was O Rh positive, ccEe, Kk. The patient decided not to perform prenatal diagnosis for personal and economic reasons. Results of the immunohematologic evaluation showed a negative DAT and a positive IAT, due to anti-K (titer 64) and anti-C (titer 1) at 14 weeks of gestation. Anti-K titer increased to 128 at 17 weeks of pregnancy, while anti-C remained stable.

The immunohematologic monitoring, performed pre and post each PE, showed anti-K reduction after the first procedure (titer from 128 to 16), followed by a mild rebound (titer 32) at 21 weeks of pregnancy, and a final stabilization (titer 64) from 24 weeks until delivery. PE was followed by weekly IVIG which continued until 28 weeks of gestation.

Fetal ultrasound surveillance did not show signs of anemia (►Fig. 1) despite the elevated anti-K titer. Cesarean section was performed at 37 weeks with the indication of nonreassuring stress test. The patient delivered a healthy female infant, weighing 3,045 g, with Apgar 9/10 and pH 7.25. The newborn was A Rh positive CcEe, Kk; DAT was positive and the elution test showed only anti-K specificity. The hemoglobin and bilirubin levels were normal without requiring a blood transfusion.

Discussion

The screening of rare antibodies is essential to identify women at risk of HDNF. In the case of positive IAT, it is needful to characterize antibodies specificity and titer. The severity of fetal anemia caused by anti-K is less predictable considering antibody titer or ultrasound signs than Rh-D sensitization.⁶ Although in literature there is no specific protocol for anti-K monitoring, a monthly immunohematologic evaluation is recommended. Moreover, there is no consensus on a critical anti-K titer predictive for HDFN.^{7,8}

In case of moderate to severe anemia (defined with a hemoglobin reduction ≥ 5 g/dL) and signs of hydrops, IUT should be performed starting from 18 weeks, because of major difficulties and high risk of complications both for fetus and mother before this period. Since the survival rates varied from 76 to 88%, with a total complication rate of 3.1%,⁹ alternative noninvasive treatment options could be applied before the 20th week. Several case reports illustrate the use of PE and IVIG for the treatment of anti-D immunization.²⁻¹⁰ PE could have an impact on plasma with possible changes in maternal pressure, coagulation factors, and electrolyte and immunoglobulin levels. Therefore, to minimize the adverse events related to the procedure it is fundamental to evaluate each patient's hemodynamic and coagulation status.¹¹ The PETIT study demonstrated the positive effect of IVIG in pregnancies at high risk for severe hemolytic disease (the majority anti-D) to postpone HDFN compared to no treatment.¹²

In our report, despite the absence of a previous history of hemolytic disease, K-immunization represents itself, as the major risk to develop HDNF because of its rarity and lack of evidence about this condition and considering the early onset of fetal anemia and the severity of clinical signs,

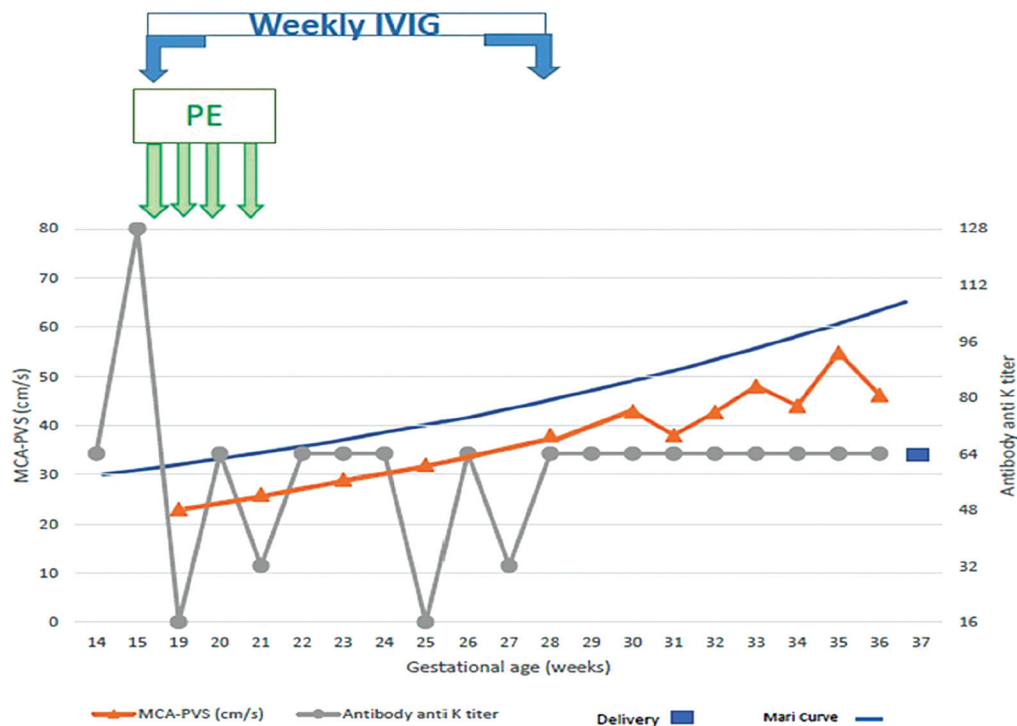


Fig. 1 Graphic representation of changes in maternal anti-K titers and fetal MCA-PSV in relation to PE and IVIG. Fetal ultrasound surveillance did not show anemia and MCA-PSV values referred to the Mari curve. MCA, middle cerebral artery; PSV, peak systolic velocity; IVIG, intravenous immunoglobulin; PE, plasma exchange.

regardless of antibody titer.⁶ For the above-mentioned reasons, we preferred combined strategy of PE and IVIG to avoid risky IUT after abnormal evidence of MCA PSV. We began PE and IVIG before 20 weeks, with continuous and careful monitoring of fetal ultrasound Doppler. Due to the possible rebound of antibody, PE was associated with IVIG, which cross the placenta and compete with the maternal alloantibodies in the fetal reticuloendothelial system, saturating protective receptors, and replacing the IgG pool removed by PE.¹³ IUT is considered standard treatment in fetal anemia although limited by the invasivity and potential risks. However, progress in noninvasive methods may render PE with IVIG a more attractive approach in early pregnancy and in high-risk conditions.

Few data are available regarding the optimal time to the delivery. In case of mild fetal hemolysis, it is recommended a delivery at 37 to 38 weeks. We may affirm that in our case the close multidisciplinary surveillance and the noninvasive therapeutic options allowed us to avoid fetal anemia and to overcome the prematurity with good perinatal and maternal outcomes.

Implications for Clinical Practice

PE and IVIG have been employed in various antibody-mediated autoimmune diseases, showing successful results as compared with PE or IVIG alone. In the near future, new drugs, such as M281, a monoclonal antibody capable of competitively binding with high affinity IGFcRn sites of the fetal monocyte-macrophage cells, inhibiting the transfer of

IG from the maternal to the fetal circle will become available.¹⁴ It must be considered a global decrease in the availability of IG due to a wide range of indications, leading to some difficulties in drug procurement. Therefore, shared protocols between transfusion medicine, obstetrics, neonatology, and hospital pharmacy are essential.¹⁵

Prospective randomized controlled studies would be required, nevertheless considering the rarity of the disease the experience of single cases or cases series is still useful to improve our knowledge. In conclusion, our data showed that in selected cases of rare alloimmunization in pregnancy, early PE procedures combined with IVIG may represent a valuable therapeutic and preventive option.

Patient Consent

Informed consent was obtained from the patient regarding the data.

Authors' Contributions

G.P., S.C., U.L.R.: conception and design of the study.
G.G., M.G., M.F.B.: acquisition of data.
G.S., D.P., B.L., F.F.: drafting the article.
P.G., R.B., G.P., S.C.: final approval of the version to be submitted.

Funding

none.

Conflict of Interest

None declared.

References

- 1 Karafin MS, Westlake M, Hauser RG, et al; NHLBI Recipient Epidemiology and Donor Evaluation Study-III (REDS-III) Risk factors for red blood cell alloimmunization in the Recipient Epidemiology and Donor Evaluation Study (REDS-III) database. *Br J Haematol* 2018;181(05):672–681
- 2 Fernández Alba JJ, León R, González-Macías C, et al. Treatment of D alloimmunization in pregnancy with plasmapheresis and intravenous immune globulin: case report. *Transfus Apheresis Sci* 2014;51(01):70–72
- 3 Grant SR, Kilby MD, Meer L, Weaver JB, Gabra GS, Whittle MJ. The outcome of pregnancy in Kell alloimmunisation. *BJOG* 2000;107(04):481–485
- 4 Bowman JM, Pollock JM, Manning FA, Harman CR, Menticoglou S. Maternal Kell blood group alloimmunization. *Obstet Gynecol* 1992;79(02):239–244
- 5 Hackney DN, Knudtson EJ, Rossi KQ, Krugh D, O’Shaughnessy RW. Management of pregnancies complicated by anti-c isoimmunization. *Obstet Gynecol* 2004;103(01):24–30
- 6 ACOG Practice Bulletin No. 192: management of alloimmunization during pregnancy. *Obstet Gynecol* 2018;131(03):e82–e90
- 7 Ghesquière L, Garabedian C, Coulon C, et al. Management of red blood cell alloimmunization in pregnancy. *J Gynecol Obstet Hum Reprod* 2018;47(05):197–204
- 8 Koumoutsea EV, Gabowski MW, Seaward G, et al. Is there a role for titre monitoring in Kell alloimmunized pregnancies. *Blood* 2019;134(01):er74–er1177
- 9 Lindenburg IT, van Kamp IL, van Zwet EW, Middeldorp JM, Klumper FJ, Oepkes D. Increased perinatal loss after intrauterine transfusion for alloimmune anaemia before 20 weeks of gestation. *BJOG* 2013;120(07):847–852
- 10 Nwogu LC, Moise KJ Jr, Klein KL, Tint H, Castillo B, Bai Y. Successful management of severe red blood cell alloimmunization in pregnancy with a combination of therapeutic plasma exchange, intravenous immune globulin, and intrauterine transfusion. *Transfusion* 2018;58(03):677–684
- 11 Wind M, Gaasbeek AGA, Oosten LEM, et al. Therapeutic plasma exchange in pregnancy: a literature review. *Eur J Obstet Gynecol Reprod Biol* 2021;260(260):29–36
- 12 Zwiers C, van der Bom JG, van Kamp IL, et al. Postponing early intrauterine transfusion with intravenous immunoglobulin treatment; the PETIT study on severe hemolytic disease of the fetus and newborn. *Am J Obstet Gynecol* 2018;219(03):291.e1–291.e9
- 13 Ruma MS, Moise KJ Jr, Kim E, et al. Combined plasmapheresis and intravenous immune globulin for the treatment of severe maternal red cell alloimmunization. *Am J Obstet Gynecol* 2007;196(02):138.e1–138.e6
- 14 Castleman JS, Moise KJ Jr, Kilby MD. Medical therapy to attenuate fetal anaemia in severe maternal red cell alloimmunisation. *Br J Haematol* 2021;192(03):425–432
- 15 Perrone G, Brunelli R, Marcoccia E, et al. Therapeutic apheresis in pregnancy: three differential indications with positive maternal and fetal outcome. *Ther Apher Dial* 2016;20(06):677–685