



Complete Remission of Cutaneous Metastasis from Invasive Breast Cancer with Abemaciclib plus Letrozole

Shaunak N. Valame¹ Dhruti D. Manek²

¹ Department of Medical Oncology, Jawaharlal Nehru Cancer Hospital and Research Centre, Bhopal, Madhya Pradesh, India

² Department of Pathology, CARE Pathology, Bhopal, Madhya Pradesh, India

Address for correspondence Shaunak Valame, DNB, Department of Medical Oncology, Jawaharlal Nehru Cancer Hospital and Research Centre, Cancer Hospital Road, Idgah Hills, Bhopal, 462001 Madhya Pradesh, India (e-mail: shaunak_valame@hotmail.com; manek.dhruti89@gmail.com).

Ind J Med Paediatr Oncol 2024;45:83–86.

Abstract

Keywords

- breast neoplasms
- cyclin-dependent kinase inhibitor proteins
- remission induction

Skin metastases from internal malignancies can be the first clinical finding of cancer recurrence. If presentation is delayed, they may ulcerate and develop secondary infection. Through this case, we will highlight a case of breast cancer recurrence with extensive cutaneous metastases that clinically completely responded to oral systemic therapy, thereby obviating the need for chemotherapy and leading to stark improvement in performance status and quality of life.

Introduction

Skin metastases from primary internal malignancies are uncommon, with an incidence of 0.6 to 10.4% of all patients with cancer.^{1,2} However, it can be the first clinical finding of cancer recurrence. The most common sites of cutaneous involvement from breast carcinoma are the chest wall and the abdomen.³ Other organs may have already been affected by the time skin lesions are identified.⁴ Here we discuss a patient whose breast carcinoma recurred after 14 years with disfiguring chest and abdominal wall metastases and the exceptional therapeutic response.

Case Report

A 58-year-old postmenopausal woman, teacher by occupation, is a known case of carcinoma of the left breast treated with breast conservation surgery in 2008. Histopathology showed invasive breast carcinoma pT2N1. Immunohistochemistry (IHC) was positive for estrogen receptor (ER) and progesterone receptor (PR) but negative for Her2neu. She had received six cycles of adjuvant chemotherapy

(fluorouracil, epirubicin, and cyclophosphamide) followed by adjuvant radiotherapy. She had completed 5 years of tamoxifen till 2014 and was on routine follow-ups till 2019. She presented in May 2022 with complaints of pustular discharge from a lesion on the left chest wall and left side of the abdomen for 3 months and chest pain for 6 months. She had also noticed heaviness in the right breast and nodular lesions developing over the skin of the right breast and sternum since the past 1 year.

At presentation, her Eastern Cooperative Oncology Group (ECOG) performance status (PS) was 3. General physical examination revealed a 6 × 5 cm fungating left breast lesion with foul-smelling sanguinopurulent discharge, a 2 × 3 cm fungating lesion on anterior abdominal wall below the xiphisternum, multiple nodular lesions over skin of the right breast (► **Fig. 1A, B**), and a 3 × 4 cm lump in the right breast upper outer quadrant. Biopsy from the right breast skin lesion and the left chest wall lesions were suggestive of invasive breast carcinoma. IHC of the right breast skin lesion showed ER 7/8, PR 6/8, and negative Her2neu, while that of the left chest wall lesion was ER 5/8, PR 6/8, and negative Her2neu. Fluorodeoxyglucose positron

article published online
September 18, 2023

DOI <https://doi.org/10.1055/s-0043-1771046>.
ISSN 0971-5851.

© 2023. The Author(s).

This is an open access article published by Thieme under the terms of the Creative Commons Attribution License, permitting unrestricted use, distribution, and reproduction so long as the original work is properly cited. (<https://creativecommons.org/licenses/by/4.0/>)

Thieme Medical and Scientific Publishers Pvt. Ltd., A-12, 2nd Floor, Sector 2, Noida-201301 UP, India

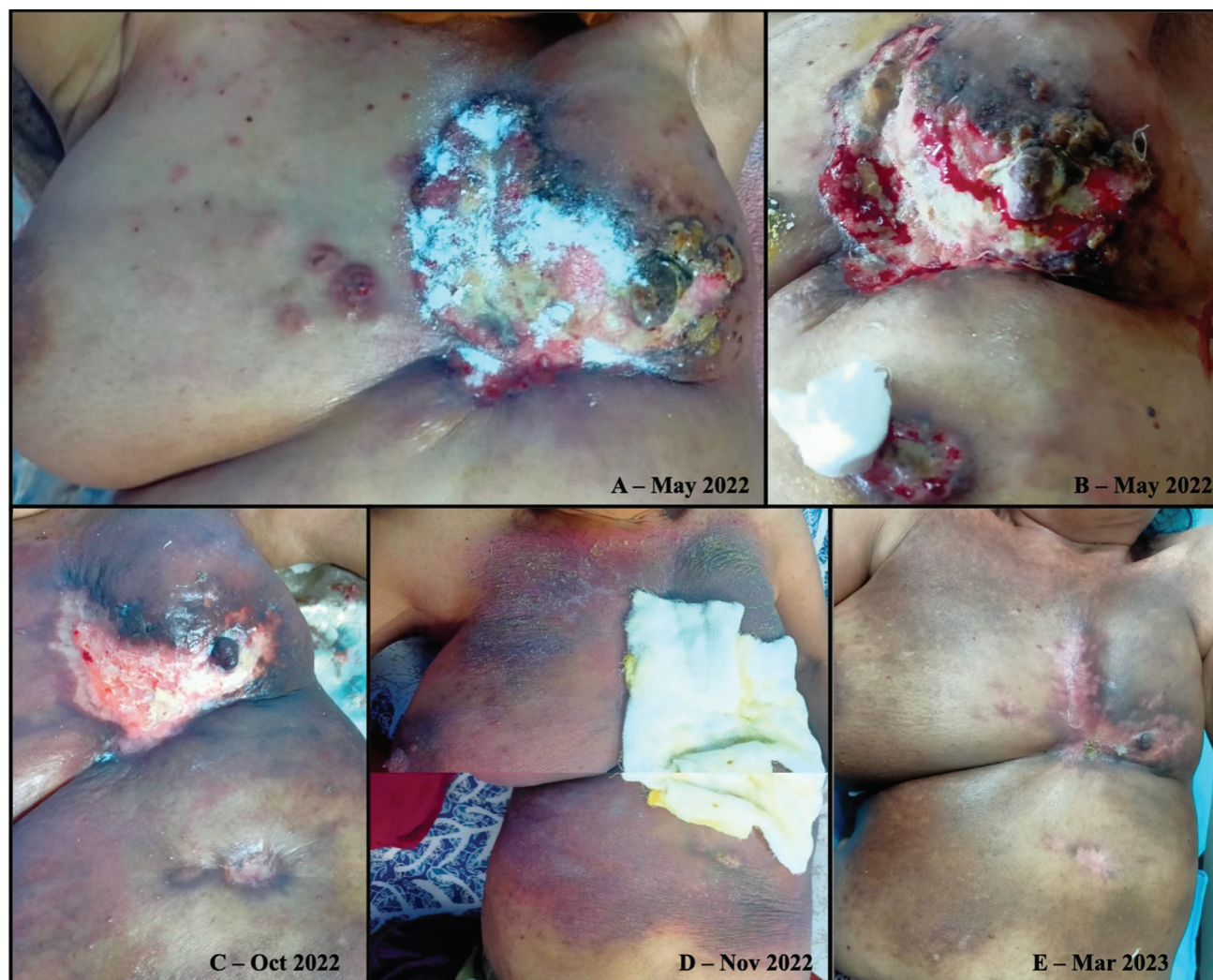

Fig. 1 (A,B) Chest wall and abdominal skin lesions prior to initiation of abemaciclib + letrozole (May 2022) and (C-E) its regression with treatment to date.

emission tomography computed tomography (FDG PET CT; ► **Fig. 2A, C**) revealed a 3.3×3.6 cm left breast upper inner quadrant mass infiltrating the overlying skin with ulceration (maximum standardized uptake value [SUVmax] 11.24), multiple cutaneous deposits below the xiphisternum, largest 3.9×6.0 cm (SUVmax 12.02), right breast lesion 4.1×3.7 cm (SUVmax 11.87), right axillary lymph node 2.5×2.2 cm (SUVmax 9.43), right anterior diaphragmatic lymph nodes 2.8×3.2 cm (SUVmax 5.27), periportal lymph node 1.5×2.6 cm (SUVmax 8.27), lytic lesion in the manubrium and the body of the sternum with soft-tissue component 3.1×5.1 cm (SUVmax 7.63), multiple subpleural and parenchymal lung lesions (SUVmax 5.98), and an FDG avid lesion (SUVmax 4.47) in segment IVB of the liver without associated CT changes. Blood panel for renal and hepatic functions were adequate. Thus, she was diagnosed as metastatic hormone receptor positive breast cancer without visceral crisis.

She was started on abemaciclib 150 mg twice daily + letrozole 2.5 mg once daily in June 2022 along with bisphosphonate and calcium support. Aerobic culture of the pustular discharge showed *Proteus vulgaris* and *Klebsiella*

pneumoniae, which were treated as per the sensitivity profile using piperacillin + tazobactam intravenous (IV), and amikacin IV for 7 days. Daily dressing and cleansing of the pustular discharge were done with povidone-iodine solution. The discharge receded, along with the foul smell, by the end of 1 month of therapy. By October 2022, the abdominal wall and left chest wall lesions (► **Fig. 1C**) showed healing with reduction in size. FDG PET CT (► **Fig. 2B, D**) reassessment showed complete metabolic response of all previously viable lesions. Complete morphologic resolution was observed in the left and right breast lesions, cutaneous deposits, lymphadenopathy, skeletal lesions, and pleural deposits. She developed a rash associated with pruritis over the right chest wall, which was managed conservatively, but by November 2022 (► **Fig. 1D**) it had not resolved. Thus, dose reduction of abemaciclib to 100 mg twice daily was done. The rash and pruritis responded to the dose reduction. Treatment was continued without interruptions. She had two episodes of grade 2 neutropenia in December 2022 and January 2023, and grade 2 diarrhea in February 2023. By March 2023 (► **Fig. 1E**), her skin lesions had shown complete

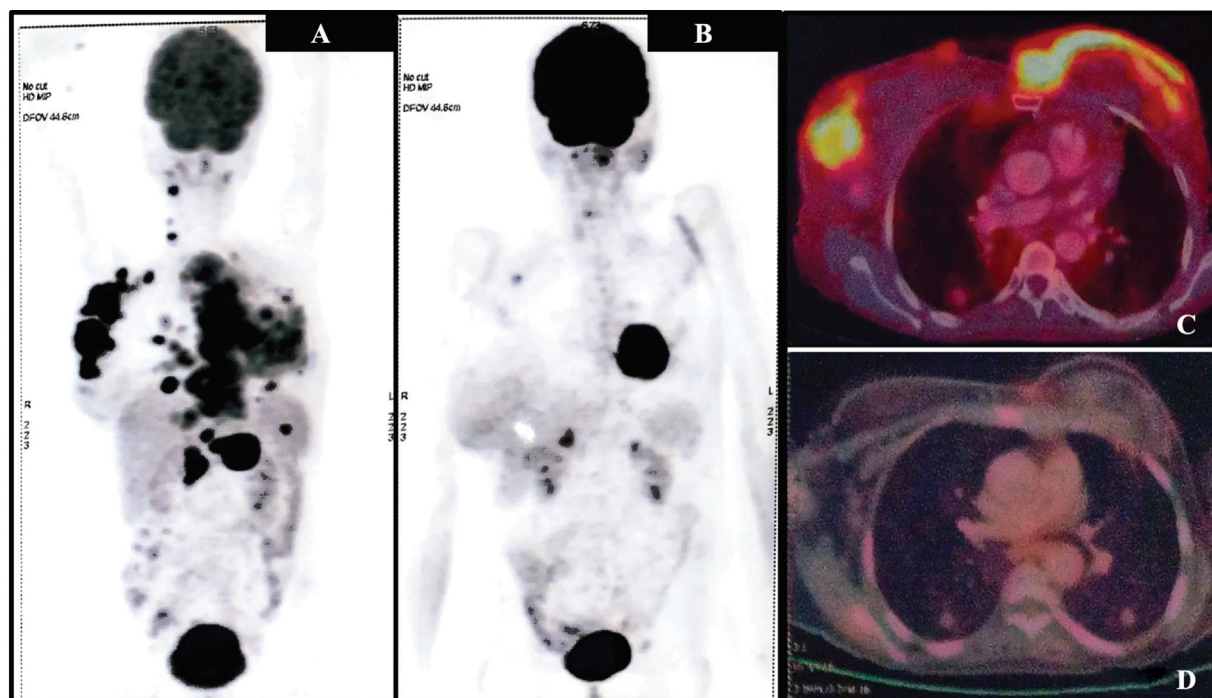


Fig. 2 Positron emission tomography (PET) at (A,C) baseline (May 2022) and (B,D) after completion of 5 months of therapy (October 2022).

clinical response, with improvement in ECOG PS to 1. As of her last visit in June 2023, she continues to be on abemaciclib 100 mg twice daily plus letrozole 2.5 mg/d.

Discussion

Cutaneous metastases from breast carcinoma occur in 23.9% of patients as per the largest reported series.² Nodules are the most common clinical presentation, ranging from 1 to 3 cm in size, firm consistency, solitary or multiple, and located in dermis or subcutaneous tissue.⁵ Nodules are generally asymptomatic but may ulcerate and develop secondary infection.⁶ Our patient initially developed skin nodules 1 year prior to her presentation. They gradually progressed leading to large ulceration with pustular discharge.

The decision to start with endocrine therapy (ET) + CDK4/6 inhibitors (CDK4/6i) was based on multiple factors. First, although skin is the largest bodily organ, extensive cutaneous metastasis is not considered a defining event of visceral crisis as per the ABC5 guidelines.⁷ ET + CDK4/6i is the preferred option for hormone-receptor-positive advanced breast cancer in the absence of visceral crisis. Our patient had visceral metastasis in the liver and lungs, but there was no organ dysfunction. Second, the use of chemotherapy, for rapid efficacy may have been a prudent option as well, before switching eventually to ET + CDK4/6i, but the concurrent secondary infection was concerning. It took 8 to 10 weeks for the skin lesions to show reduction in size, although the pustular discharge was resolving by the end of 1 month of therapy. Third, among the three available CDK4/6i, abemaciclib causes the least neutropenia,⁸ keeping in mind the concurrent skin infection. Fourth, our patient has an endocrine-sensitive

disease, which usually indicates a favorable prognosis with this combination therapy. In the authors' region of practice, accessibility to CDK4/6i is dependent on the eligible patient's out-of-pocket expenditure. With availability of generic options, an increasing number of patients are reaping the benefit of these molecules. A detailed counseling regarding these options goes a long way in helping the patient choose the most suitable modality of treatment.

Overall, cutaneous metastases portend a poor prognosis with a median survival of 6.5 months. The median survival of patients of primary breast cancer presenting with cutaneous metastases is 13.8 months.⁹ Data for overall survival in the era of CDK4/6i are, however, lacking. Our patient has completed 12 months of treatment (as of June 2023) and she showed a steady regression. It does remain to be seen how long it sustains. With her disease predominantly involving skin rather than viscera, it would be interesting to see her progression-free survival in comparison to the MONARCH3 data.¹⁰

The improvement in our patients' quality of life (QoL) from ECOG PS 3 to 1 cannot be understated. At presentation, she was unable to sleep due to frequent awakenings related to pain. Her decubitus for sleeping was on her knees bent forward. Due to the skin fungation and odor, her social activities had been severely compromised. With stark improvement due to therapy, she has currently resumed her teaching activities, socializing with friends and family, and has an uninterrupted sleep. Rash was observed in 15.3% of cases in MONARCH3,¹⁰ but only three cases were of grade 3. For our patient, it responded to dose reduction of abemaciclib. The grade 2 diarrhea and neutropenia she experienced did not have a major detrimental impact on her QoL.

However, patients must be counseled to seek medical attention at the earliest new symptom onset. Our patient had a delayed presentation as she was aware that skin lesions could be a sign of cancer recurrence but did not want to undergo chemotherapy and experience its adverse events once again. The utility of CDK4/6i in obviating the need for chemotherapy is also one of its advantages.

Conclusion

Thus, our case report shows that CDK4/6i and ET have an important role to play in cutaneous metastasis of advanced breast cancer. To our knowledge, this is the first report of cutaneous metastasis showing complete metabolic and clinical response to CDK4/6i + ET.

Patient's Consent

Patient's consent was obtained to use her clinical images and PET scan images during publishing of this Case Report.

Contribution by Authors

Shaunak N. Valame was responsible for identifying the appropriate patient for treatment, counselling of patient, treatment protocols, starting of treatment and follow-ups, and providing the necessary data for compiling the article. Dhruti D. Manek contributed to reviewing the reports, literature search, and manuscript preparation and editing. The manuscript has been read and approved by both the authors.

Funding

None.

Conflict of Interest

None declared.

Acknowledgments

The authors would like to thank our patient and her family for giving support and permission for publishing her case.

References

- 1 Schwartz RA. Cutaneous metastatic disease. *J Am Acad Dermatol* 1995;33(2, Pt 1):161–182, quiz 183–186
- 2 Lookingbill DP, Spangler N, Helm KF. Cutaneous metastases in patients with metastatic carcinoma: a retrospective study of 4020 patients. *J Am Acad Dermatol* 1993;29(2, Pt 1):228–236
- 3 De Giorgi V, Grazzini M, Alfaioli B, et al. Cutaneous manifestations of breast carcinoma. *Dermatol Ther* 2010;23(06):581–589
- 4 Hussein MR. Skin metastasis: a pathologist's perspective. *J Cutan Pathol* 2010;37(09):e1–e20
- 5 Pipkin CA, Lio PA. Cutaneous manifestations of internal malignancies: an overview. *Dermatol Clin* 2008;26(01):1–15, vii
- 6 Alcaraz I, Cerroni L, Rütten A, Kutzner H, Requena L. Cutaneous metastases from internal malignancies: a clinicopathologic and immunohistochemical review. *Am J Dermatopathol* 2012;34(04):347–393
- 7 Cardoso F, Paluch-Shimon S, Senkus E, et al. 5th ESO-ESMO international consensus guidelines for advanced breast cancer (ABC 5). *Ann Oncol* 2020;31(12):1623–1649
- 8 Roncato R, Angelini J, Pani A, et al. CDK4/6 inhibitors in breast cancer treatment: potential interactions with drug, gene, and pathophysiological conditions. *Int J Mol Sci* 2020;21(17):6350
- 9 Schoenlaub P, Sarraux A, Grosshans E, Heid E, Cribier B. Survival after cutaneous metastasis: a study of 200 cases. *Ann Dermatol Venereol* 2001;128(12):1310–1315
- 10 Johnston S, Martin M, Di Leo A, et al. MONARCH 3 final PFS: a randomized study of abemaciclib as initial therapy for advanced breast cancer. *NPJ Breast Cancer* 2019;5:5