



H3 K27M-Altered Diffuse Midline Gliomas: A Review

Karol Wiśniewski^{1,2} Andrew Ghaly¹ Kate Drummond^{1,3}  Andreas Fahlström^{1,4} 

¹Department of Neurosurgery, Royal Melbourne Hospital, Melbourne, Australia

²Department of Neurosurgery and Neurooncology, Medical University of Łódź, Łódź, Poland

³Department of Surgery, Royal Melbourne Hospital, University of Melbourne, Melbourne, Australia

Address for correspondence Kate Drummond, MD, FRACS, Department of Neurosurgery, Royal Melbourne Hospital, Melbourne, Victoria 3051, Australia (e-mail: kate.drummond@mh.org.au).

⁴Department of Medical Sciences, Section of Neurosurgery, Uppsala University, Uppsala, Sweden

Indian J Neurosurg 2023;12:104–115.

Abstract

Diffuse midline glioma H3 K27M-altered is a recently renamed high-grade glioma in the 2021 World Health Organization (WHO) Classification of Central Nervous System Tumors, previously being labelled diffuse midline glioma H3 K27M-mutant in the 2016 update and diffuse intrinsic pontine glioma prior to 2016. After identification of multiple alterations causing H3 K27 hypomethylation, the definition of this tumor subtype was changed. To further characterize this new entity in both the pediatric and adult population, we conducted a review of the current literature, investigating genetic, epidemiological, clinical, radiological, histopathological, treatment and prognostic characteristics, particularly highlighting the differences between adults and children. This tumor is more common in children, and has a poorer prognosis. Additionally, childhood H3 K27-altered gliomas are more common in the brainstem, but more common in the thalamus in adults. Sadly, limited treatment options exist for these tumors, with radiotherapy the only treatment shown to improve overall survival.

Keywords

- ▶ diffuse midline glioma
- ▶ H3.1 or H3.2 K27-mutant
- ▶ H3-wildtype with EZHIP overexpression
- ▶ *EGFR*-mutant
- ▶ H3.3 K27-mutant

Introduction

H3 K27M-altered diffuse midline gliomas (DMG) are a rare primary central nervous system (CNS) glioma subtype. This tumor was previously known, in children, as diffuse intrinsic pontine glioma (DIPG).¹ However, genetic analysis showed that 80% of DIPG harbored an H3 K27 mutation associated with poor prognosis. Analysis of a wider cohort of tumors for this mutation expanded the classification in the World Health Organization (WHO) 2016 Update of Classification of Tumours of the CNS.² In 2021, the WHO created a specific group of pediatric-type diffuse high-grade gliomas. The group consists of four tumors (DMG, H3 K27-altered; diffuse hemispheric glioma, H3 G34-mutant; diffuse pediatric-type high-grade glioma, H3-wildtype and

IDH [isocitrate dehydrogenase]-wildtype; infant-type hemispheric glioma) that differ molecularly and prognostically (▶ **Table 1**). DMG H3 K27-altered may also occur in the adult population.³

We review the features of DMG H3 K27-altered in the adult and pediatric populations and compare their genetic, epidemiological, clinical, radiological, histopathological, treatment, and prognostic characteristics.

Methodology

We conducted a PubMed search up to July 31, 2022 using the terms “diffuse midline glioma” and “H3 K27M” that returned 110 articles. We excluded articles without or with incomplete abstracts, books and documents, conference

article published online
July 26, 2023

DOI <https://doi.org/10.1055/s-0043-1771192>.
ISSN 2277-954X.

© 2023. The Author(s).

This is an open access article published by Thieme under the terms of the Creative Commons Attribution License, permitting unrestricted use, distribution, and reproduction so long as the original work is properly cited. (<https://creativecommons.org/licenses/by/4.0/>)

Thieme Medical and Scientific Publishers Pvt. Ltd., A-12, 2nd Floor, Sector 2, Noida-201301 UP, India

Table 1 Subtype definitions for pediatric-type high-grade glioma

Pediatric-type high-grade glioma subtypes
DMG H3K27-altered An infiltrative midline glioma with loss of H3 p.K28me3 (K27me3) and either an H3 c.83A > T p.K28M (K27M) substitution in one of the histone H3 isoforms, aberrant overexpression of EZHIP, or an <i>EGFR</i> mutation (CNS WHO grade 4)
Diffuse hemispheric glioma H3G34-mutant Malignant IDH-wildtype glioma with a G34R/V mutation in H3F3A, and located in the cerebral hemispheres
Diffuse pediatric-type high-grade glioma, H3-wildtype and IDH wildtype High-grade glioma predominantly located in the hemispheres, both IDH and H3-wildtype
Infant type hemispheric glioma High-grade glioma predominantly found within the cerebral hemispheres of infants, with mutations in ROS, ALK, MET, and NTRK receptor tyrosine kinases

Abbreviations: ALK, anaplastic lymphoma kinase; CNS, central nervous system; DMG, diffuse midline glioma; EGFR, epidermal growth factor receptor gene; EZHIP, enhancer of zest homolog inhibitory protein; ROS, proto-oncogene tyrosine protein kinase; MET, mesenchymal epithelial transition; NTRK, nonreceptor proto-oncogene tyrosine protein kinase; WHO, World Health Organization.

abstracts, letters, editorials, comments, published errata, case reports, and retracted articles. Only articles in English were considered. The search was supplemented by reviewing the article reference lists (►Fig. 1). Overall, 96 articles were included in the study (as one of 97 articles originally identified was retracted). There has been an increase in the number of articles related to this tumor type published per year over the previous decade (►Fig. 2).¹⁻⁹⁶ Although a systematic review was attempted, the data was not, ultimately, appropriate for meta-analysis and therefore a rigorous integrative qualitative/narrative review was undertaken.

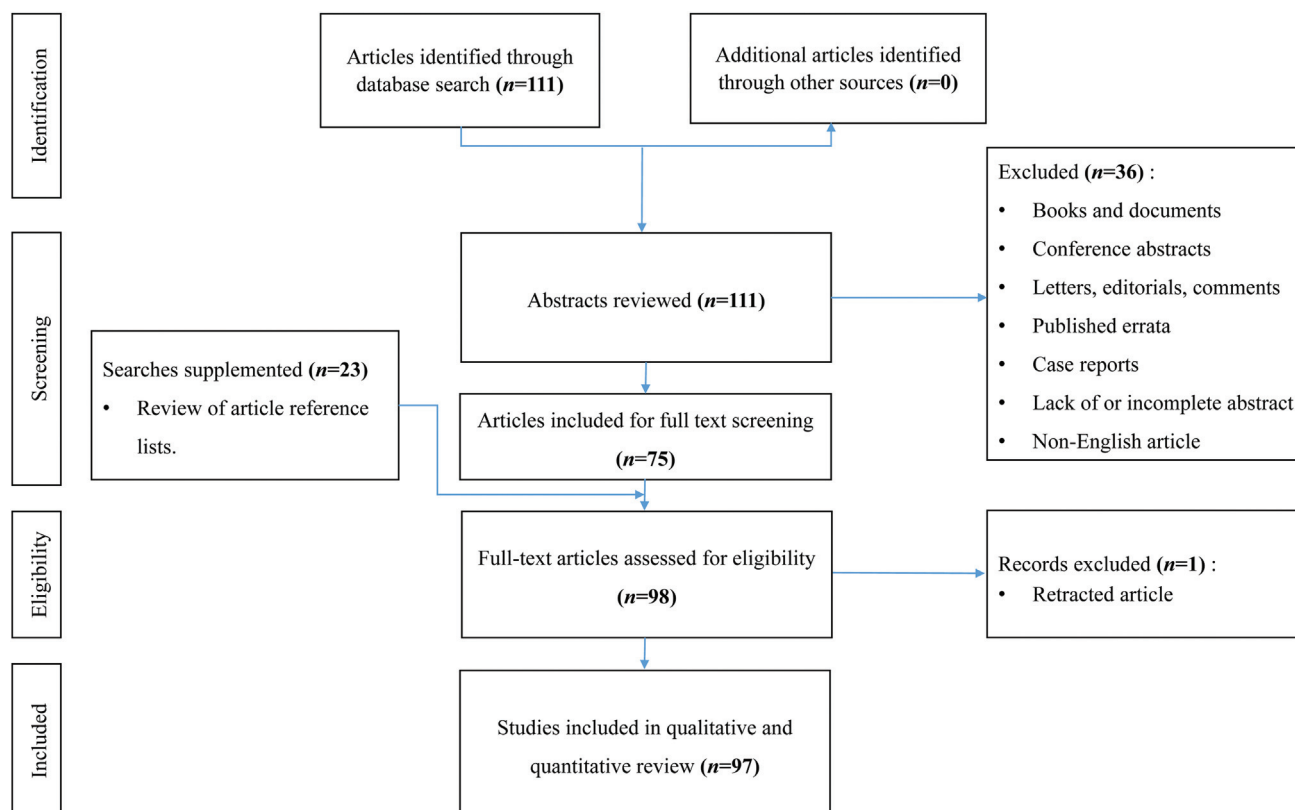
Definition and Classification

H3 K27M-Mutant Diffuse Midline Glioma

In 2016, the WHO created a new tumor subtype, DMG H3 K27M-mutant, a diagnostic entity based on its epigenetic signature.¹ The WHO criteria for diagnosis of DMG H3 K27M-mutant are described in ►Table 2.

H3 K27-Altered Diffuse Midline Glioma

Subsequently, in 2021, the WHO amended this classification to DMG H3 K27-altered to encompass the varying mechanisms that can lead to the epigenetic alteration

**Fig. 1** Flow diagram presenting study selection in the review.

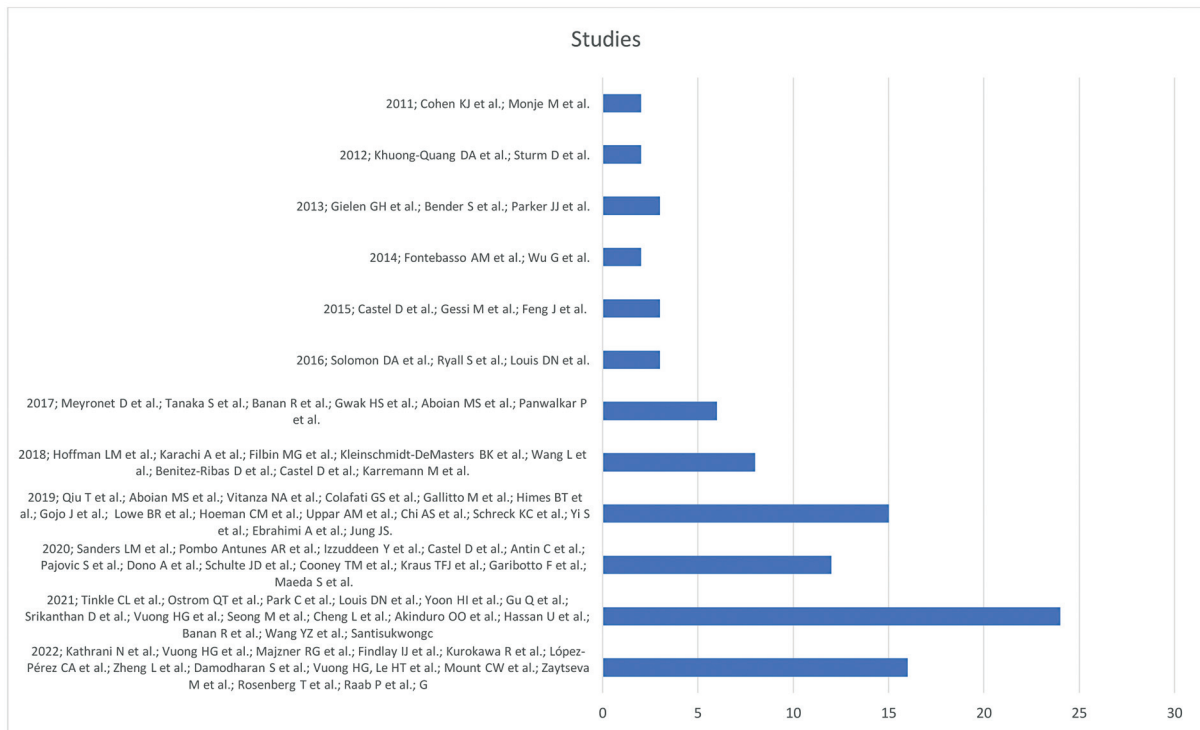


Fig. 2 Graphic presentation of the studies included in the review by year, showing the growth in publications in recent years.

Table 2 2016 WHO classification criteria for DMG H3 K27M-mutant

DMG H3 K27M-mutant DMG criteria
Infiltrative glioma and Located in the midline and Loss of H3 K27me3 and K27M mutation (immunohistochemistry) in either H3F3A or HIST1H3B/C
Results from molecular analysis are desirable

Abbreviations: DMG, diffuse midline glioma; WHO, World Health Organization.

characteristic of this tumor type^{21,50} and based on these molecular changes distinguished four subtypes of DMG H3 K27-altered (→ **Table 3**)⁷⁶:

- DMG, H3.3 K27-mutant,
- DMG, H3.1 or H3.2 K27-mutant,
- DMG, H3-wildtype with EZHIP overexpression,
- DMG, *EGFR*-mutant.

Genetic Characteristics and Cell of Origin

The molecular profile of DMG H3 K27-altered is still under investigation. The timing of H3 K27M mutation in children and the effect on embryonic, neonatal, and childhood brain development have not been characterized.⁴² In addition, the

relationship between spinal cord DMG and supratentorial DMG regarding genetic alterations is also not clear, but spinal cord high-grade glioma in children and adults frequently harbors H3 K27M mutations.⁶⁶

In a 2018 study by Castel et al, investigating the epigenetic profile of H3 K27M-mutant tumors in a group of 215 children with pediatric high grade gliomas, it was found that subtypes of H3 K27M-mutant tumors were more accurately differentiated based on their methylation profile and gene expression, rather than their location, particularly when comparing supra- and infratentorial tumors. This may suggest these subtypes arise from a different precursor or epigenetic reorganization.⁷⁵ Up to now, there is no conclusive evidence regarding the cell of origin for these tumors, but a few studies suggest an oligodendrocyte precursor cell, due to the strong immunophenotypic resemblance of the tumor cells to oligodendrocytes and the temporal and spatial relationship of tumor incidence to the expression of the precursor cells in neural development.⁹⁵ This was later supported in a study by Filbin et al in 2018, who also found that, compared to IDH-mutant gliomas, H3 K27M-mutant gliomas are largely composed of cells resembling oligodendrocyte precursor cells.⁷¹ They also reported that H3 K27M-mutant gliomas had a large component of highly undifferentiated cells with high proliferative index, consistent with their aggressive behavior compared to IDH-mutant glioma.⁷¹

DMG H3 K27M-mutants are characterized by a somatic gain of function mutation that leads to a lysine 27 to methionine (p.lys27Met: K27M) substitution in histone 3 (H3) variants.⁹² The K27 residue is essential for all variants of the H3 histone, as methylation of K27 has an inhibitory effect

Table 3 20121 WHO classification criteria for DMG H3 K27-altered

DMG H3 K27-altered criteria
Infiltrative glioma and Loss of H3 p.K28me3 (K27me3) (immunohistochemistry) and Located in the midline and one of below H3 p.K28M (K27M) or p.K28I (K27I) mutation (for H3 K27–mutant subtypes) or Pathogenic mutation or amplification of <i>EGFR</i> (for the <i>EGFR</i> -mutant subtype) or Overexpression of <i>EZH1P</i> (for the H3-wildtype with <i>EZH1P</i> overexpression subtype) or Methylation profile of one of the subtypes of DMG
Results from the molecular analysis that enable discrimination of the H3.1 or H3.2 p.K28 (K27)-mutant subtype from the H3.3 p.K28 (K27)-mutant subtype are desirable.

Abbreviations: DMG, diffuse midline glioma; EGFR, epidermal growth factor receptor gene; EZHIP, enhancer of zest homolog inhibitory protein; WHO, World Health Organization.

on gene transcription. Thus, H3 affects gene expression with a wide influence on cellular differentiation, proliferation, and epigenetic regulation.⁶¹ The H3 K27M mutation, causing reduced H3 K27 trimethylation, affects stability of genetic transcription, inhibiting cellular differentiation while conversely promoting proliferation, with overexpression of genes that promote gliomagenesis.⁶¹

This K27M substitution affects histone variants H3.1 and H3.3 and results from mutations to the HIST1HH3B/C or H3F3A gene, with the H3F3A gene being most commonly affected.⁶¹ H3.1K27M tumors are also associated with mutations in the ACVR1 (Activin A receptor type 1), while H3.3K27M gliomas are associated with a gain of function mutation of PDGFRA (platelet-derived growth factor receptor alpha) and loss of function p53 mutations. Interestingly, up to one-third of DMG H3 K27M-mutant have ACVR1 mutations. Alteration of function of this receptor induces hyperactive bone morphogenic protein (BMP) signaling, which arrests oligodendrocyte differentiation and is potentially tumorigenic. In H3 K27M-mutant mouse models, mice with additional ACVR1 mutations survive only 70 days compared to those without, which have an average survival of 180 days.^{62,87}

H3 K27 hypomethylation is not necessarily due to K27M mutation.⁴⁵ In 2020, Castel et al, described a subgroup of DMG with EZHIP (enhancer of zest homolog inhibitory protein) overexpression and H3 K27 trimethylation loss, in the absence of a H3 K27M-mutation, in a cohort of 10 patients with diffuse pontine glioma.⁴⁵ This has subsequently been confirmed by other groups.⁴⁶ EZHIP binds to PRC 2 (polycomb repressive methyltransferase complex 2) through the EZH2 subunit. PRC2 is the complex responsible for modifying the lysine residue on histone 3, resulting in methylation of the H3 protein to HK27me3. By binding to PRC2, EZHIP leads to a reduction in HK27me3. H3 K27me3 hypomethylation leads to driver mutations that contribute to oncogene activation through gene expression alteration.⁶ These genetic alterations include, as mentioned

above, TP53 loss, associated with radiotherapy resistance, tumor immortality and self-renewal of neural stem cells,^{6,82} and gain of function of PDGFR, associated with tumor cell proliferation, invasion, and migration.⁹⁰ Finally, a subset of DMG H3 K27M-mutant has been associated with amplification or pathogenic mutation of the EGFR (epidermal growth factor receptor) and overexpression of EGFR is associated with aggressive behavior and migration.⁹¹ Conversely, prognosis is improved in those DMG H3 K27M-mutant tumor subtypes with RAS-MAPK pathway alterations, such as FGFR1 (fibroblast growth factor receptor).⁴⁷ Additional genetic alterations described in these tumors involve PPM1D (protein phosphatase, Mg²⁺/Mn²⁺ dependent 1D, MYC proto-oncogene transcription factor family, NF1 (neurofibromin 1), ATRX (α -thalassemia mental retardation X-linked protein), CDK (cyclin dependent kinase)4/CDK6, and CCND (cyclin) 1-3.^{6,88,92,93}

The prognosis of DMG H3 K27M-altered varies between the pediatric and adult population and some genomic differences are noted between the two populations. The H3.3 K27M mutation rate in adults is significantly higher than in children.^{8,65,73,82} However, H3.1 mutant DMG occur more often in the young.^{15,38} Molecular profiling reveals higher frequencies of ATRX loss and H3.3 mutation in adult than in pediatric H3 K27M-mutant DMG and loss of ATRX expression has been associated with improved survival.^{49,63} TERT (telomerase reverse transcriptase) promoter mutations and MGMT (O⁶-methylguanine DNA methyltransferase) promoter methylation is not detected in children,⁸ but are present in a few adult patients. Loss of ATRX expression is observed mainly in adult patients. TERT promoter mutations and MGMT promoter methylation are present in up to 50% of IDH WT (wildtype)/H3-WT gliomas,¹ in opposition to H3 K27M-mutant DMG, where TERT promoter mutations occur in 0 to 10% and MGMT is usually not methylated.^{8,77} Similar to children, adults with H3 K27M-mutant tumors harbor TP53 and FGFR1 mutations. To a large extent, however, the molecular profile of DMG H3 K27M-altered

tumors in adults is similar to that in children and the key to novel treatments of these tumors is likely to be the development of epigenetic modulators (► **Table 4**).^{48,77,86} Tumor diagnosis and monitoring using “liquid biopsy” to detect DMG H3K27-altered mutations in cell-free DNA (cfDNA) in cerebrospinal fluid (CSF) or blood is a promising alternative to biopsy of highly eloquent regions such as the brainstem. Ventricular CSF is more reliable than lumbar CSF samples.¹²

Epidemiology

Our epidemiological understanding of DMG H3 K27M-altered DMG is still incomplete as the entity was only described in 2021.⁷ This tumor is more common in children than in adults, but the mechanism for the pediatric predilection is unclear (► **Table 4**). Some studies have suggested that children are three times more likely than adults to have mutations in their H3F3A or HIST1HB gene.⁷⁷

Of midline pediatric primary brain tumors, 80% are H3 K27M-altered, and they comprise 75% of all pediatric brainstem tumors.^{9,19,49} However, DMG constitute only 10 to 15% of pediatric brain tumors overall and the prevalence of DMG is estimated at 0.54 cases per 1 million person-years.^{69,83} DMG comprise only 3 to 5% of adult primary brain tumors.^{25,55}

Anatomical Location

DMG H3 K27-altered are almost exclusively located in midline CNS structures. In adults, the most common location is the thalamus, but the brainstem, cerebellum, corpus callosum, hypothalamus, cerebral hemispheres, and spinal cord have also been reported.⁵⁴ In children, brainstem tumors predominate (► **Table 4**)⁸¹ chiefly in the pons (51.9%), then in the thalamus/basal ganglia (36.5%) and spine (9.6%).¹⁵ This is in contrast to non-H3 K27-altered tumors that are more widely distributed in children (31.3%

thalamus/basal ganglia, 31.3% spinal cord, 12.5% pons, 12.5% midbrain/tegmentum, 12.5% other intracranial locations).¹⁵ No difference in location has been found for H3.1 and H3.3 molecular subgroups.¹⁵ For spinal cord DMG H3 K27-altered, H3 K27M-mutated tumors have a greater propensity for the thoracic spine, but there is no difference in location between mutated and wildtype tumors.⁶⁸

Clinical Presentation

Clinical Features of Cranial DMG H3 K27-Altered

The clinical presentation of DMG H3 K27-altered correlates with location. Focal neurological deficits, hemiparesis, ataxia and cranial nerve palsies, account for more than 50% of presentations.⁴⁸ In patients who present with cranial nerve palsies, cranial nerves VI and VII are most commonly affected, but cranial nerves III, IV, and X have also been reported.⁵⁷ Symptoms of raised intracranial pressure are not common, although impaired level of consciousness is reported.⁴⁸ Interestingly, hydrocephalus at first presentation occurs in less than 10% of patients with DMG H3 K27-altered. In children, ataxia and cranial nerve palsies are frequent modes of presentation.²⁴ Symptomatic intratumoral hemorrhage is rare, occurring in up to 6% of patients, and generally only symptomatic in the pediatric population.^{16,48} In contrast to other brainstem gliomas, DMG H3 K27-altered typically present with an acute course of months and in both adults and children, with an average duration of symptoms of 2 to 3 months (► **Table 4**).^{24,40}

Clinical Features of Spinal Cord DMG H3 K27-Altered

In spinal cord DMG H3 K27-altered, the clinical presentation is generally nonspecific, and varies with the spinal level. Local pain generally precedes the development of neurological signs and symptoms, which most commonly comprise ataxia, sphincter dysfunction, and limb weakness.³¹

Table 4 Comparison of DMG H3 K27-altered in children and adults

	Children	Adults
Prevalence	0.54 cases per 1 million person-years	3–5% of adult primary brain tumors
Location	Primarily brainstem	Primarily thalamus, also brainstem, cerebellum, corpus callosum, hypothalamus, cerebral hemispheres, spinal cord
Clinical presentation	Ataxia, cranial nerve palsies, developmental regression	Focal neurological deficits, hemiparesis, ataxia and cranial nerve palsies
Radiological features	Nonspecific	Nonspecific
Histopathology features	No significant differences	No significant differences
Mutation in H3F3A or HIST1HB gene	More frequently	Less frequently
Mainstay of treatment	Radiotherapy	Radiotherapy
Prognosis	Median survival 9 to 15 months	Median survival 8–27.6 months

Abbreviation: DMG, diffuse midline gliomas.

Radiological Characteristics

Radiological Features of Cranial DMG H3 K27-Altered

DMG H3 K27-altered in both adults and children have similar radiological features, but no pathognomonic or unique imaging characteristics have been described when compared to other cranial gliomas apart from location (–Figs. 3 and 4, –Table 4).⁸¹ On T1-weighted magnetic resonance imaging (MRI), these tumors are hypointense and enhanced with contrast with a diffuse or heterogenous pattern. On T2-weighted MRI, they have heterogenous signal intensity.⁵⁴ Contrast enhancement may be patchy, nodular, cystic, homogenous or ring-like, and rarely absent.^{49,54,65} Extensive spread can occur craniocaudally to involve the cerebral hemispheres and spinal cord, and there may be leptomeningeal spread. Cortical invasion and leptomeningeal tumor spread are usually related to normal expression of ATRX.²⁶ Other MRI findings include peritumoral edema, diffusion restriction, and hemorrhage, with peritumoral edema most common.³⁰ However, no studies have identified imaging features able to differentiate DMG H3 K27M-altered and other high-grade gliomas.⁸¹

On diffusion-weighted imaging (DWI), DMG usually do not, or only mildly, restrict and this is correlated with the presence of the H3K27M-mutation. Differences between H3 K27M-mutant and wildtype DMG have been noted. DWI and MRI perfusion-weighted imaging may be useful

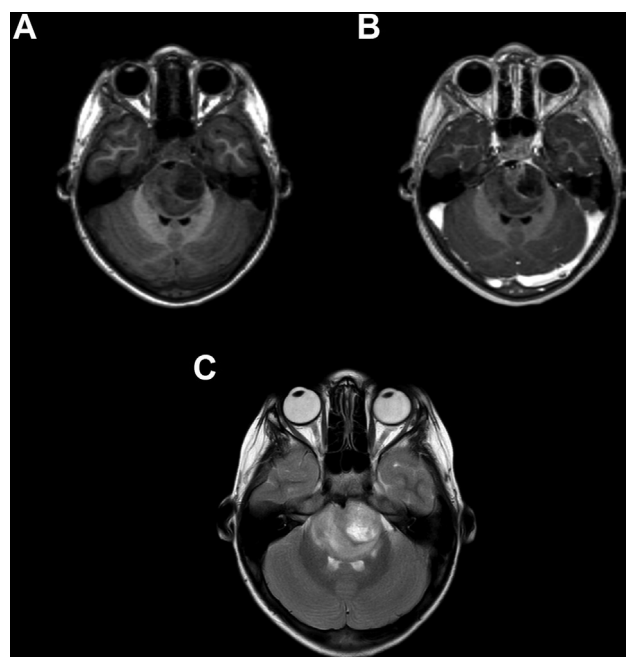


Fig. 3 Magnetic resonance imaging (MRI) of pediatric brainstem diffuse midline glioma (DMG)-H3 K27M-altered. (A) T1-weighted MRI. The tumor is hypointense. (B) T1-weighted contrast-enhanced MRI. There is minimal and heterogeneous enhancement. (C) T2-weighted MRI. The tumor is heterogeneously hyperintense.

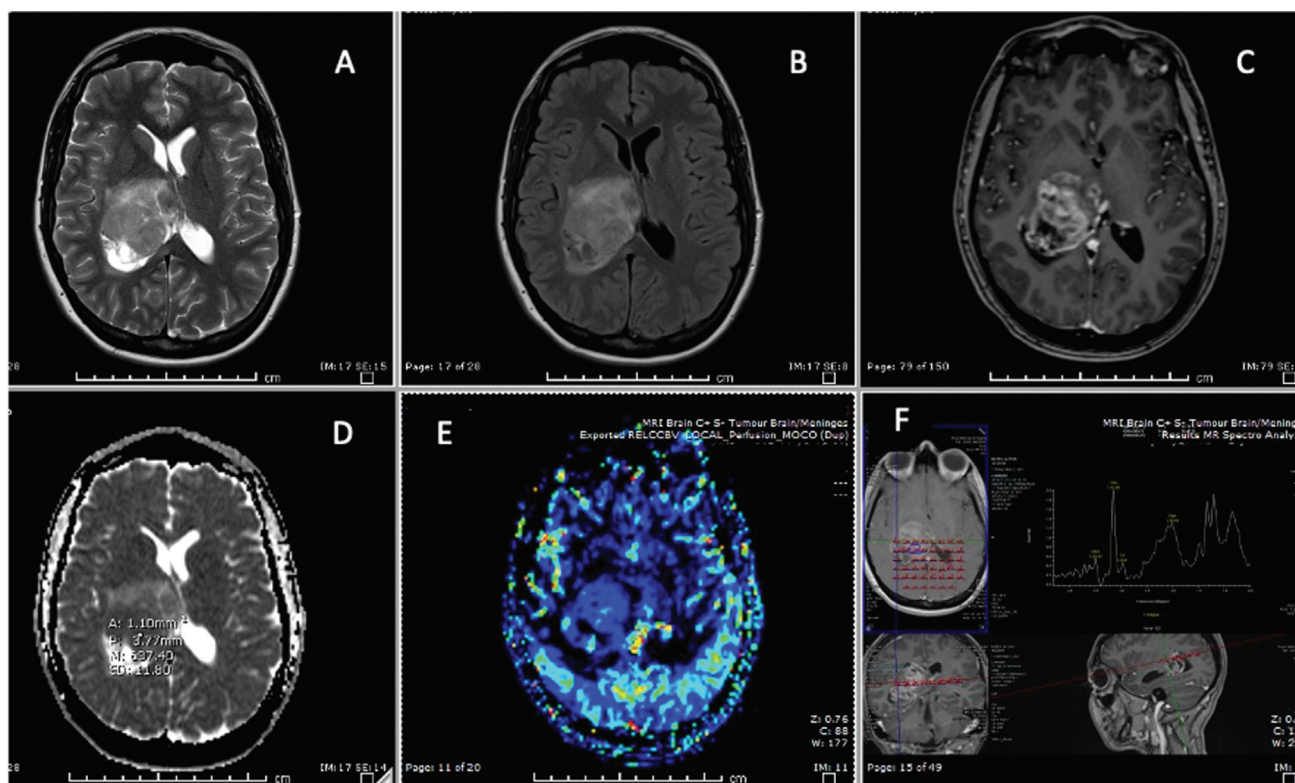


Fig. 4 MRI of adult thalamic DMG-H3 K27M-altered. (A) T2-weighted MRI. The tumor is heterogeneously hyperintense. (B) Fluid attenuated inversion recovery MRI. The tumor is hyperintense. (C) T1-weighted contrast-enhanced MRI. There is significant heterogeneous enhancement. (D) Apparent diffusion coefficient MRI. There is minimal diffusion restriction. (E) Cerebral blood volume MRI. There is patchy increase in perfusion. (F) MR spectroscopy. A gliial tumor trace is identified.

in preoperative prediction of H3 K27M-mutation status. The normalized tumoral and peritumoral relative apparent diffusion coefficient (rADC) values have been reported to be lower and the relative cerebral blood volume (rCBV) and the normalized maximum rCBV (nrCBV) values higher in DMG H3 K27M-mutant.⁴ It has also been suggested that lower minimum rADC values in DMG H3 K27M-mutant indicate more malignant histology, likely representing a more complex tissue microstructure.¹³ Multiparametric MRI-based radiomics models may be useful to predict H3 K27M-mutant status in DMG¹⁴ using ADC histogram parameters. Additionally, myo-inositol/creatine plus phosphocreatine (Ins/tCr) ratios were lower than in the wildtype DMG in both children and adults.^{17,41} Moreover, when comparing DMG H3 K27M-mutant with H3 K27M-wildtype tumors, significant differences were found in T2 signal intensity, with H3.1 and H3.3 mutant tumors demonstrating higher signal intensity and wildtype tumors demonstrating homogeneous T2 signal, and T1 signal homogeneity, with H3 K27M-mutants demonstrating more heterogeneous T1 signal (► **Table 5**). No significant imaging differences have been found between H3.1 and H3.3 K27M mutant tumors¹⁵ (► **Figs. 3 and 4**).

Radiological Features of Spinal Cord DMG H3 K27-Altered

Studies evaluating the radiological features of spinal cord DMG have demonstrated a predilection for the cervical spine.^{78,85} They are isointense on T1-weighted images and hyperintense on T2-weighted. They have either absent or heterogenous peripheral enhancement.³⁵ No significant difference has been described for MRI features of H3 K27M-mutant and H3 K27 wildtype tumors²⁷ however, spinal DMG H3 K27M-mutant tumors are more likely to display lesional hemorrhage.⁶⁸

Pathology

There are no significant histopathological differences between adult and pediatric DMG H3 K27-altered tumors.⁸ Macroscopically, DMG H3 K27-altered share similar appearances to other gliomas in that they are infiltrative, enlarge, and distort invaded structures and have associated necrosis and hemorrhage.²⁹ Microscopically, tumor cells are generally small and monomorphic, but polymorphism

similar to other gliomas may be seen.⁸² Microvascular proliferation, necrosis, and frequent mitoses may be seen but are not associated with prognosis.⁸⁴ Perineural or perivascular clustering does not occur.¹ According to the WHO 2021 classification, those tumors are grade IV, irrespective of histopathological appearance.¹

Immunophenotyping and molecular confirmation of characteristic mutations is essential for diagnosis. Typically, DMG H3 K27-altered stain positive for OLIG2, MAP2, and S100. GFAP (glial fibrillary acidic protein) immunoreactivity varies. The EGFR-mutant subtype often shows positive staining for GFAP and less commonly OLIG2 and SOX10. Antibodies against H3 p.K28M (K27M), H3 p. K28me3 (K27me3), and EZHIP (CXorf67) combined with additional molecular analysis are key to confirm the diagnosis^{45,96} (► **Figs. 5 and 6**).

Treatment

There is no effective treatment for DMG H3 K27M-altered DMG, including for chemotherapy and targeted molecular agents. There is a paucity of literature on treatment of the specific DMG H3 K27M-altered tumor subtypes; therefore, treatment decisions rely on studies addressing DMG in general. Due to the predominantly eloquent location of these tumors, surgical management is often limited to biopsy to avoid postoperative morbidity. The current mainstay of treatment is radiotherapy, which has been shown to provide a symptomatic and survival benefit with limited disease control.⁵⁸

Radiotherapy in H3 K27M-Altered DMG

Fractionated external beam radiotherapy is the mainstay for DMG H3 K27M-altered, due to the known effects in other gliomas.⁴³ The current treatment regimen is 54 Gy in 30 fractions.⁵⁸ In a systematic review by Gallito et al, 49 studies investigating the role of conventionally fractionated, hyperfractionated, and hypofractionated radiotherapy in DIPG were evaluated. Patients who received radiotherapy had a median survival of 11 months as opposed to 6 months without radiotherapy.⁵⁸ The median survival of patients who received hyperfractionated, hypofractionated and conventionally fractionated radiotherapy was 7.9, 10.2, and 12 months, respectively.⁵⁸

Table 5 Comparison of radiological features of DMG H3 K27M-mutant and wildtype

	<i>DMG H3 K27M-mutant</i>	<i>DMG wildtype</i>
<i>MRI</i>	Hyperintense on T2, heterogeneous intensity on T1	Homogeneous intensity on T1 and T2
<i>DWI</i>	Low rADC values	High rADC values
<i>PWI</i>	High rCBV and rCBV values	Low rCBV and rCBV values
<i>MR spectroscopy</i>	Low Ins/tCr ratios	High Ins/tCr ratios

Abbreviations: Cr, creatine; DMG, diffuse midline gliomas; DWI, diffusion-weighted imaging; Ins, inositol; MRI, magnetic resonance imaging; PWI, perfusion weighted imaging; rADC, relative apparent diffusion coefficient; rCBV, relative cerebral blood volume.

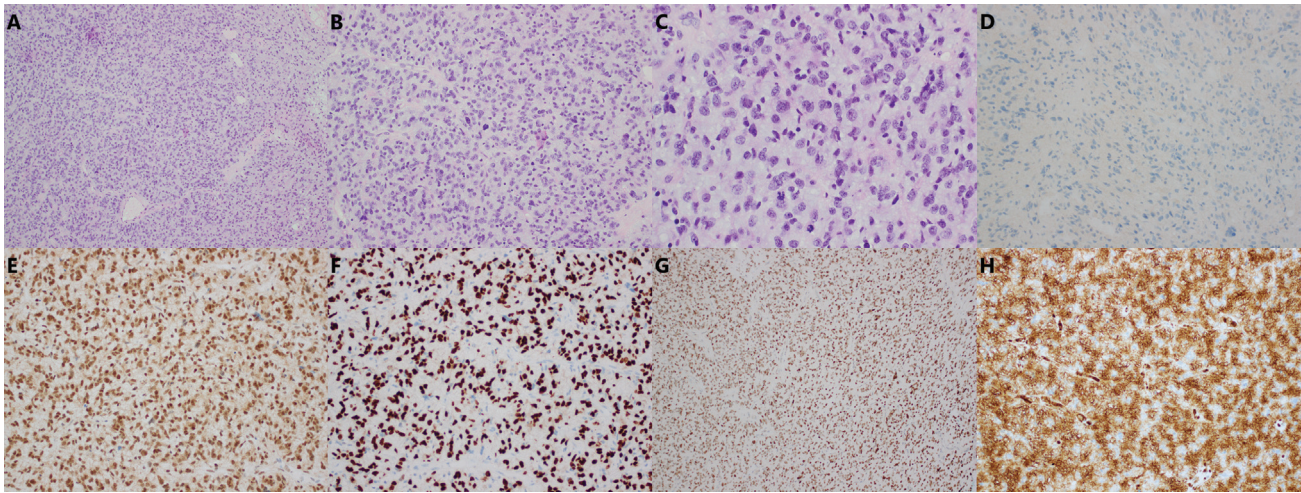


Fig. 5 Histopathology of diffuse midline glioma (DMG) H3 K27M-altered with high grade appearance. (A–C) Sections show a hypercellular glioma. The tumor cells have hyperchromatic, pleomorphic nuclei. Mitoses are numerous, being present in numbers up to 14 per 10 high-power field. There is no necrosis or microvascular proliferation. (D–F) isocitrate dehydrogenase (IDH) immunostain is negative, indicating the absence of an IDH1 R132H mutation. α -thalassaemia mental retardation X-linked protein (ATRX) is retained. OLIG2 is positive, indicating the glial nature of the tumor. (G, H) H3K27M-positive (mutated), H3K27me3—lost. H3K27M immunostain is positive, establishing the diagnosis of diffuse midline glioma, H3 K27-altered (central nervous system World Health Organization grade 4).

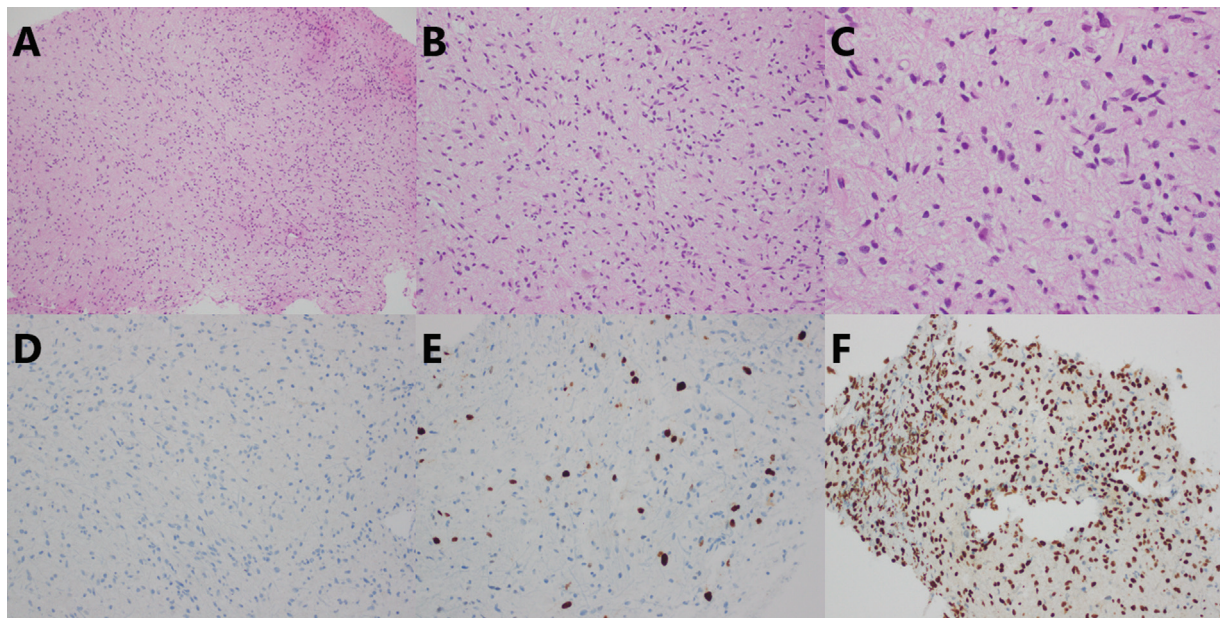


Fig. 6 Histopathology of diffuse midline glioma (DMG) H3 K27M-altered with low grade appearance. (A–C) Sections from a left thalamic lesion showed a moderately cellular glioma. The tumor cell nuclei were moderately enlarged and angulated. No mitoses were identified, and there was no necrosis or microvascular proliferation. (D–F) The isocitrate dehydrogenase (IDH) immunostain was negative, indicating a lack of an IDH1 R132H mutation. Ki67 was elevated at approximately 10%. The H3K27M immunostain was strongly positive, establishing the diagnosis of diffuse midline glioma, H3 K27-altered (central nervous system World Health Organization grade 4). In addition, the lesion underwent pyrosequencing for H3F3A which confirmed the presence of the K27M mutation.

Chemotherapy and Targeted Agents in H3 K27M-Altered DMG

Despite no demonstrated impact on prognosis, chemotherapy is commonly used for DMG. However, even in combination with radiotherapy, chemotherapy has shown no survival benefit.²² The most common agent is temozolomide due to its demonstrated effect in other gliomas.⁷⁰ Other chemotherapy and targeted agents, including panobinostat, gefitinib, thiotepa, and busulfan,

have been trialed, with no benefit.^{22,39,51} In the study by Izzuddeen et al, children with DIPG were randomized to conventional fractionated radiotherapy or hypofractionated radiotherapy with concurrent temozolomide. The median survival was 11 and 12 months, respectively, with no significant difference, but the patients who received radiotherapy and chemotherapy had a higher incidence of hematological toxicity.⁴⁴ Cohen et al compared temozolomide and radiotherapy to combination

chemotherapy with carboplatin/cisplatin, etoposide, cyclophosphamide, and vincristine with radiotherapy, with no improved event-free survival rate compared to combination chemotherapy in DIPG.⁹⁴ Patients receiving temozolomide and radiotherapy had a 1-year overall survival of 40%, compared to 32% in those receiving combination chemotherapy and radiotherapy. Interestingly, H3 K27M mutations cause DNA hypomethylation, including the MGMT promoter.⁷⁹ Therefore, expression of MGMT in DMG H3 K27M-altered tumors will lead to temozolomide resistance in these patients.³⁴

Identification of new therapeutic targets and corresponding targeted therapies against them is an area of intense research and a detailed overview is beyond the scope of this review. Abe et al suggested ALK2 receptor inhibitors may benefit patients with DMG as the type I BMP receptor ALK2 is encoded by ACVR1 gene that is frequently mutated in DMG HIST1H3B-mutant, but not H3.3 H3 K27M-mutant tumors.³⁴ This receptor mutation causes constitutive activation of the BMP signaling pathway that can also be activated in ACVR1-wildtype DMG. Thus, the use of ALK2 inhibitors may be warranted. The same group has suggested PARP (poly (ADP-ribose) polymerase) inhibitors as PARP-mediated base excision facilitates repair of damaged DNA. DMG cells express PARP, thus inhibiting this pathway may be a potential therapeutic.³⁴ Additionally, ONC206, a DRD2/3/4 (dopamine receptor D2/3/4) antagonist, is currently in trial for newly diagnosed and recurrent DMG (ClinicalTrials.gov Identifier: NCT04732065). The availability of new chemotherapy and targeted treatments would provide DMG patients with the option of more efficacious drugs with improved tolerability in a more convenient dosage format. Thus, intense ongoing research is required to give new hope to DMG patients.

Surgery in H3 K27M-Altered DMG

Given the eloquent location of DMG H3 K27M-altered, surgical resection is almost always contraindicated as no survival benefit has been demonstrated and there is a high risk of neurological deterioration and death. No randomized study to date has investigated the role of surgery in DMG. The primary aim of surgery is to obtain a biopsy for diagnosis, prognosis, and research.^{22,77} The single-center, retrospective study by Wang et al that investigated outcome for those with DMG H3 K27M-mutant of the spinal cord found that surgical treatment, including biopsy, subtotal resection, or aggressive resection, showed no significant survival benefit.³¹ Interestingly, another single-center, retrospective study by Dorfer et al reported that surgical resection, as opposed to biopsy, was associated with a statistically significant improvement in overall survival, in a pediatric population of both H3 K27M-mutant (14 patients) and H3 K27M-wildtype (35 patients) thalamic gliomas.³³ However, this was associated with high postoperative surgical morbidity including ataxia, visual field defects, and hemiparesis. A separate analysis of the DMG H3 K27M-mutant tumors was not done and due to the small number of patients, the

inclusion of better prognosis patients with pilocytic astrocytoma (almost 50% of the cohort) and the retrospective data, this study should be interpreted with caution.

In the multicenter, retrospective study by Karremann et al, extent of resection was not associated with improved survival in adults and children with DMG H3 K27M-mutant and H3-wildtype tumors.⁷⁶ A trend to shorter survival in patients in the H3 K27M-mutant group who underwent more than 90% resection compared to those with <90% resection was reported, with 10% 2-year survival for those with less than 90% resection and 0% for those with more than 90% resection.⁷⁶ These findings were replicated by Park et al, who also reported surgical resection was not associated with increased survival in adults with DMG (21.9 vs. 20.4 months), including for gross total compared to subtotal resection (13.2 vs. 21.9 months).²⁰ Similarly, in the review of adult and pediatric patients with H3 K37M-mutant DMG by Vuong et al, surgical resection was not associated with improved overall survival.²⁵

Immunotherapy and Future Perspectives

The search for novel therapies has intensified recently, particularly in relation to immunotherapy.¹¹ Phase 1 studies of chimeric antigen receptor (CAR) T-cells (CAR-T cells) in patients with pontine DMG H3 K27M-mutant have demonstrated both radiological improvements, with reduced T2/FLAIR signal extent on MRI, and clinical improvement. There was, however, also CAR-T cell-mediated inflammation with brainstem edema and obstructive hydrocephalus or transient worsening of clinical deficits.⁵ Other forms of immunotherapy, including immune-modulatory and dendritic cell vaccines, have shown initial promise.⁷⁴

In children, crenolanib, a selective inhibitor of PDGFR-mediated phosphorylation, has shown promising early phase results. It was well tolerated at doses slightly higher than the established maximum tolerated dose in adults, with a similar toxicity spectrum.¹⁸

Combination treatments of personalized cytotoxic agents or targeted inhibitors, chosen based on molecular analysis of biopsied tissue, are being examined in ongoing trials.^{60,80} Additionally, novel methods of drug delivery, including CED (convection-enhancing delivery), with small volume infusions via intraparenchymal catheters⁵⁹ or MRI-guided focused ultrasound that enhances focally drug delivery of targeted chemotherapeutics to brain tumors are being investigated to bypass the blood-brain barrier.²⁸ In a study by Gojo et al, mutations identified in patients with H3 K27M-mutant tumors, including those in E545K, G118D, and ACVR1, were targeted in a personalized medicine approach. However, the median survival of 16.5 months for the treatment group was not different to 17.5 months for the control group.⁶⁰ Chi et al reported a promising response using a selective dopamine receptor D2/3 antagonist.⁶⁴ Clearly further research into new approaches is needed.

Prognosis

DMG H3 K27M-altered carry a poor prognosis for both adults and children, with a median survival around 1 year and a poorer prognosis compared to most other gliomas (► **Table 4**).^{28,29,36,40,53,59,67,86,92} In adults, prognosis does not vary by anatomical site.¹⁰ In children with DMG H3 K27M-mutant, the median survival is 9 to 15 months,⁸⁹ except in children with NF1 for whom all DMG have an extremely poor prognosis, independent of the presence or absence of H3 K27M mutation.⁵²

Adults fare slightly better with a median survival of 8 to 27.6 months.^{8,49,65,72,77} The mechanisms of this survival advantage are unknown; however, as pediatric DMG H3 K27M-mutant tumors occur more commonly in the brainstem, and adult tumors in the thalamus, location may be important, with a greater morbidity in brainstem tumors.^{10,49,73} Additionally, the molecular genetics of thalamic DMG H3 K27M-mutant tumors differ compared to those in the brainstem, including in expression of the CDK6, TP53, K27M, and IDH1 genes.⁸⁶ Additionally, TP53 mutation has been reported as a poor prognostic indicator, but FGFR1 mutation and ATRX loss confers prolonged survival.²⁵ Thus, the molecular characteristics are likely more important than location to predict prognosis and should be examined in all patients.

For spinal cord DMG, the H3 K27M mutation predicts a worse outcome than other gliomas, although thoracic tumors have a significantly better prognosis than cervical.³⁷

Conclusion

DMG H3 K27-altered are uniformly fatal primary CNS tumors for which the biology is only beginning to be determined. Differences in location and prognosis between adults and children are not fully understood. Current treatments are ineffective with research efforts aimed at novel drug delivery mechanisms, targeted agents, and immunotherapy. Further investigation is clearly required to improve outcomes.

Conflict of Interest

K.W. reported financial support provided by the Polish National Agency for Academic Exchange (the Bekker Programme). All other authors reported no conflict of interest.

Acknowledgment

K.W. gratefully acknowledges financial support provided by the Polish National Agency for Academic Exchange (the Bekker Programme).

References

- Louis DN, Perry A, Reifenberger G, et al. The 2016 World Health Organization Classification of Tumors of the Central Nervous System: a summary. *Acta Neuropathol* 2016;131(06):803–820
- Kurokawa R, Kurokawa M, Baba A, et al. Major Changes in 2021 World Health Organization Classification of Central Nervous System Tumors. *Radiographics* 2022;42(05):1474–1493
- Vuong HG, Ngo TNM, Le HT, et al. Prognostic implication of patient age in H3K27M-mutant midline gliomas. *Front Oncol* 2022; 12:858148
- Kathrani N, Chauhan RS, Kotwal A, et al. Diffusion and perfusion imaging biomarkers of H3 K27M mutation status in diffuse midline gliomas. *Neuroradiology* 2022;64(08):1519–1528
- Majzner RG, Ramakrishna S, Yeom KW, et al. GD2-CAR T cell therapy for H3K27M-mutated diffuse midline gliomas. *Nature* 2022;603(7903):934–941
- Findlay IJ, De Luliis GN, Duchatel RJ, et al. Pharmacoproteogenomic profiling of pediatric diffuse midline glioma to inform future treatment strategies. *Oncogene* 2022;41(04): 461–475
- López-Pérez CA, Franco-Mojica X, Villanueva-Gaona R, Díaz-Alba A, Rodríguez-Flórida MA, Navarro VG. Adult diffuse midline gliomas H3 K27-altered: review of a redefined entity. *J Neurooncol* 2022;158(03):369–378
- Zheng L, Gong J, Yu T, et al. Diffuse midline gliomas with histone H3 K27M mutation in adults and children: a retrospective series of 164 cases. *Am J Surg Pathol* 2022;46(06):863–871
- Damodharan S, Lara-Velazquez M, Williamsen BC, Helgager J, Dey M. Diffuse intrinsic pontine glioma: molecular landscape, evolving treatment strategies and emerging clinical trials. *J Pers Med* 2022;12(05):840
- Vuong HG, Le HT, Jea A, McNall-Knapp R, Dunn IF. Risk stratification of H3 K27M-mutant diffuse midline gliomas based on anatomical locations: an integrated systematic review of individual participant data. *J Neurosurg Pediatr* 2022;29:1–8
- Mount CW, Gonzalez Castro LN. Advances in chimeric antigen receptor (CAR) t-cell therapies for the treatment of primary brain tumors. *Antibodies (Basel)* 2022;11(02):31
- Zaytseva M, Usman N, Salnikova E, et al. Methodological challenges of digital PCR detection of the histone H3 K27M somatic variant in cerebrospinal fluid. *Pathol Oncol Res* 2022; 28:1610024
- Raab P, Banan R, Akbarian A, et al. Differences in the MRI signature and ADC values of diffuse midline gliomas with H3 K27M mutation compared to midline glioblastomas. *Cancers (Basel)* 2022;14(06):1397
- Guo W, She D, Xing Z, et al. Multiparametric MRI-based radiomics model for predicting H3 K27M mutant status in diffuse midline glioma: a comparative study across different sequences and machine learning techniques. *Front Oncol* 2022; 12:796583
- Hohm A, Karremann M, Gielen GH, et al. Magnetic resonance imaging characteristics of molecular subgroups in pediatric H3 K27M mutant diffuse midline glioma. *Clin Neuroradiol* 2022;32 (01):249–258
- Ikeda K, Kolakshyapati M, Takayasu T, et al. Diffusion-weighted imaging-gadolinium enhancement mismatch sign in diffuse midline glioma. *Eur J Radiol* 2022;147:110103
- Su X, Liu Y, Wang H, et al. Multimodal MR imaging signatures to identify brain diffuse midline gliomas with H3 K27M mutation. *Cancer Med* 2022;11(04):1048–1058
- Tinkle CL, Broniscer A, Chiang J, et al. Phase I study using crenolanib to target PDGFR kinase in children and young adults with newly diagnosed DIPG or recurrent high-grade glioma, including DIPG. *Neurooncol Adv* 2021;3(01):vdab179
- Ostrom QT, Cioffi G, Waite K, Kruchko C, Barnholtz-Sloan JS. CBTRUS statistical report: primary brain and other central nervous system tumors diagnosed in the United States in 2014–2018. *Neuro-oncol* 2021;23(12, Suppl 2):iii1–iii105
- Park C, Kim TM, Bae JM, et al. Clinical and genomic characteristics of adult diffuse midline glioma. *Cancer Res Treat* 2021;53(02): 389–398
- Louis DN, Perry A, Wesseling P, et al. The 2021 WHO classification of tumors of the central nervous system: a summary. *Neuro-oncol* 2021;23(08):1231–1251

- 22 Yoon HI, Wee CW, Kim YZ, et al; KSNO Guideline Working Group. The Korean Society for Neuro-Oncology (KSNO) guideline for adult diffuse midline glioma: version 2021.1. *Brain Tumor Res Treat* 2021;9(01):1–8
- 23 Gu Q, Huang Y, Zhang H, Jiang B. Case report: five adult cases of H3K27-altered diffuse midline glioma in the spinal cord. *Front Oncol* 2021;11:701113
- 24 Srikanthan D, Taccone MS, Van Ommeren R, Ishida J, Krumholtz SL, Rutka JT. Diffuse intrinsic pontine glioma: current insights and future directions. *Chin Neurosurg J* 2021;7(01):6
- 25 Vuong HG, Le HT, Ngo TNM, et al. H3K27M-mutant diffuse midline gliomas should be further molecularly stratified: an integrated analysis of 669 patients. *J Neurooncol* 2021;155(03):225–234
- 26 Seong M, Kim ST, Noh JH, Kim YK, Kim HJ. Radiologic findings and the molecular expression profile of diffuse midline glioma H3 K27M mutant. *Acta Radiol* 2021;62(10):1404–1411
- 27 Cheng L, Wang L, Yao Q, et al. Clinicoradiological characteristics of primary spinal cord H3 K27M-mutant diffuse midline glioma. *J Neurosurg Spine* 2021;24:1–12
- 28 Ishida J, Alli S, Bondoc A, et al. MRI-guided focused ultrasound enhances drug delivery in experimental diffuse intrinsic pontine glioma. *J Control Release* 2021;330(330):1034–1045
- 29 Hassan U, Latif M, Yousaf I, et al. Morphological spectrum and survival analysis of diffuse midline glioma with H3K27M mutation. *Cureus* 2021;13(08):e17267
- 30 Banan R, Akbarian A, Samii M, et al. Diffuse midline gliomas, H3 K27M-mutant are associated with less peritumoral edema and contrast enhancement in comparison to glioblastomas, H3 K27M-wildtype of midline structures. *PLoS One* 2021;16(08):e0249647
- 31 Wang YZ, Zhang YW, Liu WH, et al. Spinal cord diffuse midline gliomas with H3 K27m-mutant: clinicopathological features and prognosis. *Neurosurgery* 2021;89(02):300–307
- 32 Santisukwongchote S, Teerapakpinyo C, Chankate P, et al. Simplified approach for pathological diagnosis of diffuse gliomas in adult patients. *Pathol Res Pract* 2021;223:153483
- 33 Dorfer C, Czech T, Gojo J, et al. Infiltrative gliomas of the thalamus in children: the role of surgery in the era of H3 K27M mutant midline gliomas. *Acta Neurochir (Wien)* 2021;163(07):2025–2035
- 34 Abe H, Natsumeda M, Okada M, et al. MGMT expression contributes to temozolomide resistance in H3K27M-mutant diffuse midline gliomas. *Front Oncol* 2020;9:1568
- 35 Cheng R, Li DP, Zhang N, et al. Spinal cord diffuse midline glioma with histone H3 K27M mutation in a pediatric patient. *Front Surg* 2021;8:616334
- 36 Ruttens D, Messiaen J, Ferster A, et al. Retrospective study of diffuse intrinsic pontine glioma in the Belgian population: a 25 year experience. *J Neurooncol* 2021;153(02):293–301
- 37 Yao J, Wang L, Ge H, Yin H, Piao Y. Diffuse midline glioma with H3 K27M mutation of the spinal cord: a series of 33 cases. *Neuropathology* 2021;41(03):183–190
- 38 Li Q, Dong F, Jiang B, Zhang M. Exploring MRI characteristics of brain diffuse midline gliomas with the H3 K27M mutation using radiomics. *Front Oncol* 2021;11:646267
- 39 Vitanza NA, Biery MC, Myers C, et al. Optimal therapeutic targeting by HDAC inhibition in biopsy-derived treatment-naïve diffuse midline glioma models. *Neuro-oncol* 2021;23(03):376–386
- 40 Alzoubi H, Maraqa B, Hasasna N, et al. Diffuse midline glioma H3 K27M-mutant in adults: a report of six cases and literature review. *Clin Neuropathol* 2021;40(02):108–117
- 41 Thust S, Micallef C, Okuchi S, et al. Imaging characteristics of H3 K27M histone-mutant diffuse midline glioma in teenagers and adults. *Quant Imaging Med Surg* 2021;11(01):43–56
- 42 Sanders LM, Cheney A, Seninge L, et al. Identification of a differentiation stall in epithelial mesenchymal transition in histone H3-mutant diffuse midline glioma. *Gigascience* 2020;9(12):136
- 43 Pombo Antunes AR, Scheyltjens I, Duerinck J, Neyns B, Movahedi K, Van Ginderachter JA. Understanding the glioblastoma immune microenvironment as basis for the development of new immunotherapeutic strategies. *eLife* 2020;9:9
- 44 Izzuddeen Y, Gupta S, Hareh KP, Sharma D, Giridhar P, Rath GK. Hypofractionated radiotherapy with temozolomide in diffuse intrinsic pontine gliomas: a randomized controlled trial. *J Neurooncol* 2020;146(01):91–95
- 45 Castel D, Kergrohen T, Tauziède-Espariat A, et al. Histone H3 wild-type DIPG/DMG overexpressing EZHIP extend the spectrum diffuse midline gliomas with PRC2 inhibition beyond H3-K27M mutation. *Acta Neuropathol* 2020;139(06):1109–1113
- 46 Antin C, Tauziède-Espariat A, Debily MA, et al. EZHIP is a specific diagnostic biomarker for posterior fossa ependymomas, group PFA and diffuse midline gliomas H3-WT with EZHIP overexpression. *Acta Neuropathol Commun* 2020;8(01):183
- 47 Pajovic S, Siddaway R, Bridge T, et al. Epigenetic activation of a RAS/MYC axis in H3.3K27M-driven cancer. *Nat Commun* 2020;11(01):6216
- 48 Dono A, Takayasu T, Ballester LY, Esquenazi Y. Adult diffuse midline gliomas: Clinical, radiological, and genetic characteristics. *J Clin Neurosci* 2020;82(Pt A)1–8
- 49 Schulte JD, Buerki RA, Lapointe S, et al. Clinical, radiologic, and genetic characteristics of histone H3 K27M-mutant diffuse midline gliomas in adults. *Neurooncol Adv* 2020;2(01):vdaa142
- 50 Cooney TM, Lubaszky E, Prasad R, Hawkins C, Mueller S. Diffuse midline glioma: review of epigenetics. *J Neurooncol* 2020;150(01):27–34
- 51 Lin GL, Wilson KM, Ceribelli M, et al. Therapeutic strategies for diffuse midline glioma from high-throughput combination drug screening. *Sci Transl Med* 2019;11(519):64
- 52 Garibotto F, Madia F, Milanaccio C, et al. Pediatric diffuse midline gliomas H3 K27M-mutant and non-histone mutant midline high-grade gliomas in neurofibromatosis type 1 in comparison with non-syndromic children: a single-center pilot study. *Front Oncol* 2020;10:795
- 53 Maeda S, Ohka F, Okuno Y, et al. H3F3A mutant allele specific imbalance in an aggressive subtype of diffuse midline glioma, H3 K27M-mutant. *Acta Neuropathol Commun* 2020;8(01):8
- 54 Qiu T, Chanchotisien A, Qin Z, et al. Imaging characteristics of adult H3 K27M-mutant gliomas. *J Neurosurg* 2019;15:1–9
- 55 Aboian MS, Tong E, Solomon DA, et al. Diffusion characteristics of pediatric diffuse midline gliomas with histone H3-K27M mutation using apparent diffusion coefficient histogram analysis. *AJNR Am J Neuroradiol* 2019;40(11):1804–1810
- 56 Vitanza NA, Monje M. Diffuse intrinsic pontine glioma: from diagnosis to next-generation clinical trials. *Curr Treat Options Neurol* 2019;21(08):37
- 57 Colafati GS, Voicu IP, Carducci C, et al. Direct involvement of cranial nerve v at diagnosis in patients with diffuse intrinsic pontine glioma: a potential magnetic resonance predictor of short-term survival. *Front Oncol* 2019;9:204
- 58 Gallitto M, Lazarev S, Wasserman I, et al. Role of radiation therapy in the management of diffuse intrinsic pontine glioma: a systematic review. *Adv Radiat Oncol* 2019;4(03):520–531
- 59 Himes BT, Zhang L, Daniels DJ. Treatment strategies in diffuse midline gliomas with the H3K27M mutation: the role of convection-enhanced delivery in overcoming anatomic challenges. *Front Oncol* 2019;9:31
- 60 Gojo J, Pavelka Z, Zapletalova D, et al. Personalized treatment of H3K27M-mutant pediatric diffuse gliomas provides improved therapeutic opportunities. *Front Oncol* 2020;9:1436
- 61 Lowe BR, Maxham LA, Hamey JJ, Wilkins MR, Partridge JF. Histone H3 mutations: an updated view of their role in chromatin deregulation and cancer. *Cancers (Basel)* 2019;11(05):11

- 62 Hoeman CM, Cordero FJ, Hu G, et al. ACVR1 R206H cooperates with H3.1K27M in promoting diffuse intrinsic pontine glioma pathogenesis. *Nat Commun* 2019;10(01):1023
- 63 Uppar AM, Sugur H, Prabhuraj AR, et al. H3K27M, IDH1, and ATRX expression in pediatric GBM and their clinical and prognostic significance. *Childs Nerv Syst* 2019;35(09):1537–1545
- 64 Chi AS, Tarapore RS, Hall MD, et al. Pediatric and adult H3 K27M-mutant diffuse midline glioma treated with the selective DRD2 antagonist ONC201. *J Neurooncol* 2019;145(01):97–105
- 65 Schreck KC, Ranjan S, Skorupan N, et al. Incidence and clinicopathologic features of H3 K27M mutations in adults with radiographically-determined midline gliomas. *J Neurooncol* 2019;143(01):87–93
- 66 Yi S, Choi S, Shin DA, et al. Impact of H3.3 K27M mutation on prognosis and survival of grade IV spinal cord glioma on the basis of new 2016 World Health Organization Classification of the Central Nervous System. *Neurosurgery* 2019;84(05):1072–1081
- 67 Ebrahimi A, Skardelly M, Schuhmann MU, et al. High frequency of H3 K27M mutations in adult midline gliomas. *J Cancer Res Clin Oncol* 2019;145(04):839–850
- 68 Jung JS, Choi YS, Ahn SS, Yi S, Kim SH, Lee SK. Differentiation between spinal cord diffuse midline glioma with histone H3 K27M mutation and wild type: comparative magnetic resonance imaging. *Neuroradiology* 2019;61(03):313–322
- 69 Hoffman LM, Veldhuijzen van Zanten SEM, Colditz N, et al. Clinical, radiologic, pathologic, and molecular characteristics of long-term survivors of diffuse intrinsic pontine glioma (DIPG): a collaborative report from the international and European Society for Pediatric Oncology DIPG registries. *J Clin Oncol* 2018;36(19):1963–1972
- 70 Karachi A, Dastmalchi F, Mitchell DA, Rahman M. Temozolomide for immunomodulation in the treatment of glioblastoma. *Neuro-oncol* 2018;20(12):1566–1572
- 71 Filbin MG, Tirosh I, Hovestadt V, et al. Developmental and oncogenic programs in H3K27M gliomas dissected by single-cell RNA-seq. *Science* 2018;360(6386):331–335
- 72 Kleinschmidt-DeMasters BK, Mulcahy Levy JM. H3 K27M-mutant gliomas in adults vs. children share similar histological features and adverse prognosis. *Clin Neuropathol* 2018;37(02):53–63
- 73 Wang L, Li Z, Zhang M, et al. H3 K27M-mutant diffuse midline gliomas in different anatomical locations. *Hum Pathol* 2018;78:89–96
- 74 Benitez-Ribas D, Cabezón R, Flórez-Grau G, et al. Immune response generated with the administration of autologous dendritic cells pulsed with an allogenic tumoral cell-lines lysate in patients with newly diagnosed diffuse intrinsic pontine glioma. *Front Oncol* 2018;8:127
- 75 Castel D, Philippe C, Kergrohen T, et al. Transcriptomic and epigenetic profiling of 'diffuse midline gliomas, H3 K27M-mutant' discriminate two subgroups based on the type of histone H3 mutated and not supratentorial or infratentorial location. *Acta Neuropathol Commun* 2018;6(01):117
- 76 Karremann M, Gielen GH, Hoffmann M, et al. Diffuse high-grade gliomas with H3 K27M mutations carry a dismal prognosis independent of tumor location. *Neuro-oncol* 2018;20(01):123–131
- 77 Meyronet D, Esteban-Mader M, Bonnet C, et al. Characteristics of H3 K27M-mutant gliomas in adults. *Neuro-oncol* 2017;19(08):1127–1134
- 78 Tanaka S, Otani R, Hongo H, et al. PATH-28. Clinical and genetic characteristics of diffuse midline glioma in the spinal cord. *Neuro-oncol* 2017;19(Suppl 6):176
- 79 Banan R, Christians A, Bartels S, Lehmann U, Hartmann C. Absence of MGMT promoter methylation in diffuse midline glioma, H3 K27M-mutant. *Acta Neuropathol Commun* 2017;5(01):98
- 80 Gwak HS, Park HJ. Developing chemotherapy for diffuse pontine intrinsic gliomas (DIPG). *Crit Rev Oncol Hematol* 2017;120:111–119
- 81 Aboian MS, Solomon DA, Felton E, et al. Imaging characteristics of pediatric diffuse midline gliomas with histone H3 K27M mutation. *AJNR Am J Neuroradiol* 2017;38(04):795–800
- 82 Solomon DA, Wood MD, Tihan T, et al. Diffuse midline gliomas with histone H3-K27M mutation: a series of 47 cases assessing the spectrum of morphologic variation and associated genetic alterations. *Brain Pathol* 2016;26(05):569–580
- 83 Ryal S, Krishnatreya R, Arnoldo A, et al. Targeted detection of genetic alterations reveal the prognostic impact of H3K27M and MAPK pathway aberrations in paediatric thalamic glioma. *Acta Neuropathol Commun* 2016;4(01):93
- 84 Castel D, Philippe C, Calmon R, et al. Histone H3F3A and HIST1H3B K27M mutations define two subgroups of diffuse intrinsic pontine gliomas with different prognosis and phenotypes. *Acta Neuropathol* 2015;130(06):815–827
- 85 Gessi M, Gielen GH, Dreschmann V, Waha A, Pietsch T. High frequency of H3F3A (K27M) mutations characterizes pediatric and adult high-grade gliomas of the spinal cord. *Acta Neuropathol* 2015;130(03):435–437
- 86 Feng J, Hao S, Pan C, et al. The H3.3 K27M mutation results in a poorer prognosis in brainstem gliomas than thalamic gliomas in adults. *Hum Pathol* 2015;46(11):1626–1632
- 87 Fontebasso AM, Papillon-Cavanagh S, Schwartztruber J, et al. Recurrent somatic mutations in ACVR1 in pediatric midline high-grade astrocytoma. *Nat Genet* 2014;46(05):462–466
- 88 Wu G, Diaz AK, Paugh BS, et al. The genomic landscape of diffuse intrinsic pontine glioma and pediatric non-brainstem high-grade glioma. *Nat Genet* 2014;46(05):444–450
- 89 Gielen GH, Gessi M, Hammes J, Kramm CM, Waha A, Pietsch T. H3F3A K27M mutation in pediatric CNS tumors: a marker for diffuse high-grade astrocytomas. *Am J Clin Pathol* 2013;139(03):345–349
- 90 Bender S, Tang Y, Lindroth AM, et al. Reduced H3K27me3 and DNA hypomethylation are major drivers of gene expression in K27M mutant pediatric high-grade gliomas. *Cancer Cell* 2013;24(05):660–672
- 91 Parker JJ, Dionne KR, Massarwa R, et al. Gefitinib selectively inhibits tumor cell migration in EGFR-amplified human glioblastoma. *Neuro-oncol* 2013;15(08):1048–1057
- 92 Khuong-Quang DA, Buczkowicz P, Rakopoulos P, et al. K27M mutation in histone H3.3 defines clinically and biologically distinct subgroups of pediatric diffuse intrinsic pontine gliomas. *Acta Neuropathol* 2012;124(03):439–447
- 93 Sturm D, Witt H, Hovestadt V, et al. Hotspot mutations in H3F3A and IDH1 define distinct epigenetic and biological subgroups of glioblastoma. *Cancer Cell* 2012;22(04):425–437
- 94 Cohen KJ, Heideman RL, Zhou T, et al. Temozolomide in the treatment of children with newly diagnosed diffuse intrinsic pontine gliomas: a report from the Children's Oncology Group. *Neuro-oncol* 2011;13(04):410–416
- 95 Monje M, Mitra SS, Freret ME, et al. Hedgehog-responsive candidate cell of origin for diffuse intrinsic pontine glioma. *Proc Natl Acad Sci U S A* 2011;108(11):4453–4458
- 96 Panwalkar P, Clark J, Ramaswamy V, et al. Immunohistochemical analysis of H3K27me3 demonstrates global reduction in group-A childhood posterior fossa ependymoma and is a powerful predictor of outcome. *Acta Neuropathol* 2017;134(05):705–714