







# Connectomic Networks and Their Impact on Clinical Outcomes in Glioma Treatment: A Review

Cameron A. Rawanduzy<sup>1</sup> Emma R. Earl<sup>2</sup> Jaden B. Brooks<sup>2</sup> Majid Khan<sup>3</sup> Nicholas B. Dадario<sup>4</sup>  
Michael E. Sughrue<sup>5</sup> Michael Karsy<sup>1,6,7</sup>

<sup>1</sup>Department of Neurosurgery, Clinical Neurosciences Center, University of Utah, Salt Lake City, Utah, United States

<sup>2</sup>School of Medicine, University of Utah, Salt Lake City, Utah, United States

<sup>3</sup>School of Medicine, University of Nevada, Reno, Nevada, United States

<sup>4</sup>School of Medicine, Rutgers Robert Wood Johnson, New Brunswick, New Jersey, United States

<sup>5</sup>Department of Neurosurgery, Prince of Wales Hospital, Randwick, New South Wales, Australia

Address for correspondence Michael Karsy, MD, PhD, MSc,

Department of Neurosurgery, Clinical Neurosciences Center,

University of Utah, 175 N. Medical Drive East, Salt Lake City, UT 84132, United States (e-mail: michaelkarsy@gmail.com).

<sup>6</sup>Global Neurosciences Institute, Upland, Pennsylvania, United States

<sup>7</sup>Department of Neurosurgery, Drexel University College of Medicine, Philadelphia, Pennsylvania, United States

Indian J Neurosurg 2023;12:116–131.

## Abstract

The emerging field of connectomics has provided an improved understanding of the structural and functional organization of the human brain into large-scale brain networks. Recent studies have helped define the canonical neurological networks and outline how considering their presence may aid in surgical decision-making in brain tumor patients. Gliomas represent one of the most common types of brain tumor and often involve displacement and/or infiltration of neurological pathways, suggesting an opportunity to use connectomic maps to improve patient morbidity and mortality based on oncofunctional goals. This review aims to provide a working knowledge of important neurological networks, examine the use of networks in surgical planning, and describe the current literature discussing the impact of these networks on clinical outcomes in glioma resection.

## Keywords

- ▶ connectomics
- ▶ glioma
- ▶ glioblastoma
- ▶ neurooncology
- ▶ networks

## Introduction

An integrated understanding of the functional innerworkings of the brain remains a limiting factor in predicting neurological outcomes of diseases like gliomas and defining appropriate neurosurgical intervention. Up to 75% of glioma patients may have neurocognitive deficits; this remains challenging to study due to variability in patient baseline cognitive status, tumor size, and location, as well as limited availability of detailed postoperative neuropsychological testing.<sup>1</sup> Although abundant research has been dedicated to learning about the structural and chemical properties of

the brain, the connective organization of the brain is largely unknown.<sup>2</sup> Neuronal tracts within the brain create functional parallel networks to share and process information.<sup>3</sup> Gliomas can impact these multiple, interrelated neurological networks in unclear ways that add complexity to clinical outcome prediction.

Connectomics is the study of the brain's entire set of neural connections ("connectome"), that is, the white matter connections that carry information between cortical and subcortical structures. Since the inception of the Human Connectome Project in 2010, the field

article published online  
July 24, 2023

DOI <https://doi.org/10.1055/s-0043-1771214>.  
ISSN 2277-954X.

© 2023. The Author(s).

This is an open access article published by Thieme under the terms of the Creative Commons Attribution License, permitting unrestricted use, distribution, and reproduction so long as the original work is properly cited. (<https://creativecommons.org/licenses/by/4.0/>)

Thieme Medical and Scientific Publishers Pvt. Ltd., A-12, 2nd Floor, Sector 2, Noida-201301 UP, India

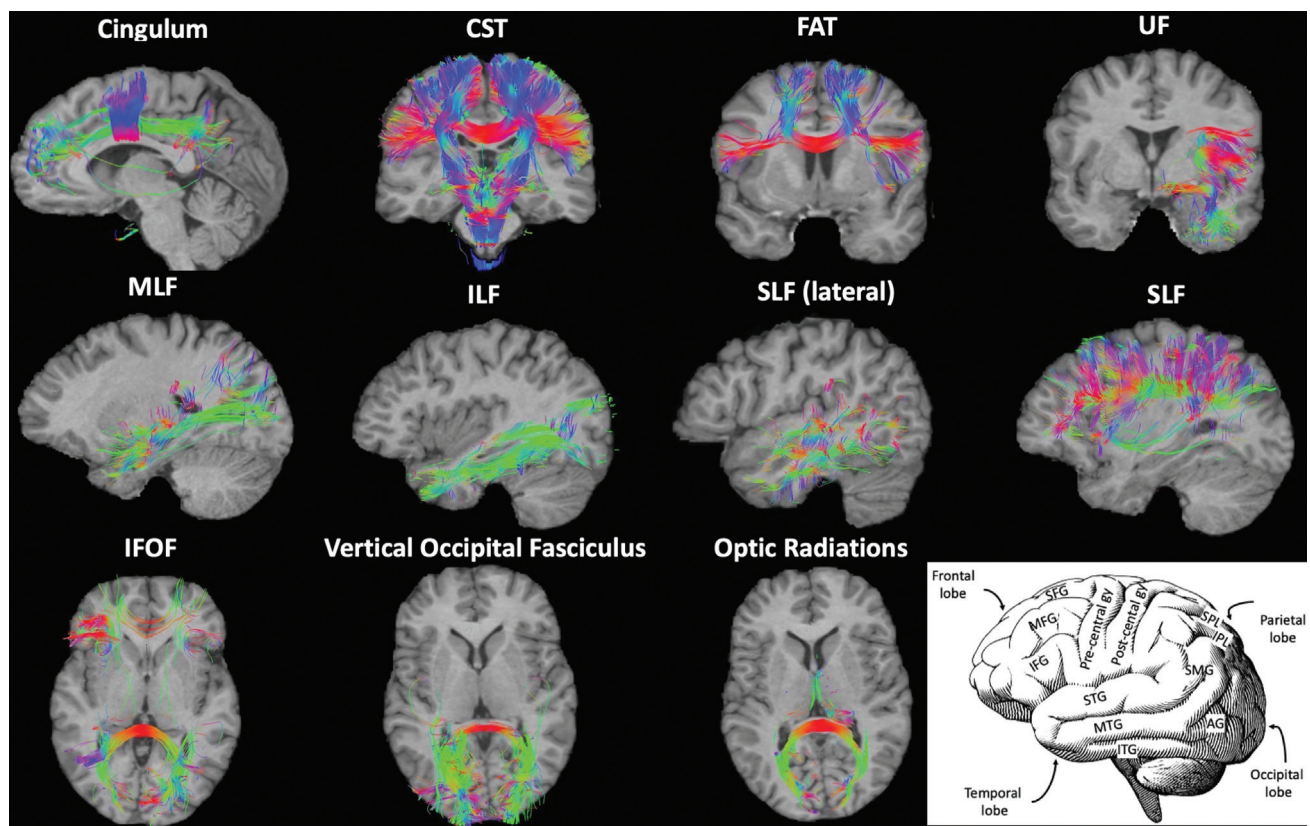
of connectomics has garnered great interest in cognitive neuroscience and neurosurgery.<sup>4</sup> This momentum, alongside advances in magnetic resonance imaging (MRI) such as functional MRI (fMRI) and diffusion tensor imaging, has led to tremendous growth in efforts to map the brain's connectivity.<sup>3</sup> Additionally, commercially available software, such as Quicktome by Omniscent (Sydney, Australia), can generate patient-specific connectomic maps that enable presurgical planning and postoperative correlation with functional changes. Connectome data can be used in research of neurodegenerative and neurodevelopmental diseases, managing neuropsychiatric illness, and improving brain tumor therapy.<sup>3,5,6</sup> An improved understanding of the human connectome offers potential avenues to mitigate these challenges and is the next step in defining neurologic disease processes and uncovering better strategies to treat them.<sup>7</sup> This review aims to highlight the significance of the connectome and its major encompassing neuronal networks, as well as discuss its use in surgical planning and clinical outcomes of glioma patients.

## The Connectome

The human cerebrum's entire set of structural and functional connections constitutes the human connectome.

While these connections can be represented at various macroscopic, mesoscopic, and microscopic levels, macroscale connections at the level of large white matter bundles are most actionable for neurosurgery at the current time. Importantly, as it has become clearer that functionally distinct regions support human behavior through interacting in dynamic large-scale brain networks, recent anatomic and lesion-based studies have also demonstrated that structural white matter connections often link these functional regions and brain networks—illustrating regions that *fire* together are *wired* together (►Fig. 1).

The primary networks are the default mode network (DMN), central executive network (CEN), salience network (SN), dorsal attention network (DAN), limbic/paralimbic network, visual network, and sensorimotor network (►Table 1).<sup>5</sup> The ventral attention network interacts closely with the aforementioned networks; however, its role is beyond the scope of this article. The language network is an additional part of the connectome closely tied to disease outcomes. Among these, the DMN, CEN, and SN are often considered the “cognitive control networks” (►Fig. 2), and damage or dysfunction in these networks often accounts for the majority of identifiable cognitive deficits in large-scale reviews.<sup>5</sup> However, each of the other networks often plays a critical role in information sharing through



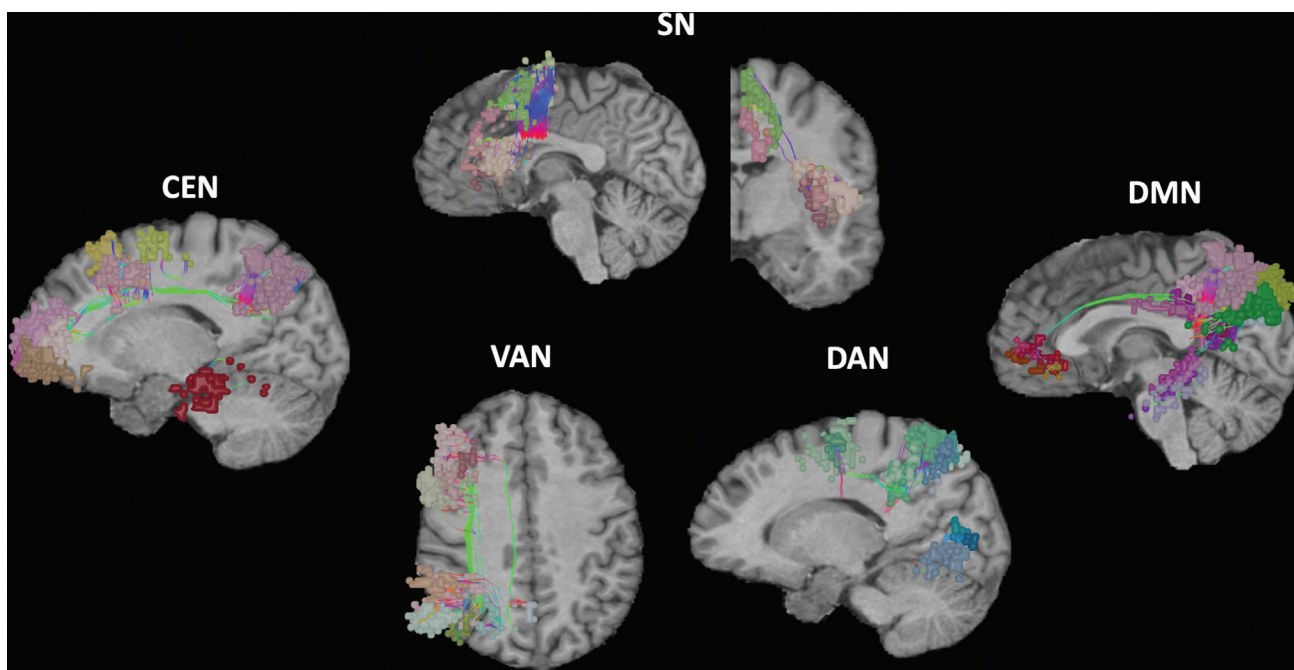
**Fig. 1** Illustration of the major white matter bundles distributed throughout the human connectome. Fibers that are presented in only one hemisphere are for figure demonstration purposes but are bilateral in actuality. Key: This figure presents a visualization of the various connectomic networks in the brain. AG, angular gyrus; CST, corticospinal tract; FAT, frontal aslant tract; IFG, inferior frontal gyrus; IFOF, inferior fronto-occipital fasciculus; ILF, inferior longitudinal fasciculus; IPL, inferior parietal lobule; ITG, inferior temporal gyrus; MFG, middle frontal gyrus; MLF, medial longitudinal fasciculus; MTG, middle temporal gyrus; SFG, superior frontal gyrus; SLF, superior longitudinal fasciculus; SMG, supramarginal gyrus; SPL, superior parietal lobule; STG, superior temporal gyrus; UF, uncinata fasciculus.

**Table 1** Summary of functional brain networks, positions, and potential clinical outcomes

Network	Location	Function	Consequences if damaged
Language <sup>173,174</sup>	Lateral prefrontal cortex, left temporal regions, left dorso-medial prefrontal cortex, inferior frontal gyrus, superior temporal cortex, anteroinferior left temporal gyrus	Verbal and written words, comprehension and processing of language	Neurological decline, aphasia
Sensorimotor <sup>134–137,139</sup>	Primary motor, cingulate, premotor cortices. Primary and sensory cortices in the parietal lobe. Supplementary motor area	External signaling processing, sensory evaluation, internal sensations, production of motor response to external stimuli	Sensory and movement disorders, degenerative diseases, developmental delays
Central executive <sup>24,47</sup>	Anterior cingulate cortex, inferior parietal lobe, posterior portions of the middle, and inferior temporal gyri	Engages in active tasks and external thinking for working memory. Controlled processing of information, integrate information from other networks, problem solving and decision making, reinforce visually learned behaviors	Psychiatric and neurological disorders such as depression, schizophrenia, autism
Default mode <sup>24,26–29</sup>	Medial prefrontal cortex, posterior cingulate cortex, retrosplenial cortex, inferior parietal lobe	Coordinating network for passive sensory processing including visual, language, and emotional stimuli via the limbic system	Neuropsychiatric disorders such as schizophrenia, PTSD, difficulty processing social situations and information
Saliency <sup>65–74</sup>	Anterior cingulate, anterior insula, presupplementary motor areas with nodes in the amygdala, hypothalamus, ventral striatum, thalamus, anterior cingulate cortex, medial temporal network, parahippocampal gyrus, olfactory lobe, and ventral tegmental area	Moderates activity between default mode and central executive networks. Plays a role in processing pain, emotion, reward, and motivation in connection with the limbic system	Akinetic mutism, dementia, schizophrenia
Dorsal attention <sup>70,86–101</sup>	Bilateral network between lateral occipital lobe, precentral sulcus, dorsal portion of superior frontal sulcus, ventral premotor cortex, superior parietal lobe, intraparietal sulcus, and motion-sensitive temporal area	Processes simultaneous inputs to multiple and guides attention and focus to most prominent and active networks	Attentional and sensory disruptions, neuropsychiatric disorders, i.e., schizophrenia
Limbic/Paralimbic <sup>114–116</sup>	Amygdala, thalamus, hypothalamus, hippocampus, prefrontal limbic system, anterior cingulate cortex, medial temporal network, parahippocampal gyrus, olfactory lobe, and ventral tegmental area	Reaction and behavioral responses to stimuli prompting self-protection or reward-seeking behaviors. The emotions associated with the response. Memories formed after the response	Neuropsychiatric disorders such as depression, memory loss, Parkinson's
Visual <sup>125,129–131</sup>	Retina, optic nerves, lateral geniculate nucleus, visual cortex to functional nodes throughout the dorsal and ventral visual pathways	Engage in visual processing, analyze motion, recognize patterns, textures, and faces. Identify location and position of objects in space. Determine function and object permanence. Aid problem solving. Reinforce learned behaviors	Visual deficits

interacting with these networks. Additionally, within the connectome are extensive subnetworks that assist in integrating and relaying signals throughout the brain. Surgical corridors avoiding component white matter tracts

of these key connectome networks may improve surgical outcomes and postoperative cognitive function (► **Fig. 3**, ► **Table 2**). The scope of this review focuses on eight of the networks.



**Fig. 2** Illustration of five nontraditional, large-scale brain networks in the human connectome. The VAN is the only unilateral network and is right-sided. CEN, central executive network; DMN, default mode network; SN, salience network; VAN, ventral attention network; DAN, dorsal attention network.

## Default Mode Network

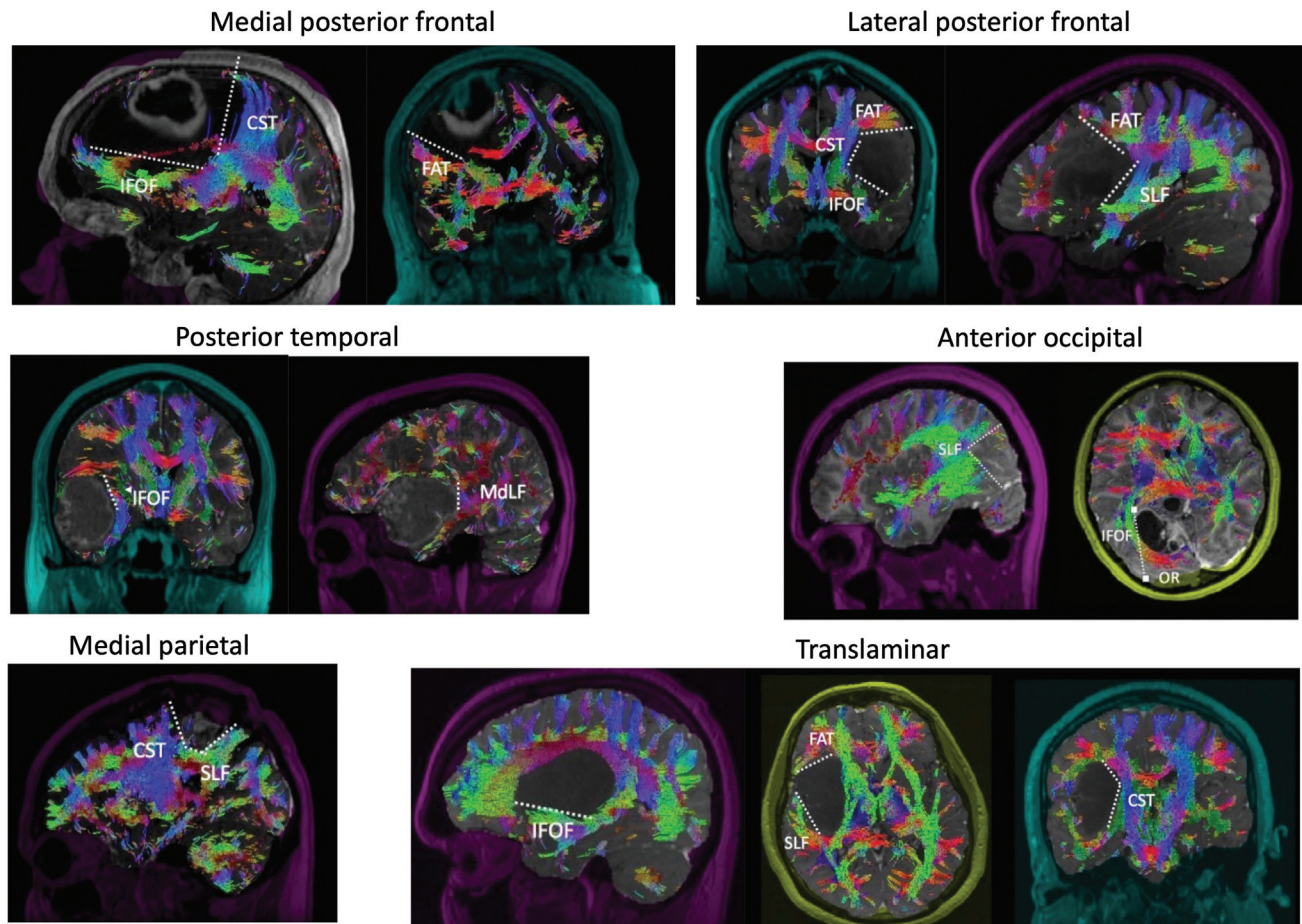
The DMN refers to the cortical networks active without externally directed attention or during activities associated with internalized states.<sup>8</sup> Although historically associated with non-goal-directed behavior or mind wandering,<sup>9</sup> the functional role of the DMN has been the source of continued debate and discussion.<sup>10</sup> Early observers described it as the dominant network during the brain's resting or baseline state that functions in the background when the brain is unstimulated.<sup>11</sup> Use of the term "task-negative network," which was previously used interchangeably with the DMN, has decreased as knowledge of the connectome has shown this definition to be mostly inaccurate.<sup>12</sup> The DMN is understood to be involved in a wide variety of goal-directed activities, including visuospatial planning<sup>13,14</sup> and task-switching.<sup>15</sup> Additional studies have also identified the role of the DMN in complex cognitive processes such as memory, sensory integration, and visual integration.<sup>16</sup> A significant amount of clinical interest in the DMN has developed because of its observable relationship with various brain diseases and nonpathological aspects of aging and neurodevelopment.<sup>17,18</sup> The DMN is involved in mental representations of the self and others, and disruptions in its connectivity are associated with changes in social and emotional processing that occur in disorders such as posttraumatic stress disorder, autism spectrum disorder, and schizophrenia.<sup>19,20</sup>

Multimodal imaging studies of the DMN indicate its structural organization as multiple interacting hubs and subsystems.<sup>21</sup> In 2008, Buckner et al<sup>21</sup> compared studies mapping the DMN to identify the greatest locations of convergence as the medial prefrontal cortex, the posterior

cingulate cortex/retrosplenial cortex, and the inferior parietal lobule. Other subcortical locations are also critical components of the network. An updated review in 2019 by Buckner et al<sup>22</sup> included studies of comparative anatomy using nonhuman primates and rodents that supported the existence of this convergent organization and outlined two primary networks (referred to as "DN-A" and "DN-B"), with separate coupling to the posterior parahippocampal cortex, that together comprise the DMN. The DMN's conceptualization as an interwoven network arrangement has been proposed to account for the contradictions in previously observed discrepancies between functional and structural connectivity.<sup>22</sup> A communicating network model allows a dimensionality layer that consolidates direct and indirect network interactions. In a 2011 review, Sporns<sup>23</sup> noted that this network understanding provides a more dynamic sense of the DMN's place in the connectome, adding that this also explains how aberrations in one network can dysregulate ostensibly unconnected areas of the brain.

The risk of having nontraditional regions of eloquence affected by gliomas may be as high as 93%.<sup>24</sup> These nontraditional areas are extensive throughout the brain's connectome and are involved in higher cognitive functions; their disruption can significantly worsen quality of life by impairing mentalizing and theory of mind in affected individuals.<sup>5</sup> The DMN is often implicated in these nontraditional eloquent areas,<sup>24</sup> in part because of the multiple interacting subsystems within the DMN.<sup>18</sup> Thus, damage to any of its nodes can result in whole-brain functional connectivity decline beyond solely local effects.<sup>25</sup> Additionally, the left parietal and temporal DMN nodes have been implicated as significant contributors to





**Fig. 3** Examples of surgical corridors using white matter tract and connectome data to treat gliomas. The medial posterior frontal, lateral posterior frontal, posterior temporal, anterior occipital, medial parietal, and transinsular surgical corridors are depicted along with key bordering white matter tracts. CST, corticospinal tract; FAT, frontal aslant tract; IFOF, inferior fronto-occipital fasciculus; MdLF, middle longitudinal fasciculus; SLF, superior longitudinal fasciculus. (Reproduced under Creative Commons License from Glenn et al.<sup>176</sup>)

neurocognitive decline when damaged by cytotoxic edema and lesions invading white matter tracts.<sup>26,27</sup> Connectivity loss can also be a consequence of overly extensive resections. Patients with reduced connectivity from regions interacting with the parietal and temporal DMN displayed worse language processing and verbal and visual working memory.<sup>28</sup> In brain tumor patients with akinetic mutism and DMN disruption, restoring DMN synchrony may provide an opportunity to regain function after surgery.<sup>29</sup> The DMN network may play a role in higher cognitive function after glioma surgery, and disruption at any point along the medial prefrontal cortex, cingulate cortex, inferior parietal lobule, and temporal can potentially impact patients.

### Central Executive Network

The CEN—in many ways the opposing network of the DMN—is the network mostly associated with goal-directed behavior and planning, decision-making, and externally directed attention.<sup>30</sup> Other terms commonly used to describe the CEN include the frontoparietal and task-positive network, reflecting its structure and function, respectively.<sup>31</sup> The CEN is heavily involved in working memory and task attention, making it a common area of study in relation to conditions

such as schizophrenia, where these functions are impacted.<sup>31</sup> As expected, based on its wide variety of functions, altered activity in the CEN is observed in most neuropsychiatric disorders.<sup>30</sup> CEN control is prominent during activities requiring emotional regulation and behavioral inhibition, and connective disruption may contribute to affective symptoms in conditions such as social anxiety disorder and obsessive-compulsive disorder.<sup>32,33</sup> Likewise, the amount of CEN structural dysfunction from disease states or injury may correlate with the level of dysfunction, such as the frequency of antisocial behavior.<sup>34</sup> However, CEN abnormalities may not always lead to psychiatric symptoms. For example, decreased CEN activity is also seen in research participants with a family history of psychosis, even when they do not have psychosis themselves.<sup>35</sup>

Originally grouped with the DAN, the anatomy of the CEN has since been primarily localized to the anterior cingulate cortex (ACC), inferior parietal lobe, and posterior middle and inferior temporal gyri.<sup>36,37</sup> As described by Uddin et al.,<sup>38</sup> lesser-known areas associated with the CEN include the dorsal precuneus, posterior inferior temporal lobe, dorsomedial thalamus, and head of the caudate. When considered in isolation, the CEN has a uniquely outsized

**Table 2** Summary of supratentorial surgical corridors and impacted white matter tract pathways

Surgical corridor	Surgical incision	Craniotomy	Involved white matter tracts	Corridor borders	Notes
Medial posterior frontal	Linear unicoronal incision	Frontal	FAT, SLF, cingulum	Posterior: CST, FAT Posterolateral: IFOF Medial: falx Inferior: ventricle Depth: lateral horn of lateral ventricle	Medial, anterior, and superior borders involve the cortical surface
Lateral posterior frontal	Linear unicoronal incision	Frontal	IFOF, SLF, FAT	Posterior: CST, FAT Medial: CST Inferior: IFOF, SLF Depth: IC, CST, basal ganglia	Lateral border involves the cortical surface
Posterior temporal	Linear unicoronal or reverse question mark	Temporal	SLF, arcuate	Superior: IFOF Posterior: SLF Medial: IFOF, MdLF Depth: temporal horn of lateral ventricle	Medial subpial dissection protects the Sylvian fissure and insula
Anterior occipital	Linear or U-shaped occipital	Occipital, supratentorial	SLF, IFOF, optic radiations	Anterolaterally: SLF Lateral: IFOF Depth: atrium of lateral ventricle	Optic radiations wrap around the atria, IFOF can be avoided by staying in medial part of atrium
Medial parietal	Linear or U-shaped	Parietooccipital	SLF, CST, cingulum	Anterior: CST, SLF Inferior: CB, IFOF Lateral: SLF Posterior SLF	Medial and lateral border involves cortical surface
Transinsular	Linear unicoronal or reverse question mark	Frontotemporal	SLF, IFOF	Anteroinferior: IFOF Superior: SLF, CST Anterosuperiorly: FAT Medial: CST Depth: hippocampus	

Abbreviations: CB, cingulate bundle; CST, corticospinal tract; FAT, frontal aslant tract; IC, internal capsule; IFOF, inferior fronto-occipital fasciculus; MdLF, middle longitudinal fasciculus; SLF, superior longitudinal fasciculus.

impact on cognitive function, especially in age-related cognitive decline.<sup>39</sup> Interestingly, alterations in the DMN, rather than the CEN, have been implicated in the cognitive deficits and executive dysfunction seen in patients with glioma.<sup>40,41</sup> The CEN is also an important integrator within the connectome, and a comprehensive understanding of its role must include its relationship with other brain networks. Shortened and unbalanced cross-network CEN interactions, particularly between the CEN and the SN, are thought to underlie conditions such as attention-deficit/hyperactivity disorder.<sup>42</sup> Mindfulness training strengthens this functional connectivity, which may explain some of its beneficial effects on executive control and focus.<sup>43,44</sup> Similarly, adaptive changes in CEN connectivity may also predict response to treatment for depression and posttraumatic stress disorder.<sup>45,46</sup>

Patients with high-grade tumors may be more susceptible to functional impairments because of the relative absence of neuroplasticity; however, predicting patient outcomes after high-grade glioma surgery is challenged by the pathway variability among tumors.<sup>47</sup> Although slow-growing, low-grade tumors display efficient cortical plasticity and remapping around the

lesion, the long-range white matter connections may still be vulnerable.<sup>48</sup> Executive function impairments are among the most frequent impairments after glioma surgery. The CEN can be compromised significantly in patients with diffuse glioma in the frontal, temporal, and parietal lobes. The ability of general processing, critical reasoning, problem-solving, and retaining knowledge and skills through long-term memory can be diminished. In a study of 100 patients by Morell et al,<sup>24</sup> patients with brain tumors and associated neurologic deficits had on average 3.42 affected networks seen on preoperative MRI versus 2.19 affected networks in patients without deficits, and the CEN was most commonly affected (49%), followed by the DMN (43%) and DAN (32%). The frontoparietal cortical areas interconnected by the dorsal perisylvian white matter are important for executive functioning, and damage to the dorsal frontoparietal and intralobar frontal tracts is correlated with worse executive function. Damage to the inferior parietal cortex and its caudal cortical projections leads to verbal fluency impairments.<sup>48</sup> Overall, disruption of the CEN within the ACC, inferior parietal lobule, and temporal gyri can impact attention, cognitive processing, and executive function.

## Saliency Network

The SN comprises the ventrolateral prefrontal cortex (VLPFC), dorsal ACC, and anterior insula.<sup>49,50</sup> The SN is used in modulating activation of the DMN and CEN by detecting the presence of salient stimuli (cognitive, homeostatic, or emotional).<sup>30,49,51–54</sup> Specifically, Goulden et al<sup>52</sup> confirmed that the SN is vital to switching between the CEN and DMN. The ACC and insula maintain reciprocal connectivity to each other and the motor and sensory regions of the brain. Therefore, these regions are ideally located to receive inputs needed to initiate the DMN and CEN switching.<sup>37</sup> This switching process is modulated by specific von Economo neurons found within the SN<sup>55</sup> that have been suggested to rapidly relay simple signals derived from information processed in the ACC and fronto-insular cortex (composed of the VLPFC and anterior insula) to other brain areas.<sup>56</sup> Notably, the SN is particularly weaker in children, and functional and structural maturation of these pathways is critical in brain network maturation.<sup>57</sup> Consequently, damage to vital SN structures, such as the insula, like damage to the DMN and CEN, has been linked to hallucination and psychosis in schizophrenia.<sup>58</sup>

A growing interest in the neurosurgical community has been placed on the SN due to its major white matter bundle, the frontal aslant tract (FAT), being implicated in supplementary motor area (SMA) syndrome.<sup>59,60</sup> When operating in the SMA in brain tumor patients, damage to the FAT can cause SMA syndrome while a network-based approach which spares these fibers results in significantly reduced outcomes.<sup>61</sup> Furthermore, transcallosal FAT connections connecting premotor area to the contralateral premotor and SMA through the corpus callosum can facilitate recovery from SMA syndrome.<sup>62,63</sup> It has been hypothesized that a prefrontal cognitive initiation axis exists, where the DMN (linked by the cingulum) and the SN (linked by the FAT) form a strip across the medial frontal lobe extending up until the SMA, and that this axis is responsible for internally modeling goal initiation.<sup>5</sup> Thus, damage to this axis or the FAT fibers may result in a loss of the initiation of spontaneous, internally motivated actions (e.g., as in abulia and akinetic mutism).<sup>61,64</sup>

The glioma literature has been less clear in understanding the role of SN resting-state function connectivity. One group found no significant differences in SN in glioma ( $n = 12$ ),<sup>65</sup> while another group found decreased SN connectivity ( $n = 13$ ).<sup>66</sup> Neuronal plasticity due to structural reorganization and functional remodeling among these neuronal networks caused by gliomas may alter the clinically observable cognitive manifestations.<sup>67–69</sup> Sparacia et al<sup>70</sup> also evaluated the SN in high-grade supratentorial glioma resection. Although their study showed wide variations in functional connectivity before and after surgery on resting-state fMRI (rs-fMRI), they found a significant correlation between the SN and the language network, the SN and the DMN, and the SN and the sensorimotor network.

A recent study by Yang et al<sup>71</sup> suggested that average SN resting-state functional connectivity was lower in patients

with gliomas, and the severity of functional connectivity loss was correlated with tumor grade and location. Their group also noted increased amplitude of low-frequency fluctuations on rs-fMRI in specific SN regions, notably the right anterior insula. These findings suggest an explanation for the cognitive deficits these patients experience.<sup>72</sup> Notably, their results indicate that tumors located in the frontal and anterior temporal lobes, near vital SN regions, gave rise to lower SN resting-state functional connectivity compared to healthy controls. Tumors in posterior regions did not produce a significant difference. High-grade gliomas produced more striking overall decreases in SN resting-state functional connectivity.<sup>71</sup> This may be due to increased infiltration and disrupted functional reorganization<sup>73,74</sup> or neurovascular uncoupling resulting in false-negative interpretations. Interestingly, their study also demonstrated only slightly decreased SN resting-state functional connectivity in recurrent gliomas ( $n = 28$ ) compared to newly diagnosed lesions. Overall, injury to the SN involving the VLPFC, ACC, anterior insula, and FAT can diminish higher cognitive function, switching between CEN and DMN function and spontaneous activity. However, the role of the SN in gliomas remains to be better uncovered.

## Dorsal Attention Network

The DAN is organized bilaterally, composed of the dorsolateral prefrontal cortex, middle temporal motion complex, superior parietal lobule, intraparietal sulcus, and frontal eye fields within each hemisphere.<sup>75–78</sup> The DAN is necessary to orient focus to a particular task.<sup>79</sup> Therefore, these areas become active when attention is overtly or covertly oriented in space during visual attention (i.e., spatial attention, feature attention, and object attention).<sup>80–84</sup> Corbetta and Shulman<sup>77</sup> also suggested that the DAN is vital in goal-directed top-down processing. Rajan et al<sup>85</sup> suggested the organization of top-down attentional control signals within the DAN, arguing against previously proposed models of the DAN (domain-general and supramodal models). They proposed a functional microstructure of attentional control mechanisms within the DAN that could serve as precise top-down projections to sensory structure. These projections may function as part of stimulus processing requirements according to behavioral goals.

The DAN is involved in multiple diseases, including gliomas. In 2021, Tordjman et al<sup>86</sup> aimed to understand the disruption of the DAN (in addition to DMN and CEN) using seed-based connectivity analysis and independent component analysis. Their study indicated that functional connectivity in the DAN is altered in glioma patients at rest, with consistently increased connectivity in the occipital region and medial prefrontal cortex and decreased connectivity in the subcallosal cortex and anterior cingulate gyrus.

Sparacia et al<sup>70</sup> evaluated the use of rs-fMRI in detecting this altered functional connectivity after high-grade glioma resection. rs-fMRI has been demonstrated to be useful in preoperatively localizing the eloquent cortex in an effort to

reduce surgery-induced neurologic deficits.<sup>87-90</sup> Among their cohort undergoing left temporal glioblastoma resection, postoperative rs-fMRI revealed that functional connectivity tended to decrease in the DAN, demonstrating a functional disconnection.<sup>70</sup> This decrease in functional connectivity was more dramatic when compared with the sensorimotor network, language network, and DMN in the same patients. These data confirm that tumor presence can impact the connectivity of the DAN.

Patients with damage to their right-sided attentional networks, including the DAN, often experience left visual neglect, behaving as though the left part of the world does not exist.<sup>91</sup> This neglect may improve with time, although slowed response times to targets in their left visual field may persist.<sup>92</sup> A study of patients with low-grade glioma with lesions producing neglect (i.e., visual) confirmed the disconnection of the intermediate branch of the superior longitudinal fasciculus, the segment connecting the caudal node of the ventral attentional network to the rostral node of the dorsal network.<sup>93-95</sup>

Preoperative brain plasticity and reorganization of the DAN and other attention networks in the setting of a low-grade glioma may contribute to a patient's normal results on standard neuropsychological assessments, as surrounding regions may take on the eloquent roles and function of the invaded tissue.<sup>96-101</sup> This can be seen in patients with low-grade glioma undergoing surgical resection who receive intraoperative electrical stimulation to assist in surrounding white matter tract preservation. Even during acute-phase postoperative deficits, complete recovery among these patients was possible within 3 months.<sup>102</sup> In sum, damage to the DAN within the prefrontal cortex, temporal lobe, superior parietal lobule, intraparietal sulcus, and frontal eye fields inhibits attention orientation and activity, which may impair higher cognitive function in glioma patients.

## Limbic/Paralimbic Network

The limbic system is one of the earliest described networks. In 1878, Broca suggested the limbic system's role was primarily olfactory.<sup>103,104</sup> It was not until Papez discovered the "Papez circuit" that the role of the limbic network expanded to include memory and emotional processing. The hypothalamus, mammillary bodies, and fornix were identified as limbic structures as well as the amygdala, septal area, hippocampus, and cingulate cortex.<sup>104</sup> Moreover, the functions of the limbic system were further understood to include regulation of homeostatic, autonomic, and neuroendocrinological functions.<sup>103-105</sup> The limbic system also plays a role in anxiety and aggression as well as reward and addiction.<sup>103,106</sup>

Because of the extensive role of the limbic system, its pathways are far-reaching and extend between most of the integral cortices and nodes in the brain. The brainstem and forebrain have limbic nodes with projections to higher cortical areas that contribute to behavioral and action modulation in response to internal and external

stimuli.<sup>103,106</sup> As a network involving some of the most primitive brain structures, the foundation of the limbic system is promoting survival through regulating responses to external and internal stimuli. The brainstem and forebrain nodes of the limbic system govern regulatory processes such as respiration and contribute to how we adapt to stressors including emotional, immune, and cognitive stimuli.<sup>105</sup> Classically, the "fight or flight" response is attributed to the limbic network through stimulation of fear, arousal, and behavioral responses. Arousal is stimulated in the median and dorsal raphe and locus coeruleus and emotion in the amygdala.<sup>105</sup> There are also tracts from the orbitofrontal cortex to the amygdala involved in information sharing to regulate emotion and reward.<sup>107</sup>

White matter tracts run between limbic structures and the DMN, SN, and CEN to modulate functional processes such as sensory perception, motor commands, spatial reasoning, and decision-making.<sup>108</sup> These tracts begin in nodes at areas including the pons, medulla, midbrain, and travel to the cerebral cortex to create a central homeostatic network. Extrinsic threats and intrinsic metabolic derangement signals are processed, and information is relayed. Interaction with the visual network, sensorimotor network, and CEN results in heightened attention, arousal, and visceral and somatic motor defenses.<sup>105</sup> The limbic system is critical to spatial and long-term memory storage via its hippocampal involvement and memory processing during sleep.<sup>4,106,109</sup> The ventral tegmental area is another important area within the limbic network that plays a role in motivation, reward, and arousal as well as possesses dopaminergic signaling. It has connections to the parabrachial pigmented nucleus and higher cortical regions serving as relay between autonomic and limbic networks to the cortex and other areas. The outcomes of the signal integration are involved in decision-making and reward-seeking behaviors.<sup>110</sup> The cingulate cortex is also part of the limbic network,<sup>111</sup> and its subdivisions including the middle, anterior, and posterior divisions are involved in action-outcome decisions (emotion and object recognition, respectively).<sup>112</sup>

As can be inferred, there is no singular function to each structure within the limbic network, and there are many integrated roles and shared connectivity to govern a diverse range of functions.<sup>111</sup> The significance of the functional connectivity of structures within the limbic network can be best illustrated when considering the effects of damage to different pathways. In patients with damage to the ACC, impairment in action-outcome learning and reward-seeking behaviors has been documented. Reward-seeking behaviors relay signals to the hippocampus to form episodic memories, and deficits will be seen if this connectivity is disrupted.<sup>113</sup>

Gliomas originating throughout multiple cortices can influence limbic connectivity. In a study of rs-fMRI after cingulate tumor resection, connectomic analysis found that the networks potentially disturbed by the approach and surgical corridor contributed to postoperative development of major depressive disorder. Not only is



tumor location an important consideration when identifying adverse outcomes of treatment but also the surgical approach or penumbra affected by radiation can be vital to normal functional connectivity. Avoiding limbic network disruption and connectomic mapping may be useful in avoiding these complications but require further clinical correlation.<sup>114</sup> The insula is a frequent site for primary and secondary tumor resection due to its critical network role and proximity to deeper subcortical regions.

Interestingly, glioma spread within the insula follows stereotypical anatomic patterns, which have been used as prognostication tools. One study found insular gliomas tend to involve the olfactocentric limbic girdle and that those in the hippocampal centric limbic girdle are associated with poorer prognosis.<sup>115</sup> Although surgical approaches to the anterior insula have generally been more favorable in avoiding neurological deficit than posterior insular resection, integrating connectomics and functional mapping may improve outcomes and the extent of resection.<sup>116</sup> Overall, while damage to the limbic structures has a known impact on memory, many recent studies support its role in cognitive processing, arousal, and coordination with other brain networks.

## Visual Network

The visual system controls sight and visual processing, but its coordination with other networks is much more complex.<sup>117</sup> As one of the earliest established networks, the basic pathway of the visual system involves tracts running from the retina, optic nerves, and lateral geniculate nuclei to the visual cortex in the occipital lobe.<sup>118</sup> There are multiple nodes within the visual cortex with unique roles, including V1, which processes the initial signals from the retina, and V2 and V3, which receive relayed information from V1.<sup>118</sup> Many processes in the visual network such as facial recognition and body recognition are signaled along distinct pathways.<sup>119</sup> The dorsal visual circuit is responsible for object perception, global motion perception, and visual stimulus processing, while independently the ventral circuit has a greater role in recognition and is closely integrated with the limbic system for facial, body, and place recognition. The visual system has key relationships with the DAN and sensorimotor network because vision is integral for movement coordination and visuospatial awareness.<sup>118</sup>

The limbic system, SN, and visual network have extensive functional connectivity, and integrating these systems plays an important role in eliciting emotion and feelings of empathy.<sup>120</sup> Visual stimuli and memory require signal sharing along pathways in these networks.<sup>121</sup> There are also strong functional connections among nodes in the visual system, amygdala, subcortical network, and hippocampus. This can be seen in studies using verbal versus visual stimuli to elicit memory retrieval and emotional responses. Visual cues engage with many limbic structures to modulate emotional processes.<sup>122</sup> The relationships among the visual system, memory, and emotion are also appreciated in instances of damage to the

occipital lobe. Visual processing of emotional stimuli travels between subcortical structures and nodes in the amygdala and can be affected by destruction of V1 nodes in the visual system.<sup>123</sup> Further associations between the limbic and visual networks are recognized with respect to survival and processing of threats. Fear due to implicit and explicit stimuli elicits different responses because of the activation of different pathways. External stimuli from visual cues can send signals through the parahippocampal gyrus and pulvinar, whereas implicit fear activates the cerebellum and amygdala then ascends to the cortex.<sup>124</sup>

The dorsal pathway of the visual network is involved in global motion perception<sup>125,126</sup> and is heavily modulated by spatial attentiveness.<sup>127,128</sup> The ventral network tracts relay information for object recognition.<sup>128</sup> The sensorimotor system is also closely integrated with the visual system. For example, children with autism spectrum disorder with greater discrepancies in visual-sensorimotor functional connectivity can show greater social deficits.<sup>125,129</sup> Hypoconnectivity between the DMN and visual and attention networks is also seen in autism spectrum disorder. Visual pathway integration into wider cortical networks remains to be explored in glioma treatment and postsurgical patients.

Focal disruption of the DMN can result in deficits in visual processing. The precuneus of the DMN is an intersection of multiple other networks such that tumors in this region lead to compensatory hyperconnectivity in tracts of the SN, DAN, and visual network.<sup>130</sup> The connectome redistribution of adjacent and remote areas to the tumor region suggests compensatory neuroplasticity that may play a role in function preservation after tumor excision.<sup>131</sup>

## Sensorimotor Network

First discovered in the 1870s, the sensorimotor network was identified in dogs by Eduard Hitzig alongside Gustav Fritsch, who observed that the electrical stimulation of the dog brain cortex contributed to limb movements.<sup>132</sup> Further classification of facial and upper extremity movement after stimulation of brain cortices was then conducted by David Ferrier.<sup>133</sup> The sensorimotor connectome encompasses brain regions responsible for controlling feeling, audition, and motor functions to integrate sensation inputs into smooth and appropriate coordinated movement and reactions. At a molecular level, these correspond to electrical signals (i.e., action potentials) that propagate physical responses.

Surgeons are especially careful when operating around the primary motor and somatosensory cortices. These brain regions include the primary motor and sensory cortex (and respective premotor and parietal lobe cortices), subcortical gray motor areas (e.g., thalamus, caudate, putamen, pallidum), cingulate cortex, inferior occipital gyrus, and SMA.<sup>134-137</sup>

The developmental trajectories of these topological modifications are system specific: sensorimotor systems develop adult-like topological properties by late childhood,

while integral connection topology of connected brain regions continues to develop into early adulthood.<sup>138</sup> It has been shown that the primary motor, somatosensory, auditory, and visual cortices demonstrate interregional plasticity that may impact recovery after glioma surgery.<sup>139</sup> Although this plasticity is greatest in children, it can occur even in adulthood; for instance, fine motor skills/movements lead to cortical reorganization in sensorimotor and related learning connectomes.<sup>140</sup> Interestingly, this motor learning process also occurs during sleep, particularly during the active rapid eye movement stage of sleep, which improves and maintains the sensorimotor connectome.<sup>141</sup>

Increased resolution and accuracy of these underlying neural connections has led to the discovery and new understanding of functional motor and sensory areas.<sup>142</sup> Primary sensorimotor areas contain nodes responsible for tactile and sensory stimulus processing, including the fine motor movements that proceed, accounting for implications in visual learning: (1) The cingulate cortex is responsible for motor planning and coordinates movement of muscles with the SMA and the spinal cord. (2) The SMA is implicated in post-visual cue processing (i.e., goal-oriented behavior coordination); further, this process appears to have directional functionality. (3) The dorsal premotor cortex participates in association of information cues to bodily movements. (4) The ventral premotor cortex is involved in active movements and their associated learned behaviors and also includes the language processing center, Broca's area.<sup>134,143–145</sup>

The sensorimotor connectome has functional significance and relationship with the hearing/vestibular, visual, and limbic systems, as well as the SN, CEN, DAN, and DMN.<sup>146–152</sup> When these systems are dysregulated by too much or too little activity, physical and mental illnesses can ensue.<sup>153</sup>

Diffuse low-grade gliomas are often found in functional brain regions, such as the frontal lobe involving the SMA. Because of the relationship with other connectomes and subnetworks, indirect implications of sensorimotor dysregulation are possible, although many patients can have mild to no deficits. This is likely related to the progressive slow-growing course of these tumors giving time for remapping. Neuroplasticity of the connectomes surrounding tumors may manifest in different ways such as remapping within the tumor, redistribution around the tumor, remote area compensation, and contralateral hemisphere compensation.<sup>130</sup> This directly contrasts high-grade tumors, or acute pathology (e.g., infarcts), where abrupt onset leads to neuronal cell death.

The handling of low-grade versus high-grade gliomas can differ with the knowledge that networks affected by low-grade tumors have greater neuroplastic potential to remap.<sup>154</sup> Treating gliomas with a connectome-based resection can lead to resection of structures previously thought of as inoperable while yielding good neurological recovery. Mapping has led to refinement of awake surgery.<sup>155</sup> The philosophy has evolved from resecting diffuse gliomas from oncological boundaries to maximal safe resection according to functional limits.<sup>156</sup> rs-fMRI can be reliably

used to map sensorimotor function preoperatively.<sup>157</sup> As we look to the future, advances in connectomic mapping with real-time function monitoring with awake surgery for gliomas in the motor strip and sensorimotor regions will be essential.<sup>154</sup> Nevertheless, the determination of which brain areas should be targeted for gross total resection in glioma patients is multifaceted and highly individualized. It depends on numerous factors (e.g., tumor size, location, patient goals, primary vs. secondary recurrence, and patient age).

## Language Network

The language connectome is mainly responsible for articulating and delivering verbal and written thought while simultaneously participating in the comprehension and processing of received input.<sup>158,159</sup> Moreover, the language connectome is not understood to be one of the seven main human connectomes because of the many required integrations with other brain networks and rich connectivity along with postprocessing that is essential for appropriate function (i.e., there is no particular brain region responsible for these actions).<sup>160</sup> Uniquely, language is a coveted network that requires multiple dependent and independent connectomes in precise orchestration to achieve as simple an output as “hello.”<sup>143</sup>

As one of the connectomes that has been described for centuries, the language network has received special attention from surgeons because of its rich connections with the visual and sensorimotor connectomes—particularly, protecting this connectome is essential to preserving independent function of language and associated processing but also has implications in vision and movement.<sup>161</sup> The associated brain regions of the language connectome include the lateral prefrontal cortex, left temporal regions, left dorsomedial prefrontal cortex, inferior frontal gyrus, superior temporal cortex, and anteroinferior left temporal gyrus.<sup>162</sup> These anatomic connections implicate connectivity with the visual, auditory, and sensorimotor connectomes, which describe functional significance for hearing and listening, reading, and speech. Furthermore, connection of the language connectome with the CEN connectome implicates a task specification role, connection with the DAN connectome implicates focus, and connection with the DMN connectome implicates contemplation.<sup>162</sup> As we further develop understanding of this involved connectome, novel implications regarding verbal and written word delivery, comprehension, and language processing may help us understand deficits and find treatment options.

Because of recent connectomic analysis, the concept that language is primary left-sided is being adapted to a new dorsal-ventral stream model, which has recently been further improvised to describe pairs of dorsal and ventral streams, connecting the prefrontal and temporal areas via connections between the temporal and premotor cortices as well as the temporal cortex and Broca's area, respectfully (e.g., patients with left-sided slow-growing lesions may develop right-sided language function in response

to localized pathology).<sup>163,164</sup> These new insights provide understanding into the language connectome that challenge traditionally accepted methodologies and have the potential to provide novel breakthroughs in treatment and our understanding of neuroscience.

Identified in the early 1860s, Broca's area in the left posterior inferior frontal gyrus was defined as functional unit of word and speech production; this designation was later reclassified in 1874 by Carl Wernicke who identified another brain region located in the left posterior superior temporal gyrus (i.e., Wernicke's area) that impacted language function.<sup>143,159</sup> We now know the functional significance of both these regions with respect to word recognition and phonological action and presentation.<sup>158,165</sup> The connectomic relationship between the two brain regions has led to over a century of significant research.<sup>161</sup> This led to identifying the arcuate fasciculus and other white matter tracks that connect areas of the language connectome.<sup>166</sup> More recently, an area known as 55b was described in the left dorsal premotor cortex, which contains few myelin-surrounded neurons and was shown to be consistently active during language input (i.e., listening).<sup>162,167</sup>

Recent advances in anatomic understanding of the language connectome have refined the key brain regions involved: the lateral prefrontal cortex, inferior temporal gyrus, anterior portion of the left inferior temporal gyrus, left temporal regions extending outside of Wernicke's area, left dorsal-medial prefrontal cortex, and superior temporal cortex.<sup>168,169</sup> Of note is that most of the language connectome resides on the left brain; however, right brain interactions have been identified during particular language processes (e.g., metaphor comprehension), indicating the potential language-driven task-dependent activation of the connectome and its associations.<sup>168</sup> Recent discovery of two language hubs has implicated new anatomic brain regions of importance, especially during surgery, due to their direct and anatomical relationship with language connectome components.<sup>170</sup>

One of the common insults to occur to the language connectome occurs following a lesion or injury. In particular, when this pathology occurs between functional connections (i.e., white and/or gray matter tracts), this may lead to core cognitive deficits, language difficulties, and comprehension issues.<sup>171</sup> Other consequences with damage include neurological decline and aphasia, including difficulties in recognition and naming,<sup>170,172</sup> alexia, and agraphia; uniquely, agraphia has implications with language processing, motor planning, and visual perception.<sup>167</sup> Similarly, after insult to either the left hemisphere or white matter tracts of the language connectome, aphasia has been demonstrated to cause difficulty with reading, writing, listening, and speaking.<sup>167</sup>

Gliomas affecting speech and language can be diverse because of the complex network that involves multiple cortices and extensive functional connectivity. In a cohort of patients with left-sided cerebral glioma, Yuan et al<sup>173</sup> used a machine-learning prediction model to discover how whole brain functional connectivity was altered by tumors in the

region of the language network. Variability in the degree of impairment was seen in high- versus low-grade glioma, and long-distance lesion effects were appreciated in the reorganization of different functional networks. Alterations in connectivity seen on fMRI were predictive of language deficits, with changes in the temporal and prefrontal regions predictive of impairments in low- and high-grade glioma. Changes in the cerebellum and limbic system were also predictive of deficits in only high-grade glioma.<sup>173</sup>

In a study of plasticity of the language and semantic network, van Dokkum et al<sup>174</sup> found that focusing on changes in one network affected by a tumor may not be suitable because many connectomes work in concert with one another. While analyzing picture naming pre- and postoperatively in patients with low-grade glioma compared with controls, they found extensive adaptive plasticity that may confer some protection to tumor infiltration. Decreased connectivity of middle temporal gyrus with superior temporal gyrus and inferior parietal lobe was compensated with increased input from right to left inferior parietal lobe, which is connected to left inferior temporal gyrus. Decreased connectivity between left middle frontal gyrus and left parahippocampal gyrus was associated with lower scores on picture naming.<sup>174</sup>

Awake brain surgery provides for the ability of language monitoring during surgical manipulation to the brain. Still, there are limitations to the use of this surgical method because of the widespread functional significance of the language connectome. Nonverbal deficits that either could not or were not being monitored during awake surgery can appear postoperatively.<sup>161</sup> Using patient-specific brain maps, connectomics can pinpoint areas of specific function and help personalize operating and therapeutic decisions for individual patients. This level of granularity further increases surgical precision regarding understanding areas of language function, allowing for better surgical planning (i.e., the route of least connectomic disruption), and ability to predict for postoperative deficits. Age also has implications with regard to the language connectome; for example, children with congenital damage to the left hemisphere may show age-appropriate language development and a relatively lower incidence of the aphasic symptoms in contrast to adults who sustain similar brain damage in these areas later in life.<sup>175</sup>

## Conclusion

This study highlights many of the known connectomic networks and their structural areas and functional impacts in patients with gliomas. The literature regarding the impact of gliomas on the structure and function of these neural networks remains an area of active exploration. Future studies aiming to understand these networks will be important to better identify the critical components of a network and predict patient outcome after treatment. These can include evaluating subsets of patients, tumor locations, and standardized surgical approaches. In addition, exploration of the impact of tumor subtypes and mutational patterns on connectomic disruption remains

to be explored. And lastly, detailed preoperative and postoperative neuropsychological testing and the impact of resection on specific pattern changes remains to be seen. The new insight into the human connectome offers an exciting future for further understanding the function of the brain and making surgical treatment gentler and safer.

#### Conflict of Interest

None declared.

#### Acknowledgment

We thank Kristin Kraus for editorial assistance and Omniscient Neurotechnology (o8t) for their illustrations as well as expertise and guidance in project visualization.

#### References

- Kirkman MA, Hunn BHM, Thomas MSC, Tolmie AK. Influences on cognitive outcomes in adult patients with gliomas: a systematic review. *Front Oncol* 2022;12:943600
- Sughrue M. What is Connectomics? <https://www.o8t.com/blog/connectomics>. Published 2022
- Shah HA, Mehta NH, Saleem MI, D'Amico RS. Connecting the connectome: a bibliometric investigation of the 50 most cited articles. *Clin Neurol Neurosurg* 2022;223:107481
- Fan Q, Eichner C, Afzali M, et al. Mapping the human connectome using diffusion MRI at 300 mT/m gradient strength: Methodological advances and scientific impact. *Neuroimage* 2022;254:118958
- Dadario NB, Sughrue ME. Should neurosurgeons try to preserve non-traditional brain networks? A systematic review of the neuroscientific evidence. *J Pers Med* 2022;12(04):587
- Shahab QS, Young IM, Dadario NB, et al. A connectivity model of the anatomic substrates underlying Gerstmann syndrome. *Brain Commun* 2022;4(03):fcac140
- Poologaindran A, Profyris C, Young IM, et al. Interventional neurorehabilitation for promoting functional recovery post-craniotomy: a proof-of-concept. *Sci Rep* 2022;12(01):3039
- Raichle ME. The brain's default mode network. *Annu Rev Neurosci* 2015;38:433–447
- Horn A, Ostwald D, Reiser M, Blankenburg F. The structural-functional connectome and the default mode network of the human brain. *Neuroimage* 2014;102(Pt 1):142–151
- Fair DA, Cohen AL, Dosenbach NU, et al. The maturing architecture of the brain's default network. *Proc Natl Acad Sci U S A* 2008;105(10):4028–4032
- Raichle ME, MacLeod AM, Snyder AZ, Powers WJ, Gusnard DA, Shulman GL. A default mode of brain function. *Proc Natl Acad Sci U S A* 2001;98(02):676–682
- Spreng RN. The fallacy of a “task-negative” network. *Front Psychol* 2012;3:145
- Elton A, Gao W. Task-positive functional connectivity of the default mode network transcends task domain. *J Cogn Neurosci* 2015;27(12):2369–2381
- Vatanserver D, Manktelow A, Sahakian BJ, Menon DK, Stamatakis EA. Default mode network engagement beyond self-referential internal mentation. *Brain Connect* 2018;8(04):245–253
- Crittenden BM, Mitchell DJ, Duncan J. Recruitment of the default mode network during a demanding act of executive control. *eLife* 2015;4:e06481
- Aguilar DD, McNally JM. Subcortical control of the default mode network: role of the basal forebrain and implications for neuropsychiatric disorders. *Brain Res Bull* 2022;185:129–139
- Mohan A, Roberto AJ, Mohan A, et al. The significance of the default mode network (DMN) in neurological and neuropsychiatric disorders: a review. *Yale J Biol Med* 2016;89(01):49–57
- Tanglay O, Young IM, Dadario NB, et al. Anatomy and white-matter connections of the precuneus. *Brain Imaging Behav* 2022;16(02):574–586
- Li W, Mai X, Liu C. The default mode network and social understanding of others: what do brain connectivity studies tell us. *Front Hum Neurosci* 2014;8:74
- Molnar-Szakacs I, Uddin LQ. Self-processing and the default mode network: interactions with the mirror neuron system. *Front Hum Neurosci* 2013;7:571
- Buckner RL, Andrews-Hanna JR, Schacter DL. The brain's default network: anatomy, function, and relevance to disease. *Ann N Y Acad Sci* 2008;1124(01):1–38
- Buckner RL, DiNicola LM. The brain's default network: updated anatomy, physiology and evolving insights. *Nat Rev Neurosci* 2019;20(10):593–608
- Sporns O. The human connectome: a complex network. *Ann N Y Acad Sci* 2011;1224(01):109–125
- Morell AA, Eichberg DG, Shah AH, et al. Using machine learning to evaluate large-scale brain networks in patients with brain tumors: traditional and non-traditional eloquent areas. *Neurooncol Adv* 2022;4(01):vdac142
- Zhang H, Shi Y, Yao C, et al. Alteration of the intra- and cross-hemisphere posterior default mode network in frontal lobe glioma patients. *Sci Rep* 2016;6:26972
- Lin YH, Dadario NB, Hormovas J, et al. Anatomy and white matter connections of the superior parietal lobule. *Oper Neurosurg (Hagerstown)* 2021;21(03):E199–E214
- Briggs RG, Tanglay O, Dadario NB, et al. The unique fiber anatomy of middle temporal gyrus default mode connectivity. *Oper Neurosurg (Hagerstown)* 2021;21(01):E8–E14
- Kocher M, Jockwitz C, Caspers S, et al. Role of the default mode resting-state network for cognitive functioning in malignant glioma patients following multimodal treatment. *Neuroimage Clin* 2020;27:102287
- Stephens TM, Young IM, O'Neal CM, et al. Akinetic mutism reversed by inferior parietal lobule repetitive theta burst stimulation: Can we restore default mode network function for therapeutic benefit? *Brain Behav* 2021;11(08):e02180
- Menon V. Large-scale brain networks and psychopathology: a unifying triple network model. *Trends Cogn Sci* 2011;15(10):483–506
- Littow H, Huossa V, Karjalainen S, et al. Aberrant functional connectivity in the default mode and central executive networks in subjects with schizophrenia – a whole-brain resting-state ICA study. *Front Psychiatry* 2015;6:26
- Qiu C, Liao W, Ding J, et al. Regional homogeneity changes in social anxiety disorder: a resting-state fMRI study. *Psychiatry Res* 2011;194(01):47–53
- Chen Y, Meng X, Hu Q, et al. Altered resting-state functional organization within the central executive network in obsessive-compulsive disorder. *Psychiatry Clin Neurosci* 2016;70(10):448–456
- Ryan NP, Catroppa C, Hughes N, et al. Executive function mediates the prospective association between neurostructural differences within the central executive network and anti-social behavior after childhood traumatic brain injury. *J Child Psychol Psychiatry* 2021;62(09):1150–1161
- Jukuri T, Kiviniemi V, Nikkinen J, et al. Central executive network in young people with familial risk for psychosis – the Oulu Brain and Mind Study. *Schizophr Res* 2015;161(2-3):177–183
- Vincent JL, Kahn I, Snyder AZ, Raichle ME, Buckner RL. Evidence for a frontoparietal control system revealed by intrinsic functional connectivity. *J Neurophysiol* 2008;100(06):3328–3342



- 37 Dosenbach NU, Visscher KM, Palmer ED, et al. A core system for the implementation of task sets. *Neuron* 2006;50(05):799–812
- 38 Uddin LQ, Yeo BTT, Spreng RN. Towards a universal taxonomy of macro-scale functional human brain networks. *Brain Topogr* 2019;32(06):926–942
- 39 Madole JW, Ritchie SJ, Cox SR, et al. Aging-sensitive networks within the human structural connectome are implicated in late-life cognitive declines. *Biol Psychiatry* 2021;89(08):795–806
- 40 Zhang X, Zhang G, Wang Y, et al. Alteration of default mode network: association with executive dysfunction in frontal glioma patients. *J Neurosurg* 2022;\*\*\*:1–10
- 41 Schouwenaars IT, de Dreu MJ, Rutten GM, Ramsey NF, Jansma JM. A functional MRI study of presurgical cognitive deficits in glioma patients. *Neurooncol Pract* 2020;8(01):81–90
- 42 Cai W, Chen T, Szegletes L, Supekar K, Menon V. Aberrant time-varying cross-network interactions in children with attention-deficit/hyperactivity disorder and the relation to attention deficits. *Biol Psychiatry Cogn Neurosci Neuroimaging* 2018;3(03):263–273
- 43 Teper R, Segal ZV, Inzlicht M. Inside the mindful mind: how mindfulness enhances emotion regulation through improvements in executive control. *Curr Dir Psychol Sci* 2013;22(06):449–454
- 44 Bremer B, Wu Q, Mora Álvarez MG, et al. Mindfulness meditation increases default mode, salience, and central executive network connectivity. *Sci Rep* 2022;12(01):13219
- 45 Abdallah CG, Averill CL, Ramage AE, et al; STRONG STAR Consortium. Reduced salience and enhanced central executive connectivity following PTSD treatment. *Chronic Stress (Thousand Oaks)* 2019;3:2470547019838971
- 46 Ge R, Downar J, Blumberger DM, Daskalakis ZJ, Lam RW, Vila-Rodriguez F. Structural network integrity of the central executive network is associated with the therapeutic effect of rTMS in treatment resistant depression. *Prog Neuropsychopharmacol Biol Psychiatry* 2019;92:217–225
- 47 Liu L, Zhang H, Reikik I, Chen X, Wang Q, Shen D. Outcome prediction for patient with high-grade gliomas from brain functional and structural networks. *Med Image Comput Comput Assist Interv* 2016;9901:26–34
- 48 Cochereau J, Lemaitre AL, Wager M, Moritz-Gasser S, Duffau H, Herbet G. Network-behavior mapping of lasting executive impairments after low-grade glioma surgery. *Brain Struct Funct* 2020;225(08):2415–2429
- 49 Seeley WW, Menon V, Schatzberg AF, et al. Dissociable intrinsic connectivity networks for salience processing and executive control. *J Neurosci* 2007;27(09):2349–2356
- 50 Briggs RG, Young IM, Dadario NB, et al. Parcellation-based tractographic modeling of the salience network through meta-analysis. *Brain Behav* 2022;12(07):e2646
- 51 Chand GB, Wu J, Hajjar I, Qiu D. Interactions of the salience network and its subsystems with the default-mode and the central-executive networks in normal aging and mild cognitive impairment. *Brain Connect* 2017;7(07):401–412
- 52 Goulden N, Khusnulina A, Davis NJ, et al. The salience network is responsible for switching between the default mode network and the central executive network: replication from DCM. *Neuroimage* 2014;99:180–190
- 53 Uddin LQ. Salience processing and insular cortical function and dysfunction. *Nat Rev Neurosci* 2015;16(01):55–61
- 54 O'Neill A, Mechelli A, Bhattacharyya S. Dysconnectivity of large-scale functional networks in early psychosis: a meta-analysis. *Schizophr Bull* 2019;45(03):579–590
- 55 Watson KK, Jones TK, Allman JM. Dendritic architecture of the von Economo neurons. *Neuroscience* 2006;141(03):1107–1112
- 56 Allman JM, Watson KK, Tetreault NA, Hakeem AY. Intuition and autism: a possible role for Von Economo neurons. *Trends Cogn Sci* 2005;9(08):367–373
- 57 Uddin LQ, Supekar KS, Ryali S, Menon V. Dynamic reconfiguration of structural and functional connectivity across core neurocognitive brain networks with development. *J Neurosci* 2011;31(50):18578–18589
- 58 Manoliu A, Riedl V, Zherdin A, et al. Aberrant dependence of default mode/central executive network interactions on anterior insular salience network activity in schizophrenia. *Schizophr Bull* 2014;40(02):428–437
- 59 Palmisciano P, Haider AS, Balasubramanian K, et al. Supplementary motor area syndrome after brain tumor surgery: a systematic review. *World Neurosurg* 2022;165:160–171.e2
- 60 Dadario NB, Tabor JK, Silverstein J, Sun XR, DAMICO RS. Postoperative focal lower extremity supplementary motor area syndrome: case report and review of the literature. *Neurodiagn J* 2021;61(04):169–185
- 61 Briggs RG, Allan PG, Poologaindran A, et al. The frontal aslant tract and supplementary motor area syndrome: moving towards a connectomic initiation axis. *Cancers (Basel)* 2021;13(05):1116
- 62 Baker CM, Burks JD, Briggs RG, et al. The crossed frontal aslant tract: a possible pathway involved in the recovery of supplementary motor area syndrome. *Brain Behav* 2018;8(03):e00926
- 63 Tuncer MS, Fekonja LS, Ott S, et al. Role of interhemispheric connectivity in recovery from postoperative supplementary motor area syndrome in glioma patients. *J Neurosurg* 2022;139(02):1–10
- 64 Darby RR, Joutsa J, Burke MJ, Fox MD. Lesion network localization of free will. *Proc Natl Acad Sci U S A* 2018;115(42):10792–10797
- 65 Maesawa S, Bagarinao E, Fujii M, et al. Evaluation of resting state networks in patients with gliomas: connectivity changes in the unaffected side and its relation to cognitive function. *PLoS One* 2015;10(02):e0118072
- 66 Liu D, Hu X, Liu Y, et al. Potential intra- or cross-network functional reorganization of the triple unifying networks in patients with frontal glioma. *World Neurosurg* 2019;128:e732–e743
- 67 Zhang N, Xia M, Qiu T, et al. Reorganization of cerebro-cerebellar circuit in patients with left hemispheric gliomas involving language network: a combined structural and resting-state functional MRI study. *Hum Brain Mapp* 2018;39(12):4802–4819
- 68 Gupta L, Gupta RK, Postma AA, et al. Advanced and amplified BOLD fluctuations in high-grade gliomas. *J Magn Reson Imaging* 2018;47(06):1616–1625
- 69 Liu D, Chen J, Hu X, et al. Contralateral homotopic functional plasticity in patients with temporal glioma. *J Neurosurg* 2020;134(02):1–9
- 70 Sparacia G, Parla G, Lo Re V, et al. Resting-state functional connectome in patients with brain tumors before and after surgical resection. *World Neurosurg* 2020;141:e182–e194
- 71 Yang J, Gohel S, Zhang Z, Hatzoglou V, Holodny AI, Vachha BA. Glioma-induced disruption of resting-state functional connectivity and amplitude of low-frequency fluctuations in the salience network. *AJNR Am J Neuroradiol* 2021;42(03):551–558
- 72 Bergo E, Lombardi G, Guglieri I, Capovilla E, Pambuku A, Zagone V. Neurocognitive functions and health-related quality of life in glioblastoma patients: a concise review of the literature. *Eur J Cancer Care (Engl)* 2019;28(01):e12410
- 73 Esposito R, Mattei PA, Briganti C, Romani GL, Tartaro A, Caulo M. Modifications of default-mode network connectivity in patients with cerebral glioma. *PLoS One* 2012;7(07):e40231
- 74 Harris RJ, Bookheimer SY, Cloughesy TF, et al. Altered functional connectivity of the default mode network in diffuse gliomas measured with pseudo-resting state fMRI. *J Neurooncol* 2014;116(02):373–379

- 75 Vossel S, Geng JJ, Fink GR. Dorsal and ventral attention systems: distinct neural circuits but collaborative roles. *Neuroscientist* 2014;20(02):150–159
- 76 He BJ, Snyder AZ, Vincent JL, Epstein A, Shulman GL, Corbetta M. Breakdown of functional connectivity in frontoparietal networks underlies behavioral deficits in spatial neglect. *Neuron* 2007;53(06):905–918
- 77 Corbetta M, Shulman GL. Control of goal-directed and stimulus-driven attention in the brain. *Nat Rev Neurosci* 2002;3(03):201–215
- 78 Fox MD, Zhang D, Snyder AZ, Raichle ME. The global signal and observed anticorrelated resting state brain networks. *J Neurophysiol* 2009;101(06):3270–3283
- 79 Corbetta M, Patel G, Shulman GL. The reorienting system of the human brain: from environment to theory of mind. *Neuron* 2008;58(03):306–324
- 80 Jerde TA, Merriam EP, Riggall AC, Hedges JH, Curtis CE. Prioritized maps of space in human frontoparietal cortex. *J Neurosci* 2012;32(48):17382–17390
- 81 Giesbrecht B, Woldorff MG, Song AW, Mangun GR. Neural mechanisms of top-down control during spatial and feature attention. *Neuroimage* 2003;19(03):496–512
- 82 Morishima Y, Akaishi R, Yamada Y, Okuda J, Toma K, Sakai K. Task-specific signal transmission from prefrontal cortex in visual selective attention. *Nat Neurosci* 2009;12(01):85–91
- 83 Slagter HA, Giesbrecht B, Kok A, et al. fMRI evidence for both generalized and specialized components of attentional control. *Brain Res* 2007;1177:90–102
- 84 Corbetta M, Tansy AP, Stanley CM, Astafiev SV, Snyder AZ, Shulman GL. A functional MRI study of preparatory signals for spatial location and objects. *Neuropsychologia* 2005;43(14):2041–2056
- 85 Rajan A, Meyyappan S, Liu Y, et al. The microstructure of attentional control in the dorsal attention network. *J Cogn Neurosci* 2021;33(06):965–983
- 86 Tordjman M, Madelin G, Gupta PK, et al. Functional connectivity of the default mode, dorsal attention and fronto-parietal executive control networks in glial tumor patients. *J Neurooncol* 2021;152(02):347–355
- 87 Lv H, Wang Z, Tong E, et al. Resting-state functional MRI: everything that nonexperts have always wanted to know. *AJNR Am J Neuroradiol* 2018;39(08):1390–1399
- 88 Metwali H, Raemaekers M, Kniese K, Samii A. Intraoperative resting-state functional connectivity and resting-state networks in patients with intracerebral lesions: detectability and variations between sessions. *World Neurosurg* 2020;133:e197–e204
- 89 Sparacia G, Parla G, Cannella R, et al. Resting-state functional magnetic resonance imaging for brain tumor surgical planning: feasibility in clinical setting. *World Neurosurg* 2019;131:356–363
- 90 Zacà D, Jovicich J, Corsini F, Rozzanigo U, Chioffi F, Sarubbo S. ReStNeuMap: a tool for automatic extraction of resting-state functional MRI networks in neurosurgical practice. *J Neurosurg* 2018;131(03):764–771
- 91 Denes G, Semenza C, Stoppa E, Lis A. Unilateral spatial neglect and recovery from hemiplegia: a follow-up study. *Brain* 1982;105(Pt 3):543–552
- 92 Bartolomeo P. The novelty effect in recovered hemineglect. *Cortex* 1997;33(02):323–332
- 93 De Schotten MT, Dell'Acqua F, Forkel S, et al. A Lateralized Brain Network for Visuospatial Attention (P02.026). *AAN Enterprises*; 2012
- 94 Thiebaut de Schotten M, Urbanski M, Duffau H, et al. Direct evidence for a parietal-frontal pathway subserving spatial awareness in humans. *Science* 2005;309(5744):2226–2228
- 95 Briggs RG, Lin Y-H, Dadario NB, et al. Anatomy and white matter connections of the middle frontal gyrus. *World Neurosurg* 2021;150:e520–e529
- 96 Duffau H. Lessons from brain mapping in surgery for low-grade glioma: insights into associations between tumour and brain plasticity. *Lancet Neurol* 2005;4(08):476–486
- 97 Duffau H, Capelle L. [Functional recuperation following lesions of the primary somatosensory fields. Study of compensatory mechanisms]. *Neurochirurgie* 2001;47(06):557–563
- 98 Duffau H, Capelle L, Denvil D, et al. Functional recovery after surgical resection of low grade gliomas in eloquent brain: hypothesis of brain compensation. *J Neurol Neurosurg Psychiatry* 2003;74(07):901–907
- 99 Herbet G, Lafargue G, Bonnetblanc F, Moritz-Gasser S, Duffau H. Is the right frontal cortex really crucial in the mentalizing network? A longitudinal study in patients with a slow-growing lesion. *Cortex* 2013;49(10):2711–2727
- 100 Sallard E, Barral J, Duffau H, Bonnetblanc F. Manual reaction times and brain dynamics after 'awake surgery' of slow-growing tumours invading the parietal area. A case report. *Brain Inj* 2012;26(13-14):1750–1755
- 101 Sallard E, Duffau H, Bonnetblanc F. Ultra-fast recovery from right neglect after 'awake surgery' for slow-growing tumor invading the left parietal area. *Neurocase* 2012;18(01):80–90
- 102 Charras P, Herbet G, Deverduin J, et al. Functional reorganization of the attentional networks in low-grade glioma patients: a longitudinal study. *Cortex* 2015;63:27–41
- 103 Banwinkler M, Theis H, Prange S, van Eimeren T. Imaging the limbic system in Parkinson's disease—a review of limbic pathology and clinical symptoms. *Brain Sci* 2022;12(09):1248
- 104 Rolls ET. Limbic systems for emotion and for memory, but no single limbic system. *Cortex* 2015;62:119–157
- 105 Edlow BL, McNab JA, Witzel T, Kinney HC. The structural connectome of the human central homeostatic network. *Brain Connect* 2016;6(03):187–200
- 106 Rajmohan V, Mohandas E. The limbic system. *Indian J Psychiatry* 2007;49(02):132–139
- 107 Rolls ET, Grabenhorst F. The orbitofrontal cortex and beyond: from affect to decision-making. *Prog Neurobiol* 2008;86(03):216–244
- 108 Crawford L. The Limbic System. <https://www.o8t.com/blog/limbic-system>. Published 2022
- 109 Li Y, Yu Z, Wu P, Chen J. Ability of an altered functional coupling between resting-state networks to predict behavioral outcomes in subcortical ischemic stroke: a longitudinal study. *Front Aging Neurosci* 2022;14:933567
- 110 Cauzzo S, Singh K, Stauder M, et al. Functional connectome of brainstem nuclei involved in autonomic, limbic, pain and sensory processing in living humans from 7. Tesla resting state fMRI. *Neuroimage* 2022;250:118925
- 111 Rolls ET. The cingulate cortex and limbic systems for emotion, action, and memory. *Brain Struct Funct* 2019;224(09):3001–3018
- 112 Vogt BA. Cingulate cortex in the three limbic subsystems. *Handb Clin Neurol* 2019;166:39–51
- 113 Rolls ET. The cingulate cortex and limbic systems for action, emotion, and memory. *Handb Clin Neurol* 2019;166:23–37
- 114 Mansouri A, Boutet A, Elias G, et al. Lesion network mapping analysis identifies potential cause of postoperative depression in a case of cingulate low-grade glioma. *World Neurosurg* 2020;133:278–282
- 115 Ülgen E, Aras FK, Coşgun E, et al. Correlation of anatomical involvement patterns of insular gliomas with subnetworks of the limbic system. *J Neurosurg* 2021;136(02):323–334
- 116 Eseonu CI, ReFaey K, Garcia O, et al. Volumetric analysis of extent of resection, survival, and surgical outcomes for insular gliomas. *World Neurosurg* 2017;103:265–274

- 117 Palejwala AH, Dadario NB, Young IM, et al. Anatomy and white matter connections of the lingual gyrus and cuneus. *World Neurosurg* 2021;151:e426–e437
- 118 Crawford L. The Visual System. <https://www.o8t.com/blog/visual-system>. Published 2022
- 119 Taubert J, Ritchie JB, Ungerleider LG, Baker CI. One object, two networks? Assessing the relationship between the face and body-selective regions in the primate visual system. *Brain Struct Funct* 2022;227(04):1423–1438
- 120 Bilevicius E, Kolesar TA, Smith SD, Trapnell PD, Kornelsen J. Trait emotional empathy and resting state functional connectivity in default mode, salience, and central executive networks. *Brain Sci* 2018;8(07):128
- 121 Griesbauer EM, Manley E, Wiener JM, Spiers HJ. London taxi drivers: a review of neurocognitive studies and an exploration of how they build their cognitive map of London. *Hippocampus* 2022;32(01):3–20
- 122 Feng C, Gu R, Li T, et al. Separate neural networks of implicit emotional processing between pictures and words: a coordinate-based meta-analysis of brain imaging studies. *Neurosci Biobehav Rev* 2021;131:331–344
- 123 Tamietto M, Pullens P, de Gelder B, Weiskrantz L, Goebel R. Subcortical connections to human amygdala and changes following destruction of the visual cortex. *Curr Biol* 2012;22(15):1449–1455
- 124 Tao D, He Z, Lin Y, Liu C, Tao Q. Where does fear originate in the brain? A coordinate-based meta-analysis of explicit and implicit fear processing. *Neuroimage* 2021;227:117686
- 125 Nebel MB, Eloyan A, Nettles CA, et al. Intrinsic visual-motor synchrony correlates with social deficits in autism. *Biol Psychiatry* 2016;79(08):633–641
- 126 Freud E, Plaut DC, Behrmann M. 'What' is happening in the dorsal visual pathway. *Trends Cogn Sci* 2016;20(10):773–784
- 127 Siegel M, Donner TH, Oostenveld R, Fries P, Engel AK. Neuronal synchronization along the dorsal visual pathway reflects the focus of spatial attention. *Neuron* 2008;60(04):709–719
- 128 Shen W, Tu Y, Gollub RL, et al. Visual network alterations in brain functional connectivity in chronic low back pain: a resting state functional connectivity and machine learning study. *Neuroimage Clin* 2019;22:101775
- 129 Lombardo MV, Eysler L, Moore A, et al. Default mode-visual network hypoconnectivity in an autism subtype with pronounced social visual engagement difficulties. *eLife* 2019;8:8
- 130 Duffau H. The huge plastic potential of adult brain and the role of connectomics: new insights provided by serial mappings in glioma surgery. *Cortex* 2014;58:325–337
- 131 Ng S, Deverdun J, Lemaitre AL, et al. Precuneal gliomas promote behaviorally relevant remodeling of the functional connectome. *J Neurosurg* 2022;\*\*\*:1–11
- 132 Hagner M. The electrical excitability of the brain: toward the emergence of an experiment. *J Hist Neurosci* 2012;21(03):237–249
- 133 Taylor CS, Gross CG. Twitches versus movements: a story of motor cortex. *Neuroscientist* 2003;9(05):332–342
- 134 Craig BT, Kinney-Lang E, Hilderley AJ, Carlson HL, Kirton A. Structural connectivity of the sensorimotor network within the non-lesioned hemisphere of children with perinatal stroke. *Sci Rep* 2022;12(01):3866
- 135 Baker CM, Burks JD, Briggs RG, et al. A connectomic atlas of the human cerebrum - Chapter 1: introduction, methods, and significance. *Oper Neurosurg (Hagerstown)* 2018;15(Suppl 1):S1–S9
- 136 Zalesky A, Akhlaghi H, Corben LA, et al. Cerebello-cerebral connectivity deficits in Friedreich ataxia. *Brain Struct Funct* 2014;219(03):969–981
- 137 Baker CM, Burks JD, Briggs RG, et al. A connectomic atlas of the human cerebrum - chapter 3: the motor, premotor, and sensory cortices. *Oper Neurosurg (Hagerstown)* 2018;15(Suppl 1):S75–S121
- 138 Breakspear M, Stam CJ. Dynamics of a neural system with a multiscale architecture. *Philos Trans R Soc Lond B Biol Sci* 2005;360(1457):1051–1074
- 139 Weinberger NM. Cortical plasticity in associative learning and memory. In: Byrne JH, ed. *Learning and Memory: A Comprehensive Reference*. Oxford: Academic Press; 2008:187–218
- 140 Andres FG, Mima T, Schulman AE, Dichgans J, Hallett M, Gerloff C. Functional coupling of human cortical sensorimotor areas during bimanual skill acquisition. *Brain* 1999;122(Pt 5):855–870
- 141 Blumberg MS. Developing sensorimotor systems in our sleep. *Curr Dir Psychol Sci* 2015;24(01):32–37
- 142 Toga AW, Clark KA, Thompson PM, Shattuck DW, Van Horn JD. Mapping the human connectome. *Neurosurgery* 2012;71(01):1–5
- 143 Flinker A, Korzeniewska A, Shestyuk AY, et al. Redefining the role of Broca's area in speech. *Proc Natl Acad Sci U S A* 2015;112(09):2871–2875
- 144 Yeo BT, Krienen FM, Sepulcre J, et al. The organization of the human cerebral cortex estimated by intrinsic functional connectivity. *J Neurophysiol* 2011;106(03):1125–1165
- 145 Margulies DS, Uddin LQ. Network convergence zones in the anterior midcingulate cortex. *Handb Clin Neurol* 2019;166:103–111
- 146 Chang EF, Niziolek CA, Knight RT, Nagarajan SS, Houde JF. Human cortical sensorimotor network underlying feedback control of vocal pitch. *Proc Natl Acad Sci U S A* 2013;110(07):2653–2658
- 147 Comstock DC, Hove MJ, Balasubramaniam R. Sensorimotor synchronization with auditory and visual modalities: behavioral and neural differences. *Front Comput Neurosci* 2018;12:53
- 148 de Araujo IE, Simon SA. The gustatory cortex and multisensory integration. *Int J Obes* 2009;33 Suppl 2(Suppl 2):S34–S43
- 149 Olivo G, Wiemerslage L, Nilsson EK, et al. Resting-state brain and the FTO obesity risk allele: default mode, sensorimotor, and salience network connectivity underlying different somatosensory integration and reward processing between genotypes. *Front Hum Neurosci* 2016;10:52
- 150 Stevens MC, Kiehl KA, Pearlson GD, Calhoun VD. Functional neural networks underlying response inhibition in adolescents and adults. *Behav Brain Res* 2007;181(01):12–22
- 151 Pi YL, Wu XH, Wang FJ, et al. Motor skill learning induces brain network plasticity: a diffusion-tensor imaging study. *PLoS One* 2019;14(02):e0210015
- 152 Doucet GE, Bassett DS, Yao N, Glahn DC, Frangou S. The role of intrinsic brain functional connectivity in vulnerability and resilience to bipolar disorder. *Am J Psychiatry* 2017;174(12):1214–1222
- 153 Bologna M, Paparella G. Neurodegeneration and sensorimotor function. *Brain Sci* 2020;10(11):808
- 154 Duffau H. Mapping the connectome in awake surgery for gliomas: an update. *J Neurosurg Sci* 2017;61(06):612–630
- 155 Duffau H. Brain connectomics applied to oncological neuroscience: from a traditional surgical strategy focusing on glioma topography to a meta-network approach. *Acta Neurochir (Wien)* 2021;163(04):905–917
- 156 Freyschlag CF, Duffau H. Awake brain mapping of cortex and subcortical pathways in brain tumor surgery. *J Neurosurg Sci* 2014;58(04):199–213
- 157 Schneider FC, Pailler M, Faillenot I, et al. Presurgical assessment of the sensorimotor cortex using resting-state fMRI. *AJNR Am J Neuroradiol* 2016;37(01):101–107
- 158 DeWitt I, Rauschecker JP. Wernicke's area revisited: parallel streams and word processing. *Brain Lang* 2013;127(02):181–191
- 159 Keller SS, Crow T, Foundas A, Amunts K, Roberts N. Broca's area: nomenclature, anatomy, typology and asymmetry. *Brain Lang* 2009;109(01):29–48
- 160 Fedorenko E, Thompson-Schill SL. Reworking the language network. *Trends Cogn Sci* 2014;18(03):120–126

- 161 Monroy-Sosa A, Chakravarthi SS, Cortes-Contreras AP, et al. The evolution of cerebral language localization: historical analysis and current trends. *World Neurosurg* 2021;145:89–97
- 162 Briggs RG, Conner AK, Baker CM, et al. A connectomic atlas of the human cerebrum - Chapter 18: the connectomic anatomy of human brain networks. *Oper Neurosurg (Hagerstown)* 2018;15 (Suppl 1):S470–S480
- 163 Parker GJ, Luzzi S, Alexander DC, Wheeler-Kingshott CA, Ciccarelli O, Lambon Ralph MA. Lateralization of ventral and dorsal auditory-language pathways in the human brain. *Neuroimage* 2005;24(03):656–666
- 164 Duffau H, Gatignol P, Mandonnet E, Peruzzi P, Tzourio-Mazoyer N, Capelle L. New insights into the anatomo-functional connectivity of the semantic system: a study using cortico-subcortical electrostimulations. *Brain* 2005;128(Pt 4):797–810
- 165 Linell P. The concept of phonological form and the activities of speech production and speech perception. *J Phonetics* 1982;10 (01):37–72
- 166 Catani M, Allin MP, Husain M, et al. Symmetries in human brain language pathways correlate with verbal recall. *Proc Natl Acad Sci U S A* 2007;104(43):17163–17168
- 167 Glasser MF, Coalson TS, Robinson EC, et al. A multi-modal parcellation of human cerebral cortex. *Nature* 2016;536 (7615):171–178
- 168 Ferstl EC, Neumann J, Bogler C, von Cramon DY. The extended language network: a meta-analysis of neuroimaging studies on text comprehension. *Hum Brain Mapp* 2008;29(05):581–593
- 169 Papathanassiou D, Etard O, Mellet E, Zago L, Mazoyer B, Tzourio-Mazoyer N. A common language network for comprehension and production: a contribution to the definition of language epicenters with PET. *Neuroimage* 2000;11(04):347–357
- 170 Baker CM, Burks JD, Briggs RG, et al. A connectomic atlas of the human cerebrum - chapter 6: the temporal lobe. *Oper Neurosurg (Hagerstown)* 2018;15(Suppl 1):S245–S294
- 171 Bajada CJ, Lambon Ralph MA, Cloutman LL. Transport for language south of the Sylvian fissure: the routes and history of the main tracts and stations in the ventral language network. *Cortex* 2015;69:141–151
- 172 Eichenbaum H, Yonelinas AP, Ranganath C. The medial temporal lobe and recognition memory. *Annu Rev Neurosci* 2007;30:123–152
- 173 Yuan B, Zhang N, Yan J, Cheng J, Lu J, Wu J. Resting-state functional connectivity predicts individual language impairment of patients with left hemispheric gliomas involving language network. *Neuroimage Clin* 2019;24:102023
- 174 van Dokkum LEH, Moritz Gasser S, Deverdun J, et al. Resting state network plasticity related to picture naming in low-grade glioma patients before and after resection. *Neuroimage Clin* 2019;24:102010
- 175 Bates E, Reilly J, Wulfeck B, et al. Differential effects of unilateral lesions on language production in children and adults. *Brain Lang* 2001;79(02):223–265
- 176 Glenn C, Conner AK, Rahimi M, Briggs RG, Baker C, Sughrue M. Common disconnections in glioma surgery: an anatomic description. *Cureus* 2017;9(10):e1778