



A Patient with Multiple System Atrophy-Parkinsonian Type Presenting with Progressive Micrographia

Halil Onder¹  Beyza Nur Cetin¹ Selcuk Comoglu¹

¹Neurology Clinic, Diskapi Yildirim Beyazit Training and Research Hospital, Ankara, Türkiye

Address for correspondence Halil Onder, MD, Neurology Clinic, Diskapi Yildirim Beyazit Training and Research Hospital, Şehit Ömer Halisdemir Street. No: 20 Altındag, Ankara, 06110, Türkiye (e-mail: halilOnder@yahoo.com).

Asian J Neurosurg 2024;19:277–279.

Abstract

Keywords

- ▶ progressive micrographia
- ▶ multiple system atrophy-parkinsonian type
- ▶ levodopa response
- ▶ pathophysiology

Herein, we present the case of a 57-year-old male patient who was admitted to our center due to progressive writing difficulty and slowness of his right hand over the last 3 years. In conclusion of the clinical and laboratory workup, a diagnosis of multiple system atrophy (MSA) was established. Our report on progressive micrographia (PM) constitutes a crucial sample remarking on this intriguing manifestation in another disease subtype of MSA, which differs from Parkinson's disease in terms of the clinical and pathophysiological processes. We think that further studies are warranted to clarify the significance of this entity in movement disorder in clinical practice and to reveal the underlying neural mechanisms.

Introduction

A 57-year-old right-handed male patient was admitted to our center with complaint of progressive writing difficulty and slowness of his right hand over the last 3 years. A diagnosis of Parkinson's disease (PD) was made in a different center 1 year ago where rasagiline 1 mg and pramipexole (titrated up to 3 mg daily) therapy was initiated, which provided a mild improvement in the patient's right-sided slowness. The patient had a history of rapid eye movement (REM) sleep behavior disorder and constipation for long years. Besides, he suffered from severe erectile dysfunction and neurogenic urinary incontinence for the last 4 years. On neurological examination at admission to our clinic, the patient was fully oriented and cooperative. The visual examinations revealed normal pursuit and saccadic eye movements. The motor and sensory examinations were normal, whereas the cerebellar examination revealed moderate truncal ataxia. The extrapyramidal examinations revealed bilateral bradykinesia and rigidity that was more prominent on the right side. Besides, hypophonia and severe postural instability were observed. Remarkably, the

handwriting examination revealed apparent progressive micrographia (PM; ▶ **Video 1**). The cranial magnetic resonance imaging (MRI) sequences showed posterolateral putaminal hypointensity on T2-weighted imaging and susceptibility weighted imaging (SWI; ▶ **Fig. 1A–C**). The MDS-Unified Parkinson's Disease Rating Scale (MDS-UPDRS) motor score was 40 points during the medication-off period. Levodopa/carbidopa/entacapone was added to the treatment and titrated up to a dosage of 3 × 100/25/200 mg that provided mild amelioration of the parkinsonian symptoms of bradykinesia and parkinsonian gait. The MDS-UPDRS motor score during the “on-medication” period was 32 points. Taken together, the patient met the criteria for clinically established multiple system atrophy (MSA).¹ Handwriting examination during the medication-on period showed mild improvement in PM. Quantitative measurements using a custom-written computer program also confirmed the improvement in the PM rate (▶ **Fig. 1D,E**). At the third month of follow-up, the patient was still receiving levodopa/carbidopa/entacapone (3 × 100/25/200 mg) therapy and defined mild benefit from the therapy. However, a mild deterioration was detected in his clinic. (The

article published online
June 10, 2024

DOI <https://doi.org/10.1055/s-0043-1771319>.
ISSN 2248-9614.

© 2024. Asian Congress of Neurological Surgeons. All rights reserved.

This is an open access article published by Thieme under the terms of the Creative Commons Attribution-NonDerivative-NonCommercial-License, permitting copying and reproduction so long as the original work is given appropriate credit. Contents may not be used for commercial purposes, or adapted, remixed, transformed or built upon. (<https://creativecommons.org/licenses/by-nc-nd/4.0/>)

Thieme Medical and Scientific Publishers Pvt. Ltd., A-12, 2nd Floor, Sector 2, Noida-201301 UP, India

MDS-UPDRS motor score was 42 points during the medication-off period.)

Video 1

The video images showing the handwriting of the patient. In the latter part of the video, the board-based and parkinsonian gait of the patient showing the slowness prominent in the right side is demonstrated. Online content including video sequences viewable at: <https://www.thieme-connect.com/products/ejournals/html/10.1055/s-0043-1771319>.

Discussion

Micrographia, a type of handwriting impairment, is characterized by small handwriting with a further progressive reduc-

tion in size is common in PD subjects.² It has been suggested to be a component of bradykinesia. However, recent studies proposed more controversial results, such that these two manifestations do not correlate frequently and micrographia can occur in the early phase of PD without accompanying bradykinesia.³ There is a tendency to classify micrographia in two forms: consistent micrographia (CM) and PM. Apart from the subtype of CM, which defines a global decrease in the letter size, PM refers to initially normal but decreasing size while writing.² These are hypothesized to represent two distinct manifestations that differ in terms of clinical features and underlying pathophysiology. For instance, PM is shown to be less responsive to levodopa, whereas levodopa provided marked amelioration in CM that was accompanied by increased activity and connectivity in the basal ganglia motor circuit.² On the other hand, the involvement of the neocortex by a Lewy body pathology is specifically discussed to be responsible for PM rather than a pathology of solely basal

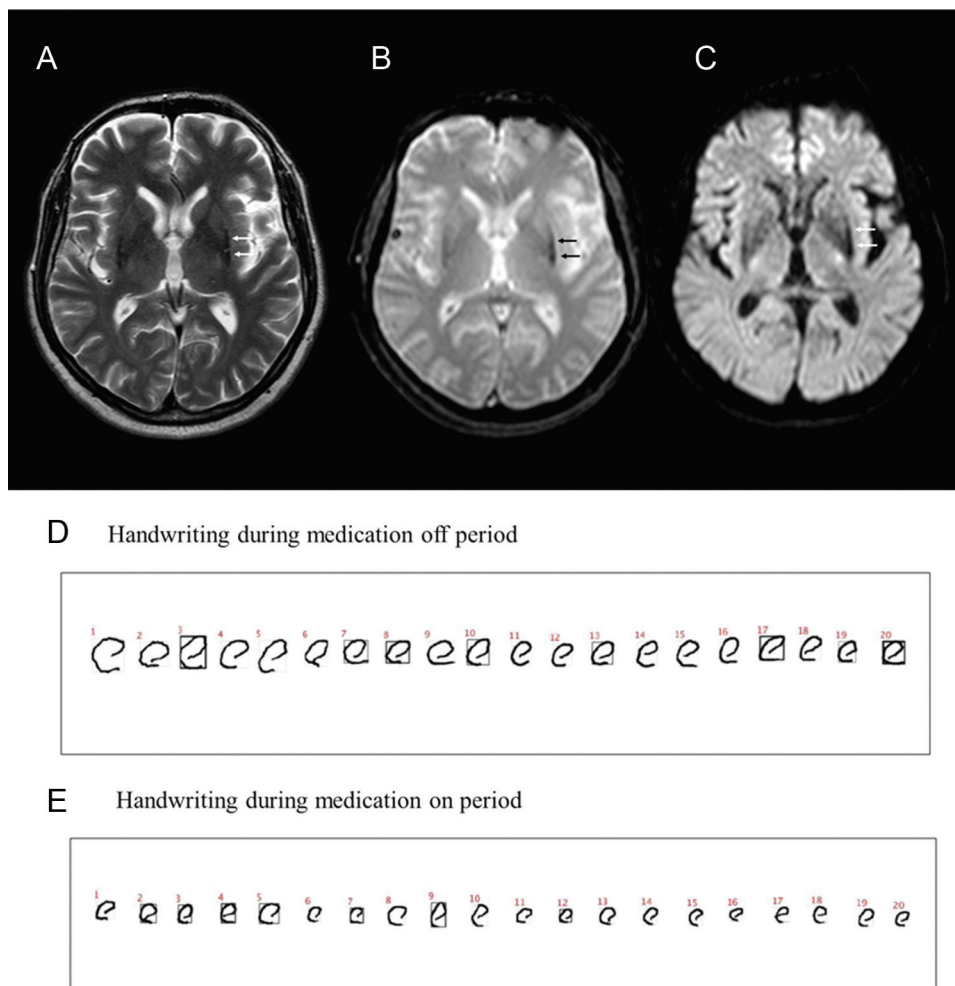


Fig. 1 The cranial magnetic resonance imaging (MRI) sequences showing the posterolateral putaminal hypointensity on (A) T2-weighted imaging, (B) susceptibility-weighted imaging, and (C) diffusion-weighted imaging. The quantitative measurement of the size of the letters were made with a digitizing tablet with an ink pen (Wacom Intuos Medium CTL-6100WLK) using a custom-written computer program to provide objective data about character size horizontally and vertically. (D) The size of the initial and final sets of five letters using x and y coordinates (in mm) were measured during the “off” period and “on” period. The initial measurements (during the “off” period) revealed 28% decrement in the horizontal size and 23% decrement in the vertical size of the letters. (E) The measurement during the “on” period confirmed the improvement in progressive micrographia (PM) quantitatively (horizontal decrement: 17% and vertical decrement: 20%). The rate of PM measured by the letter area (multiplying X by Y length) improved from 45 to 34% after levodopa therapy.

ganglia circuit underlying CM.⁴ Neuroimaging studies showed glucose hypometabolism in the left pre-supplementary motor area (pre-SMA) and right superior frontal gyrus selectively in PD patients with PM compared with the healthy controls (HC).⁴ In a recent functional MRI (fMRI) study by Wu et al, the authors suggested that disconnection between the rostral SMA, rostral cingulate motor area, and cerebellum likely contributes to PM in addition to dysfunction of the basal ganglia motor circuit.³ Remarkably, in a comparative study including PD and progressive supranuclear palsy (PSP) subjects, the letter size was found to be smaller in PSP subjects, whereas the decrement effect that is typical for PM is rather seen in PD subjects.⁵ In discussion, the authors suggested that PM may be rather specific for PD. However, to the best of our knowledge, the presence of micrographia in MSA subjects has not been investigated previously, which certainly makes our observation more interesting. In a case series, a unique case of a 68-year-old male MSA patient presenting with stooped posture, hypomimia, sialorrhea, micrographia, and gait difficulty was described.⁶ However, the onset time and clinical features of micrographia were not described.⁶ Cuoco et al compared the linguistic profiles among MSA and PD patients and HC using the “Screening for Aphasia in NeuroDegeneration” (SAND) questionnaire.⁷ In conclusion, they found that MSA patients performed worse in total MSA-tailored SAND Global Score, as compared to HC ($p < 0.01$)⁷ and the writing subscore was lowest in the MSA group. However, the authors removed the subscores of the writing task from analyses for the reason that the motor dysfunction of MSA could affect the writing task, which requires involvement of the motor circuit in addition to the language networks.⁷

We think that the subtype of PM, which requires the disturbance of a widespread neural network,^{3,4} surely constitutes a more intriguing motor phenomenon other than the classical micrographia and other motor symptoms. The improvement in PM with levodopa in our MSA subject was not notable, supporting the involvement of neurotransmitter systems other than dopaminergic as hypothesized in PD subjects.^{2,3} Supporting this view, Eklund et al. did not find any association between the severity of micrographia and dopamine transporter (DAT) binding in their large group of PD patients, suggesting nondopaminergic mechanism in PD micrographia.⁸ There are some critical distinctions in MSA, such that the α -synuclein accumulation also occurs in oligodendrocytes and the glial cytoplasmic inclusions are required for the pathological diagnosis of MSA.⁹ In addition to the involvement of the substantia nigra dopaminergic neurons, a selective involvement of GABAergic medium spiny neurons in the striatum constitutes specific features of MSA. Pathology studies on MSA subjects showed marked involvement of the motor and supplementary motor cortices,¹⁰ which are the anatomical regions, hypothesized specifically to be involved in PM pathophysiology.⁴ Therefore, the illustration of micrographia in MSA, which is totally a distinct entity from PD, may give interesting perspectives for further deliberation.

In conclusion, our report on PM constitutes a crucial sample remarking on this intriguing manifestation in another disease subtype of MSA that differs from PD in terms of the clinical and pathophysiological processes. We think that further studies are warranted to clarify the significance of this entity in movement disorders in clinical practice and to reveal the underlying neural mechanisms.

Patients' Consent

Signed informed consent has been obtained from the patient and his spouse. We confirm that we have read the journal's position on issues involved in ethical publication and affirm that this work is consistent with those guidelines.

Author's Contributions

H.O. contributed to the concept and design of the study, literature search, and writing the manuscript. Supervision and critical review were done by S.C. Material collection was done by H.O, S.K., and S.C. Data collection and/or processing and analysis and/or interpretation were done by HO., B.N.C., S.C.

Funding

None.

Conflict of Interest

None declared.

References

- 1 Wenning GK, Stankovic I, Vignatelli L, et al. The Movement Disorder Society criteria for the diagnosis of multiple system atrophy. *Mov Disord* 2022;37(06):1131–1148
- 2 Wagle Shukla A, Ounpraseuth S, Okun MS, Gray V, Schwankhaus J, Metzger WS. Micrographia and related deficits in Parkinson's disease: a cross-sectional study. *BMJ Open* 2012;2(03):e000628
- 3 Wu T, Zhang J, Hallett M, Feng T, Hou Y, Chan P. Neural correlates underlying micrographia in Parkinson's disease. *Brain* 2016;139 (Pt 1):144–160
- 4 Kanno S, Shinohara M, Kanno K, et al. Neural substrates underlying progressive micrographia in Parkinson's disease. *Brain Behav* 2020;10(08):e01669
- 5 Ling H, Massey LA, Lees AJ, Brown P, Day BL. Hypokinesia without decrement distinguishes progressive supranuclear palsy from Parkinson's disease. *Brain* 2012;135(04):1141–1153
- 6 Koga S, Li F, Zhao N, et al. Clinicopathologic and genetic features of multiple system atrophy with Lewy body disease. *Brain Pathol* 2020;30(04):766–778
- 7 Cuoco S, Picillo M, Carotenuto I, et al. The language profile in multiple system atrophy: an exploratory study. *J Neural Transm (Vienna)* 2021;128(08):1195–1203
- 8 Eklund M, Nuutila S, Joutsa J, et al. Diagnostic value of micrographia in Parkinson's disease: a study with [¹²³I]FP-CIT SPECT. *J Neural Transm (Vienna)* 2022;129(07):895–904
- 9 Monzio Compagnoni G, Di Fonzo A. Understanding the pathogenesis of multiple system atrophy: state of the art and future perspectives. *Acta Neuropathol Commun* 2019;7(01):113
- 10 Tsuchiya K, Ozawa E, Haga C, et al. Constant involvement of the Betz cells and pyramidal tract in multiple system atrophy: a clinicopathological study of seven autopsy cases. *Acta Neuropathol* 2000;99(06):628–636