Article published online: 2023-09-28

Can a Single Glomerulus Morphology Implicate Successful Therapy?

Mohamed O. Ezwaie[1] Sabah M. Elbarasi[2] Huda A. Shawish[1]

[1] Nephrology and Hemodialysis Division, Benghazi Medical Center, Faculty of Medicine, University of Benghazi, Benghazi, Libya
[2] Nephrology Division, National Cardiac Center, Faculty of Medicine, University of Benghazi-Libya, Benghazi, Libya

Address for correspondence Mohamed O. Ezwaie, Nephrology and Hemodialysis Division, Benghazi Medical Center, Faculty of Medicine, University of Benghazi- Libya, Benghazi, Libya (e-mail: ezwaie@gmail.com).

Libyan Int Medical Univ J 2023;8:54–59.

Abstract

Recurrent gross hematuria of glomerular origin is frequently encountered in clinical practice, and in absence of specific serological marker, renal biopsy is mandatory to address the definitive diagnosis, and set out an appropriate therapeutic protocol. Technical deficiencies associated with practice of renal biopsy are frequently encountered, as inadequate number of glomeruli or poor immunofluorescence staining of kidney biopsy specimen; however, these deficiencies can be offset by detailed electron microscopy analysis of a single abnormal glom.

We present a single middle-aged Libyan woman, with a rare glomerular disease, related to abnormal activation of alternative complement pathway, where renal biopsy report was initially not adequate and lacking immunohistochemistry workup. However, electron microscopy reports a characteristic abnormal glomerular deposit, coupled with clinical and biochemical data that guided our therapeutic protocol.

In a middle-aged female who presented with recurrent gross hematuria and nephrotic range proteinuria, we should suspect a glomerular pathology. Further to immunoglobulin A nephropathy or lupus nephritis, particularly in presence of complement abnormalities and negative serology for glomerulopathy-related autoantibodies, dense deposit disease and C3 glomerulonephritis that are rare complement mediated glomerulopathy should be considered as a seronegative lupus nephritis-equivalent, in terms of their membranoproliferative features on light microscopy, and when setting out appropriate therapeutic protocol. Patient and family counseling for C3 glomerulopathy is essential because this type of glomerulopathy has a recurrence rate after kidney transplant.

Keywords
- recurrent gross hematuria
- C3 glomerulopathy
- dense deposit disease
- complement system
- renal biopsy

article published online
September 28, 2023

DOI https://doi.org/10.1055/s-0043-1771361.
ISSN 2519-139X.

© 2023. The Author(s).
This is an open access article published by Thieme under the terms of the Creative Commons Attribution License, permitting unrestricted use, distribution, and reproduction so long as the original work is properly cited. (https://creativecommons.org/licenses/by/4.0/)
Thieme Medical and Scientific Publishers Pvt. Ltd., A-12, 2nd Floor, Sector 2, Noida-201301 UP, India

ملخص المقال باللغة العربية

هل يمكن لمورفولوجيا الكبيبة المفردة أن تضمن علاجاً ناجحاً؟

المؤلفون:

محمد الزوي، صباح البرعصي، هدي شاوش. كلية الطب، جامعة بنغازي، ليبيا.

المؤلف المسؤول: محمد الزوي ، **البريد الإلكتروني-** ezwaie@gmail.com

في الممارسة السريرية يتم كثيراً مصادفة البيلة الدموية الظاهرة المتكررة ذات الأصل الكبيبي. وفي حالة عدم وجود علامة مصلية محددة، فإن خزعة الكلى تصبح إلزامية للوصول إلى التشخيص النهائي ووضع بروتوكول علاجي مناسب. ومن ناحية أخري فإن ممارسة الخزعة الكلوية قد يعترضها العديد من أوجه القصور الفنية المرتبطة، مثل عدم كفاية عدد الكبيبات أو ضعف في صبغة الخلايا المناعي. ومع ذلك، يمكن تعويض هذه العيوب عن طريق التحليل المجهري الإلكتروني المفصل لكبة واحدة غير طبيعية.

في هذا البحث نقدم امرأة ليبية في منتصف العمر، مصابة بمرض نادر في الكبيبات، مرتبط بتنشيط غير طبيعي للمسار البديل في الكلية. تقرير الخزعة الكلوية في البداية لم يكن كافياً ويفتقر إلى الكيمياء الهيستولوجية المناعية، ولذلك قمنا بالفحص المجهري الإلكتروني والذي أشار إلى وجود ترسبات كبيبية مميزة غير طبيعية. ذلك إلى جانب البيانات السريرية والكيميائية الحيوية التي وجهت بروتوكولنا العلاجي.

في أنثى في منتصف العمر تعاني من بيلة دموية متكررة وبيلة بروتينية كلوية. بالإضافة إلى اعتلال الكلية بالجلوبيولين المناعي نوع (أ) أو التهاب الكلية الذئبي، لا سيما في حالة وجود تشوهات تكميلية وأمصال سلبية للأجسام المضادة المرتبطة بالاعتلال الكبيبي، ومرض الرواسب الكثيفة والتهاب كبيبات الكلى الذي يعتبر نادراً من اعتلال الكبيبات التكميلي، يجب اعتبار كل ذلك مرادفاً لالتهاب الكلية الذئبي السلبي المصلي، من حيث خصائصها الغشائية التكاثرية في الفحص المجهري الإلكتروني، وكذلك عند وضع البروتوكول العلاجي المناسب. إن تقديم المشورة للمريض والأسرة بشأن اعتلال كبيبات الكلي أمر ضروري لأن هذا النوع من اعتلال الكبيبات له معدل تكرار عالٍ بعد زراعة الكلى.

الكلمات المفتاحية: بيلة دموية متكررة، اعتلال كبيبات الكلية، مرض ترسب كثيف، نظام مكمل، خزعة كلوية.

Introduction

Clinical manifestations of glomerulonephritis (GN) range from the asymptomatic person who is discovered to have hypertension or microscopic hematuria during a routine medical examination to patients who may present with proteinuria, gross recurrent hematuria, or even rapidly progressing GN.[1] Awareness of such spectrum of clinical presentation is mandatory to practicing physicians, for early detection and management of these nephritides to avoid progression to end-stage renal disease.

Renal biopsy is considered a valuable diagnostic tool in glomerular diseases, particularly in the setting of overlapping clinical presentation, and paucity of definitive serological marker: moreover, it provides direct exploration of the type and extent of renal pathology, providing a robust guide for the therapy.[2] Nonetheless, many renal biopsy reports are considered inadequate based on number of glomeruli obtained in the biopsy core; ideally, they should not be less than 10 to 12 glomeruli, for proper processing for light microscopy or immunohistochemistry staining (immunofluorescence and immunoperoxidase sections). Nevertheless, even with a single glom, use of detailed electron microscopy (EM) examination can provide valuable information. Furthermore, abnormalities of complement system (primary or secondary defects) play central role in pathogenesis of many glomerulopathies, and we should consider them in differential diagnosis of patients presenting with recurrent hematuria.

We present a case with rare glomerular disease that her renal biopsy report was initially not adequate and lacking immunohistochemistry workup. However, E/M report eventually addressed abnormal glomerular deposits, coupled with clinical and biochemical data that guided our therapy protocol with remarkable patient outcome.

Case Presentation

In October 2021, a single Libyan woman, in her mid-thirties (35 years) with no previous medical problems, presented to our nephrology clinic, complaining of several episodes of red discoloration of her urine over the last 3 months, lasting few days, and subside spontaneously. No history of dietary or drug was found that may cause urine discoloration. These episodes of gross hematuria were not associated with pain or other significant associated urinary tract symptoms. There was no history of lower limb swelling or facial puffiness. She had reported two episodes of hematuria that are linked to concurrent upper respiratory infection. She denied bleeding from any site, skin rash, or oral ulceration. She had no

significant family history of similar illness. She denied any history of coronavirus disease 2019 (COVID-19) infection.

Her physical examination revealed average body-built woman, her blood pressure was 110/70 mm Hg, pulse 88 beats per minute, pale conjunctivae, normal throat, and mild pitting lower limb edema. No skin rash, photosensitivity, or alopecia was found. Precordial, chest, and breast examination were normal.

Her initial blood testing showed that hemoglobin was 10.9 g/dl (12–15 g/dL), mean corpuscular volume 76 fL (80–100 fL), white blood cell (WBC) was $6.1 \times 10^3/\mu L$ ($4–11 \times 10^3/\mu L$), platelet count was $254 \times 10^3/\mu L$ ($150–450 \times 10^3/\mu L$). Urine sediment examination showed protein +++, WBC was 1–4/HPF (high-power filed [0-5]), red blood cell (RBC) was 25–50/HPF (0-3) with irregular shape, no cast, no crystals. Blood chemistry showed urea was 41 mg/dL (15–50 mg/dL), creatinine was 0.5 mg/dL (0.5–0.9 mg/dl), K^+ was 3.64 mmol/L (3.5–5.5 mmol/L), Na was 137 mmol/L (135–148 mmol/L), serum albumin was 3.1 g/dL (4–6 g/dL), calcium was 7.6 mg/dL (8.4–10.2 g/dL), was uric acid 4.3 mg/dL (3.5–5.7 g/dL), low-density lipoprotein was 254 mg/dL (100–129 g/dL), triglycerides was 134 mg/dL (50–200 g/dL), hemoglobin A1c was 5.4% (5.5–6.4%), transferrin saturation was 14% (20–50), C3 was 0.2 g/L (0.9–1.8 g/L), and C4 was 0.3 g/L (0.2–0.5 g/L). Chest imaging showed no signs of pulmonary or pleural disease. Serological workup for autoantibodies showed antistreptolysin-O titer was normal, positive for antinuclear antibodies with titer of 1:64, and was negative for anti-ds-DNA level 0.1 and 0.3 (< 25, repeated twice), while anticytoplasmic antibodies, antiphospholipid, and antiglomerular basement membrane (GBM) antibodies were all negative. Urine protein: creatinine ratio (UPCR) was 2.2 mg/g (< 0.2 mg/mg), which after 2 and 4 weeks became 3.1 and 4.4 mg/mg, respectively (nephrotic range). COVID-19 immunoglobulin M and immunoglobulin G (IgG) antibodies were negative. Peripheral blood film showed no evidence of schistocytes. On ultrasonography, both kidneys were normal in size and Echo showed no evidence of any pelvic or abdominal masses.

Presence of significant proteinuria mandates renoprotective measures, using low dose enalapril 2.5-5mg per day, statins for hyperlipidemia, atorvastatin 40 mg once daily, and starting steroid therapy, prednisolone 1mg /kg, for 6-8 weeks, to achieve clinical and renal remission, and to proceed with gradual tapering of steroid therapy thereafter. Patient treatment is further supplemented with iron tablet, to treat her iron deficiency anemia.

A month later, she came with cushingoid facies, blood pressure of 120/70 mm Hg, biochemical data—fasting blood glucose, 87 mg/dL (70–110 mg/dL); urea, 34 mg/dL; creatinine, 0.7 mg/dL—and with improvement of her lipid profile. Urine analysis showed ongoing hematuria of 12–20/HPF and significant proteinuria (UPCR 3 mg/g) and for this reason azathioprine tablet (50 mg twice daily) was added.

Over a period of 2 months, the patient was monitored. We observe improvement in her clinical picture (no gross hematuria no more pitting edema) but on laboratory level she had persistent microscopic hematuria and nephrotic range proteinuria (urine RBC 60–70/HPF, 24 urine collection for protein 4.8 g). Low C3 and normal C4 indicate that complement-mediated glomerulopathy and immunoglobulin A (IgA) nephropathy have been excluded on this basis. Renal biopsy was advised for the patient (3 months after her first presentation) and because of technical issue the biopsy report (January 2022) was deficient as under light microscopic examination of serial sections only one glomerulus was seen and showed segmentally thickened capillary basement membrane and mesangial expansion, EM ultrastructural examination (►**Fig. 1**) revealed GBM thickening with extensive subendothelial electron dense deposits (ribbon like), and large globular mesangial densities, going with the picture of membranoproliferative C3 GP or lupus nephritis.

At this stage, mycophenolate mofetil (MMF) tablet 1 g twice per day was prescribed for 2 months, replacing azathioprine, with prednisolone 0.5 mg/kg mg per day, as we adopted lupus nephritis-equivalent treatment regimen. In close follow-up over next 6 months, in August 2022, patient showed remarkable clinical and biochemical improvement, with complete remission, as no microscopic hematuria was found; urine RBC was 0–2 HPF, her U_{PCR} was 0.14, and C3 and C4 returned to normal level of 0.64 and 0.28, respectively, with normal renal function. She is currently on MMF tablet 500 mg twice per day, and prednisolone tablet 10 mg daily.

Based on renal biopsy report, together with persistently low C3 level, normal C4 level, and no serological markers of lupus nephritis, we conveniently diagnosed C3 glomerulopathy; possibly dense deposit disease (DDD) pattern.

Discussion

Recurrent hematuria is significant clinical problem; screening programs show a prevalence of 0.18 to 16.1% among apparently healthy individuals, and glomerular hematuria contributes to a significant proportion of these cases in adults.[3] Presence of glomerular hematuria alerts physicians' attention to broad differential diagnosis (►**Table 1**.[4–9]).

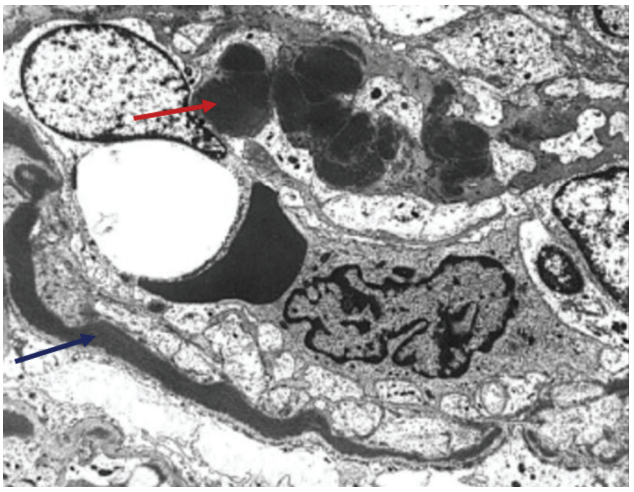

Fig. 1 Dense deposit disease with ribbon-like dense deposits along the basement membrane lamina densa (blue arrow), and large globular mesangial densities (red arrow).

Table 1 Systematic approach to recurrent gross hematuria

	Systematic approach to patients with recurrent gross hematuria					
- Review drug history (anticoagulants) - Rule out renal stones, polycystic kidneys, or urological malignancies; renal cell carcinoma or bladder carcinoma (ultrasound/ CT abdomen)						
If above ruled out, and urine sediment examination shows acanthocytes, RBC casts, and proteinuria Glomerular hematuria						
Disease characters	**IgA nephropathy**	**Lupus nephritis**	**C3 glomerulopathy**	**Atypical hemolytic uremic syndrome**	**Thin membrane disease**	**Alport syndrome**
Incidence; per 100,000 of population (related reference)	3.1–4.5 cases, according to geographic area[4]	20–150 cases, may be higher in woman and black race[5]	0.1–0.2 cases,[6] a rare glomerulopathy	<0.1 cases,[7] a rare glomerulopathy	1000,[8] a common benign condition	1–2[9] relatively rare hereditary disease
Precipitating factor	Synpharyngitic hematuria	Provoked by systemic flares of lupus	No specific precipitating factor	- Pregnancy, kidney transplantation or its therapy, non-enteric bacterial infections	No specific precipitating factor	No specific precipitating factor
Family history /genetic mutations	Majority are sporadic cases. But familial clustering possible	Association with HLA-DR2/DR3 alleles	- Mostly acquired form - Familial cases reported, due to genetic mutations of complement alternative pathway	- Mostly acquired form - 20% Familial/ genetic mutations cases reported	Autosomal dominant from parents to their children	Autosomal dominant X-linked, AR, both males and females are affected
Systemic manifestations	- No systemic manifestations - Clinical associations; celiac disease, and dermatitis herpetiformis	- Involving several organs; skin, joints, pulmonary, cardiac, renal, nervous system	Few cases demonstrate partial lipodystrophy, and macular degeneration	- Symptomatic anemia - Petechial skin rash	- No systemic manifestations	- Sensorineural deafness - Ocular abnormalities
Specific serological markers	- No specific autoantibody - Measurement of serum galactosylated-IgA level and IgA/C3 ratio	- Several autoantibodies; - Anti-ds DNA - Anti-histone antiphospholipid	- Low C3, normal C4 level - Circulating C3-nef autoantibodies - Complement factor- H mutations analysis	- Thrombocytopenia - Peripheral blood schistocytes - Complement factor- H mutations analysis	- No specific autoantibody	- No specific autoantibody
Renal biopsy	- Characteristic IgA mesangial deposition - Few C3 or other Ig deposits - No C1q deposits	- Several histological classes, wire-loop lesions - Full house immune complex, C3, C4, and C1q deposits	- Membranoproliferative pattern on light microscopy - C3 deposits on immunofluorescence - Characteristic dense deposits according to DDD or C3 GN pattern (see discussion paragraph)	- Thrombotic microangiopathy pattern with glomerular and arteriolar involvement, and double contouring of GBM	- Uniformly thinning of lamina densa of GBM - Occasional IgM or IgG deposits, - No complement deposits	- Thich GBM - Loss of normal staining for alpha 3 and alpha 4 proteins - No complement deposits

Abbreviations: AR, autosomal recessive; CT, computed tomography; GBM, glomerular basement membrane; HLA-DR2/DR3, human leukocyte antigen; IgA, immunoglobulin A; IgG, immunoglobulin G; IgM, immunoglobulin M.

 © 2023. The Author(s).

The case presented with recurrent episodes of painless hematuria, no history of coagulopathy medications, no evidence of renal stones, and no evidence of urological malignancies; urine sediment examination repeatedly showed hematuria with nephrotic range proteinuria (UPCR 4.2) associated with hyperlipidemia, makes hematuria of glomerular origin is the most likely pathology. These episodes of hematuria are not associated with history of Pharyngitis. No features of systemic lupus (photosensitivity, malar rash, arthritis, or oral ulcers), no features of systemic vasculitis, acrocyanosis, or cutaneous lipodystrophy. Family history was negative for similar episodes or any renal disease. No evidence of previous streptococcal infection or COVID-19 infection was found. This clinical presentation was further supplemented by laboratory data, which showed persistently low level of C3 and normal C4 level (excluding IgA nephropathy) and absence of thrombocytopenia (excluding hemolytic uremic syndrome). Patient's screening was negative for glomerulopathy-related autoantibodies. Due to persistence of microscopic hematuria with no serological diagnosis, request for renal biopsy was made. Renal biopsy report showed, light microscopic examination of serial sections, only one glomerulus was seen and segmentally thickened capillary basement membrane and mesangial expansion. E/M ultrastructural examination (►**Fig. 1**) revealed GBM thickening with extensive subendothelial electron dense deposits (ribbon-like). Segmental GBM duplication was detected, mesangial expansion by electron dense deposits (ribbon-like appearance). There had been a segmental GBM duplication with mesangial expansion due to electron dense deposits. Therefore, the diagnosis is in favor of C3 GP of DDD type, rather than IgA nephropathy or lupus nephritis. Many case reports addressed the nonbenign nature of this emerging glomerulopathy. We do treat our patient as lupus nephritis-equivalent disease, with combination of regular dose of MMF 2 g per day, with prednisolone starting dose of 0.5 mg/kg/day for 8 weeks. Patient is currently on MMF 500 mg twice per day, and low dose prednisolone (10 mg/day), maintaining clinical and biochemical remission for 6 months; after renal biopsy diagnosis, prednisolone dose will be reduced to 5 mg/day, with close monitoring of her clinical and biochemical status for any relapses.

Abnormalities of complement pathway, whether due to genetic or quired defects (primary or secondary to immune complex deposition), could result in a variety of diseases, namely thrombotic microangiopathies and glomerulonephritides. Abnormalities of classical pathway, such as C1q deficiency, are associated with impaired ability of complement system to clear immune complexes and cellular debris, resulting in lupus-like illness. While abnormalities of alternative pathway activation are usually associated with low circulating C3 levels, and result in overt-deposition of C3 component and development of C3 glomerulopathy.[10]

Advances in classification of GN have been set out, where, a consensus conference in Cambridge (UK) in 2012, renamed type II Membranoproliferative GN to a new terminology, as "C3 glomerulopathy" (C3 GP).[11–13] C3 GP is a recently introduced terminology, a rare form of glomerulopathy (►**Table 1**) due to abnormalities of alternative complement pathway activation, in most cases characterized by membranoproliferative appearance on light microscopy with strong deposition of C3 component on immunofluorescence,[14] without significant staining for immunoglobulins or components of classical pathway activation (C1q, C4). Based on E/M appearance, C3 GP has been further classified into; DDD where GBM is replaced by bands of intramembranous osmiophilic lamina densa deposits, may be associated with large electron densities in the mesengium, and C3 GN characterized by presence of less dense deposits of C3 in the mesangial, subendothelial, and subepithelial portions of glomerulus.[15] The incidence of C3 GP is quite low. Up to now, no known geographic variations. A British case series study identified 80 cases over 17 years duration, with incidence of 0.1 to 0.2 per 100,000, the ratio of C3 GN/DDD is 3:1, DDD tends to occur in younger age group, with female performance, female to male ratio 3:1 compared to C3 GN, where the latter one occurs around 30 years of age.[6,15] They share common clinical presentation, with nephrotic syndrome occurring in two-third of cases of C3 GP, associated with recurrent hematuria and hypertension; about 20% of patient's have nephritic syndrome presentation.[16] In minority, DDD is associated with macular degeneration and partial lipodystrophy (symmetric loss of adipose tissue) of face, arms, and upper trunk. C3 GP is not a benign glomerulopathy, proteinuria tends to persist, 50% of patient's progress to end-stage renal disease within 10 years of diagnosis, with young females having greatest risk.[16] A case series of 26 cases in New Zealand with median follow-up to 30 months, combination therapy (MMF+ prednisolone) used in 12 cases, resulted in complete remission in 17% of cases, partial remission (stable disease) in 58% of cases, while, ESRD occurred in 50% of untreated cases, compared to 25% in treated cases.[17] Recurrence after kidney transplantation is high; up to 50% of recipients eventually lose their graft within 5 years of transplantation, a fact that requires patient and family counselling, and need for specific complement 5 (C5) blocking therapy as eculizumab to save kidney graft from progressive damage and loss.[18]

Conclusions

IgA nephropathy and lupus nephritis are both characterized by recurrent gross hematuria with nephrotic range proteinuria. Others, such as C3-GN or DDD that are considered seronegative lupus nephritis-equivalents, must be ruled out in the context of complement abnormalities and negative serology results for glomerulopathy-related autoantibodies. Validated C3-GN diagnosis with EM report is essential for appropriate treatment protocol, planning for kidney transplantation, and prognosis.

Conflict of Interest
None declared.

References

1 Chang JH, Kim DK, Kim HW, et al. Changing prevalence of glomerular diseases in Korean adults: a review of 20 years of experience. Nephrol Dial Transplant 2009;24(08):2406–2410

2 Richards NT, Darby S, Howie AJ, Adu D, Michael J. Knowledge of renal histology alters patient management in over 40% of cases. Nephrol Dial Transplant 1994;9(09):1255–1259
3 Moreno JA, Sevillano Á, Gutiérrez E, et al. Glomerular hematuria; causes or consequence of renal inflammation. Int J Mol Sci 2019; 20(09):2205
4 Schena FP, Nistor I. Epidemiology of IgA nephropathy: a global perspective. Semin Nephrol 2018;38(05):435–442
5 Danchenko N, Satia JA, Anthony MS. Epidemiology of systemic lupus erythematosus: a comparison of worldwide disease burden. Lupus 2006;15(05):308–318
6 Smith RJH, Appel GB, Blom AM, et al. C3 glomerulopathy - understanding a rare complement-driven renal disease. Nat Rev Nephrol 2019;15(03):129–143
7 Yan K, Desai K, Gullapalli L, Druyts E, Balijepalli C. epidemiology of atypical hemolytic uremic syndrome: a systematic literature review. Clin Epidemiol 2020;12:295–305
8 Haas M. Thin glomerular membrane nephropathy. Arch Pathol Lab Med 2006;130:•••
9 Saran R, Li Y, Robinson B, et al. US renal data system 2015 annual data report: epidemiology of kidney disease in the United States. Am J Kidney Dis 2016;67(3, Suppl 1):S1–S305
10 Ballanti E, Perricone C, Greco E, et al. Complement and autoimmunity. Immunol Res 2013;56(2-3):477–491
11 Schena FP, Esposito P, Rossini M. A narrative review on C3 glomerulopathy: a rare renal disease. Int J Mol Sci 2020;21 (02):525
12 Pickering MC, D'Agati VD, Nester CM, et al. C3 glomerulopathy: consensus report. Kidney Int 2013;84(06):1079–1089
13 Tinawi M. Update on the etiology, classification, and management of glomerular diseases. Avicenna J Med 2019;10(02):61–67
14 Sethi S, Fervenza FC. Membranoproliferative glomerulonephritis–a new look at an old entity. N Engl J Med 2012;366(12):1119–1131
15 Medjeral-Thomas NR, O'Shaughnessy MM, O'Regan JA, et al. C3 glomerulopathy: clinicopathologic features and predictors of outcome. Clin J Am Soc Nephrol 2014;9(01):46–53
16 Lu DF, Moon M, Lanning LD, McCarthy AM, Smith RJ. Clinical features and outcomes of 98 children and adults with dense deposit disease. Pediatr Nephrol 2012;27(05):773–781
17 Sutherland LJ, Talreja H. C3-glomerulonephritis in New Zealand - a case series. BMC Nephrol 2020;21(01):399
18 McCaughan JA, O'Rourke DM, Courtney AE. Recurrent dense deposit disease after renal transplantation: an emerging role for complementary therapies. Am J Transplant 2012;12(04):1046–1051